


MANUAL OF OPHTHALMIC PLASTIC AND RECONSTRUCTIVE SURGERY

GUILHERME CASTELA



MANUAL OF OPHTHALMIC PLASTIC AND RECONSTRUCTIVE SURGERY

Editor and author: Guilherme Castela

Proofreading: Guilherme Castela, Filipa Ponces e Nádia Lopes

Linguistic review: Jean Burrows

Cover image: Hugo Castela

Illustrations on Chapter 1: Ana Fonseca

Illustrations on Chapter 2 and 3: Ricardo Correia

1st Edition - October 2016

Design and layout: Ricardo Correia

ISBN: 978-989-98118-5-0

Legal deposit: 415575/16

Circulation: 1,100 copies

Printed at: Ondagrafe - Artes Gráficas, Lda. Loures - Portugal

Published by:

Sociedade Portuguesa de Oftalmologia

Campo Pequeno, 2 - 13º

1000-078 Lisboa

All rights reserved. No part of this book shall be reproduced, stored in a retrieval system, or transmitted by any means – electronic, mechanical, photocopying, recording, or otherwise – without written permission from the publisher and the author.

All texts, diagrams and images in this book are responsibility of their authors.

All the content of this book was published without any interference from Théa Portugal S.A.

MANUAL OF OPHTHALMIC PLASTIC AND RECONSTRUCTIVE SURGERY

Editor and Author
Guilherme Castela



Authors

Editor and Author



Guilherme Castela

Head of the Orbit and Oculoplastics Unit, Department of Ophthalmology, Centro Hospitalar e Universitário de Coimbra, Portugal.

Invited assistant professor of Ophthalmology, Medical School, University of Coimbra, Portugal.

Co-authors

Ana Amaro

Orbit and Oculoplastics Unit, Department of Ophthalmology, Centro Hospitalar de Lisboa Central, Portugal.

Ana Cabugueira

Ophthalmology Resident, Department of Ophthalmology, Centro Hospitalar de Lisboa Central, Portugal.

Ana Duarte

Fellow of Oculoplastic and Orbit at the Department of Ophthalmology, Otorhinolaryngology and Head and Neck Surgery, School of Medicine of Ribeirão Preto, University of São Paulo, São Paulo, Brazil.

Ana Magriço

Orbit and Oculoplastics Unit, Department of Ophthalmology, Centro Hospitalar de Lisboa Central, Portugal.

Ana Paula Pina

Orbit and Oculoplastics Unit, Department of Ophthalmology, Centro Hospitalar de São João, Porto, Portugal.

Ana Rosa Pimentel

Associated Professor, Head of Ophthalmology and Otorhinolaryngology department, Medical School, Federal University of Minas Gerais, Belo Horizonte, Brazil.

Head of the Oculoplastics, Orbit and Lacrimal Unit, Hospital São Geraldo, Belo Horizonte, Brazil.

Andreia Silva

Ophthalmology Resident, Department of Ophthalmology, Centro Hospitalar Universitário de Coimbra, Portugal.

Antonio Augusto Velasco e Cruz

Department of Ophthalmology, Otorhinolaryngology and Head and Neck Surgery, Hospital das Clínicas of Ribeirão Preto School of Medicine of Ribeirão Preto, University of São Paulo, Ribeirão Preto, São Paulo, Brazil.

Cátia Azenha

Ophthalmology Resident, Department of Ophthalmology, Centro Hospitalar Universitário de Coimbra, Portugal.

Authors

Cecília Ramos

Orthoptist, Association for Innovation and Biomedical Research on Light and Image (AIBILI), Coimbra, Portugal
Ocularist, S. Martinho Óptica, Coimbra, Portugal.

Célia Simões Cardoso de Oliveira Stathler

Head of the Oculoplastic Unit, Hospital de Olhos Paulista, São Paulo, Brazil.
Oculoplastic unit, Hospital da Santa Casa de Misericórdia de São Paulo, Brazil.

Consuelo Prada Sánchez.

Ophthalmologist, Oculoplastics.
International Institute of Orbit and Oculoplastics, Centro Oftalmológico Moreiras, Santiago de Compostela, Spain.

Cristina Fonseca

Ophthalmology Resident, Department of Ophthalmology, Centro Hospitalar Universitário de Coimbra, Portugal.

Diana Carolina Ortegata Páez

Medical ophthalmologist, Sanitas University Foundation.

Filipa Ponces

Orbit and Oculoplastics Unit, Department of Ophthalmology, Centro Hospitalar e Universitário de Coimbra, Portugal.
Invited assistant professor of Immunology, Medical School, University of Coimbra, Portugal.

João Aragão Rodrigues

School of Medicine, University of Porto, Porto, Portugal.

João Barbosa-Breda

Ophthalmology Resident, Department of Ophthalmology, Centro Hospitalar de São João, Porto, Portugal.

João Cabral

Department of Ophthalmology, Hospital da Luz, Lisboa, Portugal.

João Gil

Ophthalmology Resident, Department of Ophthalmology, Centro Hospitalar Universitário de Coimbra, Portugal.

Joana Providência

Ophthalmology Resident, Department of Ophthalmology, Centro Hospitalar Universitário de Coimbra, Portugal.

José Costa

Ophthalmology Resident, Department of Ophthalmology, Centro Hospitalar Universitário de Coimbra, Portugal.

José Vicente Perez Moreiras.

Professor of Medicine and Surgery at the University of Santiago de Compostela, Spain.
Ex president of the SECPOO.
International Institute of Orbit and Oculoplastics, Centro Oftalmológico Moreiras, Santiago de Compostela, Spain.

Mara Ferreira

Department of Ophthalmology, Hospital da Luz, Lisboa, Portugal.

Marco Marques

Ophthalmology Resident, Department of Ophthalmology, Centro Hospitalar Universitário de Coimbra, Portugal.

Marco Rego

Ophthalmology Resident, Department of Ophthalmology, Centro Hospitalar Universitário de Coimbra, Portugal.

Maria Angélica Salazar Román

Ophthalmologist, School of Ophthalmology Barraquer Institute of America, Colombia.

Oculoplastic Specialist São Geraldo Hospital, Minas Gerais, Brazil.

Professor of Oculoplastic, Sanitas University Foundation, Oculoplastic National Institute of Ophthalmology and Plastic Surgery.

Maria Araújo

Ophthalmologist, Department of Neurosciences, Hospital de Santo António, Centro Hospitalar do Porto, Portugal.

Maria Shekhovtsova

School of Medicine, University of Porto, Porto, Portugal.

Maria Varela

Ophthalmologist, International Institute of Orbit and Oculoplastics, Centro Oftalmológico Moreiras, Santiago de Compostela, Spain.

Margarida Anastácio

Anesthesiologist consultant, Department of Anesthesiology, Centro Hospitalar Universitário de Coimbra, Portugal.

M. Tomé

Endocrinologist, Hospital Clínico Universitário de Santiago de Compostela, Santiago de Compostela, Spain.

Nádia Lopes

Oculoplastics Unit, Department of Ophthalmology, Centro Hospitalar do Médio Tejo, Tomar, Portugal.

Renata Rothwell

Ophthalmology Resident, Department of Ophthalmology, Centro Hospitalar de Vila Nova de Gaia/Espinho, Portugal.

Ricardo Dias

Orbit and Oculoplastics Unit, Department of Ophthalmology, Centro Hospitalar de São João, Porto, Portugal.

Rui Tavares

Head of the Oculoplastics and Lacrimal Unit, S. Teotónio Hospital, Viseu, Portugal.

Consultant of Oculoplastic and Lacrimal Surgery of the Centro Cirúrgico de Coimbra, Portugal.

Sandra Prazeres

Chief of the Oculoplastics and Reconstructive Surgery, Department of Ophthalmology, Centro Hospitalar de Vila Nova de Gaia/Espinho, Portugal.

Sara Marques

Ophthalmology Resident, Department of Ophthalmology, S. Teotónio Hospital, Viseu, Portugal.

Sara Ribeiro

Orbit and Oculoplastics Unit, Department of Ophthalmology, Hospital de Braga, School of Health Sciences, University of Minho, Braga, Portugal.

Department of Ophthalmology, Hospital Lusíadas, Porto, Portugal.

School of Medicine of Ribeirão Preto, University of São Paulo, Ribeirão Preto, São Paulo, Brazil.

Vera Soares

ENT surgeon, Rhinology and Sinus Surgery, Lacrimal Surgery Unit, S. Teotónio Hospital, Viseu, Portugal.

Vitor Leal

Orbit and Oculoplastics Unit, Department of Ophthalmology, Centro Hospitalar de São João, Porto, Portugal.

Index

Preface	11
Introductory note and acknowledgements	13
 BASIC PRINCIPLES	
1. Anatomy and Clinical Examination of the Eyelids	17
2. Anatomy and Clinical Examination of the Lacrimal Drainage System	29
3. Anatomy and Clinical Examination of the Orbit	37
4. Instruments in Ophthalmic Plastic Surgery	49
5. Sutures and Needles in Ophthalmic Plastic Surgery	57
6. Anesthesia for Orbit and Oculoplastic Surgery	63
7. Graft Harvesting in Ophthalmic Plastic Surgery	69
 EYELIDS	
8. Ectropion	91
9. Entropion	99
10. Blepharoptosis	105
11. Trichiasis	119
12. Facial Palsy and Lagophthalmos	125
13. Eyelid Tumors	135
14. Superior Eyelid Reconstruction	145
15. Inferior Eyelid Reconstruction	155
16. Cosmetic Blepharoplasty	167
17. Periorbital Rejuvenation Fillers and Botulinum toxin	173
 LACRIMAL DRAINAGE SYSTEM	
18. Congenital Nasolacrimal Duct Obstruction	185
19. External Dacryocystorhinostomy	195
20. Endonasal Dacryocystorhinostomy	199
21. Transcanalicular Laser Dacryocystorhinostomy	205
 ORBIT	
22. Enucleation and Evisceration	217
23. Anophthalmic socket	223
24. Congenital Anophthalmia	229
25. Orbital Inflammatory Disease	241
26. Bacterial Orbital Cellulitis	249
27. Thyroid Orbitopathy	261
28. Adult Orbital Tumors	273
29. Pediatric Orbital Tumors	285
30. Ocular Prosthesis	301

Preface

The Manual of Ophthalmic Plastic and Reconstructive Surgery is a very important book for all ophthalmologists, not only for those who are beginning their career in this exciting clinical area. We are fortunately seeing interest growing in this subspecialty, which in the past was almost abandoned by the majority of ophthalmologists. Recent advances and the growing interest in this area are factors that have stimulated the writing of this work.

Ophthalmologists commencing orbit and oculoplastic surgery commonly find the anatomy of the eyelids, lacrimal drainage system and orbit difficult, even though they may know the theory well. The first part of this manual presents the relevant anatomy and clinical examination to help readers to acquire detailed knowledge so that they can start the learning process in this field. The other three parts have been written with the intention of providing a complete approach to the diagnosis and management of patients with oculoplastic, orbital and lacrimal problems. This book also contains a great many illustrations, practically making it an atlas, to accompany the descriptions of diagnostic procedures and surgical techniques.

This manual will definitely offer valuable knowledge on the field of ophthalmic plastic and reconstructive surgery for those with limited experience, and provide a very strong basis as experience grows.

We are very grateful to Dr. Guilherme Castela, as well as to all our colleagues from Portugal, Spain, Brazil and Colombia, whose input demonstrates the invaluable and very careful preparation of this manual. I am sure that this book, produced by very active and dynamic persons, will stimulate interest and improve surgical standards in this fascinating area of Orbit and Oculoplastics.

Joaquim Neto Murta

Introductory note and acknowledgements

The main purpose of this manual is to disseminate a part of ophthalmology that is all too often overlooked, a part that has been developing in Portugal in recent years. The orbit and oculoplastics are areas often shared by other medical areas, but it is the ophthalmologist that has a more comprehensive and deeper understanding of the periocular region as a whole, which enables us to be at the forefront of this subspecialty.

This work is divided in four parts and has 30 chapters. The first part deals with the concepts of surgical anatomy, surgical instruments, threads and sutures, anesthesia in the orbit and oculoplastics procedures, and graft harvesting. The second part covers the entire field of eyelid pathology, from eyelid malposition, eyelash pathology, tumors of the eyelid, lagophthalmos management and includes aesthetic treatments of the periorbital region. Part three looks at the pathology of the lacrimal apparatus and includes congenital nasolacrimal duct obstruction and external, endonasal and transcanicular dacryocystorhinostomy techniques. Finally, part four deals with disorders of the orbit, starting with enucleation and evisceration techniques and then covering treatment of the anophthalmic socket in adults and in children. There are chapters on inflammatory and infectious disorders of the orbit, orbital tumors in adults and in children and this part ends by describing the preparation and adaptation of external ocular prosthesis.

The conception and planning of this work started two years ago when I realized that there was no textbook on this subspecialty in Portugal. Then began a journey that has not always been easy and that involved enlisting the help of many people. In addition to the various Portuguese authors with expertise in these areas, I decided to enrich the book with the input of authors from abroad who were my teachers; without them this project would not make sense. Professor Perez Moreiras and Dr. Consuelo Prada, from the International Institute of Orbit and Oculoplastics in Santiago de Compostela, a center that is a world leader in this area, were the people who guided my first steps, and they sparked my interest and provided me with the tools to start and develop my career. I am indebted, too, to Professor Ana Rosa Pimentel from the Federal University of Minas Gerais, Belo Horizonte, who helped to consolidate my training as a whole. I offer my eternal gratitude to them, my teachers and my friends.

I would also like to thank Professor Joaquim Murta, my head of department, for his constant support, this book would not be here without him, and Professor Maria João Quadrado, the president of the Portuguese Society of Ophthalmology for her encouragement.

Indeed, I would like to thank all the authors and everyone who has helped me with the editing and revision of this textbook, and all my family for the warmth with which they have supported me, every day.

Finally a special thank to Thea for having believed and supported financially this book.


As Fernando Pessoa said, "I have in me all the dreams of the world". I had a dream and here is the result.

I hope you both like and benefit from this book.

To my family.

Guilherme Castela

BASIC PRINCIPLES

- 
- 1 Anatomy and Clinical Examination of the Eyelids
 - 2 Anatomy and Clinical Examination of the Lacrimal Drainage System
 - 3 Anatomy and Clinical Examination of the Orbit
 - 4 Instruments in Ophtalmic Plastic Surgery
 - 5 Sutures and Needles in Ophtalmic Plastic Surgery
 - 6 Anesthesia for Orbit and Oculoplastic Surgery
 - 7 Graft Harvesting in Ophtalmic Plastic Surgery

1. Anatomy and Clinical Examination of the Eyelids

Cristina Fonseca, Andreia Silva, Guilherme Castela

The eyelids are anatomical structures that cover the globe and play four main roles: globe protection, tear flow towards the drainage system, tear film distribution in the ocular surface and contribution to tear film secretion. This chapter provides a practical and systematic outline of the surgical anatomy and physical examination of the eyelids.

1. Surface Anatomy

The upper eyelid extends from the superior palpebral margin to the eyebrow, and the inferior eyelid extends to the area below the inferior orbital rim, where it joins the maxilla.

The superior eyelid crease, which corresponds to the cutaneous insertion of fibers of the levator aponeurosis, is usually 7 to 8 mm above the palpebral margin in Caucasian males and in females it is 10 to 12 mm above the palpebral margin. The space between the superior eyelid crease and the superior orbital rim is called the superior orbital sulcus. The inferior eyelid crease, more easily seen in children, is always less evident than the superior one. It runs from the inferior margin of the tarsus, 3 mm below the palpebral margin medially and 5 mm laterally, and it corresponds to the cutaneous insertion of the inferior retractor muscle fibers. Inferior eyelid anatomical limits are defined by the nasojugal fold medially, and the malar fold laterally.

Races differ regarding the eyelid crease location. The superior eyelid crease in Asians is lower and the upper eyelid sulcus more prominent. The orbital septum fuses with the levator aponeurosis between the eyelid margin and the superior border of the tarsus, in contrast to the supratarsal fusion in Caucasians. Furthermore, this allows the preaponeurotic fat to occupy a lower and more anterior position in the eyelid. There are also racial differences in the inferior eyelid of Asian population, the commonest being the epiblepharon, which consists in a skin fold below the inferior palpebral margin. The inferior eyelid crease is often indistinct or has a higher position near the palpebral margin.

The palpebral fissure is the exposed area between

the upper and lower eyelids. These join medially and laterally to form the medial and lateral canthus, respectively. The natural curvature of the palpebral fissure varies according to gender, age and race but in general it measures 10 to 12 mm vertically and 28 to 30 mm horizontally.

The lateral canthus lies approximately 2 mm above the medial canthus (higher in Asians) and it is located 5 to 7 mm lateral to the orbital rim. The medial canthus lies over the medial orbital rim. In adults, the upper palpebral margin is 1 to 2 mm below the superior limbus, whereas the inferior palpebral margin is located at the level of the inferior limbus. The distance from the medial canthus to the nasal pyramid midline is about 15 mm. The medial canthus is separated from the globe by a lacrimal tear reservoir, the lacrimal lake. The plica semilunaris is a crescent-shaped fold of conjunctiva that forms the floor of the lacrimal lake. The caruncle, a fleshy modified skin structure lies medial to the plica semilunaris and is covered by nonkeratinized stratified squamous epithelium that contains goblet cells and hair follicles, as well as sweat and sebaceous glands.

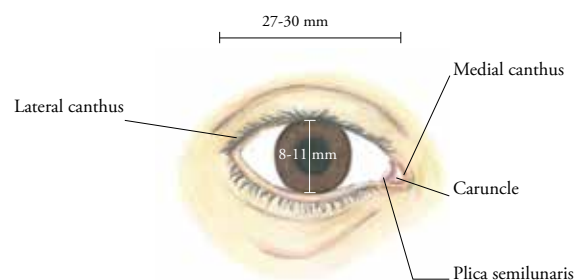


Figure 1: Landmarks of the external eye.

2. Orbicularis Oculi Muscle

The orbicularis muscle is one of the superficial muscles responsible for facial expression and is composed of fibers concentrically arranged around the orbit and eyelids. It is the main structure responsible for palpebral fissure closure and also plays an important role in the lacrimal pump system. This muscle can be divided into three parts: the pretarsal portion (over

1. Surgical Anatomy and Clinical Examination of the Eyelids

the tarsus), the preseptal portion (over the orbital septum) and orbital portion. The pretarsal and preseptal are both parts of the palpebral orbicularis muscle. The voluntary contraction of the orbital portion closes the palpebral fissure. The palpebral orbicularis is responsible for involuntary movements like spontaneous and reflex blinking, and lacrimal pump function. Palpebral periocular skin wrinkles are perpendicular to the orbicularis contractions lines.

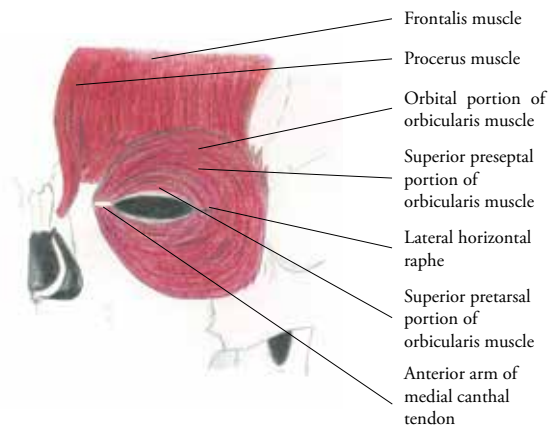


Figure 2: Orbicularis muscle (portions) and related musculature of the orbit.

3. Canthal tendons

The medial canthal tendon (MCT) has a complex and variable structure whose two main portions are the muscular and fibrous components. The fibrous component consists of a fibrous band that stabilizes the tarsus, and it is attached to the frontal process of the maxilla. It inserts anteriorly in the anterior lacrimal crest and posteriorly in the posterior lacrimal crest (lacrimal bone). The muscular component is composed of superficial and deep muscular fibers from the preseptal and pretarsal portions of the orbicularis. The superficial pretarsal orbicularis fibers join the fibrous component to create the anterior limb of the MCT. The posterior fibers, also called Horner's muscle, insert in the posterior lacrimal crest behind the lacrimal sac. The superficial fibers from the preseptal orbicularis insert in the anterior aspect of the MCT and its deep fibers insert in the lacrimal sac fascia, anterior and posterior to the Horner muscle. The Horner muscle contraction pulls the eyelid medially and posteriorly. The preseptal orbicularis deep fibers pull the lacrimal sac fascia laterally and, together with the Horner muscle, they form the lacrimal pump.

The lateral canthal tendon (LCT) is formed of dense fibrous tissue from the tarsus that travels laterally deep into the orbital septum to insert in the orbital tubercle, 1.5 mm posterior to the lateral orbital rim. In the space between the anterior orbital septum and the lateral retinaculum there is sometimes a small

pocket of fatty tissue, called Eisler's pocket. It also has a muscular portion created by pretarsal and preseptal orbicularis fibers. LCT insertion is approximately 3 mm higher than MCT insertion, imposing a slight upward slope of the palpebral fissure from medial to lateral. The LCT attaches the canthal angle and the superior and inferior tarsus to the lateral orbital tubercle, which gives the eyelids a correct lateral apposition to the globe.

4. Eyelid margin

Palpebral margins consist of the confluence of conjunctiva, orbicularis muscle and skin epithelium. They are in apposition to the globe and contain the cilia and the meibomian glands' openings. The palpebral margin can be divided into two portions: the lacrimal portion (that corresponds to the medial sixth) and the ciliar portion (the lateral 5/6). This division occurs at the lacrimal papilla, an elevation that contains the lacrimal puncta, which are the openings of the lacrimal canaliculi. The lash implantation line is more anterior and contains about 100 to 150 cilia in the upper eyelid and 50 to 75 in the lower eyelid, arranged in 2 or 3 irregular rows. Cilia arise from hair follicles in the anterior aspect of the tarsus and project outwards. Each follicle associates two sebaceous glands called glands of Zeiss. Moll glands (sweat glands) are also located near the cilia and empty into adjacent follicles. Posterior to the lash line and anterior to the tarsus, the gray line can be found (also known as the muscle of Riolan), which represents the pretarsal orbicularis insertion into the palpebral margin. The gray line is an anatomical feature that divides the eyelid into the anterior and posterior lamellas. Some authors consider the presence of three lamellas, with the third intermediate lamella being the gray line and eyelid retractor muscles. The meibomian glands and tarsus are posterior to the gray line and belong to the eyelid posterior lamella. Meibomian glands (about 25 in the upper eyelid and 20 in the inferior one) are arranged vertically in the eyelid and empty into the orifices at the marginal surface. The mucocutaneous junction is posterior to the glands' orifices and is often erroneously referred to as the gray line.

5. Fat pads

Adipose tissue acts as a protective cushion for the globe. Submuscular fat is composed of adipose tissue and connective tissue under the orbicularis. Beneath the interdigitation of the orbicularis and frontal muscles lies a fibro-fatty layer, known as retroorbicularis oculi fat (ROOF), which contributes to the volume and mobility of the eyebrow and eyelid. The anatomical relationship between the

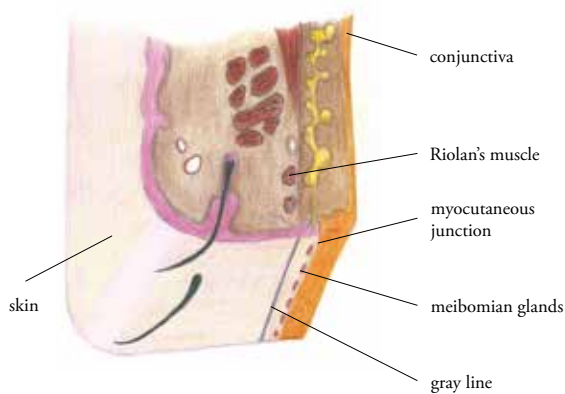
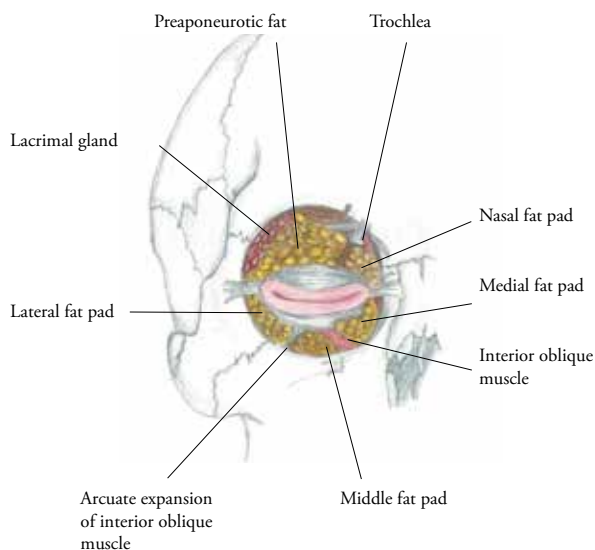


Figure 3: Eyelid margin anatomy.

ROOF and the eyelid must be kept in mind during surgery in order to avoid confusing the eyebrow fat and the preaponeurotic fat of the eyelid.

In the superior eyelid two preaponeurotic fat pads can be found: a medial one (most of the times excised during blepharoplasty procedures) and a central one. The preaponeurotic fat pads are important anatomical landmarks in eyelid surgery as they are usually posterior to the orbital septum and anterior to the levator muscle aponeurosis. The medial pad is surrounded by the medial horn of the levator aponeurosis and by the tendon of the superior oblique muscle. The palpebral lobe of the lacrimal gland is located lateral to the central fat pad and can be easily confused with the latter during surgical approach.

There are three fat pads in the lower eyelid, the nasal, central and temporal, commonly located anterior to the capsulopalpebral fascia (CPF). The medial and central pads are separated by the origin of the inferior oblique muscle and many authors consider them to be a single pad. Laterally, a third pad is located below the lateral canthus, separated from the central pad by a fibrous extension from the orbital septum to the orbital rim.



The midface compartment includes also the suborbicularis oculi fat (SOOF) and the malar fat pads. The SOOF is composed of adipose and loose connective tissue, under the inferior portions of the orbicularis muscle and extends into the malar region.

These pads can become noticeable with the aging process because the gravitational descent of the midface contributes to the aesthetic distortion of the lower eyelid.

6. Orbital septum

The orbital septum is an anatomical structure composed of dense connective tissue that attaches peripherally to the superior and inferior orbital rims (*arcus marginalis*). It separates the palpebral and orbital compartments and acts as an anatomical barrier to infection, hemorrhage or edema. These pathological processes are regarded as preseptal or postseptal according to their position relative to this structure. From the orbital rim, the septum extends to the anterior orbit, beneath the orbicularis, joining the levator muscle aponeurosis 2 to 3 mm above the tarsal plate and 10 mm above the eyelid margin (although there are racial and interindividual differences). In the lower eyelid, the septum emerges from the orbital rim and extends anteriorly to join the capsulopalpebral fascia. The complex septum-capsulopalpebral ligament inserts in the anterior and posterior aspects of the tarsus and in the inferior border of the tarsal plate. The septum extends medially with the pretarsal orbicularis to insert in the anterior and posterior lacrimal crests. Laterally, it attaches to the lateral orbital tubercle with the preseptal orbicularis and is separated from the LCT by the Eisler fat pad. As a result of aging, a thinning of the superior and inferior septum as well as orbicularis laxity occurs, leading to anterior herniation of the orbital fat through the septum.

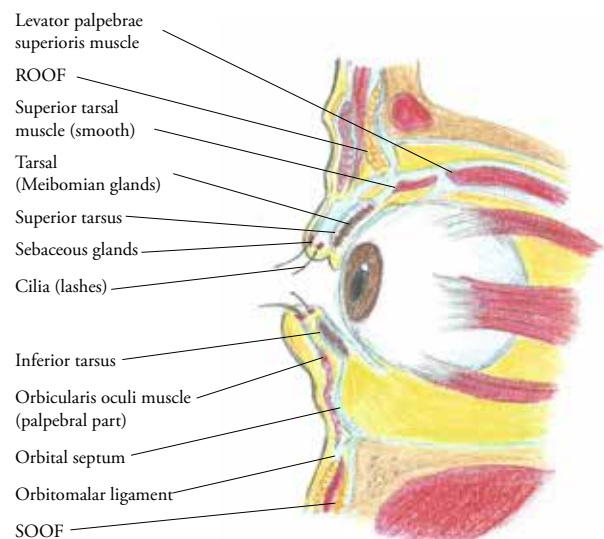


Figure 4: a) Upper and lower eyelid fat pads; b) ROOF and SOOF pads.

1. Surgical Anatomy and Clinical Examination of the Eyelids

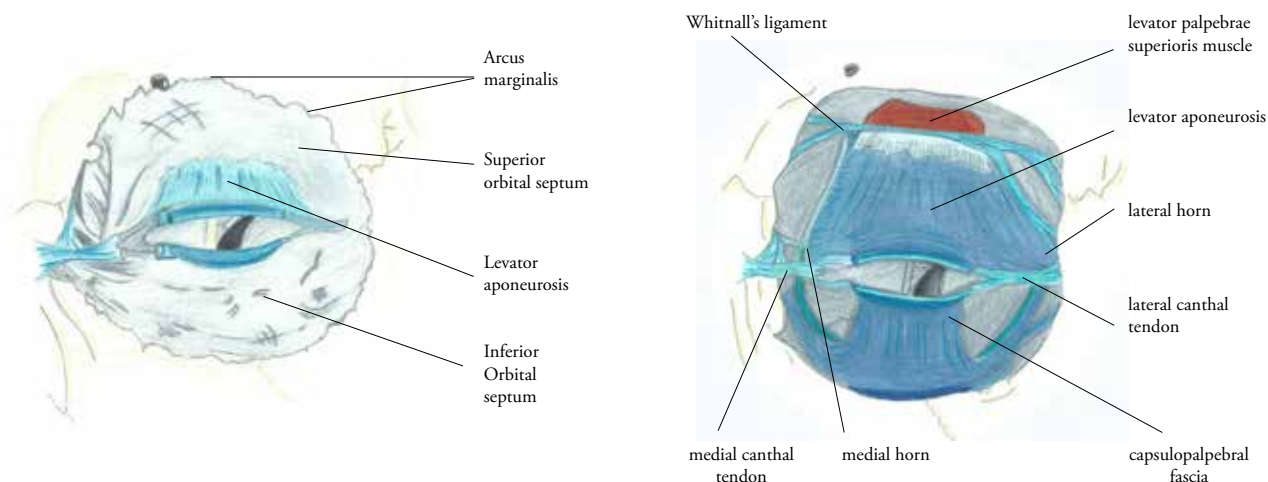


Figure 5: a) Orbital septum; b) Eyelid dissection posterior to the orbital septum.

7. Retractor muscles

a. Upper eyelid retractors

Upper eyelid retractors include the levator palpebrae superioris muscle (LPS) and the superior tarsal muscle (Müller muscle). The former is a skeletal muscle innervated by the oculomotor nerve (III cranial nerve) and the latter is a sympathetically innervated smooth muscle. The LPS arises from the orbital apex in the lesser wing of the sphenoid bone, above the annulus of Zinn, superolateral to the optic foramen. The LPS and superior rectus muscle share a common origin and are connected by fibrous attachments. The muscular portion of the LPS extends anteriorly (40 mm) and ends in an aponeurosis in the final 10 to 14 mm. This muscle crosses over the transverse ligament of Whitnall, which is a condensation of connective tissue (collagen and elastic fibers), and represents the transition between the muscular and aponeurotic portions of the LPS.

The LPS aponeurosis extends laterally and medially as fibrous condensations to form the lateral and medial horns, which are located below the Whitnall ligament. The lateral horn is stronger and inserts in the orbital tubercle, dividing, during its course, the palpebral and orbital lobes of the lacrimal gland. The medial horn passes over the superior oblique tendon and inserts in the posterior lacrimal crest and posterior aspect of the MCT. The levator palpebrae superioris aponeurosis continues its course anteriorly to join the orbital septum 2 to 3 mm above the superior margin of the tarsus. Fusion between the orbital septum and the LPS aponeurosis occurs at the level of the superior eyelid crease, which is the result of the LPS aponeurosis and preseptal orbicularis insertions in the subcutaneous tissue. The LPS aponeurosis finally inserts on the lower one third of the anterior aspect of the tarsus, with its strongest attachments 3 mm above the eyelid margin.

Müller's muscle (superior tarsal muscle) is also an upper eyelid retractor muscle. This highly vascularized muscle is a common source of hemorrhage during eyelid surgery. The peripheral arterial arcade can be found between the LPS aponeurosis and Müller's muscle, just above the superior margin of the tarsal plate. Muscle fibers arise from the inferior surface of the LPS aponeurosis/muscle transition, travel inferiorly between the LPS and the conjunctiva and insert in the superior margin of the tarsus. With age, fatty infiltration occurs giving this muscle a yellowish appearance. In Grave's orbitopathy, increased sympathetic stimulation can retract the upper eyelid 2 to 3 mm, and the reverse happens in cases of decreased sympathetic tone. The topical administration of 2.5% phenylephrine can be used to preoperatively determine the effect of Müller's muscle resection on ptosis surgery.

Superior eyelid excursion, from full depression to complete elevation, is about 15 to 20 mm, which is considered the LPS function. The Müller muscle is responsible for about 2 mm of eyelid elevation.

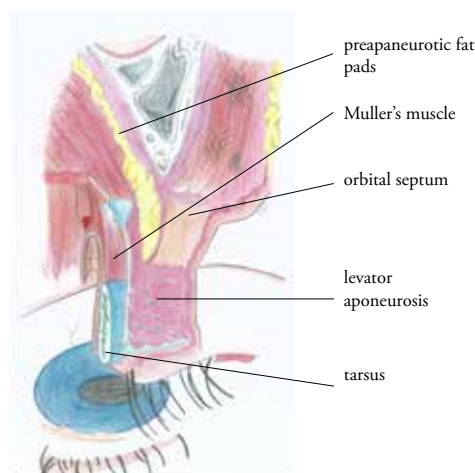


Figure 6: Anatomical planes of the eyelid in sagittal view.

b. Lower eyelid retractors

Lower eyelid retractors include the inferior tarsal muscle and the capsulopalpebral fascia (CPF). The capsulopalpebral head (inferior rectus fibers extension) passes anteriorly, splits to envelop the inferior oblique muscle and reunites to form the inferior transverse ligament (Lockwood ligament). From this point, this fascial tissue constitutes the capsulopalpebral fascia which inserts on the tarsus. This structure is analogous to the LPS aponeurosis. The orbital septum fuses with the CPF and the inferior tarsal muscle 5 mm below the inferior border of the tarsus. The inferior eyelid opens passively by traction from the inferior rectus muscle, through the CPF.

The Lockwood ligament acts as a suspensory ligament for the inferior eyelid; it is composed of intramuscular septa, Tenon's capsule and fibers from the inferior rectus and lower eyelid retractors. It attaches to the Whitnall tubercle laterally, and behind the lacrimal crest medially. It originates anterior projections into the conjunctival fornix to form the suspensory ligament of the fornix, projections that divide the central and temporal fat pads and also subcutaneous projections that define the lower eyelid crease.

Inferior tarsal muscle (inferior Müller's muscle) lies posterior to the CPF and arises from the capsulopalpebral head and inferior rectus sheath. This muscle is adherent to the overlying CPF and the subjacent conjunctiva. Its function is analogous to the superior Müller muscle in that it acts as a palpebral retractor under sympathetic innervation.

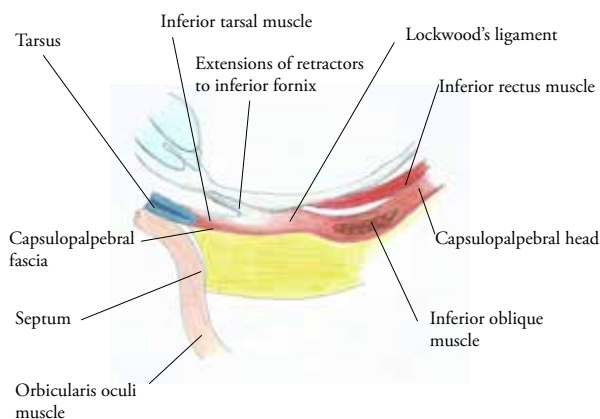


Figure 7: Scheme of the lower eyelid retractor system.

8. Tarsus

The tarsal plates are composed of dense fibrous and elastic tissue and are responsible for the structural integrity of the eyelids, as a part of the posterior lamella. They extend along the entire length of the upper and lower eyelids, measuring about 25 mm in length and 1 mm in width. The upper tarsus measures approximately 9 to 10 mm in vertical

height and its highest point is just medial to the pupil. The lower tarsus measures 4 to 5 mm in vertical height, in its central portion. The posterior surfaces adhere to the conjunctiva and the medial and lateral borders of the tarsal plates anchor to the periosteum of the orbital rims through the medial and lateral canthal tendons. The upper tarsus contains approximately 30 meibomian glands and the lower tarsus approximately 20 glands, which have a vertical course. The orifices of these glands open in the palpebral margin, posterior to the grey line and anterior to the mucocutaneous junction.

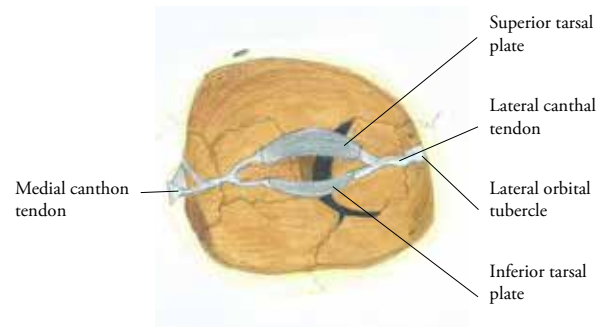


Figure 8: Superior and inferior tarsal plates.

9. Conjunctiva

The tarsal conjunctiva is composed of nonkeratinizing stratified squamous epithelium, containing mucous-secreting goblet cells and accessory lacrimal glands of Wolfring and Krause. These latter are located in the subconjunctival tissue of the upper eyelid between the tarsal border and the fornix. The mucin-secreting cells are scattered in the conjunctiva and concentrated in the crypts of Henle, above the tarsal border.

10. Arterial Irrigation

The palpebral arterial supply has two major sources, the internal and external carotid arteries. The ophthalmic artery arises from the internal carotid, whose terminal branches primarily supply the upper eyelid. The external carotid gives rise to the superficial arterial system through facial and angular arteries, supplying mainly the lower eyelid. Anastomosis between the internal and external systems occurs in eyelid irrigation through the marginal arcades of the eyelid, which arise in branches from the ophthalmic artery and branches from the lacrimal arteries, the latter from the maxillary branch of the external carotid artery.

The deep irrigation system originates from the internal carotid artery and, through the ophthalmic artery, gives rise to its terminal branches, which perforate the orbital septum to irrigate the upper eyelid. The terminal branches are: lacrimal artery, supraorbital artery, supratrochlear artery and dorsal nasal artery. The lacrimal artery runs along the superior border of the lateral rectus muscle and terminates as the lateral

1. Surgical Anatomy and Clinical Examination of the Eyelids

palpebral artery, which irrigates the lacrimal gland, conjunctiva and lateral aspect of the upper eyelid. The supraorbital artery passes anteriorly between the LPS and the superior periorbital and accompanies the supraorbital nerve through the supraorbital foramen to irrigate the upper eyelid, scalp, forehead, LPS muscle and periorbital. The supratrochlear branch runs along with the supratrochlear nerve to vascularize the skin of the superior medial aspect of the orbit, forehead and scalp. The ophthalmic artery passes through the orbital septum nasally and becomes the dorsal nasal artery, irrigating the bridge of the nose, the lacrimal sac and terminating as the medial palpebral artery. Palpebral medial and lateral arteries anastomose to form the vascular arcades of the upper eyelid. The marginal palpebral arcade lies on the anterior tarsal surface, 2 to 3 mm from the palpebral margin, and the peripheral vascular arcade passes above and parallel to the superior border of the tarsus, between the LPS aponeurosis and the Müller muscle. Medially, both arcades have a tortuous pathway through the medial fat pad, which is a common source of bleeding during a superior blepharoplasty.

In the lower eyelid, the marginal arcade has its origin in the medial and lateral palpebral branches and runs horizontally 3 mm below the inferior palpebral margin and anterior to the inferior tarsal plate. There is no peripheral vascular arcade in the lower eyelid.

The superficial irrigation of the eyelids originates from the external carotid artery, through 3 branches of the facial system: facial artery, temporal superficial artery and infraorbital artery. The facial artery crosses the mandible diagonally, anterior to the masseter muscle to reach the nasolabial fold. Within the orbicularis muscle, the artery passes to the medial region (6 to 8 mm medial to the medial canthus) and gives rise to the angular artery, which perforates the orbital septum above the MCT and anastomoses with the nasal dorsal artery.

The superficial temporal artery is a terminal branch of the external carotid and ascends superiorly to the periauricular region, 1 mm anterior to the tragus. This artery gives 3 branches that irrigate the eyelids: frontal branch, zygomatic-orbital branch and transverse facial branch. The frontal branch heads superiorly along the frontal and orbicularis muscles anastomosing with the lacrimal and supraorbital arteries. The zygomatic-orbital branch passes along the superior border of the zygoma and irrigates the upper eyelid and anterior orbit. The transverse facial branch travels below the zygoma to supply the malar region and lateral lower eyelid, anastomosing with the lacrimal and infraorbital arteries. The infraorbital artery is a branch of the internal maxillary artery and it enters the orbit through pterygopalatine fossa. It

travels along the infraorbital fissure, through the infraorbital canal before exiting the orbit by the infraorbital foramen to supply the lower eyelid.

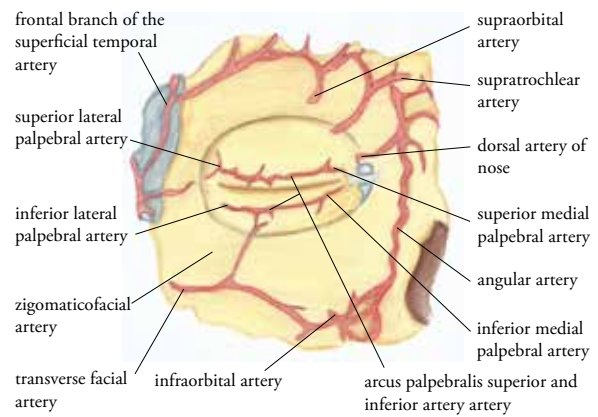


Figure 9: Periorbital and eyelid arterial irrigation.

11. Venous Drainage

The eyelids venous drainage is performed by the tributary veins of the ophthalmic vein and superficially, by the angular and temporal superficial veins. The junction of the superficial frontal and supraorbital veins form the angular vein. The angular vein has dual drainage, posteriorly into the deep venous system through the superior ophthalmic vein, and superficially and inferiorly into the anterior facial vein. Superolaterally, the venous drainage from the forehead, eyebrow and eyelid occurs through the supraorbital vein into the superficial temporal vein, and from this into the external jugular vein. The deep venous system drains the forehead, eyebrow and superior eyelid through the supraorbital vein and from this into the superior ophthalmic vein. The anastomosis of the angular and supraorbital veins gives rise to the superior ophthalmic vein and occurs in the superonasal aspect of the orbit, close to the ophthalmic artery. The superior ophthalmic vein enters the muscular cone and receives drainage from the superior vortex veins but also from the ethmoidal, lacrimal, central retinal vein and ciliary veins. The superior ophthalmic vein joins the inferior ophthalmic vein near the orbital apex and they leave the orbit through the superior orbital fissure to drain into the cavernous sinus. A branch of the inferior orbital vein drains through the inferior orbital fissure into the pterygoid plexus.

12. Lymphatic Drainage

The lymphatic drainage of the eyelids occurs through a superficial and a deep system. The superficial system drains the skin and orbicularis and the deep system drains the tarsus and conjunctiva. The upper eyelid, the lateral half of the lower eyelid and the lateral canthus drain into the preauricular and deep cervical nodes. Skin and orbicularis muscle drain

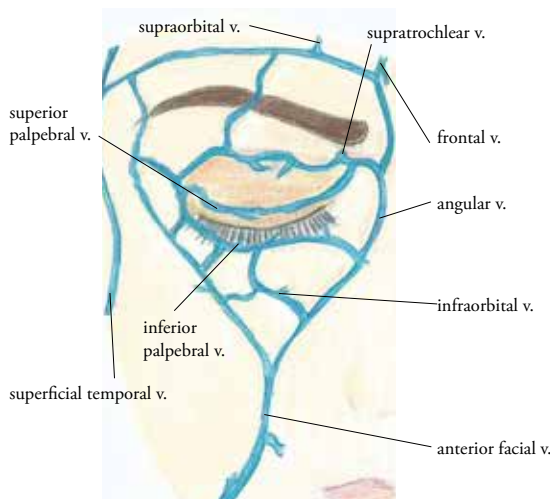


Figure 10: Eyelid venous drainage system.

into the deep cervical nodes near the jugular vein. The medial half of the lower eyelid, medial canthus and conjunctiva drain to the submandibular nodes.

13. Innervation

Sensitive innervation of the eyelids originates from the terminal branches of the ophthalmic (CN V1) and maxillary (CN V2) divisions of the trigeminal nerve (CN V). In the superior orbit, the frontal branch of the ophthalmic division of the CN V passes anteriorly between the orbital roof and the LPS muscle, dividing into the supraorbital and supratrochlear nerves. The supraorbital nerve leaves the orbit through the supraorbital foramen or notch, and provides innervation to the upper eyelid and forehead skin, except for a vertical region in the midline, which is supplied by the supratrochlear nerve. The latter passes above the trochlea and pierces the orbital septum in the superonasal region of the orbit giving rise to the sensitive innervation of the medial canthus, skin of the root of the nose, middle forehead and lacrimal apparatus structures.

The lacrimal nerve enters the orbit above the annulus of Zinn and eventually supplies the lacrimal gland, giving rise to the lateral palpebral nerve that supplies the skin of that region. An inferior branch of the lacrimal nerve anastomoses with fibers of the zygomaticotemporal branch (branch of the CN V2), which carries parasympathetic secretory fibers from the CN VII to the lacrimal gland. The infratrochlear nerve, a terminal branch from the nasociliary nerve (CN V1), supplies the skin and conjunctiva of the medial canthus, caruncle, canaliculus and nasolacrimal sac. Sensitive innervation of the rest of the lower eyelid is supplied by the infraorbital nerve (V2) and zygomaticofacial nerve (V2). The latter supplies the skin of the inferior eyelid and malar region, and the palpebral branch of the infraorbital

nerve supplies the medial aspect of the lower eyelid and conjunctiva. Orbital floor fractures that affect the infraorbital nerve can result in paraesthesia of the cheek, superior lip, teeth and gums.

Eyelid motor innervation originates from the facial (CN VII) and oculomotor (CN III) nerves. CN VII branches supply the facial mimic muscles and carry motor and parasympathetic fibers. Their frontal and zygomatic branches supply the orbicularis muscle and the forehead muscles (frontal, corrugator and procerus muscles). The LPS muscle is supplied by the superior branch of the CN III, which enters this muscle in its posterior one-third.

Orbital sympathetic innervation is responsible for vasoconstriction, smooth muscular function, pupillary dilation, hydrosis, eyelid retraction, and pilomotor and sweat gland function of the skin. The Müller muscle has sympathetic innervation and its postganglionic fibers arise from the superior cervical ganglion, travelling superiorly in the neck around the internal carotid artery. These fibers have an intracranial course in the cavernous sinus and enter the orbit through the superior orbital fissure. In the orbit, the course of the sympathetic fibers is still a matter of controversy, but some evidence suggests that they travel alongside the ophthalmic arteries and nerves and beside the peripheral eyelid vascular arcades.

EYELID EXAMINATION

1. History

A thorough clinical and ophthalmological history are essential, as is knowledge of a patient's personal systemic and family background. Medical history is important to learn about previous surgical procedures, medications and allergies, all of which helps in the selection of the surgical and anesthetic approaches. Also, factors like the patient's age and occupation may help in deciding which surgical procedure to adopt. Knowing the patient's main concern is paramount to a successful surgical outcome that enables the surgeon to meet the patient's expectations.

It is important to examine previous patient photographs to interpret aging-associated changes and patient's personal characteristics. In pathological conditions, photos help to establish a timeline for our evaluation. For example, in cases of eyelid ptosis, previous photos can help differentiating a congenital from an acquired condition.

A full pre-operative ophthalmologic examination is essential. If peri- or post-surgical complications develop, documentation of previous ocular conditions helps to determine which problems are direct consequences of the surgical procedure.

1. Surgical Anatomy and Clinical Examination of the Eyelids

Such documentation can be used for medico-legal purposes.

2. Eyelid Examination

Eyelid examination is an essential part of the ophthalmologic examination and a systematic evaluation is important to ensure that every aspect of the eyelid function is documented.

Ideally, the eyelid examination begins the moment the patient enters the room. General appearance, head posture, brow elevation, facial contours and ocular motility disturbances are sometimes best observed even before the patient realizes the examination has already started. Prior to any direct measurements, a careful static inspection should be performed to evaluate facial symmetry, protractor and retractor function and the presence of superficial lesions (scars, inflammation and tumors) or eyelid malposition.

Palpation is also important to identify the presence of lumps or nodules, and to determine their consistency, mobility, adhesion to deeper planes and tenderness.

For the eyelid examination the examiner only needs a portable source of light and a ruler. The examiner should be seated in front of the patient with the eyes kept at the same level as the patient's eyes.

The registration of any measurement in the eyelid examination is essential and should be performed with a light source and in primary gaze position.

Palpebral fissure – The palpebral fissure width (intercanthal distance) varies from 28 mm to 30 mm. The palpebral fissure height is 7 to 10 mm in males and 8 to 12 mm in females.

Eyelid position – Superior eyelid margin rests 1 to 1.5 mm below the superior limbus. The inferior eyelid rests on the inferior limbus. Eyelid retraction is present when the upper eyelid is displaced superiorly or the lower eyelid inferiorly, exposing the sclera between the limbus and the eyelid margin, which frequently leads to lagophthalmos and exposure keratitis.

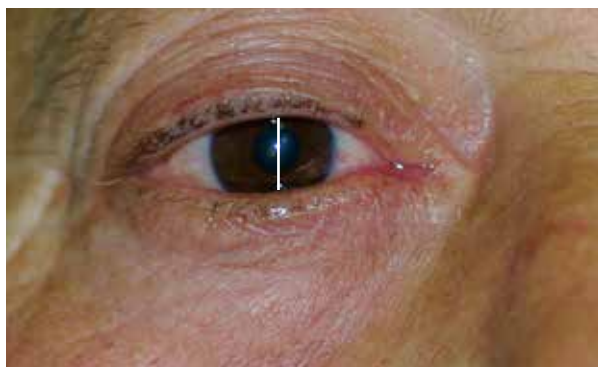


Figure 11: Palpebral fissure height.

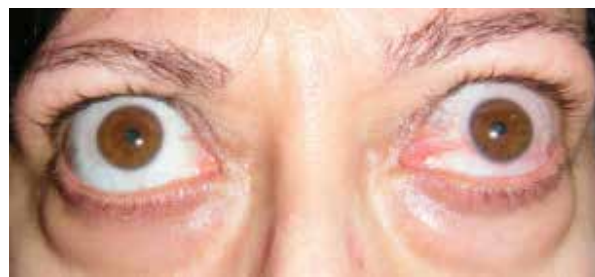

Figure 12: Upper and lower eyelid retraction.

Margin-Reflex Distance (MRD) – This is the distance from the eyelid margin to the pupillary light reflex in the primary gaze position. In the superior eyelid (MRD1), this distance usually measures between 4 mm and 4.5 mm. In severe ptosis, the light reflex may be totally obstructed by the eyelid. In the inferior eyelid (MRD2), the normal distance is about 5 mm. Lower eyelid retraction (or scleral show) is normally present with MRD2 values above 7 mm.

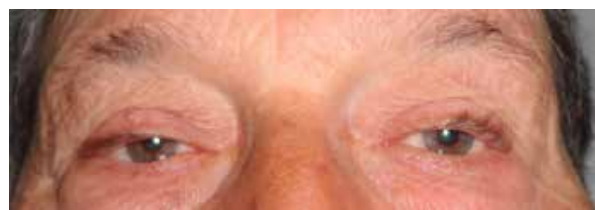

Figure 13: Margin reflex distance. In this case MRD1 is nearly 0 mm.

Upper eyelid crease – Some surgical procedures begin with an upper eyelid crease incision, making this structure a major anatomical reference. It is measured vertically from the superior eyelid margin to the eyelid crease in downgaze. The distance is approximately 8 mm in men and 9 to 10 mm in women. High, duplicated or asymmetric creases can indicate an abnormal position of the LPS aponeurosis (abnormal insertion or disinsertion). The crease is usually high in patients with acquired aponeurotic ptosis and is often shallow or absent in patients with congenital ptosis.

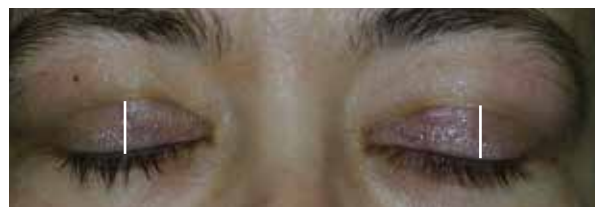

Figure 14: Upper eyelid crease.

Eyelid motility - It is important to evaluate eyelid movements in up and downgaze.

Levator Palpebrae Superioris (LPS) function – Evaluating LPS function is crucial to determine the etiology of the ptosis and its severity, and to plan a surgical procedure. In primary gaze position the brow should be held manually with digital pressure to minimize the elevator contribution from the frontalis muscle. The superior eyelid excursion is observed from full downgaze (maximum relaxation) to full upgaze (maximum contraction). The LPS excursion normally measures approximately 16 to 20 mm.

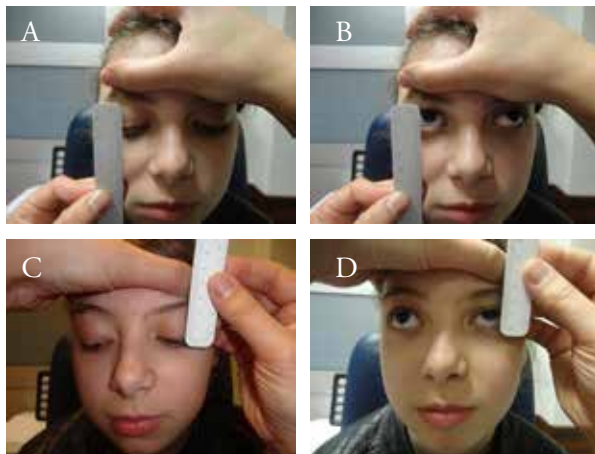


Figure 15: LPS function. On the right eye (A and B) it measures approximately 15 mm, and on the left eye (C and D) it measures approximately 12 mm.

Measurement of the LPS function is important for differentiating acquired from congenital ptosis. Acquired ptosis patients commonly have a good LPS function. A congenital ptosis patient, however, usually has fair to poor LPS function.

The relation between the degree of ptosis and the LPS function can be assessed by quantitative methods, but this relationship is not consensual and there are multiple tables in the literature. The table below demonstrates one example of how this relationship can be assessed.

Degree of ptosis	Amount of ptosis	Levator function	Amount of levator function
Mild	1-2 mm	Good	≥ 10 mm
Moderate	3 mm	Fair	5-7 mm
Severe	≥ 4 mm	Poor	≤ 4 mm

Table 1. Relation of degree of ptosis to amount of LPS function.

During examination, as the examiner manually elevates the ptotic eyelid the normal eyelid may drop. This is known as Hering's law of equal innervation and it allows to detect a possible bilateral ptosis.

Lid Lag – This refers to a lid lag in downgaze. It is a valuable sign to determine whether the patient has congenital ptosis or acquired involucional ptosis. The congenitally ptotic eyelid is typically higher in downgaze than the contralateral, normal eyelid. In acquired involucional ptosis, the affected eyelid remains ptotic in all positions of gaze and may even worsen in downgaze with relaxation of the frontalis muscle. Lid lag is also an early sign in Graves' orbitopathy and it is found either unilaterally or bilaterally in 50% of patients.

Drug testing with phenylephrine 2.5%

A 2.5% solution of phenylephrine can be used to identify the presence of bilateral ptosis in asymmetric cases. One drop of phenylephrine is used in the ptotic eye and the contralateral eyelid position is assessed. Bilateral but asymmetric ptosis is often present and the compensating frontalis contraction can normalize contralateral eyelid position. If the opposite eyelid lowers after phenylephrine instillation, bilateral ptosis is confirmed and bilateral surgery is indicated to obtain a satisfactory result.

It is also an important test to see if a surgical procedure on the Müller muscle will be effective in ptosis treatment. If ptosis is mild (1 to 2 mm) and is resolved after applying a drop of phenylephrine, then a conjunctivo-mullerectomy can be performed to correct the eyelid malposition.

Horizontal Eyelid Laxity

This is often seen in the inferior eyelid and in elderly patients, and leads to eyelid malpositions. Laxity is present when the distance between the cornea and posterior eyelid surface is more than 10 mm. A snap-back test can also be performed by pulling the lower lid away from the globe and noting the time it takes to resume its original position without blinking. A quick eyelid snap-back indicates minimum or absent laxity, a slower return to the original position means moderate laxity and when the eyelid does not return spontaneously to its position without blinking, a severe laxity is present.

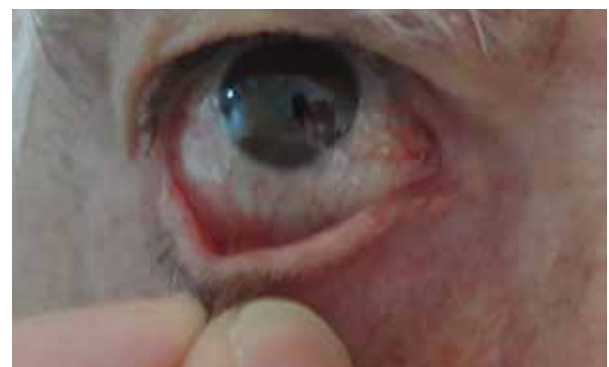

Figure 16: Snap-back test.

1. Surgical Anatomy and Clinical Examination of the Eyelids

Medial Canthal Tendon

Pulling the lower lid laterally from the medial canthus enables the tendon's integrity to be assessed. The canthus displacement should not exceed 1 mm. It is important to assess asymmetry between the eyes.

Lateral Canthal Tendon

Lateral canthal laxity is tested by pulling the lower lid medially from the lateral canthus and measuring the displacement of the lateral canthal corner. Normal displacement should not exceed 2 mm. Once again, it is very important to check for asymmetry between the eyes.

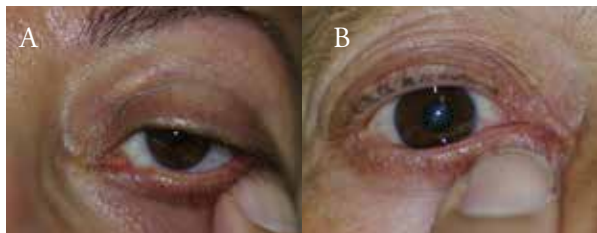


Figure 17: Medial (A) and Lateral (B) Canthal tendon evaluation.

Lagophthalmos

Lagophthalmos is defined as the residual height of the palpebral fissure after a voluntary eyelid closure. It is of extreme importance to check for its presence and determine its degree. Nocturnal lagophthalmos is present in about 5% of the general population. It is a relevant condition when planning ptosis surgery and often requires a surgical hypocorrection, if present.

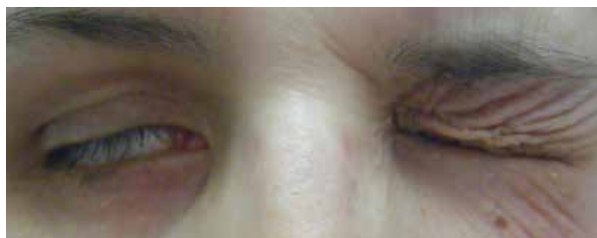

Figure 18: Lagophthalmos.

Marcus Gunn jaw-winking synkinesis

This is the most common form of synkinetic neurogenic ptosis. The existing ptosis disappears with the mandibular movements of chewing, sucking, opening the mouth or contralateral lateralization. This synkinesis is thought to be caused by aberrant connections between the motor division of the trigeminal nerve and the levator muscle. The Marcus Gunn phenomenon occurs in 4 to 6% of all cases of congenital ptosis and it is usually unilateral.

3. Eyebrow

Unilateral or bilateral elevation indicates frontal muscle hyperaction, a common mechanism of compensation for eyelid ptosis. Eyebrow ptosis suggests

frontotemporal nerve palsy (facial nerve branch).

Frontalis suspension surgery for upper eyelid ptosis required good function of the frontal muscle as the contraction of this muscle is essential for the eyelid to open after surgery.

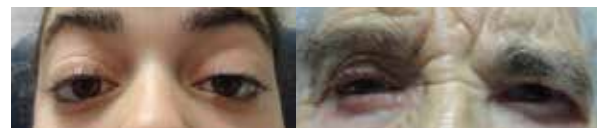

Figure 19: Frontal muscle hyperaction. B. Eyebrow ptosis.

4. Exophthalmometry

Although there are several methods to evaluate proptosis, Hertel's exophthalmometry is used most often. This method measures the distance between the lateral orbital rims (base distance) and the ocular globe position. It assesses ocular protrusion by measuring in millimeters the reflection of the corneal apex in lateral mirrors. Results above 20 mm indicate proptosis and a difference between the eyes of 2 mm or more requires special attention, regardless of the absolute value. Exophthalmometry is very important when performing eyelid ptosis surgery because post-operative eyelid retraction can occur in patients with proptosis.



Figure 20: Left eye proptosis. B. Hertel's exophthalmometry.

5. Ocular motility

Extraocular muscle motility should also be assessed since various dysfunctions can be associated with ptosis in congenital conditions (combined superior rectus/levator muscle maldevelopment, congenital oculomotor palsy), and acquired conditions (ocular or systemic myasthenia gravis, chronic progressive external ophthalmoplegia, oculopharyngeal dystrophy, and acquired oculomotor palsy, with or without aberrant regeneration).

Strabismus, especially vertical strabismus needs to be addressed before eyelid surgery is performed.

6. Ocular surface

The protective mechanisms of the ocular surface include tear production, blink frequency (should be around 15 times per minute), palpebral movement and position, corneal sensation, ocular motility and Bell's phenomenon.

Ocular surface evaluation is essential because eyelid

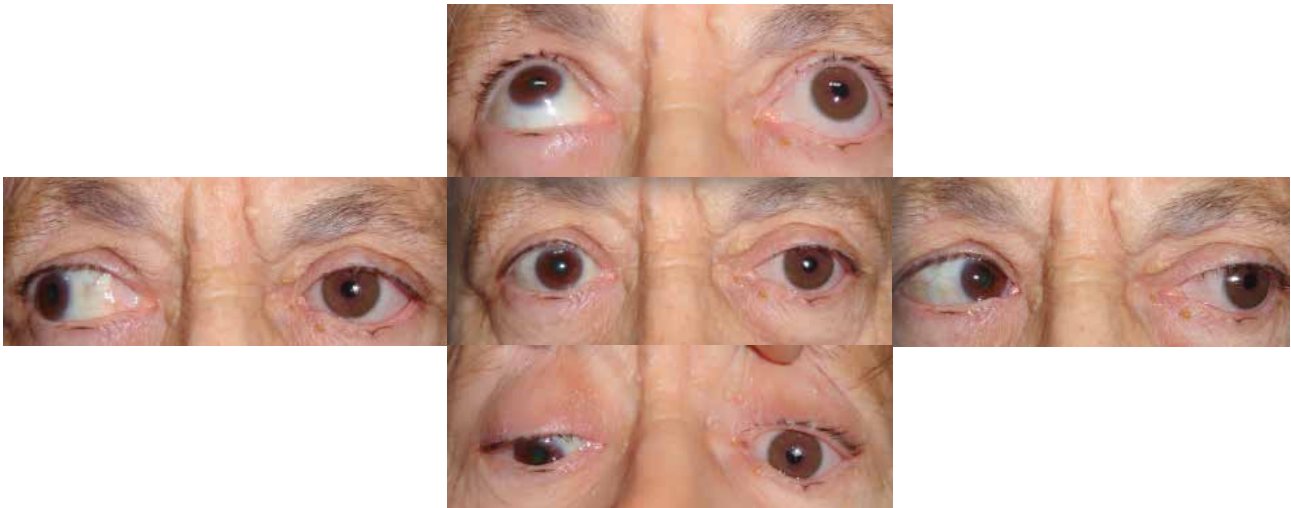


Figure 21: Ocular motility evaluation.

changes can give rise to or aggravate ocular surface diseases. Ocular surface protection mechanisms are assessed by clinical examination that includes visual inspection, slit lamp examination, Schirmer's testing, fluorescein and rose Bengal staining, and tear breakup time (BUT). Previous ocular surface diseases must be taken into consideration when planning surgery. If such a condition is present, we must take a conservative approach to avoid worsening it.

Schirmer's Test – A special thin filter-paper strip (Whatman 41) 5 mm wide and 30 mm long is placed at the junction of the middle and lateral thirds of the inferior fornix, with or without anesthesia. The moist extension in the paper is measured and compared with the contralateral side. The normal value is approximately 15 mm. The Schirmer I test is performed without topical anesthetic; it measures combined basic and reflex tearing and diagnoses aqueous tear deficiency. The Schirmer II test, which measures basal secretion, is performed in a similar manner but with topical anesthetic. Wetting of less than 15 mm after 2 minutes is consistent with a defect in basal secretion.

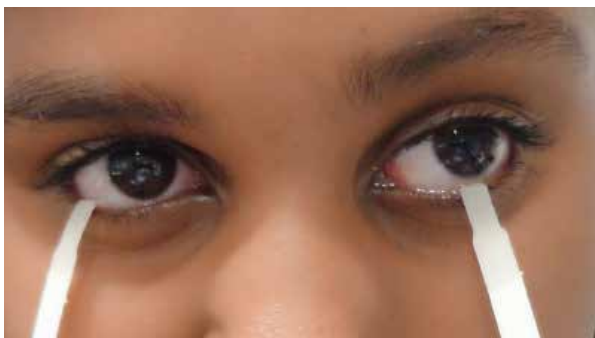

Figure 22: Schirmer's test.

Tear breakup time (BUT) – The mucin layer of tear film helps to spread the other tear film layers over the corneal surface. BUT is abnormal when the aqueous and lipid layers are deficient (Meibomius gland disturbances), and it is best checked after instillation of fluorescein in the conjunctival fornix. The patient has to keep the eyes open and must not blink. The examination is undertaken with the slit lamp, using a broad beam of light with a cobalt-blue filter. The normal breakup time is greater than 15 seconds; if it is less than 10 seconds, it is clearly abnormal.

Corneal Sensitivity – Touching the cornea elicits one of the most important protective reflexes of the human body: blinking. Corneal sensitivity is extremely high, especially at the central zone. A loss or reduction of normal corneal sensitivity (corneal hypoesthesia) can compromise the blinking reflex, delay epithelial healing, reduce tear film flow and could lead to keratitis, neurotrophic ulcers, sterile corneal necrosis or even infectious keratitis. Corneal sensitivity may be tested using a cotton filament in the central zone or a esthesiometer.

Corneal and conjunctival epithelium evaluation

– Rose bengal stain can detect subtle ocular surface abnormalities as it stains devitalized conjunctival and corneal epithelium. Fluorescein stains corneal epithelium defects. Staining in the inferior third of the cornea may indicate exposure ulcer.

Bell's phenomenon – When planning a surgery, it is important to confirm the presence of Bell's phenomenon as it appears to be an important ocular surface protective mechanism. It consists of a superolateral movement of the eye when voluntary

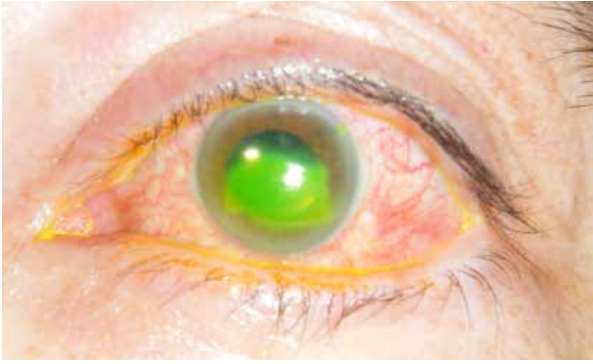


Figure 23: Fluorescein staining a corneal epithelium defect.

eyelid closure occurs. It can be absent in cases of ophthalmoplegia, myasthenia and severe myogenic ptosis. If Bell's phenomenon is not present, surgical treatment should be more conservative to avoid postoperative corneal exposure.

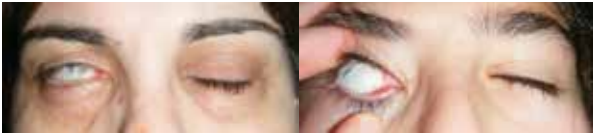

Figure 24: Bell's phenomenon.

7. Photography

To complete the examination of the eyelid, photographs should be taken before surgery and a schematic drawing made of the preexisting conditions. Besides helping with surgical planning, these photographs allow evaluation of the surgical outcome by comparing the post- and pre-operative states.

Photographs should be taken in the primary gaze position, upgaze, downgaze and lateral gaze. Occlusion should also be documented.

REFERENCES

1. Amato MM, Monheit B, Shore, JW. *Duane's Ophthalmology on CD-ROM*, 2006 Edition
2. Cantor LB, Rapuano CJ, Cioffi GA (2014-2015) Orbit, Eyelids and Lacrimal System - Section 7. American Academy of Ophthalmology
3. Golberg, RA *et al* (2005) *Oculoplastic Surgery Atlas – Cosmetic Facial Surgery*. Chapter 1; pp 1-23
4. Grover AK, Badeja S. *et al* (2011) *Long Case of Ptosis*. eJournal of Ophthalmology
5. Holds, J.B *et al* (2014) *Orbit, eyelids and lacrimal system*. Section 7. Chapter 9, pp 131-143. American Academy of Ophthalmology
6. Kanski J, Bowling B. (2012) *Clinical Ophthalmology - A systematic approach*. 7th Ed. Elsevier
7. Kim IT, Choi JB. (2001) Normal range of exophthalmos values on orbit computerized tomography in Koreans. *Oftalmológica*. 215(3) :156-62
8. Patel, B.; Taylor, S.F.; Gupta, R. (2013) *Eyelid anatomy*. Emedicine, Medscape
9. Rêgo MG, Rodvalho AJ *et al* (2003) Sensibilidade corneana e secreção lacrimal após LASIK. *Arquivo Brasileiro de Oftalmologia*. 66: pp 183-188.
10. Tan, K.; Oh, SR; Priel, A.; Korn, B.; Kikkawa, D. (2011) *Master Techniques in Blepharoplasty and Periorbital Rejuvenation*. Chapter 2; pp 11-24; 1st Edition, Springer
11. Wobig JL, Dailey RA (2004) *Oculofacial Plastic Surgery*. Evaluation of the eyelids. Chapter 3, pp 29-33. Thieme, United States of America

2. Anatomy and Clinical Examination of the Lacrimal Drainage System

João Gil, Marco Rego, Guilherme Castela

Background

A patient complaining of watery eyes will be one of the most common challenges any general ophthalmologist will face in their everyday clinical practice. Establishing the true nature of the patients' complaint and its underlying causes requires a systematic, organized approach. Causes can be conceptually divided between excessive tear production, obstruction or stenosis along the lacrimal excretory apparatus, and a functional, non-anatomical, failure. To determine the causes, the clinician should rely on a well-structured investigative process that begins with a detailed clinical history, continues with an accurate physical examination and, when indicated, includes additional exams or imaging procedures. The successful completion of all these steps requires a thorough comprehensive knowledge of the anatomy, physiology and pathophysiology of the lacrimal apparatus. A thorough understanding of the anatomy of the lacrimal system will further facilitate the chance of a successful surgical outcome

ANATOMY OF THE LACRIMAL SYSTEM

The lacrimal apparatus is part of the accessory organs that surround the eyeballs inside the bony orbit. The orbit is a pyramidal space confined by the bones of the skull. Its volume in the average adult is approximately 30 cm³, of which the eye contributes only 6 to 7.5 cm³.

Lacrimal secretion system

The Lacrimal Gland

The lacrimal gland is located on the supero-temporal aspect of the orbit. It lies within a small concavity of the frontal bone – the lacrimal gland fossa – part of the roof of the orbit. [Figure 1] A lateral expansion of the levator aponeurosis (the lateral horn) indents the lacrimal gland and separates it into two lobes, the orbital lobe and the palpebral lobe.¹ The palpebral lobe lies more anteriorly to the conjunctiva of the superior fornix, while the orbital lobe is located posteriorly and superiorly, still within the bony orbit.

Key-Point

Normally, eversion of the upper eyelid allows visualization of the palpebral lobe of the lacrimal gland

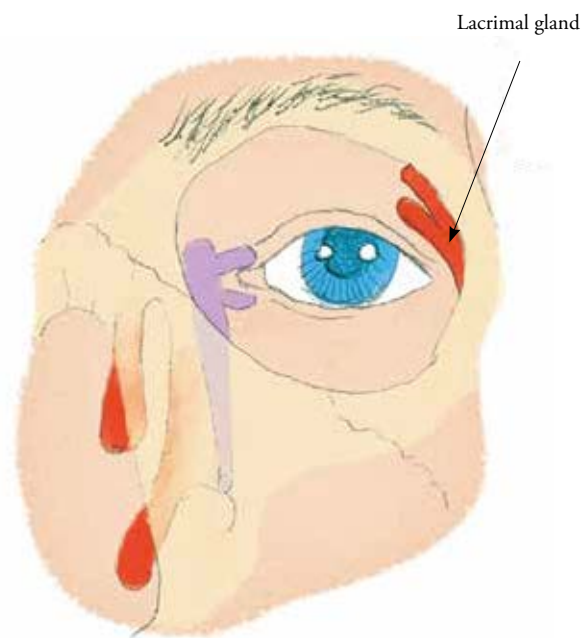


Fig.1 Location of the lacrimal gland.

The lacrimal ducts empty into the superior fornix after passing through the orbital lobe to the palpebral lobe.²

The accessory lacrimal glands of Krause, located in the superior fornix, and the lacrimal glands of Wolfring, located above the superior border of the tarsus, also aid exocrine tear secretion.^{3,4}

Key-Point

Any procedure performed on the superotemporal conjunctival fornix risks damaging the palpebral lobe and therefore causing dry eye. Biopsies of the lacrimal gland are usually performed on the orbital lobe, since damage to the palpebral lobe will impact on secretion from the entire gland.

2. Anatomy and Clinical Examination of the Lacrimal Drainage System

Lacrimal Drainage System

The main function of the lacrimal apparatus is to keep the eyeball properly moisturized and protected. For that to happen there must be a proper balance between inflow and outflow of tears. Tears are produced by the multiple lacrimal glands, they are then spread across the ocular surface and discarded through a drainage system that includes the superior and inferior puncta, the superior and inferior canaliculi, the common canaliculus, the lacrimal sac, and the nasolacrimal duct. The lacrimal drainage system structures and respective relative sizes are displayed schematically in Figures 3 and 4.

Medial Orbital Wall

The anatomy of the medial orbital wall is important for the surgical approach and radiological assessment of the lacrimal drainage system. Four bones constitute this wall: the maxillary, lacrimal, ethmoid, and sphenoid bones. [Figure 2] The foremost anterior part of the wall is composed of the frontal process of the maxillary bone. It contains the anterior landmark of the lacrimal fossa – the anterior lacrimal crest – and forms the anterior half of the fossa. The posterior part of the lacrimal sac fossa is formed by the lacrimal bone. The lacrimo-maxillary suture lies vertically in the center of the lacrimal fossa and constitutes a weaker point through which bony osteotomies can be constructed during an external DCR. The lacrimal sac occupies the superior part of the fossa, while the initial section of the nasolacrimal duct is in the inferior part of the fossa.

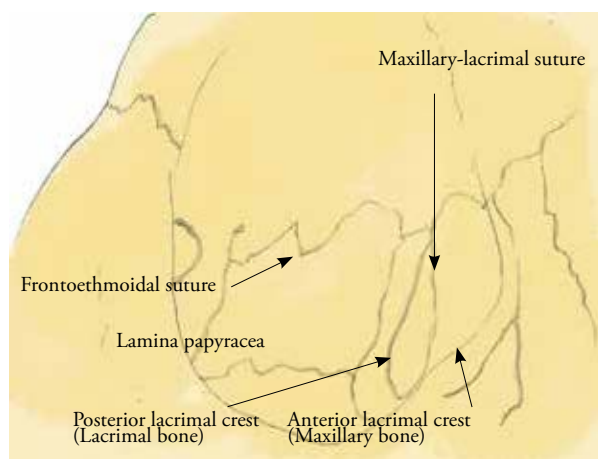


Fig. 2. Anatomy of the bones forming the medial orbital wall and lacrimal sac fossa.

Lacrimal Puncta

The drainage pathway is entered through 2 small orifices – or puncta – located medially on the margin of the inferior and superior eyelids.⁵ They are normally 0.2 to 0.3 mm in diameter and easily

recognizable macroscopically. They should be inverted slightly inwards, against the globe, and when the eyelids close they meet against each other and submerge within the tear lake. With the eyelids open, the inferior punctum can be seen lying slightly lateral to the superior punctum.⁶ Proper positioning of the puncta is essential for tear drainage and should always be assessed when investigating epiphora. Eccentric position, outward displacement or covering of the puncta by conjunctivochalasia can all lead to clinically significant epiphora.

Key-Point

The inferior punctum lies submerged in the tear meniscus and should require manual eversion of the eyelid for visualization.

Lacrimal Canaliculi

The tear drainage system proceeds from the puncta into the canaliculi. They are 1 to 1.5 mm in diameter and are lined by non-keratinized, stratified squamous epithelium.⁷ They travel 2 mm vertically before turning 90° and running another 8 to 10 mm horizontally while lying directly beneath the anterior limb of the medial canthal tendon. [Figure 3] In most people, the inferior and superior canaliculi then join to form a common canaliculus before entering the wall of the lacrimal sac. In approximately 10% of cases, the inferior and superior canaliculi enter the sac separately.^{8,9} However, the lower canaliculus is the most important drainage pathway, being responsible for 80-90% of the total tear volume that drains to the sac. Therefore, even a minor malfunction at this point can lead to pathological epiphora. The common canaliculus usually runs 2 to 5 mm horizontally and from back to front before entering the sac. It enters the sac at a sharp angle.¹⁰ This sharp flexure creates a short mucous membrane – the valve of Rosenmuller – which functions as a 1-way valve, preventing tears from returning from the sac back into the canaliculi.

Key-Point

The anatomical structure of the valve of Rosenmuller is suspected to be the cause of lacrimal sac mucocoele formation. When tears accumulate in the lacrimal sac due to nasolacrimal duct obstruction, the hydrostatic pressure in the sac increases, leading to apposition of the fold and permanent closure of the ostium to the common canaliculus.

Lacrimal Sac

The lacrimal sac is confined to the lacrimal fossa in the medial orbital wall and separated from the orbit

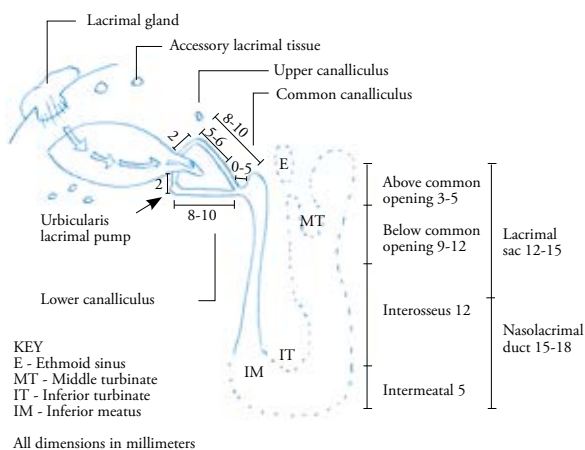


Fig. 3. Lacrimal Drainage System shapes and sizes.

by the orbital septum. It measures approximately 12 to 15 mm in height and is approximately 2 to 3 mm wide in its resting, semi-collapsed, state.⁷ The total volume of the sac should be around 0.1 ml. Like the canaliculi, it can change in size, and the maximum width that should be considered pathological is still open to question.^{11,12} Changes in canaliculi and lacrimal sac lumen size have a physiological function and are determined by the combined work of the orbital muscle and the medial palpebral ligament to create a pump effect, thus permitting tear drainage. During eyelid closure, the distal part of the canaliculi lumen constricts under pressure from Horner's muscle and compresses tear fluid into the sac. When eyelids open, the lumen dilates to cause the absorption of fluid. Contrary to the lacrimal canaliculi, the lacrimal sac expands during eyelid closure and contracts when the eyelids open. With contraction, positive pressure rises inside the sac, expelling tears through the nasolacrimal duct. When eyelids open, negative pressure is created, drawing tears into the sac.

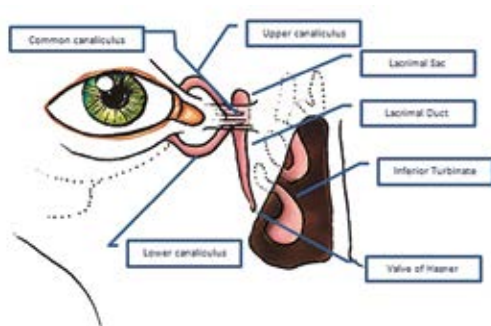


Fig. 4. Lacrimal Drainage System.

The medial palpebral ligament splits into 2 arms before reaching the lacrimal sac: the anterior arm that covers the anterior portion of the sac and attaches to anterior lacrimal crest, and the posterior arm that

runs posterior to the sac and is fixed to the posterior lacrimal crest. The medial palpebral ligament is an important landmark for lacrimal system semiology and surgery. The superior part of the sac that rises above the line of the ligament is called the fornix. The central part of the sac is confined anteriorly by the ligament, thus preventing distension of the sac by accumulation of fluid or mucus. For this reason, when a mucocele or amniocoele is present, distension of the sac occurs below the level of the medial canthal tendon. Despite its firm structure, the medial ligament will not contain an infiltrative neoplastic growth. Therefore, any enlargement of the sac above the ligament should raise immediate suspicion.

Key-Point

Sac enlargement below the medial canthal tendon is characteristic of mucocele and nasolacrimal duct obstruction. Enlargements at the level of the ligament are suspicious and should be clarified by magnetic resonance imaging

Inferiorly, the lacrimal sac narrows progressively and eventually continues into the nasolacrimal duct, a transition marked by the presence of a small membranous fold, the valve of Krause.

Nasolacrimal Duct

The nasolacrimal duct travels infero-laterally and posteriorly for another 15mm, draining tears from the lacrimal sac into the inferior turbinate in the inferior meatus of the nose.¹³ [Figure 4] Its course can be divided, in a superior portion located in the fossa of the lacrimal sac separated from an inferior portion, located in the bony canal of the nasolacrimal duct. This division is of some diagnostic importance because ultrasound can be used to assess the superior portion while the inferior portion can only be visualized by X-ray or endoscopic imaging. The inferior ostium of the duct represents the distal ending of the lacrimal system and is usually covered in part by a mucosal fold called the valve of Hasner. This valve is formed late in the course of embryological development and often a small imperforate obstruction is present in newborns. Three or four weeks into the newborn's life, epiphora and an abundance of mucous secretion will be noted. In most cases the condition is self-limiting and spontaneous opening of the meatus is achieved in the first 12 months of life. If spontaneous improvement is not noted, a surgical intervention might be warranted, usually by nasolacrimal probing.¹⁴

EVALUATION OF THE LACRIMAL SYSTEM

Although both terms are sometimes used interchangeably, one should be alert to the distinction between true epiphora and excessive lacrimation. Lacrimation (hypersecretion, reflex tearing, hyperlacrimation) is excessive tearing caused by reflex hypersecretion due to the irritation of the cornea or conjunctiva. Epiphora refers to frank overflow of tears onto the cheek and implies some type of impairment to tear drainage. It can be caused by a mechanical obstruction to the lacrimal drainage system, which may include puncta, canaliculi, lacrimal sac, or nasolacrimal duct obstruction. These anatomical obstructions can be congenital, like nasolacrimal duct obstructions in children, or acquired diseases, such as primary acquired nasolacrimal duct obstructions, or obstructions caused by trauma or infection. The second, but less frequent, cause of epiphora is a physiological dysfunction called functional epiphora where there is a lacrimal pump failure due to lid laxity or weakness of the orbicularis muscle.¹⁵

Although different components of the lacrimal system – production, distribution, drainage – may be anatomically separate, symptoms caused by disruption in any of them can be strikingly similar. Not all patients complaining of watery eyes will actually have epiphora and they may have little or no benefit from lacrimal drainage surgery.

A systematic and thorough history and clinical examination will allow the clinician to accurately distinguish between epiphora and lacrimation and to appropriately handle the management of the patient.

History

As in most medical conditions, careful history taking can be invaluable to helping to identify the cause of tearing. Guiding the interview to try and differentiate patients with hyper-secretion of tears from those with impairment of drainage can be a good starting point.¹⁶ It is important to characterize tearing episodes in terms of laterality, severity, onset, duration, seasonal and circadian variations, factors associated with exacerbation or remission, association with potential occupational exposure, and other accompanying symptoms. Subjective ocular surface discomfort is an important marker of dry eye and should alert the clinician to the possibility of increased reflex tear secretion. A history of known allergies, chronic use of topical eye medications (e.g. glaucoma medication), poor contact lens habits, previous refractive surgery or eyelid surgery are all risk factors for ocular surface disorders and their presence should be asked about and noted.

Previous intranasal or facial trauma and/or surgery could be the cause of nasolacrimal obstruction and detailed imaging evaluation should be requested.

Numerous episodes of lacrimal sac inflammation and dacryocystitis are also indicators of probable obstruction.

A full systemic health review should be part of the interview, along with an up-to-date medication history.

Examination

Like history taking, examination is best conducted as a systematic, organized process that can help us differentiate patients with lacrimal drainage obstruction from patients with excess lacrimation.

Before any specific test, a watchful gross examination of the patient is mandatory. Many patients complain of constant, relentless tearing but don't display any actual tears during examination or history taking. The general features of cranial and facial features are also important since they could be indicative of anatomical or functional disorders. The patient's blinking pattern while sitting in the examination room should be carefully observed. An incomplete blink could cause lacrimal pump insufficiency, and a frank lagophthalmos caused by previous facial paralysis could lead to surface damage and reflex hyperlacrimation.

Eyelid Examination

Numerous eyelid disorders could lead to clinically significant tearing and it is important not to overlook them.¹⁷

Upper and lower eyelid entropion and lower lid ectropion should be excluded. The laxity and mobility of the lower eyelid can be tested using the lateral distraction test, "snap back" test^{11,6} and horizontal "pinch" test⁶. Asking the patient to look up and simultaneously open his/her mouth might elicit cicatricial vertical traction on the eyelid that was not visible before. The lid margins need to be examined for signs of chronic blepharitis, trichiasis or other lesions that could be responsible for ocular surface injury. All of the eyelid surface, with special attention to the medial canthus, should be carefully palpated in the search of any extrinsic compressive lesions or intrinsic lacrimal sac lesions.

Careful examination of the lacrimal sac is mandatory.¹⁸ Obvious signs of inflammation should be noted. A distended lacrimal sac that elicits a reflux of mucoid material through the puncta when palpated is pathognomonic of nasolacrimal duct obstruction.

Slit Lamp Examination

Biomicroscopy should start with a quick assessment of the ocular surface health. The tear meniscus should be evaluated in terms of tear quantity and quality - the presence of mucous strands or other inappropriate traces could indicate a deficient tear film. The puncta

must be closely examined to make sure they are properly positioned – everted posteriorly, facing the tear lake – and patent. Examination of the puncta should be repeated while massaging the lacrimal sac and the canaliculi, looking for the presence of any subtle discharge. In some patients exuberant conjunctivochalasis can partially or entirely cover the opening of the puncta.

The use of diagnostic colorants – rose Bengal, lissamine green or fluorescein – will show up any ocular surface damage.

Two other tests, the tear breakup time and Schirmer test, can be useful to judge normal tear quality and secretion, respectively.

Lacrimal Outflow Evaluation

The dye disappearance test (DDT) is a simple procedure that can provide relevant information on the real lacrimal outflow under physiologic conditions.⁽¹⁹⁾ Fluorescein solution is instilled in the fornices of both eyes and tear film is observed. Observation is repeated after 5 minutes and the level of dye disappearance is noted and compared for the two eyes. Complete disappearance excludes any significant anatomical or functional impairment. Incomplete or asymmetric disappearance is indicative of some level of drainage impairment and should warrant further testing.²⁰

The Jones I and II tests have long been used to evaluate the ability of tears to be excreted through the lacrimal apparatus.^{6,11,21} The Jones I test is similar to the DDT and requires instilling fluorescein dye in the fornices. After 5 minutes, the area under the inferior meatus is anesthetized and then swabbed with a cotton-tipped wire probe to demonstrate the presence of fluorescein in the nasolacrimal drainage system. If the Jones I test is unsuccessful, the Jones II test can be conducted. Any residual dye is completely rinsed from the conjunctival sac. The lower punctum is then dilated and the lacrimal drainage system is irrigated with clear sterile saline. Outcomes from the Jones I and II tests can differ: 1) it is impossible to inject any fluid into the system and a complete blockage is assumed; 2) fluid regurgitates through the upper punctum indicating blockage of the common canaliculus or the nasolacrimal duct; 3) fluid mixed with fluorescein exits the nose after the Jones II test indicating a partial distal obstruction that was overcome with the manual irrigation; 4) completely clear fluid is expelled from the nose, implying that no fluorescein was able to enter the system and punctal stenosis or eyelid malposition are the most likely culprits.

Key-Point

The Jones tests are technically difficult to perform and the added information they provide is debatable. We find them of historical importance but have abandoned their use in clinical practice and perform only the DDT and lacrimal permeability test.

The lacrimal permeability test is useful to better establish the exact point of obstruction after drainage impairment has been diagnosed with the DDT.²² First, local anesthetic is instilled and careful dilation of the punctum is performed. A syringe is filled with clear saline and its cannula gently inserted into the punctum and manipulated through the canaliculus. Manual lateral traction on the lower eyelid helps to straighten the canaliculus and aids the procedure. Any significant difficulty advancing the cannula and the level where it occurs should be noted. When the cannula is properly placed in the horizontal section of the canaliculus, saline is injected and the result observed. Under normal circumstances the patient should notice the passage of the saline into the nasopharynx. Regurgitation through the opposite punctum suggests blockage of the common canaliculus or the nasolacrimal duct. Palpation or not of distension of the lacrimal sac with irrigation may help differentiate between the two. If mucoid or purulent material accompanies the reflux, a nasolacrimal duct obstruction is likely present. The presence of blood with saline reflux is consistent with a potential lacrimal system malignancy that needs to be excluded.

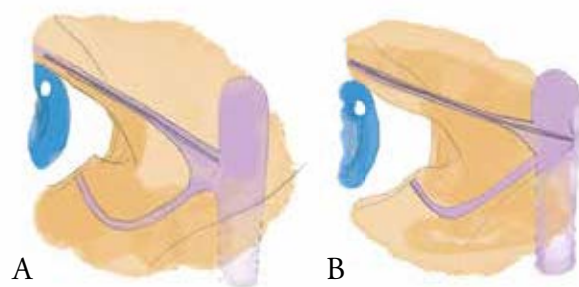


Fig. 5. A) Soft Stop; and B) Hard Stop.

Probing of the canaliculus can help determine the exact location of an obstruction revealed by the lacrimal permeability test. Careful probing is performed with a Bowman probe and a “soft stop” is felt at the site of obstruction. [Figure 5A] There is perception of a “hard stop” when the probe encounters bone and this implies entry into the lacrimal sac. [Figure 5B] Upon encountering a stenosis, marking the point of the probe at the level of the punctum and then measuring the length that is withdrawn can help estimate the location of the obstruction.²³

2. Anatomy and Clinical Examination of the Lacrimal Drainage System

Key-Point

Free passage of saline into the nose implies a patent drainage system but even gentle irrigation involves a higher hydrostatic pressure than that of normal tear flowing. Therefore, patients with mild stenosis or with a functional impairment can have apparently normal results with the lacrimal permeability test.

Probing of the nasolacrimal duct is reserved for cases of congenital nasolacrimal duct obstruction in children and should never be performed in adults.

Key-Point

The probe should never be forcibly advanced through an area of stenosis, under the risk of creating a false passage.

Imaging

For most patients, a meticulous physical examination and careful history taking should be enough to determine the underlying point of obstruction and appropriate therapeutic procedure. However, in some cases, decisions about the method of treatment and subsequent prognosis are better made with the aid of imaging information. Imaging techniques commonly used include dacryocystography (DCG), dacryoscintigraphy, computed tomography (CT), and magnetic resonance imaging (MRI).

Dacryocystography is a method that involves the injection of a radio-opaque fluid instilled into either the lower or upper canaliculus. Magnified radiological images are then obtained and provide an accurate insight into the anatomy of the lacrimal pathway. It is usually requested after a blockage has been found by syringing the lacrimal system. Common indications are: 1) complete obstructions: reveals the

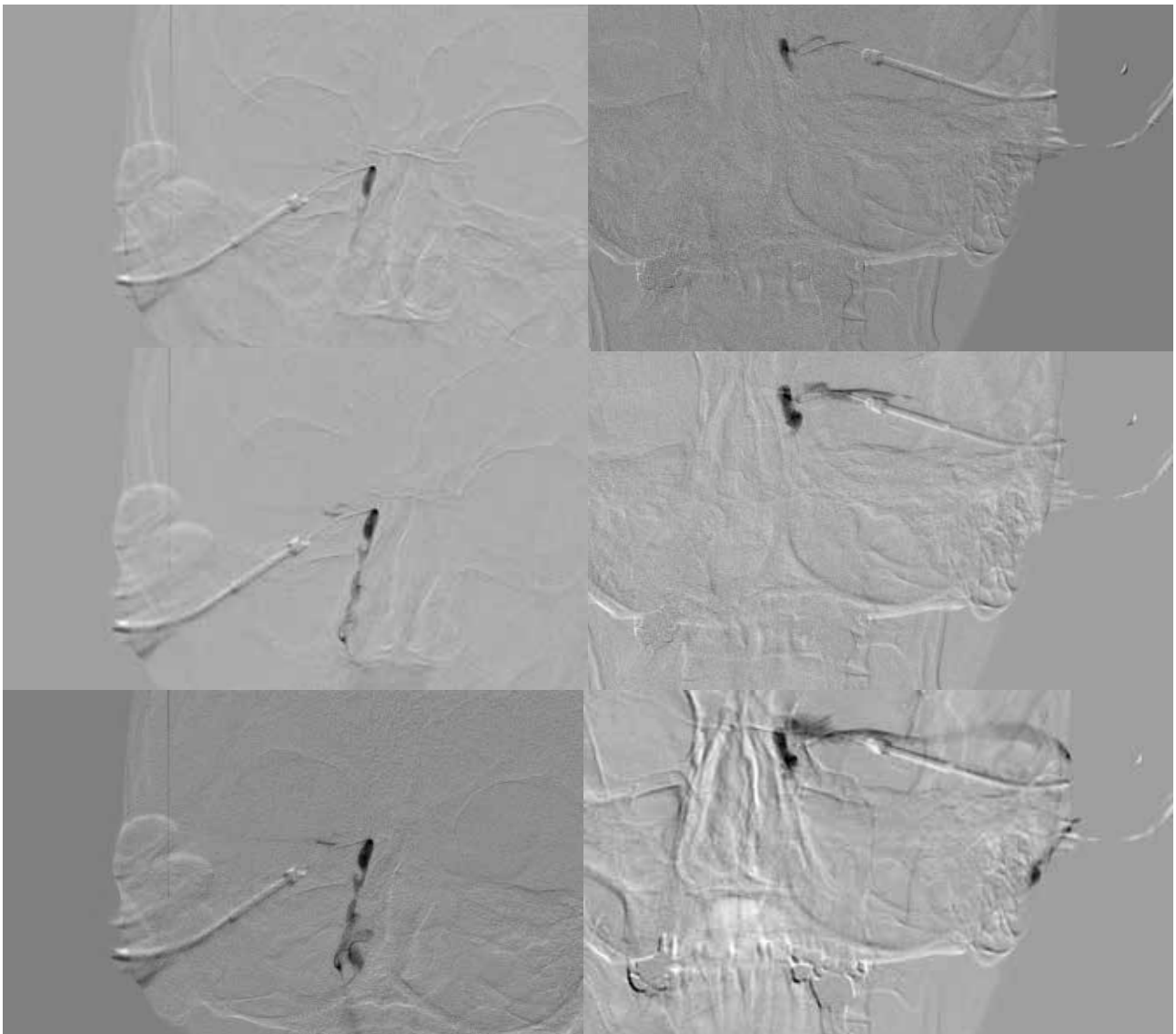


Fig. 6. Dacryocystography. Normal lacrimal system on the right. Slightly dilated lacrimal sac with complete obstruction at the sac–NLD junction on the left.

size of the sac and NLD, helps determine the precise location of the obstruction; 2) partial or functional obstruction: location of the stenosis, diverticulum, or stone; confirms a diagnosis of functional disorder when there is no anatomical anomaly; 3) suspected lacrimal sac tumor; 4) suspicion of abnormal anatomy: previous trauma, craniofacial surgery, congenital anomalies, failed lacrimal surgery.

Despite the merits of DCG we do not perform it routinely in cases of complete obstruction in non-traumatic patients.^{6,11,22} When indicated, we prefer to perform bilateral studies, as a better way to compare both sides and understand the anomalies seen. [Figure 6.]

Dacryoscintigraphy is another exam that outlines the anatomy of the lacrimal pathway through the instillation of a radionuclide tracer (technetium-99m pertechnetate) that is then imaged with a gamma camera. Dacryoscintigraphy is a more physiological test than DCG, and it can be particularly useful in cases of incomplete patency or of an apparently patent lacrimal system in a patient with constant epiphora. (24) Despite being more physiological it lacks some of the anatomical detail provided by DCG. Because of that, the interaction between the anatomical (DCG) and the functional (Dacryoscintigraphy) findings should be carefully assessed when planning surgery.^{6,25}

Computed tomography or magnetic resonance imaging are very seldom performed. When needed, their benefit lies in the ability to evaluate structures surrounding the lacrimal drainage system. CT images are used mainly when an extrinsic disease is suspected: following facial trauma or surgery, or in patients with a suspected lacrimal sac malignancy.²² MRI is virtually never used and is reserved only for cases when previous imaging results require further differentiation.

References

1. Morton AD, Elner VM, Lemke BN, White VA. Lateral Extensions of the Muller Muscle. *Archives of Ophthalmology*. 1996. p. 1486–8.
2. Lemke B, Lucarelli M. Anatomy of the ocular adnexa, orbit, and related facial structures. *Smith's Ophthalmic Plastic and Reconstructive Surgery*. 2nd ed. St Louis: Mosby, an imprint of Elsevier; 1998. p. 3–78.
3. Dutton J. The lacrimal systems. *Atlas of Clinical and Surgical Orbital Anatomy*. Philadelphia: WB Saunders; 1994. p. 140–2.
4. Seifert P, Spitznas M, Koch F, Cusumano A. Light and Electron Microscopic Morphology of Accessory Lacrimal Glands. *Lacrimal Gland Tear Film Dry Eye Syndr Adv Exp Med Biol*. 1994;350:19–23.
5. Whitnall S. *The Anatomy of the Human Orbit and Accessory Organs of Vision*. New York: Oxford University Press; 1932. 1-252 p.
6. Hurwitz J. *The Lacrimal System*. Philadelphia: Lippincott-Raven; 1996.
7. Jones L. An anatomical approach to problems of the eyelids and lacrimal apparatus. *Arch Ophthalmol*. 1961;66:111–24.
8. Yazici B, Yazici Z. Frequency of the common canaliculus: a radiological study. *Arch Ophthalmol*. 2000;118(10):1381–5.
9. Lemke B. Lacrimal anatomy. *Adv Ophthalm Plast Reconstr Surg*. 1984;3:11–23.
10. Tucker NA, Tucker SM, Linberg J V. The anatomy of the common canaliculus. *Arch Ophthalmol*. 1996;114(10):1231–4.
11. Olver J. *Colour Atlas of Lacrimal Surgery*. Oxford: Butterworth-Heinemann; 2002. 2-23 p.
12. Malik SR, Gupta a K, Chatterjee S, Bhardwaj OP, Saha M. Dacryocystography of normal and pathological lacrimal passages. *Br J Ophthalmol*. 1969;53(3):174–9.
13. Groell R, Schaffler GJ, Uggowitzer M, Szolar DH, Muellner K. CT-anatomy of the nasolacrimal sac and duct. *Surg Radiol Anat*. 1997;19(3):189–91.
14. Rego M, Láins I, Leal A, Paiva C, Ponces F, Castela G. FATORES PREDITIVOS E TAXA DE SUCESSO DA SON-DAGEM NA OBSTRUÇÃO CONGÊNITA DO CANAL NASOLACRIMAL. *Manuscr Submitt Publ*. 2014.
15. Leatherbarrow B. *Oculoplastic Surgery*. 1st ed. London: Martin Dunitz; 2002.
16. Watkins LM, Janfaza P, Rubin PAD. The evolution of endonasal dacryocystorhinostomy. *Surv Ophthalmol*. 2003;48(1):73–84.
17. Gonnering R. Dacryocystorhinostomy and conjunctivodacryocystorhinostomy. *Ophthalmic plastic surgery: prevention and management of complications*. New York: Raven Press; 1994. p. 237–50.
18. Frueh BR. The role of lacrimal sac palpation in evaluation of lacrimal drainage problems. *Ophthalmic Surg*. 1985;16(9):576.
19. Bowyer JD, Holroyd C, Chandna A. The use of the fluorescein disappearance test in the management of childhood epiphora. *Orbit [Internet]*. 2001;20(3):181–7. Available from: <http://eutils.ncbi.nlm.nih.gov/entrez/eutils/efetch.fcgi?dbfrom=pubmed&id=12045910&retmode=ref&cmd=prlinks\papers2://publication/uuid/CAE793C9-BF8A-4BDC-B142-82E55C960CA3>
20. Kashkouli MB, Mirzajani H, Jamshidian-Tehrani M, Pakdel F, Nojomi M, Aghaei G-H. Reliability of Fluorescein Dye Disappearance Test in Assessment of Adults With Nasolacrimal Duct Obstruction. *Ophthalmic Plast Reconstr Surg [Internet]*. 2013;1. Available from: <http://content.wkhealth.com/linkback/openurl?sid=WKPTLP:landingpage&an=00002341-9000000000-99467\papers2://publication/doi/10.1097/IOP.0b013e3182873b40>
21. Hagele JE, Guzek JP, Shavlik GW. Lacrimal testing. Age as a factor in Jones testing. *Ophthalmology*. 1994;101(3):612–7.
22. Komínek P, Červenka S, Müllner K. *The lacrimal diseases. Diagnosis and treatment*. Prague: Maxdorf; 2003.
23. Komínek P, DellaRocca RC, Rosenbaum S. *Diagnostics*. In: Weber PDRK, Keerl DR, Schaefer DSD, DellaRocca DRC, editors. *Atlas of Lacrimal Surgery*. Springer Berlin Heidelberg; 2007.
24. Mannor GE, Millman AL. The prognostic value of preoperative dacryocystography in endoscopic intranasal dacryocystorhinostomy. *Am J Ophthalmol*. 1992;113(2):134–7.
25. Chung YA, Yoo IR, Oum JS, Kim SH, Sohn HS, Chung SK. The clinical value of dacryoscintigraphy in the selection of surgical approach for patients with functional lacrimal duct obstruction. *Annals of nuclear medicine*. 2005.

3. Anatomy and Clinical Examination of the Orbit

Mara Ferreira, João Cabral

The goal of this chapter is to describe the clinical and surgical anatomy of the orbit.

In the adult, the bony orbit (Fig.1) is roughly pyramidal or pear shaped due to the posterior curve of the medial and lateral walls and floor, which narrow towards the apex. The anterior entrance is approximately rectangular, measuring 4 cm wide by 3.5 cm high¹. The orbit is at its widest about 1 cm behind the bony rim. The rest of the walls of the orbit are formed by bones that converge posteriorly. The medial wall and roof extend posteriorly to the optic canal (Fig. 2). The lateral wall terminates at the superior orbital fissure and the floor merges with the medial wall and extends posteriorly to the inferior orbital fissure. The dimensions of the orbit, especially its depth, are quite variable, thus the surgeon must proceed with extreme caution with posterior orbital dissections and, if it is possible, they should study the orbit images of the patient to know the location of the optic canal, superior orbital fissure, the ethmoidal foramina and the bridging over the infraorbital canal.

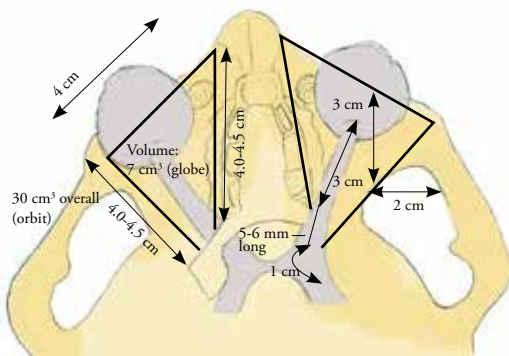


Figure 1. Anatomy of the orbital walls.

The orbital rim (Fig. 2)

The **superior orbital rim** is formed by the frontal bone. In the medial third there is the notch for the supraorbital neurovascular bundle. In one third¹ of the orbits the notch is closed to form a foramen just above the rim. The location of the notch is an

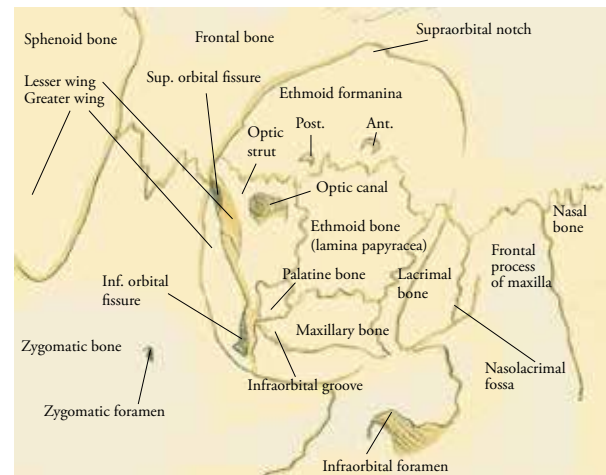


Figure 2. Bones of the orbit.

important guide to help avoid injury to the nerve, for example in the surgery of the brow, or for the anesthesia of the medial superior lid.

The supratrochlear nerve and artery, the infratrochlear nerve and the dorsal nasal artery emerge between the supraorbital notch and the medial canthal tendon. Surgical access to the medial wall through a frontomaxillary incision may interfere with these structures.

Medially the rim is formed by the anterior crest of the frontal process of the maxillary bone. It begins above the medial canthal tendon. An incision at this level for lacrimal surgery should take extreme care with the artery and the angular vein.

The **inferior orbital rim** is composed medially of the maxillary bone and laterally of the zygomatic bone. The infraorbital foramen, which carried the infraorbital artery and nerve, is located 4 to 10 mm¹ below the central portion of the rim. During surgery on the orbital floor, care must be taken not to elevate the periosteum anterior to the rim for more than about 4 mm otherwise these neurovascular structures could be injured.

The **lateral wall** is formed by the frontal process of the zygomatic bone and the zygomatic process of the frontal bone. The anterior cranial fossa lies 5 to 15 mm above the frontozygomatic suture line. This is an important landmark for removing the

3. Surgical Anatomy and Clinical Examination of the Orbit

lateral rim during orbital surgery. About 10 mm below the frontozygomatic suture line, on the inside edge of the lateral rim and 5 mm posterior², is the Whitnall tubercle, which serves as the insertion site for the posterior crus of the lateral canthal tendon, Lockwood's inferior suspensory ligament, the lateral horn of the levator aponeurosis, the lateral check ligament of the lateral rectus muscle, and the deep layer of the orbital septum.

The orbital walls (Fig. 1 and 2)

The medial walls of the orbit are approximately parallel to each other and to the mid-sagittal plane. They measure 45 to 50 mm from the anterior lacrimal crest (medial orbital rim) to the medial optic canal entry ring. They are formed by the maxillary, lacrimal, ethmoid and sphenoid bones. This wall is very thin and separates the orbit from the nasal cavity at the front and the ethmoidal cells and the sphenoidal sinus posteriorly.

It starts with the anterior lacrimal crest, where the anterior limb of the medial canthal tendon is attached. Posteriorly is the lacrimal sac fossa. The thick anterior part of this fossa is formed by the frontal process of the maxillary bone, and the thin posterior part is formed by the lacrimal bone. It is limited by the posterior lacrimal crest (the posterior limb of the medial canthal tendon inserts here).

In a dacryocystorhinostomy procedure, it is easy to create a bony osteum in the lacrimal bone and difficult to do so in the frontal maxillary part of the lacrimal sac fossa. We should leave the tendon attached to use it as a guide for placement of the upper border of the bony osteum so as to prevent cerebrospinal fluid leakage (the distance to the anterior cranial fossa is 0 to 30 mm¹).

Behind the lacrimal bone is the lamina papyracea that is 40 to 60 mm in length and 0.2 to 0.4 mm thick, which is why it fractures so frequently after orbital trauma. When there is a medial displacement to the ethmoid air cells of the orbit content, after papyracea fracture, we can have 1 to 1.5 mm of enophthalmos, which is used in decompression surgery. The lamina papyracea offers only a minimal barrier to the spread of infection from the ethmoid sinus into the orbit, resulting in cellulitis associated with ethmoid sinusitis. Superiorly the ethmoid joins the orbital roof at the frontoethmoidal suture line. This approximately marks the roof of the ethmoid labyrinth and the floor of the anterior cranial fossa. Just medial to the labyrinth, on either side of the crista galli, is the cribriform plate, which may extend 5 to 10 mm below the level of the frontoethmoidal suture line. The root of the middle nasal turbinate separates the cribriform plate from the superior ethmoid

air cells. This relationship is important in surgery along the medial wall. The anterior and posterior ethmoidal foramina lie within the frontoethmoidal suture line; they carry branches of the ophthalmic artery and nasociliary nerve and are our references for the upper limit in the surgery of the medial wall. A mnemonic for the average positions of the ethmoidal foramina relative to the anterior lacrimal crest is "24-12-6", that is, 24 mm from the lacrimal crest to the anterior ethmoid foramen, another 12 mm from the anterior to the posterior foramen, and 6 mm from the posterior foramen to the optic canal ring (only 2 mm in Asians)². Subperiosteal hematoma following trauma frequently occurs after rupture of one of these arteries.

Behind the ethmoid bone and forming the posterior portion of the medial wall is the body of the sphenoid bone, which contains the sphenoid sinus.

The **optic canal**, with the optic nerve and the ophthalmic artery, is situated in the superomedial portion of the apex and is enclosed by the body of the sphenoid medially, the lesser sphenoid wing superiorly, and the optic strut inferolaterally. At its orbital end it assumes a vertically oval shape and measures about 5 to 6 mm in diameter. It is 8 mm long² and travels inward and upward, allowing visualization of the medial wall of the canal endoscopically or from an anterior surgical approach. In cases of compressive optic neuropathy in Graves' disease, it is essential to open the posterior ethmoid sinus back to the ethmoid-sphenoid suture line.

The **orbital floor** is triangular, curvilinear (horizontally flat only in the anterior-most portion), very thin plate composed of three bones: the maxillary, zygomatic, and palatine bones. It is thinnest medial to the infraorbital canal, where it may be only 0.5 mm thick. This is the portion of the floor that is usually involved in blow-out fractures and the convenient point for initial entrance into the maxillary sinus during orbital decompression surgery. A trauma with fracture and a 3 mm downward displacement of the entire floor results in 1 to 1.5 mm¹ of enophthalmos. The floor is strengthened by the infraorbital canal, which runs through it near its midline.

The orbital plate of the maxillary bone also forms the roof of the maxillary sinus.

The floor is bounded medially by the maxilloethmoid suture line, anterolaterally by the zygomaticomaxillary suture, and posterolaterally by the inferior orbital fissure. It does not extend to the apex, but ends at the pterygopalatine fossa. It is the shortest orbital wall, about 35 to 40 mm from the rim. During orbital fracture surgery or floor decompression, dissection need

not be carried farther than the posterior antral wall.

The **infraorbital sulcus**, carries the maxillary branch of the trigeminal nerve and the infraorbital artery from the pterygopalatine fossa. The posterior portion is approximately in the center of the floor. At about mid-portion of the floor, the sulcus is bridged by the maxillary bone to form the infraorbital canal, and can be identified a slight ridge. This thin bridge is pierced by one or more tiny foramina that take anastomotic vessels from the infraorbital artery to the inferior muscular branch of the ophthalmic artery. It continues forward to the orbital rim, where it exits as the infraorbital foramen. Recognition of the canal is critical in orbital floor surgery because if damaged it results in anesthesia of the cheek and upper lip.

Separating the maxillary bone, forming the floor, from the greater wing of the sphenoid, part the lateral orbital wall, is the **inferior orbital fissure**. The anterior edge is usually 20 to 15 mm^{1,2} from the orbital rim. This opening is approximately 20 mm long and runs in an anterolateral to posteromedial direction. It varies in shape, usually being widest at its anterior border and narrowing as it extends posteromedially. At the orbital apex, just below the optic canal, the inferior fissure joins the superior orbital fissures and is contiguous with the foramen rotundum. The inferior fissure transmits structures into the orbit from the pterygopalatine fossa posteriorly and from the infratemporal fossa anteriorly. These structures are: multiple branches of the inferior ophthalmic vein that go on to communicate with the pterygoid venous plexus; maxillary branch of the trigeminal nerve from the foramen rotundum; infraorbital artery; postganglionic parasympathetic secretory and vasomotor neural branches from the pterygopalatine ganglion.

The **lateral wall** of the orbit (Fig. 3) is triangular and composed of the zygomatic bone anteriorly and the greater wing of the sphenoid posteriorly. It is bordered posteriorly by the superior orbital fissure, inferioposteriorly by the inferior orbital fissure, and the frontosphenoidal suture forms the junction between the lateral wall and the roof. It separates the orbit and the temporal fossa anteriorly with the temporal muscle, and the orbit and the middle cranial fossa posteriorly with the temporal lobe of the brain. It forms an angle of approximately 45 degrees at the mid-sagittal plane and the length from the orbital rim to the superior orbital fissure is about 40 mm², similar to medial wall. Because of the oblique orientation of the lateral wall, the lateral rim lies about 10 mm posterior to the medial rim.

In the anterolateral wall there are small foramina that perforate the wall of the zygomatic bone and transmit branches of the lacrimal artery and zygomatic nerve as zygomaticotemporal and zygomaticofacial neurovascular bundles. The tubercle of Whitnall can be found 5 mm posterior to the lateral rim.

The lateral wall is the thickest wall of the orbit, and thinnest part is at the zygomaticosphenoid suture, about 10 mm behind the orbital rim. During lateral orbital surgery, cuts through the bone must be made to this level so that the rim can be fractured outward easily. Approximately 10 mm behind the zygomaticosphenoid suture and 20 mm from the lateral rim, the sphenoid bone thickens at the triangular diploic trigone, where it forms the anterior corner of the middle cranial fossa, overlying the anterior tip of the temporal lobe. Here, compact bone becomes cancellous bone, a useful landmark when taking down the lateral wall to gain access to the orbit. It again becomes fairly thin bone near the superior orbital fissure.

Near the frontosphenoid suture line, 30 mm from the orbital rim, there may be one or more cranio-orbital foramina, which carry an anastomotic branch between the middle meningeal artery and the ophthalmic arterial system, at the root of the lacrimal artery. They are easily ruptured during lateral orbital surgery, resulting in bleeding that can usually be controlled with compression for several minutes.

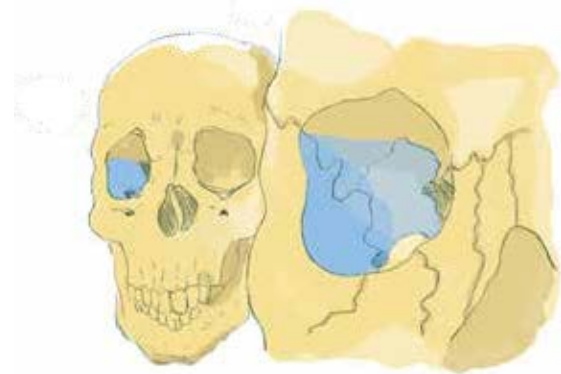

Figure 3. Lateral bony wall of the orbit.

At the junction of the lateral wall and the roof is the **superior orbital fissure** (Fig.4), lying between the greater and lesser wings of the sphenoid bone near the orbital apex, and between the middle cranial fossa and the orbit. Its size and shape vary considerably, but it is generally triangular with a posterior inferomedial base, and its anterior edge is approximately 32 to 40 mm² from the orbital margin. The central portion is anatomically divided by the annulus of Zinn, which serves as the tendinous origin for the rectus muscles. The central opening enclosed by the annulus is called the oculomotor foramen and it transmits into the

3. Surgical Anatomy and Clinical Examination of the Orbit

intraconal orbital space the superior and inferior branches of the oculomotor nerve, the abducens nerve, and the nasociliary nerve. Outside the annulus, it transmits trochlear nerve, the frontal and lacrimal branches of the trigeminal nerve and ophthalmic vein to the extraconal space.

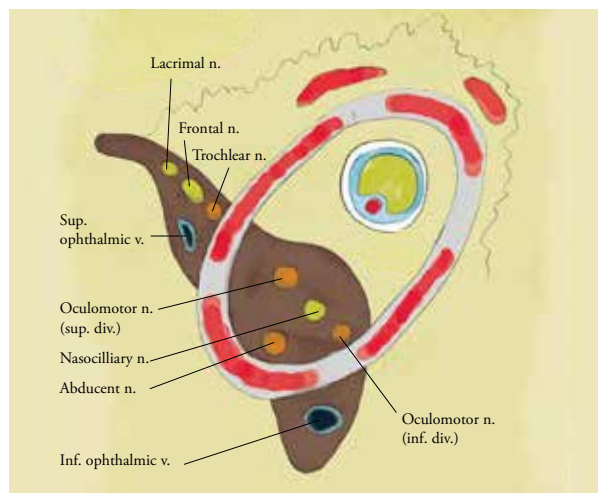


Figure 4. Superior orbital fissure.

The **orbital roof** is formed primarily by the orbital plate of the frontal bone, with a small contribution by the lesser wing of the sphenoid bone posteriorly. In the anterior superolateral corner is a poorly defined concavity for the lacrimal gland. A small depression in the superomedial corner, about 3 to 5 mm behind the rim, is the fibrocartilaginous trochlea for the superior oblique tendon.

The orbital roof is very thin and easily perforated by surgical instruments. The frontal sinus is housed in the frontal bone in the anteromedial portion of the roof, and behind is the anterior cranial fossa with the frontal lobe of the brain.

The muscles of ocular motility

The four rectus muscles arise from a fibrotendinous ring at the orbital apex, the annulus of Zinn. It consists of two half circles, the tendon of Zinn inferiorly (the thicker portion) and the tendon of Lockwood superiorly (Fig. 5).

The tendon of Zinn is attached to the greater wing of the sphenoid bone laterally, lining the superior orbital fissure, and to the body of the sphenoid medially along the medial orbital surface of the optic foramen. It serves as the origin for the inferior, medial, and lateral rectus muscles.

The tendon of Lockwood is much less well developed and laterally it bridges the superior orbital fissure; medially, it fuses with the dura and the periorbital at the lesser wing of the sphenoid along the superomedial roof of the optic foramen. It serves as the origin for the superior rectus muscles and, more anteriorly, for the levator palpebrae superior.

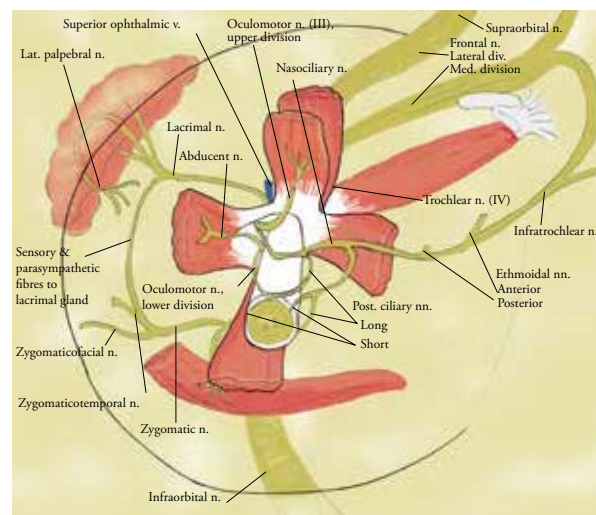


Figure 5. Extraocular muscles.

The medial and the superior rectus muscles are contiguous with the optic nerve sheath at the orbital apex. This is why, when retrobulbar neuritis affects this portion of the nerve, there is painful ophthalmoplegia. The contraction of these muscles is transmitted directly to the inflamed dura at the entrance to the optic canal.

Thickening of the medial and inferior rectus muscles associated with thyroid orbitopathy, especially when near the orbital apex, is a major cause of compression of the optic nerve as it enters the optic canal adjacent to the body of the sphenoid bone.

During superior orbital surgery with unroofing of the superior orbital fissure or optic canal, the annulus of Zinn can be opened most easily between the medial edge of the superior rectus and the origin of the medial rectus muscles. Division of the annulus in this region carries the least risk of damaging neurovascular structures, which are concentrated superolaterally. To gain access to this portion of the annulus, the origin of the levator must first be disinserted. The annulus must then be dissected from the dura covering the optic nerve, to which it firmly adheres.

After the origin of the rectus muscles within the annulus of Zinn, about 8 mm anterior to the optic strut, the rectus muscles separate as individual structures, while the fibrous tissue of the annulus thins and becomes continuous with the muscle sheaths. At this level, the medial and lateral rectus muscles lose most of their strong fascial connections to the adjacent periorbital.

The four rectus muscles pass forward from the orbital apex, parallel to their respective orbital walls. Each muscle is 40 to 42 mm in length, excluding its tendon of insertion, 7 to 10 mm in width and about 2.5 to 4.0 mm thick at its midpoint¹. In the orbital apex, the rectus muscles lie close to their respective bony walls, a distance generally less than 1 mm¹. In the mid-

orbit, the entire muscle cone shifts slightly medially so that the lateral rectus lies 3 to 5 mm from the lateral orbital wall, whereas the other rectus muscles are located less than 1.5 mm¹ from their respective bony walls. At the level of the ocular equator, the muscle cone becomes centered within the orbit, and the distance between the muscle insertions and the orbital walls increases to 7 to 8 mm¹.

The rectus muscles insert onto the sclera by tendons that vary in length from 3.7 mm (for the medial rectus) to 8.8 mm (for the lateral rectus muscles). At their insertions, the tendons are 9 to 11 mm in width, except for the superior rectus, which is only about 7 mm. The average distance from the anterior corneal limbus to the insertion for each muscle varies, too, for the medial rectus muscles it is 5.5 mm, for the inferior rectus 6.5 mm, for the lateral rectus 7 mm and for the superior rectus 7.5 mm. A line known as the spiral of Tillaux can be drawn through the insertions (Fig. 6).

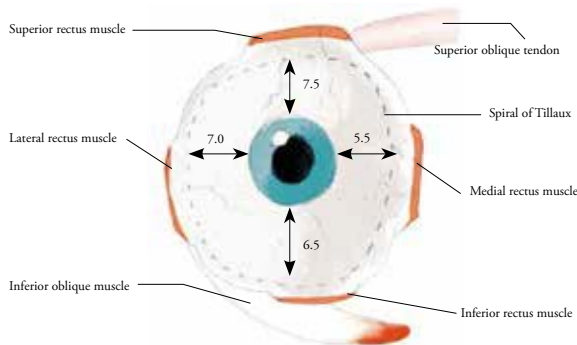


Figure 6. Spiral of Tillaux.

The rectus muscles are encased in a thin, fibrous sheath that represents an anterior connective tissue extension of the annulus of Zinn. The sheaths are interconnected circumferentially by fascial sheets, which form the intermuscular septum, more evident posteriorly. A complex system of fine connective tissue septa also extends between the individual muscles, the intermuscular septum, the optic nerve, Tenon's capsule and periorbita (Fig. 7). At the posterior surface of the globe, the rectus muscles pierce the posterior portion of Tenon's capsule.

The **superior oblique muscle** originates from the lesser wing of the sphenoid bone by a short tendon immediately above and medial to the annulus of Zinn. About 12 to 15 mm behind the orbital rim, the muscle fibers become rounded tendon. The muscles and the tendon are supported by fascial septa attached to the adjacent orbital wall.

Just behind the superomedial orbital rim, the tendon passes through the trochlea which is a 4x6 mm¹ saddle-shaped cartilaginous structure attached to the periosteum of the frontal bone. After passing through

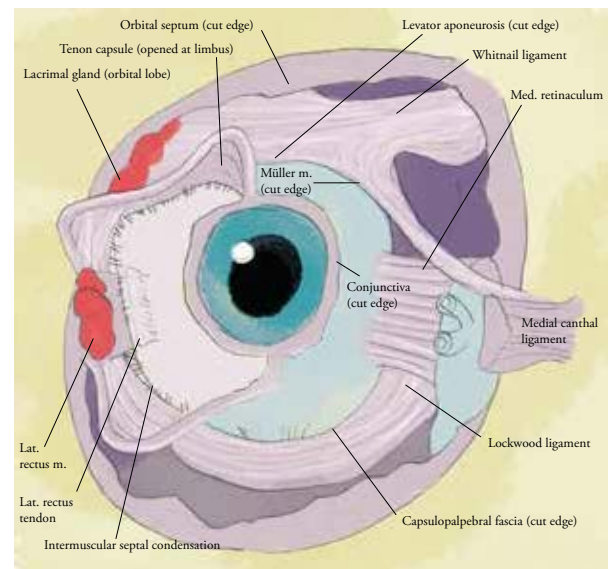


Figure 7. Tenon's capsule.

the trochlea, the tendon turns posterolaterally and travels towards the globe within Tenon's capsule for a distance of 8 mm. It pierces Tenon's capsule 3 to 4 mm nasal to the superior rectus muscle. The tendon then passes beneath the superior rectus and inserts onto the sclera near the superotemporal vortex vein, approximately 6.5 mm from the exit of the optic nerve.

During surgery of the roof of the orbit, the trochlea is easily separated from the bone by careful elevation of the periosteum. To maintain normal function postoperatively, it is important to reposition the trochlea by meticulously reapproximating the periosteum over the frontal bone.

The **inferior oblique muscle** arises from the periosteum in a shallow depression on the maxillary bone, 1.5 mm lateral to the entrance of the bony lacrimal canal and less than 1 mm behind the orbital rim¹. The site of the muscle origin is about 4 mm in horizontal width by 2.5 mm anteroposteriorly¹. The origin may easily be injured during extraperiosteal dissections along the orbital floor and medial wall for blow-out fracture repair, and during orbital decompression procedures. It is important to remain behind the posterior lacrimal crest during such operations.

The inferior oblique muscle courses posteriorly and penetrates the Tenon's capsule on the medial side of the inferior rectus muscles in a short distance from its origin. Its total length is 37 mm¹. As the inferior oblique passes beneath the inferior rectus muscles, the two individual fascial sheaths become firmly fused to each other and to Tenon's capsule, and form part of Lockwood's inferior ligament of the orbit. The inferior oblique muscle continues posterolaterally and inserts without a tendon into the posterior sclera

3. Surgical Anatomy and Clinical Examination of the Orbit

over the macula. The insertion measures about 10 mm in width and about 16 mm behind the lateral corneal limbus; it is tilted so that the anterior border lies 1 to 2 mm lower than the posterior border, with the latter being 5 to 6 mm from the exit of the optic nerve¹.

The **levator palpebrae superioris muscle** is a retractor of the upper eyelid. Embryologically it differentiates from the superior rectus muscle. It originates from the lesser wing of the sphenoid bone and the annulus of Zinn, where it blends with fibers of the superior rectus muscle above the optic canal. It continues in close approximation with the superior rectus muscle. About 10 mm behind the orbital septum¹, it passes into a thin membranous expansion, the levator aponeurosis, which spreads out to insert into the upper eyelid. Fine fascial septa interconnect the levator and the superior rectus muscles sheaths. During major levator muscle resection procedures for ptosis, these fascial attachments must be divided to prevent downward traction on the superior rectus through these fascial slips. Also, major vertical superior rectus muscle resections or recessions may alter the position of the eyelid because of these septa. In Graves' orbitopathy it is important to correct any vertical strabismus before performing ptosis surgery.

The orbital nerves

The functional groups of the orbital nerves are the optic nerve, the motor nerves to the extraocular muscles, iris and ciliary body, the sensory branches of the trigeminal nerve, and the autonomic nervous system.

The **optic nerve** (Fig. 1), in the adult, is 50 mm in length from the optic disc to the chiasm. Within the orbit the nerve is invested with pia, arachnoid and dural sheaths. The subarachnoid space is continuous from the middle cranial fossa, along the nerve, into the posterior sclera. This relationship may result in optic nerve compression and papilledema from increased intracranial cerebrospinal fluid pressure.

There are four anatomically important portions of the optic nerve: the intraocular, the intraorbital, intracanalicular and the intracranial.

The intraocular portion lies within the limits of the posterior sclera, in the lamina cribosa, and is approximately 1 mm in length and 1.5 to 2 mm in diameter.

Immediately behind the sclera, the intraorbital portion of the nerve axons become myelinated by oligodendrocytes and surrounded by pia, arachnoid and dura mater, which causes the nerve to enlarge to 3 to 4 mm in diameter. It has clinical significance in the treatment of choroidal malignant melanomas

closer than 1.5 to 2 mm to the optic disc. They cannot be reliably treated with an episcleral plaque because the thickening of the nerve, as it exits the sclera, precludes placement of any plaque closer than 1 mm to the edges of the intraocular optic disc. The orbital length of the nerve is 25 to 30 mm¹, and it describes an S-shaped path from the globe downward and then upward to the optic canal. This redundancy allows ocular motility without stretching the nerve. It also allows a considerable amount of axial proptosis without functional compromise. The posterior ciliary arteries and nerves run along the orbital portion of the optic nerve.

The intracanalicular portion of the nerve is 5 to 6 mm in length¹. The ophthalmic artery also passes through the optic canal, inferior and slightly lateral to the nerve and separated from it by dural fibers. It is vulnerable to compression from small mass lesions, such as optic sheath meningiomas or ophthalmic artery aneurysms. Because of the fusion of the dura to the periosteum at the superomedial canal wall, this portion is also vulnerable to contusion injury. With blunt trauma, the nerve may slide within its sheaths; which can result in shearing of the pial vessels supplying the nerve. Also, indirect transmission of mechanical forces by the bones, may result in contusion and edema of the nerve with compression and occasionally optic ischemic neuropathy.

The intracranial segment is about 10 mm long and extends from the intracranial opening of the optic canal to the optic chiasm and passes above the cavernous sinus.

The afferent limb of the pupillary reflex to light passes through the optic nerve, it hemidecussates at the chiasm and continues in the optic tracts. Just before the lateral geniculate bodies, these fibers branch off and go to synapse in the pretectal subnuclei of the mesencephalon. From here, interneurons pass to the visceral (Edinger-Westphal) nuclei of the oculomotor complex. The efferent limb consists of parasympathetic fibers that project from the Edinger-Westphal nuclei to the iris sphincter muscle via the oculomotor nerve, ciliary ganglion and short ciliary nerves.

The **oculomotor nerve** (III cranial nerve) carries somatic motor fibers to the medial, superior and inferior rectus, the inferior oblique muscle, and to the levator palpebrae superioris muscle. It also carries parasympathetic fibers to the intrinsic muscles of the eye and sensory neurons from proprioceptive receptors in the extraocular muscles it innervates. The oculomotor nucleus is in the midbrain, just ventral to the aqueduct of Sylvius. Subnuclei of the inferior and medial rectus and inferior oblique muscles innervate muscles on the ipsilateral side. The superior rectus

subnuclei fascicular fibers cross the midline, passing through the subnucleus on the opposite side to join with axons from other oculomotor subnuclei on that side. The motor cells that supply the levator muscle of both sides lie in a single subnucleus in the dorsal midline. In the cavernous sinus, pupillomotor fibers maintain a superomedial position, where they are susceptible to early compression by aneurysms of the posterior communicating artery. It divides into a superior and an inferior division in the anterior cavernous sinus or in the orbit. The superior orbital fissure passes through the oculomotor foramen of the annulus of Zinn. The superior division supplies motor neurons to the superior rectus and the levator muscles. The larger inferior division divides into three or more branches as it enters the intraconal space. One branch follows an upward and forward course and joins the ciliary ganglion inferolateral to the optic nerve.

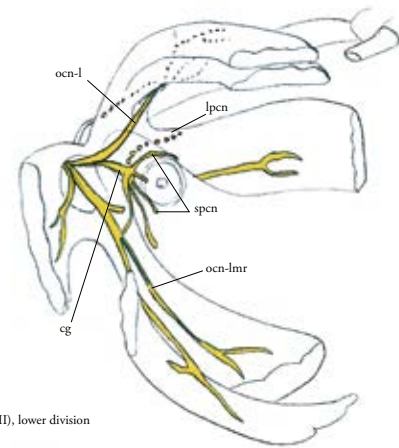
Nuclear lesions may result in unilateral third nerve palsy with contralateral superior rectus weakness and either no ptosis or bilateral ptosis. Complete dysfunction of the third nerve results in a downward and outward deviation of the globe, as well as ipsilateral upper eyelid ptosis. The pupil is dilated and does not react to light or accommodation. Lesions located in the cavernous sinus tend to result in partial third nerve palsies with sparing of pupillary function.

The **ciliary ganglion** (Fig. 8) is a small, irregular structure measuring 2 mm horizontally by 1 mm vertically. It is located in the loose fatty tissue at the orbital apex, 10 mm anterior to the medial end of the superior orbital fissure. The ganglion lies between the optic nerve and lateral rectus muscle. The following fibers pass through it: 1. preganglionic parasympathetic fibers from the inferior division of the oculomotor nerve that synapse with postganglionic fibers; 2. sensory fibers from the eye, without synapse, exit via the small root to join the nasociliary nerve; 3. sympathetic fibers en route to the choroidal vasculature (the sympathetic fibers to the dilator muscle of the iris travel with or within the nasociliary nerve, bypass the ciliary ganglion, and reach the eye through the long posterior ciliary nerves).

The ganglion gives rise to the short posterior ciliary nerves (parasympathetic fibers), that penetrate the posterior sclera adjacent to the optic nerve and innervate the ciliary muscle and the pupillary sphincter muscle of the iris.

Insults to post ganglionic parasympathetic fibers within the ciliary ganglion or short posterior ciliary nerves may cause isolated internal ophthalmoplegia, known as tonic pupil.

The **trochlear nerve** (IV cranial nerve) carries somatic



KEY:
ocn-lmr - oculomotor nerve (III), lower division to medial rectus muscle
spcn - short posterior ciliary nerves
ocn-l - oculomotor nerve (III), upper division to levator palpebrae and superior rectus muscles
cg - ciliary ganglion
lpcn - long posterior ciliary nerves

Figure 8. Ciliary ganglion.

motor fibers to the superior oblique muscle and originates in the trochlear nucleus in the midbrain at the level of the inferior colliculus. They pass dorsally to decussate and exit on the dorsal surface. The trochlear nerve runs ventrally around the cerebral peduncle, enters the cavernous sinus (Fig. 9) inferior to the oculomotor nerve, and runs superiorly to enter the superior orbital fissure above the annulus of Zinn. In the orbit it crosses over the origin of the superior rectus muscles, runs medially between the orbital roof and the levator palpebrae superioris muscle, and continues to the lateral surface of the superior oblique muscle. As it has a long intracranial course and part of its orbital extent lies adjacent to the bony orbital wall it is predisposed to injury from blunt head trauma.

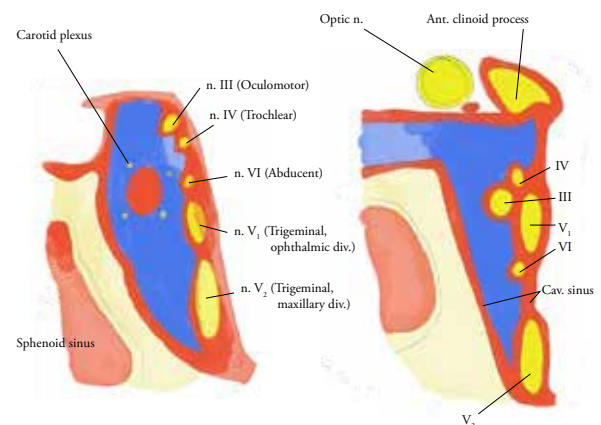


Figure 9. Cavernous sinus.

The **abducens nerve** (VI cranial nerve) carries somatic motor fibers to the lateral rectus muscle. These neurons arise in the pons, immediately ventral to the floor of the fourth ventricle. They emerge near the midline in the sulcus between the

3. Surgical Anatomy and Clinical Examination of the Orbit

pons and medulla oblongata. They ascend through the subarachnoid space along the clivus, in close proximity, thus compressive lesions in this region can result in bilateral sixth nerve palsies without associated neurologic deficits. The nerve then bends over the petrous apex and passes through Dorello's canal (here, the nerve can be affected by chronic mastoiditis) and enters the cavernous sinus. At this point it bends laterally around the intracavernous carotid artery (therefore it is usually the first nerve to be affected by an intracavernous carotid aneurysm) within the body of the sinus, unlike the oculomotor and trochlear nerves that lie in the lateral wall of the sinus. Enters the orbit through the superior orbital fissure and the oculomotor foramen of the annulus of Zinn. It follows a lateral course and penetrates the sheath of the lateral rectus shortly after.

The abducens nerve is predisposed to injury from head trauma because of its course along the base of the skull and its abrupt angulation over the petrous ridge.

The **trigeminal nerve** (V cranial nerve) consists of a small motor component and a larger sensory component. The sensory component has three main divisions: the ophthalmic (V1), maxillary (V2) and mandibular (V3). The ophthalmic and the maxillary divisions arise from Gasserian ganglion and pass over the apex of the petrous portion of the temporal bone, continuing forward along the lateral wall of the cavernous sinus (Fig. 9) before entering the orbit through the superior orbital fissure, above the annulus of Zinn (Fig. 4). The ophthalmic division (Fig. 10) splits into three branches: 1. the lacrimal, 2. frontal (that divides into the supraorbital and supratrochlear nerves), and 3. nasociliary.

The lacrimal nerve courses anteriorly in the extraconal space and enters the lacrimal gland.

The frontal nerve passes forward and medially along the midorbital roof between the levator muscle and the periorbita (in close association with the trochlear nerve). About halfway between the orbital apex and the rim it divides into two branches: the supraorbital nerve, and supratrochlear nerve. The supraorbital nerve exits the orbit at the supraorbital notch with the supraorbital artery and ascends in the submuscular plane of the orbicularis and frontalis muscles. The medial branches penetrate the muscle just below the brow, whereas those more lateral one penetrate higher. It transmits sensory fibers from the forehead, conjunctiva and skin of the central two thirds of the upper eyelid. In direct brow lifts, excision of tissue just above the brow should leave the deeper frontalis muscles fibers behind in the medial forehead to prevent injury to the supraorbital branches. More laterally, the dissection can be deeper,

to the submuscular plane. The supratrochlear nerve passes above the trochlea, pierces the orbital septum at the superomedial orbital rim and ascends to the central forehead under and through the corrugator muscle. It receives sensory information from the lower portion of the forehead and the medial one-third of the upper eyelid.

The nasociliary nerve gives off a sensory branch to the ciliary ganglion and anteriorly it gives off two to three long ciliary nerves that penetrate the sclera adjacent to the optic nerve. It continues medially and gives off one or more posterior and anterior ethmoidal branches, and it ends as the infratrochlear nerve. It pierces the orbital septum above the medial canthal tendon and receives input from the medial portion of the eyelids, the medial conjunctiva, the caruncle, the lacrimal sac, and the side of the nose.

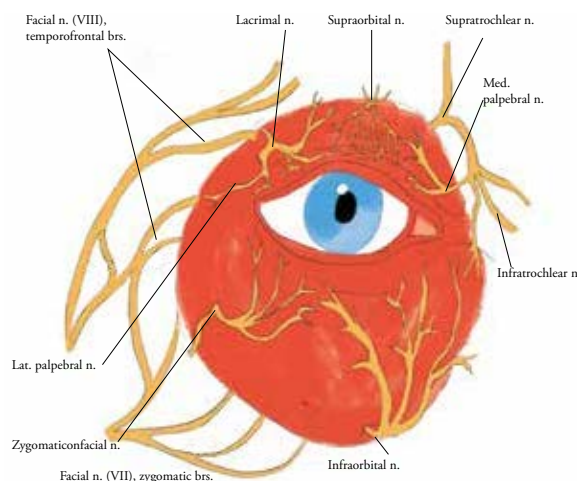


Figure 10. Sensory nerves.

The **efferent sympathetic innervation** of the eye and orbit is thought to arise within hypothalamus. First-order neurons descend uncrossed in the brain stem to synapse in the spinal cord. Second-order neurons leave the spinal cord with the last cervical to the second thoracic spinal nerves and enter the paravertebral sympathetic chain. They synapse in the superior cervical ganglion. Some of the third-order neurons (postganglionic neurons) extend along the external carotid artery branches and are responsible for facial vasodilatation and sweating, others pass intracranially as a plexus that follows the internal carotid artery to the Gasserian ganglion and cavernous sinus. The exact relationships of the sympathetic pathway within the sinus remain controversial. Sympathetic fibers pass the ciliary ganglion without synapsing and enter the short ciliary nerves, through which they reach the globe to provide vasoconstrictor stimulation to uveal blood vessels. Other sympathetic fibers bypass the ciliary

ganglion, leave the nasociliary nerve via the long posterior ciliary nerves, and penetrate the sclera to supply the dilator muscle of the iris.

The **facial nerve** supplies motor fibers to the eyelid protractors through its temporal and zygomatic branches and parasympathetic fibers to the lacrimal gland. The nucleus is located in the pons and can be divided into an upper segment that supplies the frontalis muscle, the superior portion of the orbicularis muscle, and the corrugator muscle, and a lower segment that supplies the other muscles of facial expression. The upper segment receives both crossed and uncrossed fibers and those in the lower segment are completely crossed. Supranuclear lesions result in paralysis of the opposite lower facial muscles with sparing of the upper face. The nerve exits the brain stem at the cerebellopontine angle, in close contact with the anterior inferior cerebellar artery (this relationship appears to play a role in the etiology of hemifacial spasm by vascular compression of the nerve resulting from aging). The motor branch exits the braincase at the stylomastoid foramen, ascends to the parotid gland, passes through it and divides in two. The upper temporofacial division usually subdivides into the temporal and zygomatic branches that supply the frontalis and orbicularis muscles along their deep surfaces. The temporal branch runs in the submuscular plane along a line from just below the tragus of the ear to a point 1.0 to 1.5 cm above the lateral aspect of the superior rim¹. Where it leaves the parotid gland it lies deep to the temporoparietal fascia layer/superficial muscular aponeurotic system (SMAS). As it crosses the zygomatic arch, it becomes slightly more superficial as it is invested by the SMAS, along with the superficial temporal artery. From the parotid to the lateral brow, the temporal branches follow a curved trajectory or a straighter trajectory lying closer to the lateral canthus. In such cases they can be injured during lower eyelid reconstruction using a Tenzel or Mustarde rotational flap.

As it approaches the lateral orbit it divides into three branches. The posterior branch innervates the anterior auricular and temporoparietal muscles. The anterior and middle branches frequently have anastomotic connections between them; they innervate the frontalis and the upper portion of the orbicularis muscles and penetrate the muscle on its posterior surface. These terminal branches are cut during an upper eyelid crease incision. This may explain the occurrence of a weak blink and temporary lagophthalmos.

Between the temporoparietal fascia and the deeper temporal fascia is a loose areolar layer. This is avascular, i.e. it does not contain vessels or nerves. Dissections in the temporal region, as for brow lifting, should be confined

to this plane. However, for extensive myocutaneous rotation procedures in which the incision curves upward and around the temporal region, the dissection plane should remain superficial to the temporoparietal fascia and within the subcutaneous fat to avoid cutting the temporal and zygomatic nerves.

The zygomatic branch crosses the zygomatic arch deep in the subcutaneous fat until 5 cm distal to the parotid gland. Here it becomes more superficial to innervate the lower portion of the orbicularis muscle.

Arterial supply to the orbit (Fig. 11)

The vascular supply to the orbit derives primarily from the internal carotid artery. After entering the cranium the artery runs in the cavernous sinus with the abducens nerve along its lateral side (Fig. 9). Here it is surrounded by sympathetic filaments derived from the superior cervical ganglion. Within the sinus it gives off several small branches. They are important because of their potential involvement in carotid-cavernous fistulas, and in aneurysm formation. In the anterior cavernous sinus the carotid artery perforates the dura and gives off the ophthalmic artery. The ophthalmic artery enters the optic canal with the optic nerve and emerges at the inferolateral portion of the orbital optic foramen. The artery can be divided into four anatomic portions in the orbit, and it exits inferior to the trochlea at the supramedial orbital rim. There is no single branching sequence that can be considered "normal". The branches are considered in topographic groups. **Branches to ocular structures** include the central retinal artery, posterior ciliary arteries (15 to 20 short posterior ciliary arteries that enter the globe near the optic nerve, more on the lateral side of the nerve, and supply the optic disc and the choroid, and 2 long posterior ciliary arteries that extend forward within the choroid to supply the ciliary muscles and the iris), small collateral vessels to the optic nerve.

Branches to orbital structures include the lacrimal artery (gives off the zygomaticotemporal and zygomaticofacial arteries that penetrate the lateral orbital wall, and the terminal branch penetrates the orbital septum and divides to form the superior and inferior lateral palpebral arteries that form the eyelid arterial arcades), branches to the extraocular and levator muscles (2 anterior ciliary arteries associated with each of the rectus muscles, except for the lateral rectus, which usually has only one), branches to the periosteum and orbital fat. **Branches to extraorbital sites** are the ethmoidal, supraorbital, supratrochlear, and dorsal nasal arteries (passes between the trochlea and the medial canthal tendon, and gives rise to the medial superior and inferior palpebral arteries, which enter the eyelid above and below the medial canthal

3. Surgical Anatomy and Clinical Examination of the Orbit

tendon, and anastomose with the lateral palpebral arteries to form the arterial arcades).

In the upper eyelid a marginal arcade runs within or just anterior to the tarsal plate about 2 to 3 mm from the lid margin. A peripheral arcade, appearing as one or more fine serpentine vessels, is located along the surface of Muller's muscle at the superior border of the tarsus. In the lower eyelid, usually only the marginal arcade is present and it is located 2 mm from the lid margin.

The external carotid artery also contributes to the vascularization of the orbit. The angular artery, a branch of the external maxillary artery, anastomoses with branches of the dorsal nasal and infraorbital arteries at the medial canthus. The infraorbital branch arises in the pterygopalatine fossa and enters in the orbit by the inferior orbital fissure.

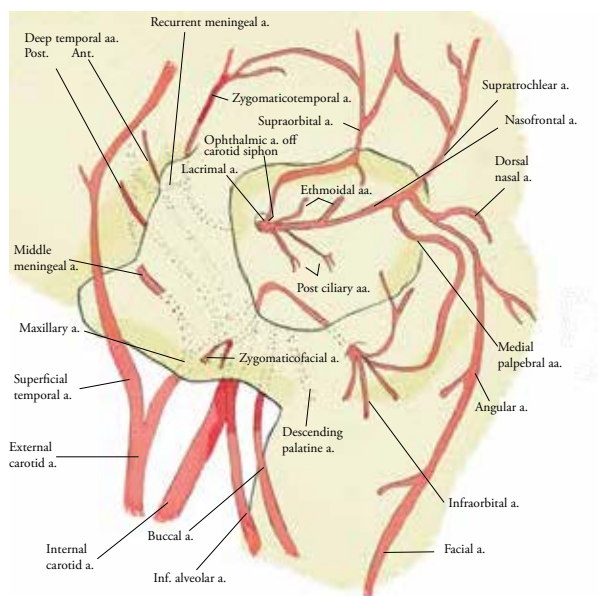


Figure 11. Orbital arteries.

The venous system of the orbit (Fig. 12)

The orbital veins do not contain valves, and blood flow within them depends largely on local pressure gradients. Their course does not generally run parallel to the arteries, as in other parts of the body, and in the posterior third of the orbit the veins are situated peripherally, in contrast with the arterial system in the apex.

The orbital venous system is composed of two major vessels: the ophthalmic veins (superior and inferior), and the angular vein. The drainage is mostly backward to the cavernous sinus and to a lesser extent to the pterygoid plexus and the facial venous system.

The superior orbital vein runs posteriorly, medial and inferior to the superior oblique muscle, and at the mid-orbit, just behind the globe, moves laterally between the optic nerve and the superior rectus muscle, at its lateral edge. It leaves the orbit by the superior orbital

fissure to enter to the cavernous sinus.

The inferior orbital vein runs backward along the lateral border of the inferior rectus muscle, gives off a branch that anastomoses with the infraorbital vein and passes through the inferior orbital fissure to join the pterygoid venous plexus. The main trunk of the inferior orbital vein drains into the cavernous sinus directly or by the superior ophthalmic vein.

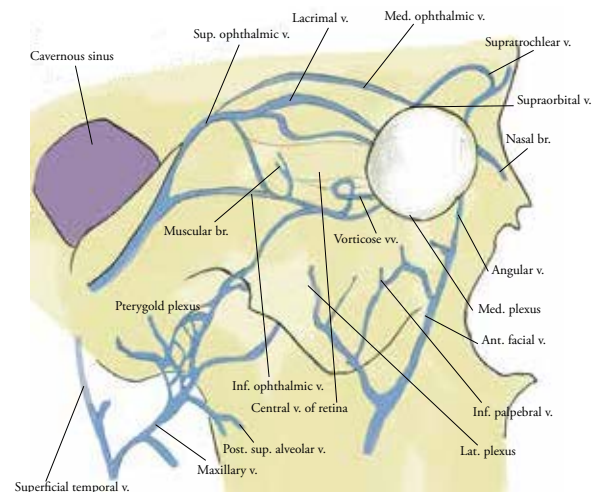


Figure 12. Orbital veins.

The lymphatic system

Drainage from the lateral two-thirds of the upper eyelid, the lateral one-third of the lower eyelid, and the lateral half of the conjunctiva is into the preauricular nodes. The medial one third of the upper eyelid, the medial two thirds of the lower eyelid, and the medial half of the conjunctiva drain into the submandibular nodes and, ultimately, to the anterior and deep cervical nodes.

The human orbit is thought to be devoid of lymphatic vessels and nodes.

Orbital fat (Fig. 13)

Orbital fat fills the space surrounding the eye, extraocular muscles, nerves, blood vessels, and the lacrimal gland, and has vaguely defined anatomic compartments: a central intraconal compartment between the four rectus muscles, a peripheral extraconal compartment between the bony orbital walls and the rectus muscles, and an anterior peribulbar compartment. Connective tissue septa surround individual fat lobules, and blood vessels and nerve fibers run within these septal membranes. In the intraconal compartment near the orbital apex these lobules are larger and surrounded by thin, weakly developed fibrous membranes with little collagen and no elastin. Anteriorly it is bounded centrally by Tenon's capsule, and peripherally by the rectus muscles and the thin intermuscular septa between them.

Anterior to the muscle insertions, a thin ring of peribulbar fat lobules separates Tenon's capsule from the orbital wall.

An anterior extension of superior extraconal fat passes down into the upper eyelid between the levator aponeurosis and the orbital septum forming the preaponeurotic fat pocket. The preaponeurotic fat in the eyelids appears more yellow than the white fat that fills the rest of the orbit and the nasal eyelid pocket.

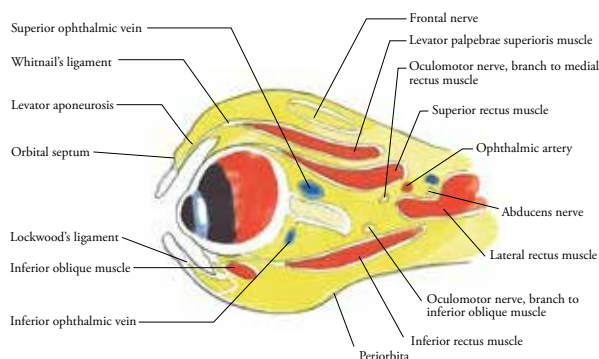


Figure 13. Orbital fat.

Periorbital and septa (Fig. 14)

The extraperiosteal space is commonly approached surgically. The periorbital is firmly adherent to the bone at the orbital rim, in the area of a fibrous condensation that gives rise to the orbital septum known as the arcus marginalis. When dissecting the periorbital at the rim care must be taken not to tear the periorbital and spill fat. Posteriorly to the arcus marginalis and the anterior concavity of the bony contour, the extraperiosteal plane is fairly easily maintained by careful blunt dissection except for the adhesions at the lateral tubercle, orbital fissures, sutures, and penetrating neurovascular foramina.

Within the orbit a complex reticular system of septa divides orbital fat into distinct pockets. The veins of the orbit lie within the septal network whereas the arteries do not. In the middle and posterior orbit, these septa are more diaphanous so that there is no distinct intermuscular septum separating the intraconal from the extraconal fat. Anteriorly these septa are well defined and form the anterior fascial system, which is primarily related to support the globe, Tenon's capsule, lacrimal gland, superior oblique tendon, and the eyelids.

It consists of a complex arrangement of well-developed fascial condensations and ligaments, and a diffuse system of fibrous septa. These structures include the medial and lateral "check ligaments", Lockwood's inferior ligament, Whitnall's superior suspensory ligament, the lacrimal ligaments, the suspensory ligament of the conjunctival fornix, the intermuscular septa, and the anterior orbital septal suspensory systems.

Disruption or scarring of septa occurring after trauma or inflammation can account for various patterns of impaired ocular movements, even in the absence of direct injury or scarring of the extraocular muscles.

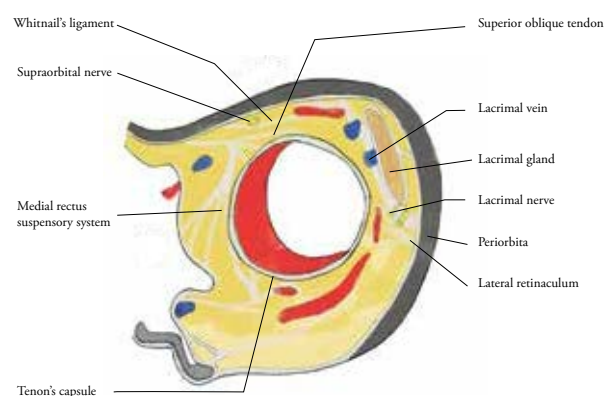


Figure 14. Orbital septa.

Tenon's capsule (Fig. 7)

Tenon's capsule is a dense elastic, fibrovascular connective tissue layer that surrounds the globe, except over the cornea, and the anterior portions of the extraocular muscles' insertions (the muscles behind the equator perforate Tenon's capsule to reach the globe). It begins anteriorly about 2 mm behind the corneal limbus, and is firmly adherent to episclera; it extends around the globe (loose adherence) to the optic nerve where it blends with fibers of the dural sheath and sclera.

Tenon's capsule separates the globe posteriorly from the intraconal orbital fat.

Orbital muscle of Muller

The orbital muscle of Muller is functionally part of the orbital connective tissue system. It forms a bridge over the inferior orbital fissure, separating the orbital contents from the pterygopalatine fossa. It is composed of smooth muscle fibers oriented roughly transverse to the inferior orbital fissure.

Bibliography

1. Dutton J. Atlas of Clinical and Surgical Orbital Anatomy. 2nd Edition. Elsevier Saunders. 2011.
2. Rootman J. Orbital surgery. A conceptual approach. 2nd Edition. Wolters Kluwer/Lippincott Williams & Wilkins. 2014.
3. Moreiras JVR, Prada MC. Orbit examination diagnosis microsurgery pathology. Highlights of Ophthalmology International. 2004.
4. Guthoff RF, Katowitz JA. Oculoplastics and Orbit. Springer. 2007.
5. Dutton JJ. Atlas of Oculoplastic and Orbital Surgery. Wolters Kluwer/Lippincott Williams & Wilkins. 2013.

4. Instruments in Ophthalmic Plastic Surgery

Ana Duarte, Antonio Augusto Velasco e Cruz

In this chapter you will find a few sets of instruments used in oculoplastic surgery, from the basic and essential material that every ophthalmologist should have in their surgery room up to the material used in more complex techniques.

Ultimately, we hope it will be easier for you to know and select the instruments for each procedure. Sutures, instruments for harvesting autogenous fascia lata, dermatomes, orbital implants and other supplementary materials are covered in other sections of this book.

1. Oculoplastic Surgery
 1. The basic instruments
 2. Cutting tools
 3. Scissors
 4. Forceps, retractors and hooks
 5. Needle holders
 6. Hemostasis
 7. Suction
2. Eyelid and Brow Surgery
3. Evisceration and Enucleation
4. Lacrimal Surgery
5. Orbital Surgery

1. OCULOPLASTIC SURGERY

1. The Basic Instruments

This is a basic set of instruments that you should have available in your practice, even if you are not an ophthalmic plastic surgeon (Fig. 1).

As you will see each instrument is available in different lengths and calibers and you should choose what suits you best for specific procedures.

2. Cutting Tools

There are three main cutting tools in oculoplastic surgery:

- No. 15 scalpel blade
- Colorado microdissection needle
- Co2 laser.

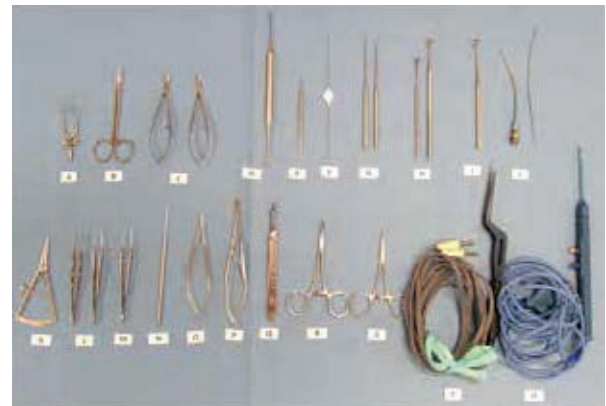

Fig. 1

- | | |
|--|---|
| A. Eye speculum | K. Measuring caliper |
| B. Curved, blunt-ended dissecting scissors | L. Forceps with teeth |
| C. Curved spring scissors (Westcott) | M. Forceps without teeth |
| D. Freer periosteum elevator | N. Muscle hook |
| E. Punctal dilator | O,P. Needle holders (Barraquer and Castroviejo) |
| F. Bowman lacrimal probe | Q. Scalpel handle with a N°15 blade |
| G. Gillies skin hooks | R,S. Small hemostatic forceps (curved and straight) |
| H. Catapult retractors | T. Bipolar cautery |
| I. Desmarres retractor | U. Unipolar cautery |
| J. Suction tube | |

Starting with the **scalpel blades** (Fig. 2), there are several types you should know.



Fig. 2 (from left to right)

No. 10 blade: it is similar to no.15 but bigger. It is not usually used on facial skin.

No. 11 blade: it has a sharp point and is ideal for curves and sharp angles.

No. 12 blade: it is a curved blade similar to a sickle, it's also not usually used on facial skin.

No. 15 blade: this is the scalpel blade most used for eyelid and facial surgery; you will use it often.

Hold the scalpel with a pencil grip, using the thumb, index and middle finger. Start cutting with the tip and then lay it down to use the curved part. Adjust the movement so you can control how deep is the incision.

Another useful tool is the **Colorado® microdissection needle**, a monopolar electrode with an ultra-sharp tungsten tip that allows a precise cut and cauterization of the skin (Fig. 3). The tissue is vaporized by the electric current that reaches the tip, and when used in tissues behind the orbital septum that current is carried into the orbit, causing pain in patients under local anesthesia. This needle can be used with a foot pedal or a hand switch. Several other Colorado-type monopolar electrodes (Fig. 4) are often used in clinical practice.



Fig. 3 In <http://www.cormedica.fr/medias/produits/medium/da-021235.jpg>



Fig. 4



Fig. 5

Finally, the **CO2 laser system** is a new technology that can also be used for cutting skin with an excellent hemostasis (Fig. 5). The high absorption of this infrared laser by tissue water makes it an excellent tool in surgery. However, some especial precautions should be taken when used, and the patient and surgical team need to wear additional protection (metal corneal shields and protective goggles).

3. Scissors

Scissors can be used as shearing cutters for cutting tissues and sutures and also as push cutters, to spread open tissue planes. There are a few hundred different types, and you can choose them according to the

length, tip sharpness, caliber, blade design, and cutting motion.

Concerning the **length**, your choice will depend on how deep the wound is. You will usually work with instruments that are also used in ocular surgery (4 inches long) and plastic surgery (6 inches long). The **tip** can be blunt (Fig. 6, left) or sharp (Fig. 6, right), usually used for cutting and dissection, respectively. The choice of the **caliber** depends on how tough the tissue is, and there is no specific rule. For example, in the thin eyelid skin it is advisable to use Westcott scissors, which are more delicate. Also, depending on the **blade design** you can find straight (Fig. 7, top) or curved (Fig. 7, bottom) scissors. The first are used mainly for cutting sutures and tissues in a straight line and the second are ideal for tissue dissection (the curve lifts the tissue as you cut between the planes) and to cut in curved lines, using the curve of the blades.

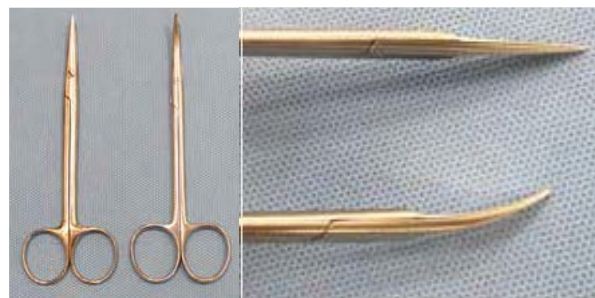

Fig. 6

Fig. 7

The tip size and not the length of the scissor is the most important characteristic. There are many long delicate scissors (for example Yasargil scissors, sometimes used for orbit surgery).

Finally, you find scissors with two kinds of **cutting motion**: the iris or ring scissors (like Mayo and Stevens scissors), which open and close with opposite hand motions, and spring scissors (Westcott scissors), which have a spring mechanism that make them very useful when you are working on delicate and fine tissues. Steven and Mayo scissors are both ring scissors but the first has thinner, shorter, curved, blunt-tipped blades that make them ideal for eyelid surgery.

The way you hold the scissors is important for the precision of the cut. Westcott scissors should be held like a pencil, as a finger tool (Fig. 8), and ring scissors are held using a three-point fixation, with your index finger providing additional support.

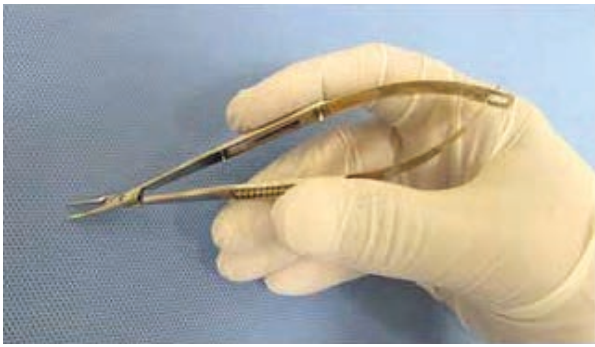


Fig. 8

4. Forceps, Retractors And Hooks

Forceps

This is an essential tool in every surgery room and differs in **length, caliber and tip** (which can have teeth, Fig. 9 left, or be smooth, Fig. 9 right). Generally, you should use forceps with teeth because smooth tips can crush the tissues when you hold them. There are some variations in the smooth-type forceps (small serrations and diamond dusting) that can mitigate this problem; however, teeth still offer a better grip.



Fig. 9

Retractors

We can consider three types of retractors: **hand-held, sutures and self-retaining retractors**. Examples of the first group (**hand-held**) are the Desmarres lid retractor, which you are certainly familiar with (Fig. 11), malleable retractors (Fig. 10 A), which are flexible and can be bent, the Farabeuf (Fig. 10 B) and the Senn Miller retractors (Fig. 10 C), all of them very useful in orbital surgery. Also, you can use **sutures** as retractors or **self-retaining retractors** (like the Jaffe eyelid speculum) which is static and used in eyelid surgery by some surgeons.

Skin Hooks

Finally, skin hooks can also provide good exposure. The Joseph (**double-pronged**) skin hook (Fig. 11, bottom), **lacrimal rake** (Fig. 11, center) and other small **double and single-pronged** skin hooks (Fig. 11, Gillies hook, top) can be very useful for eyelid and lacrimal surgery



Fig. 10



Fig. 11

5. Needle Holders

The needle holders most often used by oculoplastic surgeons are those with **spring handles** (the Castroviejo needle holder is the most popular) and those with **ring handles**. The first type is a finger tool, perfect when you are working with needles smaller than 5-0, and it should be held like a pencil (Fig. 12, top). Needle holders with a ring handle, like the Webster needle holder, are bigger and held with a three-point fixation. They are mostly used with needle sizes 4-0 and larger (Fig. 12, bottom).

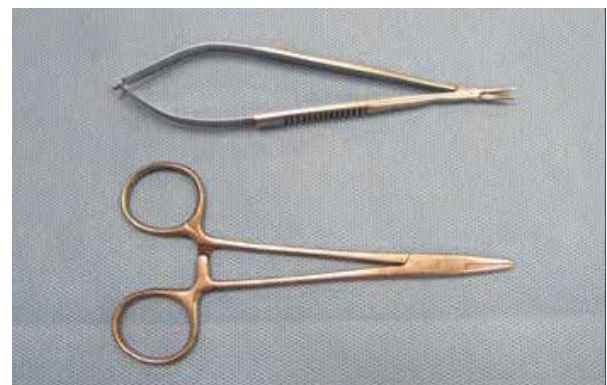

Fig. 12

6. Hemostasis

Effective hemostasis is crucial for safe surgery. You need to pay attention to several aspects, even before the surgery.

Before surgery- always ask the patient what drugs they are taking and why. Don't stop anti-aggregating

4. Instruments in Ophthalmic Plastic Surgery

drugs or anticoagulants without knowing if there is any risk. Contact an anesthesiologist or the patient's physician to be sure that these drugs can be stopped and need to be replaced by a low-molecular-weight heparin (LMWH). Warfarin should be stopped 5 days before surgery and anti-aggregation (like aspirin) should be stopped 10 to 14 days before. Nonsteroidal anti-inflammatory medications should also be taken into account and stopped 3 days before surgery - and don't forget that some supplements, like ginkgo biloba, can affect blood clotting. Patients usually don't consider them relevant information when you ask about medication.

In the surgery room there are also a few mechanisms you can use to help control bleeding: drugs, tamponade, cautery, drains and bone wax (which can be a big help in stemming bleeding from perforating vessels of the bone).

Epinephrine- There are many advantages in its use: besides decreasing bleeding through local vasoconstriction, it also delays the anesthetic absorption, increasing its activity duration and decreasing local toxicity and volume needed. The concentrations of epinephrine commonly used are 1:50,000 and 1:100,000 (containing 0.02 mg and 0.01 mg of epinephrine per mL of the anesthetic solution). For noradrenaline, concentrations of 1:30,000 or 1:50,000 are used. Complications in normal patients occur at doses above 0.5 mg of epinephrine (50 mL of 1:100,000), and in patients with heart problems you should not use more than 0.2 mg epinephrine (20 mL of 1:100,000 and 10 mL of 1:50,000). When you are working with nasal mucosa you can use topical 0.05% oxymetazoline (Afrin) applied in a small neurosurgical cottonoid.

Cautery- There are three types of cautery: **hand-held cautery unit**, **unipolar** and **bipolar cautery**. The first has a small wire that gets hot when you press its on-off button. It can be used in small procedures (chalazion, pterygium) but is not appropriate for most oculoplastic procedures. **Unipolar cautery** is very commonly used (Fig.13). The Colorado® microdissector needle discussed earlier is a unipolar cutting and cautery unit that uses an electrical current and has a very fine point, which makes it perfect for delicate tissues. **Bipolar cautery** has a forceps type instrument (Fig.14) with a high frequency electrical current that runs from one tip to the other. It needs some type of fluid irrigation but tissues are usually wet enough to conduct the current between the tips without thermal damage to the surrounding structures.



Fig. 13



Fig. 14

Drains- The purpose of a drain is to prevent blood or other fluid build-up in a closed space. In selected cases of orbital surgery or after managing large flaps you can use active or passive suction devices. The Jackson-Pratt Drain (also called JP Drain) is an active suction device consisting of an internal drain connected to a grenade-shaped bulb via plastic tubing that can be useful after reconstructive surgery using grafts. The Penrose, on the other hand, is a very common passive drain.

Bone wax- Very useful for plugging small vessels in bone where bipolar cautery is not effective (Gelfoam®, Surgicel®, Thrombogen®). Take a small piece of this wax and just plug the source of bleeding.

7. Suction

The most used suction catheter is the **Frasier suction tube**, a metal angled catheter, (Fig. 15, left) but there are other versions, like the **Yasargil suction tube** (Fig. 15, right) and **flexible catheters**, too. Suction is an important adjuvant in surgery, it clears any fluid from the surgical site, thereby increasing its exposure, and the tube can also be used to retract tissues. When you are next to tissues that can be easily sucked into the catheter tip (like orbital fat) use a gauze pad or cottonoid over the suction tube to prevent damage to the surrounding tissues.

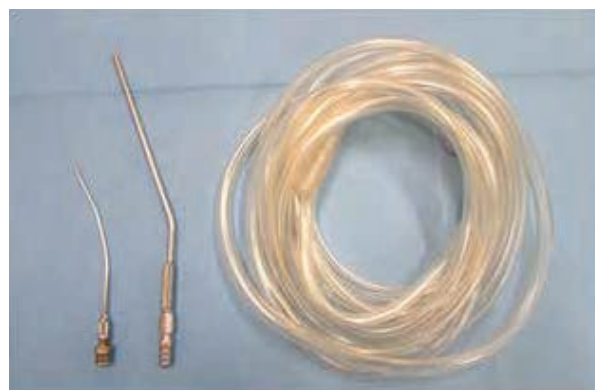

Fig. 15

2. EYELID AND BROW SURGERY

For most surgery (entropion, ectropion, ptosis, blepharoplasty, brow lift...) a basic set of instruments (Fig. 1) will be enough. However a few procedures

will need special instruments. Some examples are the Putterman clamp (Fig. 16), used for Müllers muscle-conjunctival resection ptosis procedure, the Berke ptosis clamp for levator resection (Fig. 17), the Wright fascia needle for frontalis sling surgery (Fig. 18) and the very widely used set for chalazion excision (Fig. 19).



Fig. 16 In <http://www.berktree.com/assets/images/default/bausch-&-lomb-putterman-mullers-muscle-conjunctival-by-clamp-original-each-model-c2508.jpg>



Fig. 17



Fig. 18

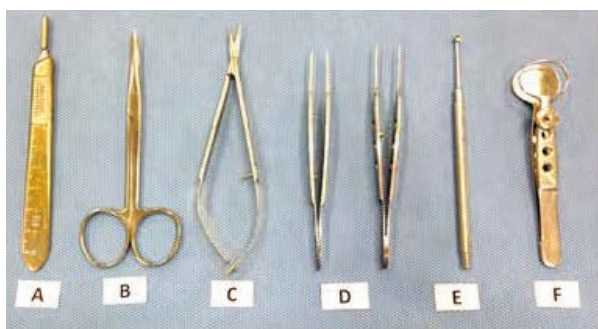

Fig. 19

- A. Scalpel blade
- B. Blunt, curved dissection scissors
- C. Westcott scissors
- D. Forceps with teeth
- E. Curette
- F. Chalazion clamp

Minimally invasive endoscopic surgery has now become a trend in various surgical fields. Oculoplastic surgery is no exception, and although the technique is often more demanding for the surgeon, with special surgical instruments being needed, the fast recovery of patients with minimal sequelae is without any doubt a major advantage. The next few years should be promising for endoscopic technology. Nowadays it is mainly used in oculoplastic surgery for dacryocystorhinostomy and forehead and facelifts. Fig. 20 displays a set of instruments for endoscopic forehead lift.

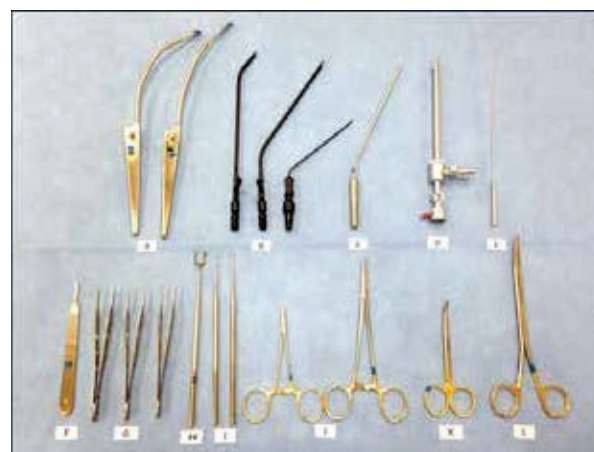


Fig. 20

- A. Endoscopic dissectors
- B. Coagulation suction tubes
- C. Suction tube
- D. Forward-oblique telescope
- E. Suture passer
- F. Scalpel blade
- G. Forceps with and without teeth
- H,I. Skin hooks (Joseph and Gillies)
- J. Needle holders with ring handles
- K. Blunt, curved small dissection scissors
- L. Metzenbaum dissection scissors

3. EVISCERATION AND ENUCLEATION

In this section we discuss the special instruments used for evisceration and enucleation. Fig. 21, below, shows an example of the instruments that you can have in your surgery room. Forceps and needle holders have already been discussed and implants will be described in other section of this book. Some surgeons also use a sphere introducer for implant placement (Fig. 22). The use of a fiber optic headlight is recommended.



Fig. 21

- A. Eye speculum
- B. Evisceration spoon (curette) – used to remove intraocular contents
- C. Westcott scissors – used for conjunctival peritomy, muscle disinsertion (enucleation) and to cut through the limbus (evisceration)
- D,E. Enucleation scissors – used to cut the optic nerve
- F. Curved, blunt-ended dissecting scissors
- G. Angled, pointed-ended scissors

4. Instruments in Ophthalmic Plastic Surgery

(Fig. 21)

H. No. 15 scalpel blade – used in evisceration to make a stab wound at the limbus and posterior cuts in the sclera to fit the implant

I. Suction tube

J. Muscle hooks

K. Forceps with teeth

L. Forceps without teeth

M. Needle holder

N,O. Small hemostatic forceps (curved and straight)

P,Q. Unipolar and/or bipolar cautery

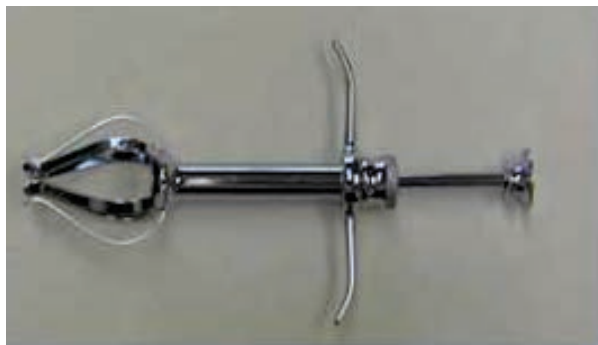

Fig. 22 In www.guldenophthalmics.com

4. LACRIMAL SURGERY

In this section we consider 4 major procedures that need special instruments: nasolacrimal duct probing and intubation; canalicular laceration; and external and endonasal dacryocystorhinostomy. Again, forceps, scissors and needle holders have already been discussed in detail. A fiber optic headlight is always advisable.

Probing and intubation of lacrimal system (Fig. 23)

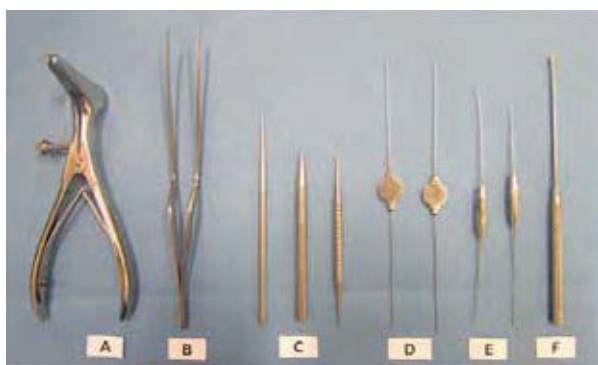


Fig. 23

A. Nasal speculum (pediatric or adult) – to visualize the inside of the nose. You can use a nasal endoscope instead.

B. Bayonet forceps – to pack the inferior turbinate with a cottonoid impregnated with oxymetazoline hydrochloride 0.05%.

C. Single-ended and double-ended lacrimal dilator.

D,E. Bowman lacrimal probes.

F. Crawford hook – used to retrieve the canalicular stent when necessary. You can also use a hemostat or a grooved director (which allows the gentler and less traumatic retrieval of the stent).

Repair of a canalicular laceration

The instruments needed depend on the extent of the injury and you will likely need a basic oculoplastic set (Fig. 1) plus other intubation instruments (see above). One possible addition is the **pigtail** probe (Fig. 24), which has 2 pigtail shaped blunt probes with suture holes in each end (for upper and lower punctum) that help to stent the canaliculus laceration.

With respect to **stents**, the choice depends on the type of injury and what is available: Mini Monoka, Crawford and Mono-Crawford, Self-Threading Monoka, etc.



Fig. 24

External Dacryocystorhinostomy, DCR (Fig. 25)

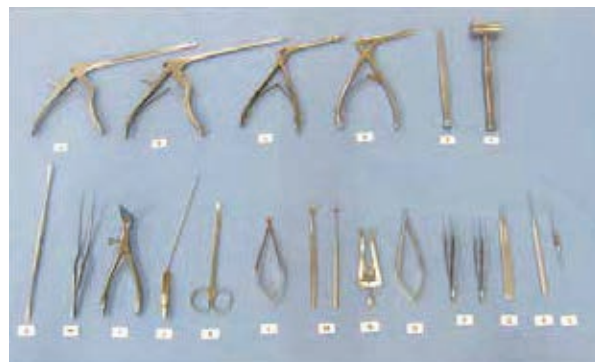

Fig. 25

A-D. Dacryorhinostomy forceps or rongeurs: A, B Kerrinson; C,D Citelli – used to enlarge the osteotomy, they come in a range of sizes that you should use consecutively to remove the bone.

E. Chisel

F. Mallet

G. Freer periosteal elevator – used to incise (sharp edge) and reflect the periosteum towards the anterior lacrimal crest, and also to break the bone when starting the osteotomy.

H. Bayonet forceps – used to pack the inferior turbinate with a cottonoid impregnated with oxymetazoline hydrochloride 0.05%.

I. Nasal speculum

J. Suction tube

K. Blunt, curved-ended dissection scissors

L. Westcott scissors

M. Catspaw retractors

N. Lacrimal sac retractor

O. Needle holder

P. Forceps with teeth

Q. Scalpel handle

R. Crawford hook, hemostat or a Tse-Anderson grooved director – used to remove the stent from the nose, when necessary. You can also use the suction tube to fit and pull the stent

S. No. 1 Bowman probe

Not shown – Monopolar and/or bipolar cautery

Endonasal Dacryocystorhinostomy

For this procedure you should be familiar with the equipment and technique and an endoscope light and video unit will be needed (Fig. 26). Some instruments are the same as those used in the external dacryocystorhinostomy procedure: Kerrinson rongeurs, used to enlarge the osteotomy; the Freer periosteal elevator; suction tube, and others (Fig. 27). Strumple-Voss nasal forceps are used to tear flaps off (as an alternative you can open the incision in the nasal and lacrimal sac mucosa with a 2.75 mm knife or a no. 66 Beaver blade).

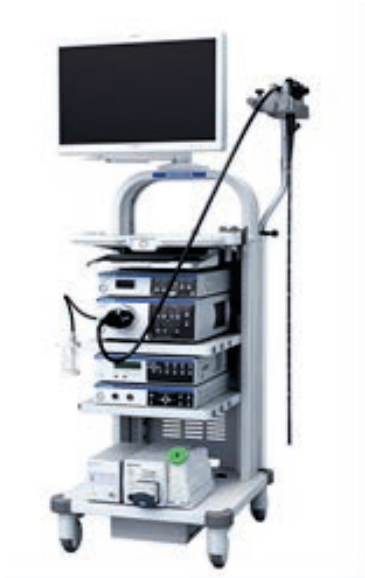

Fig. 26 In http://www.nippon.com/en/files/c00513_ph04.jpg

5. ORBITAL SURGERY

Of all the procedures we have discussed, orbital surgery is the one that requires the largest set of specialized instruments. Depending on the location and the nature of the surgery you are going to do (incisional or excisional biopsy of a lesion, with an anterior or deep location, medial or lateral to the optic nerve, with or without bone removal) the instruments you need will be different.

A fiber optic headlight (Fig. 27) and surgical loupes are highly advisable, but you can use an operating microscope instead (ideally one that can be positioned and moved in any direction within a three-dimensional space, like those used in neurosurgery).

Orbital instruments (Fig. 28)

We will not explain each procedure individually, but describe the main instruments needed for these procedures as a whole. A set of orbital decompression instruments can have more than 60 pieces.



Fig. 27

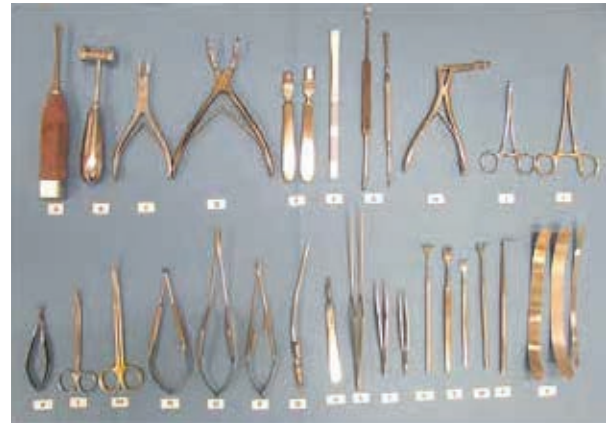

Fig. 28

- A. Chisel
- B. Mallet
- C,D. Bone rongeur
- E. Farabeuf rugines
- F. Chisel
- G. Periosteal elevators
- H. Citelli rongeur
- I,J. Hemostatic forceps
- K. Westcott scissors for anterior procedures
- L,M. Sharp and blunt, curved, dissection scissors
- N. Angled, pointed scissors (Gills-Aron-Rosa)
- O. Curved, sharp bayonet (Yasargil) scissors
- P. Needle holder
- Q. Suction tube (Frasier)
- R. Scalple handle
- S. Bayonet forceps
- T. Forceps with teeth
- U. Desmarres lid retractor
- V. Catspaw retractors
- W. Joseph skin hook
- X. Senn Miller retractor
- Y. Malleable retractors of different sizes

Not shown - Colorado microdissection needle (used outside the orbit) and bipolar cautery (used outside and inside the orbit). When using the latter, choose jeweler's tips for anterior cauterization and long bayonet tips for deep spaces (like the Fisher micro-bipolar bayonet forceps)

Forceps and scissors used for deep procedures are similar to other commonly used but have longer, bayonet-type handles (ex. Yasargil scissors).

Be careful when using orbital retractors, try to release the pressure sometimes so that blood flow is not interrupted.

4. Instruments in Ophthalmic Plastic Surgery

Other useful instruments

Special forceps and scissors -There are multiple types of small nasal forceps and scissors, with different handles for grasping deep tissues. In Fig. 29 we show the **Takahashi nasal forceps**, which can be used to remove bony fragments or to sample suspect tissue for biopsy,

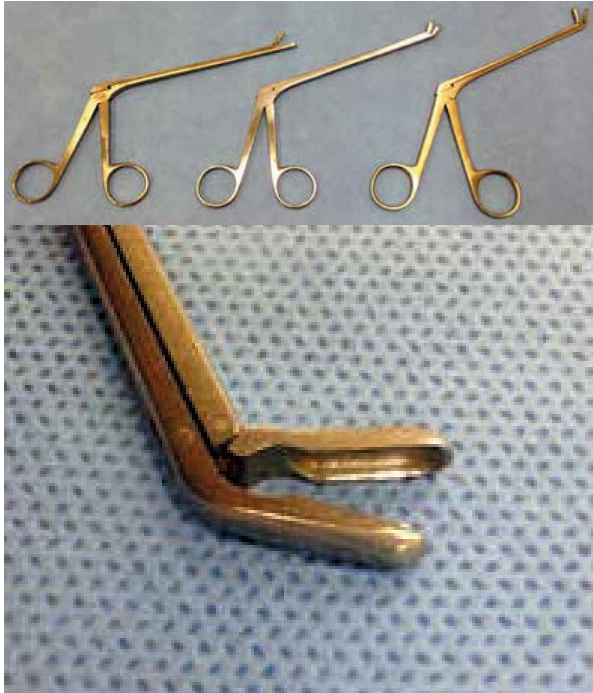

Fig. 29

Power saws and drills for bone removal. The MicroAire® System (Fig. 30), a small power instrument, can be used with an electric or pneumatic motor. It can have either reciprocating or oscillating saws, with several interchangeable head modules and a large set of blades, bits and burs for bone sculpting, cutting and drilling. The Midas Rex® Set (Fig. 31) is another pneumatically operated surgical drill system that is very useful in deep lateral wall orbital decompression.



Fig. 30



Fig. 31

Final message

For each step of each procedure there are specific instruments designed to make your job as a surgeon easier and more efficient. It is essential that besides knowing the technique you get to know your own tools.

In this chapter we have provided an overview of the instruments most often used in oculoplastic and orbital surgery. We do not expect them to be used universally as we have indicated; this is our experience and method, and we leave to the discretion of each surgeon to prepare the set of tools that best suits their own technique.

BIBLIOGRAPHY

1. Nerad, JA. Techniques in Ophthalmic Plastic Surgery. A personal tutorial. Saunders-Elsevier, 2010
2. Tse, DT. Color Atlas of oculoplastic surgery. Wolters Kluwer - Lippincott Williams and Wilkins. 2 Ed., 2013.
3. Rootman J. Orbital Surgery: A Conceptual Approach. Hardcover. 2 Ed., 2013
4. McCarthy, FM. - A clinical study of blood pressure response to epinephrine - containing local anesthetic solutions. J. Dent. Res. 36:132-141.

5. Sutures and needles in ophthalmic plastic surgery

Ricardo Dias

Sutures

A – Characteristics of materials

Configuration, capillarity, diameter, tensile strength, elasticity/plasticity, memory.

B - Characteristics of handling

Flexibility, friction coefficient, knot security, tissue reaction, tissue cutting, absorption, infection induction.

A – Characteristics of materials

A1-Configuration

Suture materials are divided into two groups: monofilament, formed by a single thread, and multifilament, formed by multiple threads (Figure 1). Monofilament threads have lower adherence to bacteria, less friction when passing through tissues, higher tensile strength for the same diameter; they fray less, but have less flexibility.

Multifilament sutures are divided in two groups: rolled and braided (Figure 1).

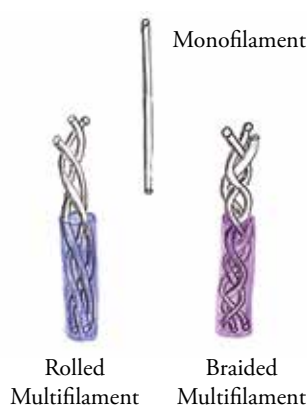

Figure 1 – Suture material types

A2-Capillarity

Capillarity is the ability to draw liquids from the immersed thread portion to the non-immersed portion (Figure 2).

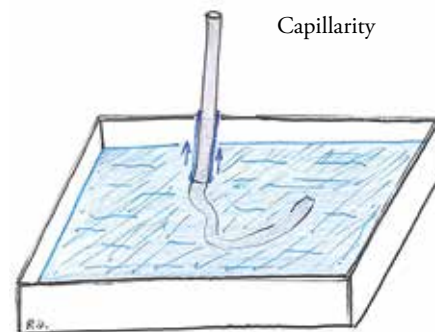


Figure 2 – Capillarity

A3-Absorption

Absorption is the ability to absorb fluid when immersed in a liquid solution. Suture materials with high capillarity and high absorption capacity are more likely to attract and retain bacteria and other microorganisms.

A4-Resistance to traction (tensile strength)

Tensile strength is the maximum force that a thread can withstand without breaking, when subjected to a sudden longitudinal force (Figure 3). It is directly proportional to the square of the thread diameter.

$$\text{Tensile strength} = d^2$$

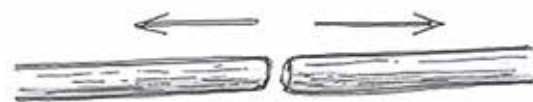

Figure 3 – Tensile strength

A5-Diameter

The smaller the thread diameter, the more zeros it has, thus a 6/0 silk is thinner than a 5/0 silk.

The diameter is the feature that indicates the ability of a specific thread to withstand a standardized tension. Each thread has a specific tensile strength (Figure 4). e.g. Polyamide 5/0 has a smaller diameter than polyglycolic acid, but they support the same weight without breaking.

5. Sutures and needles in ophthalmic plastic surgery

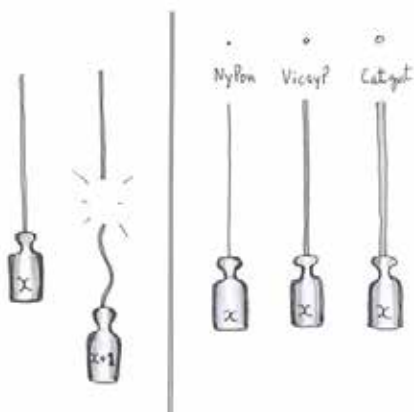


Figure 4 – A suture diameter represents its ability to resist a standardized force

A6-Elasticity and plasticity

Elasticity is the ability of a thread to deform and return to its original diameter and length, after being subjected to a longitudinal stress (Figure 5) that has increased its length and decreased its diameter (e.g. an elastic band).

Plasticity is the ability of a thread to deform and remain deformed after relaxation of a given stress (e.g. plastic bag or chewing gum) (Figure 5).

Threads with high plasticity deform and allow the deformation of knots as the wound swells, but can slacken when there is a decrease in the swelling of the wound edges.

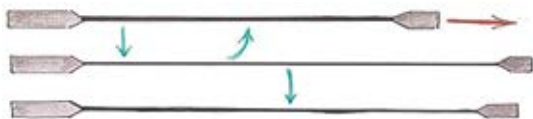


Figure 5 – Elasticity and plasticity

A7-Memory

Memory is the tendency of a material to return to its original form after suffering deformation (e.g. after tying a knot) (Figure 6).

e.g. polypropylene has a high memory (to tie safer knots a greater number of loops are needed. The knot is more likely to untie).

e.g. silk has a low memory.

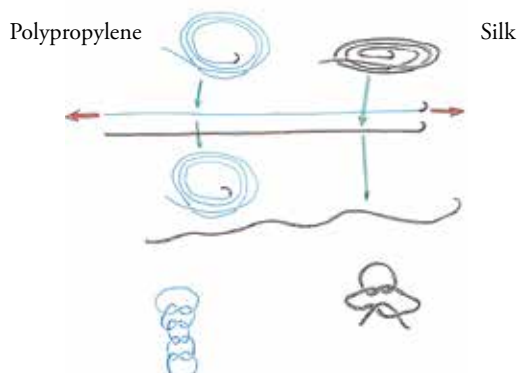


Figure 6 - Memory

B - Characteristics of handling

B1-Flexibility

Flexibility is the ease of handling a suture material (e.g. silk is more flexible than nylon, when you are tying the knot).

B2-Coefficient of friction

The coefficient of friction measures the suture's ability to slide through the tissue.

Monofilament sutures usually have a lower coefficient of friction than multifilament sutures.

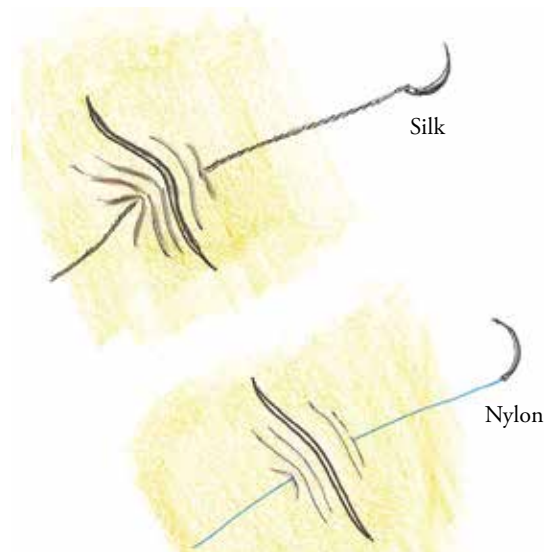


Figure 7 – Coefficient of friction

B3-Tissue reaction

Every suture material causes a foreign body reaction in the tissue. The reaction differs depending on the nature of the material and the tissue where it is introduced.

As a rule, the greater amount of material, the greater the tissue reaction!

On the whole, monofilament wires produce less tissue reaction!

When you have an intense and prolonged tissue reaction, you can expect poorer closure of the wound edges, while healing will take longer and be imperfect. In the first 4 days of suturing, the tissue is invaded by lymphocytes and monocytes.

Between the 4th and 7th days, macrophages and fibroblasts reach the tissue, and between days 7 and 21 a fibrous reaction develops.

With absorbable sutures, inflammatory reaction persists until the suture has been rejected or reabsorbed by the body.

With non-absorbable sutures, a fibrous capsule is expected to form around the suture material, with minimal inflammation.

B4-Tissue cut (saw effect)

Suture materials have a tendency to cut when they cross tissues.

This effect is greater when a suture has low elasticity, high tensile strength, small diameter and high friction coefficient. Fragile tissues can be easily damaged and sawed by a simple passing suture.

B5-Absorption

By definition, an absorbable suture loses at least 50% of its tensile strength by the 60-day mark (e.g. polyglactin 910, pds...)

In the presence of infection, when absorption is enzyme-mediated, the process speeds up. On the other hand, when absorption is hydrolysis-mediated (by inflammatory cells), it is slower in the presence of infection, especially in an acidic pH.

Non absorbable sutures do not lose 50% of the tensile strength prior to 60 days, and they can remain in the tissues for a long time (e.g. polypropylene, polyester...). Other sutures absorption is mediated by different mechanisms (e.g. polyamide into the cornea, is slowly degraded by light).

B6-Induction of infection

When a suture material passes through an infected tissue, there is a tendency to spread infection.

This tendency is higher with rolled or twisted multifilament (silk, polyester, polyglycolic acid, polyglactin 910...), and lower when a monofilament suture (nylon, polypropylene, polydioxanone,...) is used. As a general rule, you should always use a monofilament in infected wounds.

Types of sutures

A – Absorbable

(Polyglycolic acid, polyglactin 910, polydioxanone, glyconate, polyglyconate, poliglecaprone 25...)

A1-Polyglycolic acid

Polyglycolic acid is a mid-term multifilament, braided and coated, synthetic absorbable suture made of pure polyglycolic acid molecules.

It allows easy handling and provides very secure knots. Degradation occurs by enzymatic hydrolysis, which is faster in an alkaline pH.

This suture causes low tissue reaction.

It keeps 50% of tensile strength for 21 days. Total absorption occurs between 100 and 120 days.

It is often used to approximate close subcutaneous planes.

Advantages: well tolerated, easy sterilization, allergic response rare.

Disadvantages: high tensile strength and low

elasticity, with some tendency to cut tissue.

Use with care and you have a good, absorbable mid-term suture.

A2-Polyglactin 910

Braided multifilament synthetic polymer made of lactic acid and glycolic acid.

Absorption by hydrolysis. Tissue reaction similar to polyglycolic acid, with slightly greater tensile strength (50% by 21-25 days).

Complete reabsorption between 60-90 days.

Other characteristics are similar to polyglycolic acid.

A3-Rapid resorption polyglactin 910

This is a polyglactin 910 suture, treated with gamma rays. Lower tensile strength: 50% on 7th day and 0% on 14th day.

Total reabsorption in 42 days.

It is widely used to suture wounds with low stress (skin and mucous membranes), when there is no need to remove sutures.

Do not use this suture if the wound requires closure for more than 7 days.

Do not use it on wounds of the eyelid margin.

This material provides a secure knot, flexibility and predictable resorption.

A4-Poliglecaprone 25

Synthetic, absorbable short-term monofilament (a copolymer of glycolic acid and epsilon-caprolactone). Tensile strength is 50% at 7th to 10th day, and 20-40% after 14 days.

Complete hydrolysis occurs between 90-120 days.

This is a monofilament with low coefficient of friction, low tissue reaction but high memory; it is often used to close deep tissue layers on the face.

A5-Glyconate

This is a mid-term absorbable synthetic monofilament suture made of glyconate, available undyed for closure of superficial wounds, or in violet for other wounds.

50% of knot tensile strength is retained at 14 days.

Complete mass absorption occurs in 60 to 90 days.

Glyconate has excellent handling properties and high knot security.

It is recommended for soft tissue closure.

A6-Polydioxanone

This is a synthetic, violet, long-term, absorbable monofilament suture made of polydioxanone, with a slow degradation profile.

It is ideal when extended support for more than 10 weeks is required.

Tensile strength is 50% at 28 days when a 4/0 or 5/0

5. Sutures and needles in ophthalmic plastic surgery

suture is used.

Complete mass reabsorption occurs in 180 to 210 days.

B - Non-absorbable

(Silk, polyamide, polypropylene, polyester, polybutester, steel...)

B1–Silk

It is a natural non-absorbable, braided or twisted, and sometimes coated suture, extracted from silkworm cocoons.

It can be coated with silicone or other materials. If left inside tissues, it is slowly absorbed over a period of months.

There is an inflammatory tissue response in the first few days, and then a fibrous reaction develops.

Main advantages: it is soft, flexible, easy to handle and provides secure knots. It rarely saws the tissue. It is also cheap.

Because of its high capillarity and absorption capacity this suture can facilitate and/or perpetuate infection. There is also some tendency to swell and to embed if it remains in tissues for more than 2 weeks.

It is widely used to suture skin of eyelids and wound edges.

B2-Polyamide

(Nylon, Nurolon, Surgilon, Supramid, Dermalon, ...)

B 2.1. Nylon

It is a synthetic, non-absorbable, monofilament, polyamide suture, with high tensile strength (higher than silk and polypropylene).

Advantages: it is ideal for skin sutures. Does not swell, and is well tolerated by tissues. It can and should be used in infected tissues.

Disadvantages: it can be difficult to tie. High memory requires more loops, and there is a tendency to untie. Bristled ends can irritate the suture site.

It can cut tissues because of its high saw effect.

B3 - Polypropylene

It is a synthetic non-absorbable monofilament suture usually blue in color to enhance visibility.

It has moderate flexibility, low tensile strength, good elasticity and elongation properties. It is soft and has a smooth surface.

It has excellent tissue tolerance (it can remain inside tissues for years) and is therefore used in iridoplasty, scleral fixation IOL....

Because of its very low tissue friction and smooth passage through tissue, it is ideal for continuous intradermal sutures, allowing easy removal a few days later.

Knots tend to get loose, so several locked loops are

needed. Moderate plasticity allows knot deformation with improvement in security.

It can and should be used in infected wounds.

Needles

An ideal needle has good tenacity (resistant to penetration and maintains direction), good ductility (flexible handling and bends without breaking, facilitating access to difficult locations), and not traumatic as it passes through tissues.

Easyslide needles, are the result of extensive research and experience in metallurgical technology, using the highest quality stainless steel.

Penetration performance, surface, body section and excellent stability in the needle holder, are important to achieve a good suture.

A needle comprises: tip, body and chuck.

The tip is important for good penetration properties.

The needle must keep continuous penetration performance after several passages, with excellent durability and needle point integrity.

Special steels are used to produce needles.

The body of the needle allows placement and tightening of needle holders. It can be round, triangular, flat... (Figure 8)

Round body needles are less likely to damage tissues; they leave a small hole that does not induce tears.

Flat body needles are widely used in ophthalmic plastic surgery to pass through thin tissues (e.g. tarsus).

Triangular body needles may be direct-cutting (widely used to suture skin) or reverse cutting, widely used to suture skin and eyelid margin.

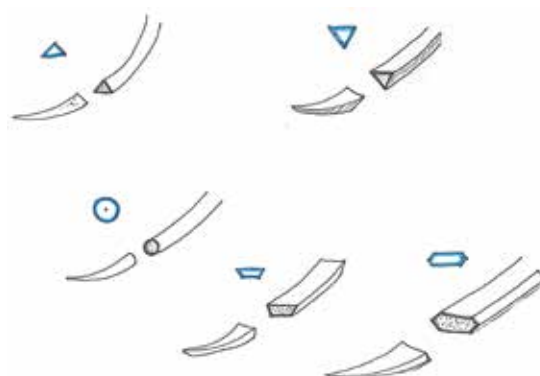


Figure 8 – Needle body types: triangular, round, flat

Materials

Needles are made of stainless steel. Steel is a metal alloy of iron+carbon (0.008 to 2.11%). Chromium is added (>11%) to make stainless steel. The addition of nickel gives the needle ductile properties.

The first stainless steel needles manufactured were made with iron + 0.24% carbon + 12.8% chromium

Needle curvature

1/8 circle

2/8 circle

3/8 circle

4/8 circle (half circle)

5/8 circle

There are also straight progressive, hook and ski configuration needles.

6. Anesthesia for Orbit and Oculoplastic Surgery

Margarida Anastácio, Guilherme Castela

1. Introduction

The role of anesthesia in providing a safe environment for performing oculoplastic surgery has changed over the past decade¹. Its importance extends beyond making the patient comfortable and less anxious², it also has to facilitate the surgical procedure without endangering the patient or the technical execution. The improvement of knowledge of the anatomy and physiology of the eye and its adjacent structures³⁻⁶, together with the direct cooperation between the anesthesiologist and the ophthalmologist^{3-4,6-7} has been essential for the better understanding and advances in local anesthesia in ophthalmology⁶⁻⁸. Teamwork is crucial, and the anesthetic approach should involve not only the anesthesiologist's preference but also the surgical techniques to be used, bearing in mind the patient's condition⁶. Clinical judgement should prevail and patient safety should always be a priority³.

The introduction of new anesthetic drugs for local anaesthesia (LA) and its widespread use in other areas of interest have driven the use of this type of anesthesia in this particular setting. Currently, the vast majority of operations in ophthalmic surgery are performed on a day-stay, under local anesthesia, since this is generally associated with lower morbidity than general anesthesia and faster recovery³. However, no local anesthesia technique is totally free of the risk of serious systemic adverse events, which can occur irrespective of the choice of surgery or anesthetic technique. Furthermore, it is of the utmost importance to balance the risks and benefits of the several types of anesthesia in different situations, such as elderly people with multiple pathologies and children^{3,6-7}.

2. General anesthesia

Anesthetic requirements are dictated by the type of patient, type of procedure and surgical technique, surgeon's preference and desire of the patient^{5,7}.

In spite of the great advantages of local anesthesia, general anesthesia (GA) will always have a place and specific indications in orbit and oculoplastic surgery^{3,7}.

The current indications for GA are:

- patients refusal of local anesthesia;
- local sepsis;
- severe coagulation disorders;
- severe reaction and allergy to anesthetic drugs;
- uncontrolled tremor;
- inability to adopt acceptable positioning;
- lack of mental ability to cooperate whilst awake;
- children;
- more complex or prolonged surgery because of the volume of local anesthetic that would be required (e.g. large tumor resections and reconstruction, dacrocystorhinostomy, enucleation of the eyeball and three-wall orbital decompression procedures for thyrotoxic exophthalmos)^{3,7,9-11}.

Preoperative assessment is always performed, as for any surgical procedure, and informed consent must be obtained for the operation and anesthesia³. The patient's concomitant medical conditions should be controlled^{7,11}, in particular, adequate blood glucose control in diabetic patients, blood pressure, medication review including antiplatelet drugs and anticoagulants and other ophthalmic drugs with systemic effects, prevention of perioperative fasting, history of known allergies or other previous complications with anesthesia or surgery^{3,7,11}.

One cannot emphasize enough the vital role of continuous monitoring, such as pulse oximetry, electrocardiogram, blood pressure, and it should start before any anesthetic action and continue after the end of the surgery^{3,7,11}.

A number of techniques are used to perform general anesthesia, but certain details regarding the orbit and oculoplastic surgery must be considered in the selection process. The laryngeal mask (LMA) is the ideal airway for most ocular procedures, because muscle relaxants are not usually required for ophthalmic surgery, it avoids airway stimulation, and can be used for short procedures. Most standard methods of maintaining anesthesia are possible, but total intravenous anesthesia (TIVA) using propofol and remifentanil are generally used for their advantages of low incidence of nausea and vomiting,

adequate control of blood pressure, good toleration, rapid recovery, rapid titration to patient's needs)^{7,11}. Eye surgery is not generally associated with disabling pain, and oculoplastic and orbit surgery is not much different in this aspect. Non-steroid antiinflammatory drugs (NSAIDs) and paracetamol are usually adequate to control pain. When there is extended surgical procedure, pain management becomes an important issue. Opioids and eye block (e.g. retrobulbar, peribulbar or sub-Tenon's and local anesthetic infiltration) to reduce pain after surgery may be required, particularly in the case of enucleations or large tumor resections^{7,11}.

3. Local anesthesia

The ideal local anesthetic drug for ophthalmic anesthesia should be safe, painless on injection, reversible, have a limited area of action, rapid onset of action, appropriate duration for the procedure, enough power to anesthetize, provide good tissue penetration and low degree of toxicity and be devoid of allergic reactions. None of the ones commonly used is ideal⁶.

3.1 Local anesthetics (LA)

Lidocaine 1 % and 2 % are probably the most used LA in oculoplastic surgery, and they are characterized by a rapid onset of action and intermediate duration of efficacy. Therefore, they are suitable for local infiltration, blocks and topical anesthesia. Adverse drug reactions (ADRs) are rare when lidocaine is correctly used. Most ADRs are related to the administration technique and to systemic pharmacological effects^{6,12}.

Bupivacaine 0.5 %-0.75 % is indicated for local infiltration and eye block (retrobulbar, peribulbar, and sub-Tenon's block). It is the most potent and has the longest duration of action. However, in comparison with other LAs, bupivacaine is markedly cardiotoxic and neurotoxic, thus it should be used with caution. The 0.75 % (most concentrated) formulation is used to improve akinesia^{6,12}.

Ropivacaine 0.75 % has the same indications as bupivacaine^{6,12} but is associated with less cardio and neurotoxicity. Hence, it has a better pharmacological profile^{1,12-13}.

Levobupivacaine 0.5 % is associated with less vasodilation, has a longer duration of action, but has a longer motor block onset time than bupivacaine. It is approximately 13 % less potent (by molarity) than racemic bupivacaine^{6,12}.

Oxybuprocaine 0.4 % is an ester-type local anesthetic, which is specifically used in topical anesthesia. The usual dosage is 1 to 3 drops administered every 5 minutes up to 20 minutes. The

onset of the effect is around 60 seconds and lasts for 60 minutes after the last instillation. Care should be taken to not exceed these doses, because of cornea toxicity^{6, 12}.

3.2 Anesthetic mixture

A mixture of equal volumes of **lidocaine and bupivacaine** is the most popular preparation (1,6,8). Lidocaine has a good tissue penetration and rapid onset of action, while bupivacaine prolongs blocking, thereby avoiding the need to reinforce local anesthesia and providing longer postoperative analgesia^{6,8-9}. The use of **lidocaine with ropivacaine** has increased in our experience, because it has the same advantages as bupivacaine but avoids its side effects.

The addition of **1:200 000 adrenaline** to local anesthetic has two advantages in oculoplastic surgery: it prolongs anesthesia and analgesia by decreasing the absorption of LAs and improves hemostasis^{5,9} through its vasoconstriction effect. Nevertheless, one should be careful in patients with cardiac disease, due to tachycardia, hypertension and tissue ischemia^{1,6,8,12}. We have been using the above mentioned mixtures in equal volumes adding adrenaline 1:200 000 (0.2 ml of adrenaline 1:100 000).

3.3 Techniques

The basis for performing ophthalmic local anesthesia is a thorough knowledge of anatomical, pharmacological and practical aspects of the techniques^{1,6,8,12-13}. It is mandatory to have an intravenous access, plus monitoring and medication for resuscitation, whenever any type of ocular block is used¹⁰.

Oculoplastic surgery has distinct features, such as patient compliance (opening and closing the eyelids during ptosis procedures to ascertain the outcomes), and for this reason local anesthesia has a key role since it allows good patient cooperation during the surgical intervention.

Topical anesthesia anesthetizes the superficial conjunctiva and cornea with minimal complications, but requires good patient selection. In oculoplastic surgery it is indicated to prevent a burning sensation during disinfection of the operative field^{1,2}.

Local infiltration is administration of local anesthetic in the skin where the procedure is performed (subconjunctival and subcutaneous). It is very useful in eyelid surgery, particularly during blepharoplasty and procedures for eyelid ptosis, entropion and ectropion. The major complications of this technique are, hematomas, distension of the tissue and systemic toxicity of the drug, if used in large quantities. Any amide-linked LA is suitable for local infiltration, but a mixture of lidocaine 2% and bupivacaine 0.5% or

ropivacaine 0.75% with adrenaline 1:200 000 have the advantages of rapid onset and long action. Extra anesthetic may be given if sensation returns or if surgery extends into another area⁸⁻⁹ (Figures 1 to 4).

Retrobulbar block involves intraconal injection of a small volume (2-4 ml) of LA, in the inferotemporal region, with a long needle (up to 31 mm). It has several shortcomings in that it is slightly painful, akinesia of the eyelids may be incomplete, and facial nerve block is often required. Moreover, it can be associated with serious complications, such as retrobulbar hemorrhage, globe perforation, optic nerve or ophthalmic artery lesion, and spread of the anesthetic to the brainstem^{1,5-6,8,10}. Hence, it is seldom used in oculoplastic surgery, with other techniques being preferred. It is useful in orbit surgery, particularly in enucleation and evisceration⁹.

Peribulbar block is extraconal anesthesia, which minimizes iatrogenic injuries to the globe. It is less painful than the retrobulbar block and since it does not involve facial nerve block, ptosis is not an issue. It has the disadvantages of prolonged onset of action (30 min to onset of block) and requiring greater technical skill, larger volumes of anesthetic (5-15 ml) and usually needs two injections (inferotemporal, medial or superonasal), which can cause more bruises or hematomas. Complications are similar to but less frequent than those of retrobulbar block^{1,5-6,8,10}. Rarely used in oculoplastic surgery, but suitable for enucleations if local anesthesia is the preferred technique⁹.

Sub-Tenon's block comprises the administration of local anesthetic (3-5 ml) into the subtenon's space. It is usually performed by the ophthalmologist, and requires additional instruments (forceps and scissors) to reach the space (Figures 5,6). Surgery can start immediately after the induction and the block lasts approximately 60 minutes. Low volumes (2-5 ml) of LA suffice because, as the solution spreads to the retrobulbar space, akinesia of the rectus muscles and analgesia of the anterior supervenes. The use of a blunt cannula prevents the severe complications associated with retro and peribulbar blocks, however this technique can cause edema, chemosis and conjunctival hemorrhage. It is very useful in patients with long eyes or in those who are taking anticoagulants^{1,5-6,8,10}.

Supraorbital nerve block – The supraorbital nerve is the lateral branch of the frontal nerve division, which in turn, is the second branch of the ophthalmic nerve. It emerges from the supraorbital notch, in the middle third of the superior orbital rim, supplies innervation to the middle two-thirds of the upper eyelid, superior conjunctiva, eyebrow, forehead and scalp. The technique consists of injecting about 0.5 ml at the junction of the inner third with the two

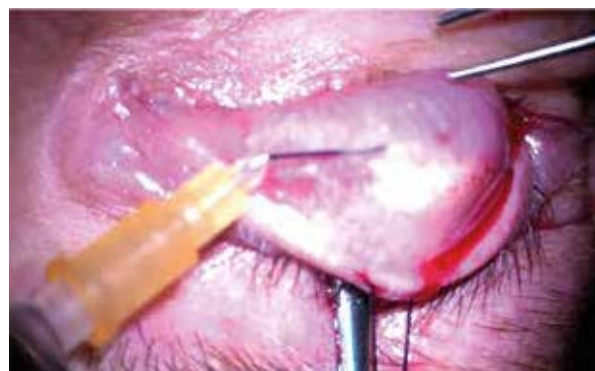

Fig. 1 Subconjunctival superior eyelid infiltration.

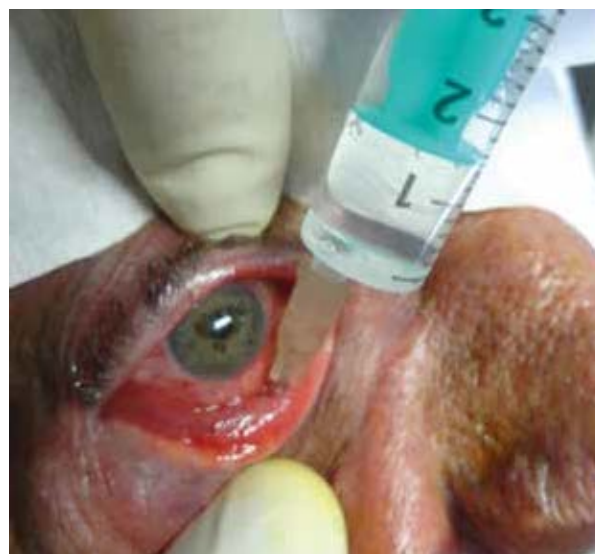

Fig. 2 Subconjunctival superior eyelid infiltration.

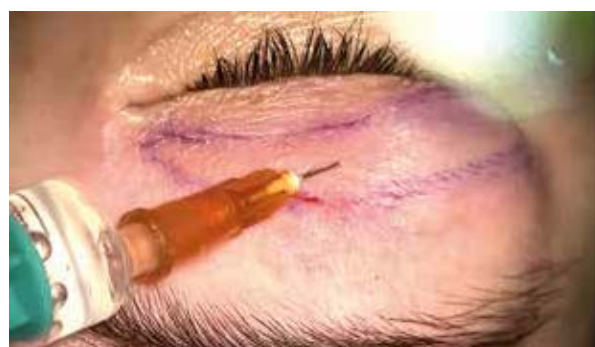

Fig. 3 Subcutaneous infiltration.

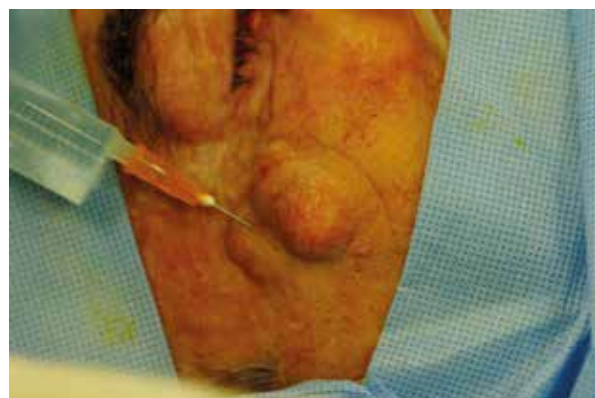

Fig. 4 Subcutaneous infiltration.

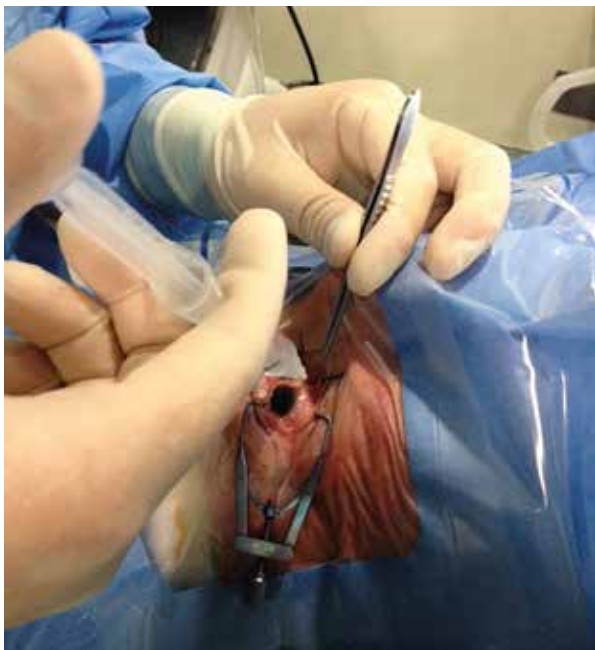

Fig. 5 Sub-Tenon's block.

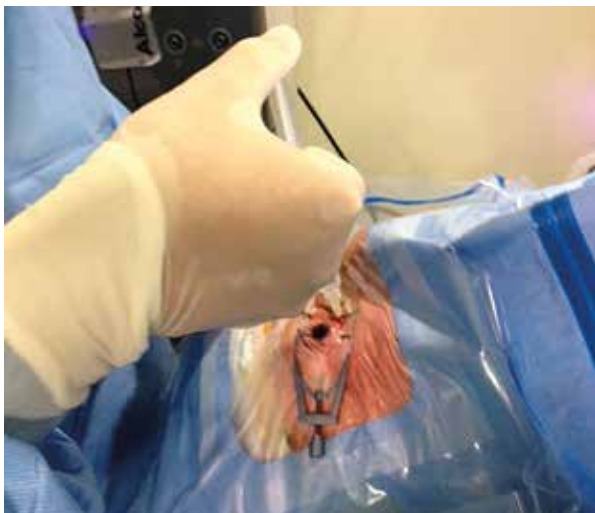

Fig. 6 Sub-Tenon's block.

external thirds in the supraorbital notch near the orbital rim (Figure 7).

Supratrochlear nerve block – Supratrochlear nerve (STN) is the medial branch of the frontal nerve. It passes over the trochlea and innervates the nasal part of the upper eyelid and eyebrow. STN block is obtained by inserting the needle in the supraorbital wall just above of the trochlea to a depth of 1.5 cm (approximately 1 cm medial to the supraorbital notch, between the notch and bridge of the nose) (Figure 8).

Nasociliary nerve block – This nerve transmits the principal somatosensory inputs from the eye. It innervates the inner corner of the eye and the cornea, lacrimal sac, nasal dorsum skin and mucosa of the anterior superior portion of the nasal fossa, through its anterior and posterior ethmoid and infratrochlear branches. It also gives sensitivity to the conjunctiva

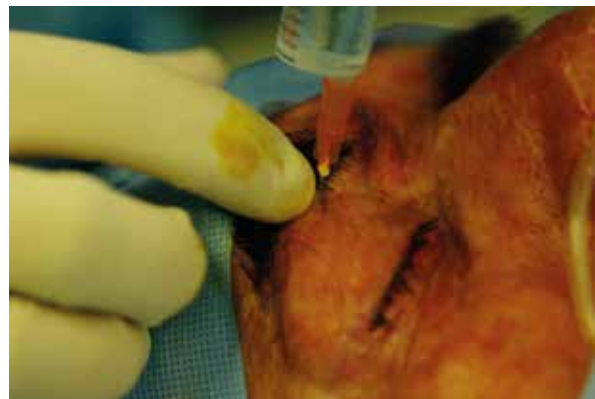

Fig. 7 Supraorbital nerve block.

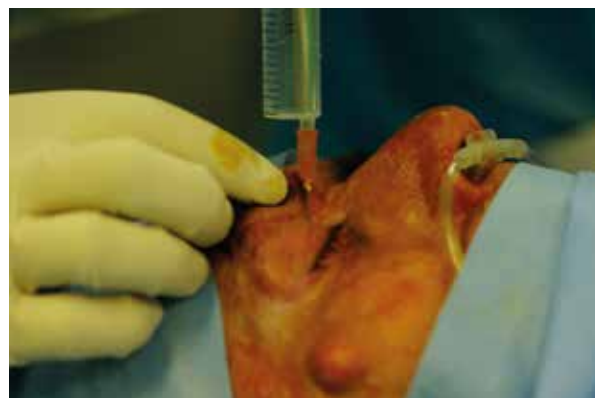

Fig. 8 Supratrochlear nerve block.

and upper eyelid. We find it just on top of the medial canthus ligament (10 to 20 mm). This block is very useful when performing dacryocystorhinostomy^{13,18}.

Infraorbital nerve block – The infraorbital nerve (IAN) is one of the maxillary nerve branches. It emerges from the infra-orbital foramen, 0.5-1 cm below the junction of the medial one-third and the lateral two-thirds of the inferior orbital rim. IAN block is accomplished by injecting 2-3 ml of the anesthetic subcutaneously at this site. It supplies good anesthesia for the skin and conjunctiva of the lower eyelid, the lower part of the side of the nose and part of the upper lip (Figure 9).

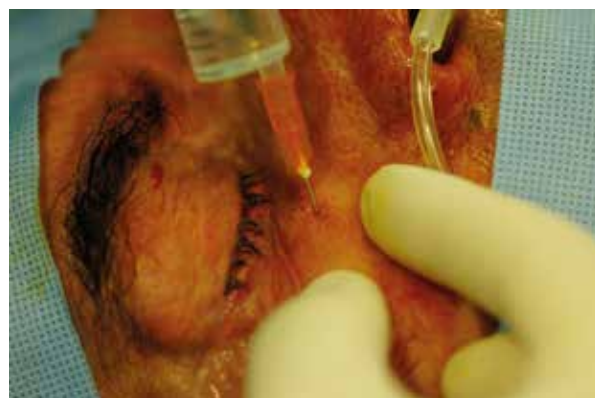

Fig. 9 Infraorbital nerve block.

Infratrochlear nerve block – Is obtained by passing the needle along the medial orbital wall, 1 cm superior to the medial canthus, advancing it 1.5 cm and injecting 2-3 ml of the anesthetic. It provides anesthesia for the skin of the upper eyelid, side of the nose, medial conjunctiva, lacrimal sac and caruncle (Figure 10).

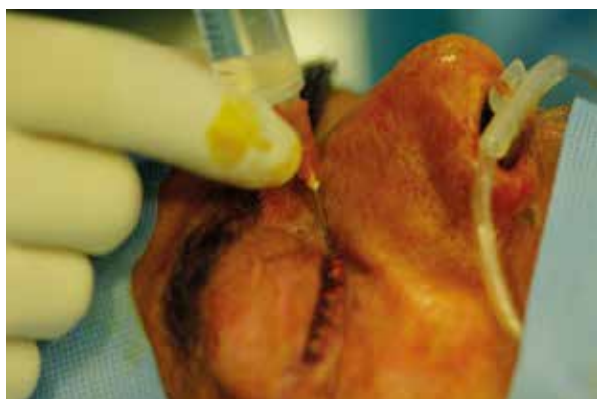

Fig. 10 Infratrochlear nerve block.

3.4 Complications

Local/regional anesthesia is most often an uneventful procedure, nonetheless it can be associated with serious complications, mostly related to akinetic injection techniques, but these are rarely used in oculoplastic surgery^{6,12}.

Complications can be divided into systemic and local. The former are due to excessive or misplaced anesthetic and may result in life-threatening complications. Brainstem anesthesia (stimulation or depression of the central nervous system) can cause anxiety, tremor, agitation, which can progress to convulsions, coma or respiratory depression. Accidental intravascular injection of LA can cause cardiovascular effects, such as bradycardia, arrhythmia, hypotension and syncope. Allergic and vasovagal reactions to LA agents can occur in regional blocks^{3,12}.

Local complications include failure of block, corneal abrasion, chemosis, sub and conjunctival or retrobulbar hemorrhage, globe perforation, optic-nerve damage and muscle damage, which are generally caused by trauma during needle insertion^{1,5-6,10,15-17}.

Some of these complications can be minimized by taking a thorough preoperative history of known allergies, using the minimum effective doses of LA, performing vacuum before injecting local anesthetic and rapid recognition and treatment of life-threatening complications associated with eye blocks.

3.5 Sedation for ophthalmic procedures

Good sedation leaves the patient relaxed, but alert and able to hear and communicate with the surgeon and obey verbal instructions^{2-3,18}. Sedation is essential

to prevent anxiety, hypertension, tachycardia and to avoid minor tremor or unintentional cough. The effects of the sedation should be easily controlled, with smooth onset, rapid recovery and minimal side-effects^{3,6,18}. Ideally, one should use minimal or moderate sedation, because deep sedation might cause unexpected movements of the patient's head or eyes, as well as impatience when the patient wakes up or airway obstruction, which may put at risk the operation³.

Short-acting benzodiazepines (midazolam), opioids and propofol are usually the preferred agents for sedation/analgesia.

The complications of sedation include excessive restlessness, sudden movement or awakening, nausea and vomiting, hypotension, paradoxical excitation, and airway obstruction with hypoxemia^{3,6}.

4. Anticoagulant therapy

Patients taking anticoagulant therapy could have an increased risk of hemorrhagic complications, but discontinuation may result in serious cardiovascular complications⁸.

Hemorrhagic complications are most frequent in orbital and oculoplastic surgery⁴, so we advocate that all patients discontinue anticoagulant and antiplatelet therapy before surgery, unless they are at high risk of thrombo-embolic complications. In this latter situation they should change from warfarin to heparin, if indicated^{3-4,8}. The coagulation profile should be checked before surgery and should be within the appropriate therapeutic range (international normalized ratio <2.0). Antiplatelet drugs should be stopped at least 10 days before eyelid procedures or dracryocystorhynchostomy⁷.

5. Conclusions

A good knowledge of the anatomy of the orbit and its components, the physiology of the eye, pharmacology and technical aspects of the anesthesia are essential for the good practice of local anesthesia in oculoplastic surgery.

The involvement of the anesthetist is crucial, because it is essential to recognize and treat life-threatening complications caused by either local or general anesthesia. Good cooperation between ophthalmologists and anesthetists is absolutely necessary for good clinical practice in this setting.

Local anesthesia is considered the preferred procedure in oculoplastic surgery, since the operations are usually rapid and they often require the cooperation of the patient. It also causes the least disruption to the patient's daily routine and is associated with lower morbidity than general anesthesia^{3,8}.

Oral or intravenous sedation also has an important

role because it helps reduce discomfort, pain or anxiety. It also enables patients to be conscious and reactive, relaxed, and provides amnesia in long surgical procedures. However, it should never be used to cover up an inadequate block⁴. A word of caution should be added here: proper monitoring and pre-anesthetic evaluation are needed to prevent serious complications arising from the drugs and/or the anesthetic technique. Whenever patients are not suitable for local anesthesia with sedation, general anesthesia should be considered.

References

1. Benatar-Haserfaty J, Puig Flores JA. Anestesia locorregional en oftalmología: una puesta al día. *Revista Española de Anestesiología y Reanimación* 2003; 50: 284-294
2. Moody BR, Holds JB. Anesthesia for office-based oculoplastic surgery. *Dermatologic Surgery* 2005; 31: 766-769
3. Bremner F, Kumar CM, Eke T, Dodds C, Deane JS, El-Hindy N, Johnston RL et al. Local anaesthesia for ophthalmic surgery. Joint guidelines from the Royal College of Anaesthetists and the Royal College of Ophthalmologists London, 2012
4. Kallio H, Rosenberg PH. Advances in Ophthalmic Regional Anaesthesia. *Best Practice & Research Clinical Anaesthesiology* 2005; 19(2) 215-227
5. Hamilton RC. Techniques of orbital regional anaesthesia. *British journal of Anaesthesia* 1995; 75:88-92
6. MacLure HA, Rubin AP. Local anaesthesia for ophthalmic surgery. *Current Anaesthesia and Critical Care* 1999; 10:40-47
7. Pritchard N. General anaesthesia for ophthalmic surgery. *Anaesthesia and Intensive Care Medicine* 2010; 11(10): 425-428
8. Wong DH. Regional anaesthesia for intraocular surgery. *Canadian journal of anaesthesia* 1993; 40 (7): 635-657
9. Tyers AG, Collin JRO. Anaesthesia. *Color atlas of ophthalmic plastic surgery* 2h edition; 2001; 59-66
10. Carr C. Local anaesthesia for ocular surgery. *Anaesthesia and Intensive Care Medicine* 2010; 11(10): 434-437
11. McGoldrick KE, Foldes PJ. General anesthesia for ophthalmic surgery. *Ophthalmology Clinics of North America* 2006; Jun; 19 (2): 179-91
12. Berde CB, Steichartz GR. Local anesthetics. Miller RD, Eriksson LI, Heisher LA, et al, editors *Miller's anesthesia* 7h edition Philadelphia, pa: Elsevier Churchill livingstone; 2005
13. Rodríguez Navarro MA, Pérez Morena MA, Padilla Rodríguez J, Cantos Gómez E, Sanz Campillo J. Uso de crema EMLA® y ropivacaína en la dacriocistorrinostomía con anestesia locorregional y sedación. *Revista Española de Anestesiología y Reanimación* 2000; 47: 252-255
14. Dortzbach RK. Dacryocystorhinostomy. *Ophthalmology* 1978; 85:1267-1270
15. Carr C. Complications after sub-Tenon's eye block. *Anesthesia and Analgesia* 2003; 96(1): 273-277
16. Calenda E, Rapoza P, Sternberg JrP et al. Peribulbar anesthesia and sub-Tenon injection for vitreoretinal surgery. *Acta Ophthalmol Scand* 2000; 78: 196-199
17. Hamilton RC. Techniques of orbital regional anaesthesia. *British journal of Anaesthesia* 1995; 75:88-92
18. Benatar-Haserfaty J, Monleón de la Calle MP, Sanz-López A, Muriel AG Dacriocistorrinostomia externa realizada en el consultorio bajo anestesia locorregional y sedación. *Revista Española de Anestesiología y Reanimación* 2007; 54: 23-28

7. Graft Harvesting in Ophthalmic Plastic Surgery

Sandra Prazeres, Renata Rothwell

Introduction

A graft is a nonvascularised tissue that is harvested from its donor bed and transferred to a recipient site. Its survival relies on the ingrowth of new vessels from the recipient bed to restore its blood supply.

An **autograft** is tissue transplanted from one site to another in the same individual. An **isograft** is transplanted from a donor genetically identical to the recipient, such as transplants between human monozygotic twins. An **allograft** is transplantation of tissues between unrelated individuals of the same species. A **xenograft** is transplantation between different species.¹

The use of autologous graft material obviates the risks of disease transmission and rejection, but it carries a risk of donor site morbidity.

Mastery of graft harvesting is very important to increase surgical options in ophthalmic plastic surgery. There are many sites for graft harvesting that can be used for the reconstruction of the periocular area and the anophthalmic socket.

When selecting the most appropriate surgical technique for eyelid reconstruction after tumor resection, a number of variables must be considered, such as the size of the eyelid defect, the health of the surrounding tissue, the patient's age, co-morbidities, the status of the contralateral eye and the surgeon's personal surgical preference.

Two basic principles apply to eyelid reconstruction: the concept of lamellar reconstruction, and viability of flaps and grafts. The two lamellae of the eyelid must be reconstructed, the anterior represented by the skin and orbicularis muscle and the posterior represented by the tarsus and conjunctiva. To perform the reconstruction, one of the lamellae must be vascularized so as to guarantee the survival of both. Thus, at least one of them must be a flap. A graft can be laid on a flap and a flap can be laid on a flap, but a graft cannot be laid on another graft because of the lack of a secure blood supply.

Autologous Skin Grafts

Autologous skin grafts can be of either full or split thickness. The full-thickness skin graft gives an excellent

cosmetic result with limited graft contraction but has the disadvantage of unreliable graft "take."

When large areas are to be covered, split-thickness skin grafting is used. It is the most commonly practiced form of tissue transplantation in plastic surgery¹ but is rarely used in ophthalmic plastic surgery.

Full-thickness skin grafts

Full-thickness skin grafts (FTSG) consist of the entire epidermal and dermal layers of the skin. The size of the graft available for transfer is limited by the donor site, since the area must be surgically closed.

FTSGs are used for anterior lamella reconstruction (following tumor excision or blepharoplasty), repair of cicatricial ectropion and scar revision surgery.

The choice of the donor site depends on factors such as the patient's age, the size of the graft and the degree of solar damage of the donor skin.²

Various potential donor sites are available for harvesting FTSG, such as the upper eyelid (Fig. 1-3), postauricular area (Fig. 4-6), preauricular area (Fig. 7 and 8), inner arm³ and supraclavicular fossa^{4,5}. The first three sites are most commonly used in ophthalmic plastic surgery.

The **upper eyelid skin** is ideal when dermatochalasis is present, since it is an excellent color and texture match for eyelid defects and has no subcutaneous fat.⁶ The upper eyelid skin is harvested from the lateral third of the eyelid (Fig. 1), or, if a larger area is required, the incision is performed in the same manner as in a superior blepharoplasty. It is important to ensure that a minimum of 12 mm of skin is preserved between the superior border of the incision and the inferior border of the eyebrow, to prevent complications such as secondary lagophthalmos and brow ptosis.²

Postauricular skin grafts can be taken from the postauricular sulcus (Fig. 4), encompassing the area from the helical rim to the hairline over the mastoid region. This donor site provides a relatively good color and texture match for the eyelid and permits the acquisition of grafts of reasonable size. A traction suture on the auricular pavilion can be used to better expose the area.

7. Graft Harvesting in Ophthalmic Plastic Surgery

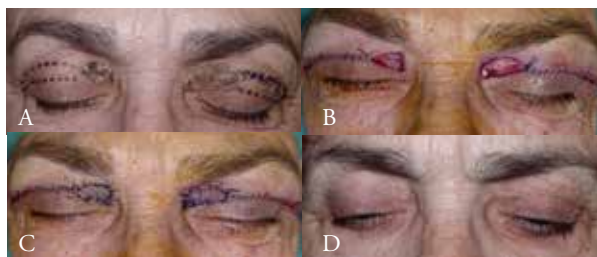

Figure 1: Use of a full-thickness skin graft from the upper eyelid to treat a partial-thickness defect. A - Incision marked; B - Appearance after removal of dermatochalasis and skin lesion (preserving the orbicularis muscle) and direct closure of the incision; C - Grafts *in situ* without bolster; D - Six month after lesion removal with placement of a full-thickness graft from the lateral region of the upper eyelid.

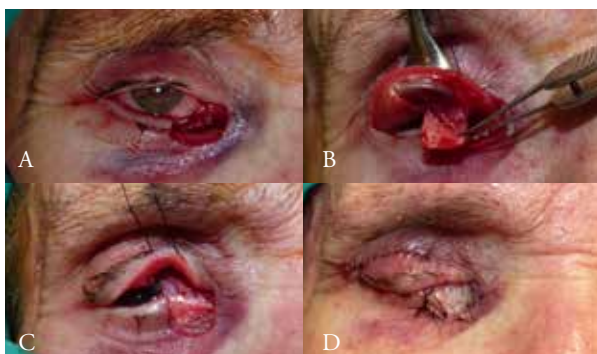


Figure 2: Use of an upper eyelid skin graft for anterior lamella reconstruction. A - Full-thickness defect of the medial third of the lower lid; B - Tarsalconjunctival flap cut and dissected from the anterior lamella; C - Tarsalconjunctival flap sutured into the defect; D - Graft harvested from upper eyelid skin.

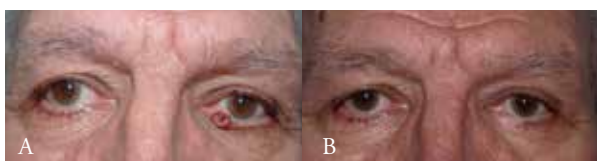


Figure 3: Hughes' lower lid reconstruction. A - Sebaceous cell carcinoma of the medial third of the left lower lid; B - One year after a tarsalconjunctival flap covered with a full-thickness upper lid skin graft.

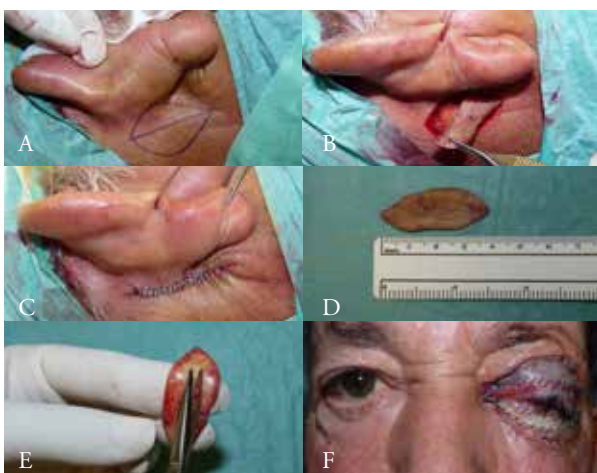

Figure 4: Postauricular skin graft. A - Incision marked in the postauricular region; B - Graft cut in the plane of the skin behind the ear; C - Continuous interlocking suture to close the wound; D - Postauricular skin graft; E - Excess fat removed from the graft; F - Postauricular skin graft in place.

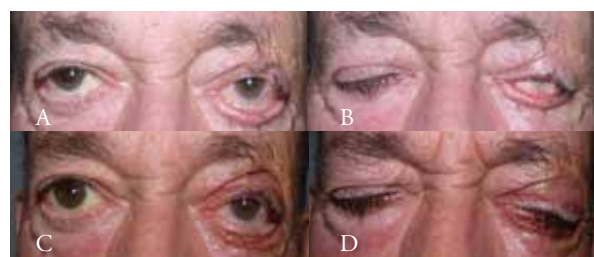


Figure 5: Use of full-thickness skin graft for management of eyelid burns. A, B - Cicatricial ectropion of both upper and lower left eyelids; C, D - Two months after placement of postauricular skin grafts.

Preauricular skin is thinner than postauricular skin and is easily accessible. It also provides a relatively good color and texture match for the eyelids. A graft of up to 1×4 cm can be obtained.⁷ However, the area of tissue is insufficient for large defects and should not be used in patients with very greasy skin. Preauricular skin grafts have a greater tendency to contract and cause a pin-cushion effect.²

Before graft harvesting is commenced, the receptor site must be prepared and its size and shape must be determined using a ruler or a paper template (one option is to use a paper hand towel). The shape of the graft is marked out at the donor site with a dermatographic marker (Fig. 7), and is about 25 % larger than the receptor area, since a certain degree of graft retraction is to be expected.^{8,9} The donor site is then injected subcutaneously with a mixture of lidocaine local anesthetic and adrenaline at 1:100,000 to aid in hemostasis and skin dissection. The skin is incised with a no. 15 blade and dissected with Stevens scissors. When collecting graft tissue at the upper eyelid, care must be taken to leave the underlying orbicularis muscle intact. In the pre- and postauricular areas as little subcutaneous tissue as possible should be included in the graft. The graft is protected in a gauze swab moistened with saline and should be kept in a safe location.

Hemostasis is performed with care at the donor site with a bipolar forceps. When the upper lid is used as donor site, the wound is closed with 6/0 polypropylene or 6/0 silk, while for the pre and postauricular areas 5/0 polypropylene or 5/0 silk suture is preferred.

Subcutaneous adipose tissue is removed from the graft with Stevens or Westcott scissors prior to placement (except in the case of upper eyelid skin). When grafting the upper eyelid, skin grafts are best placed pretarsally and a supraciliary upper eyelid skin incision is used.¹⁰ In cases where the tarsus is used as the graft bed, oversizing is not necessary as the tarsus offers good stability, reduces contraction and produces good cosmetic results.⁶

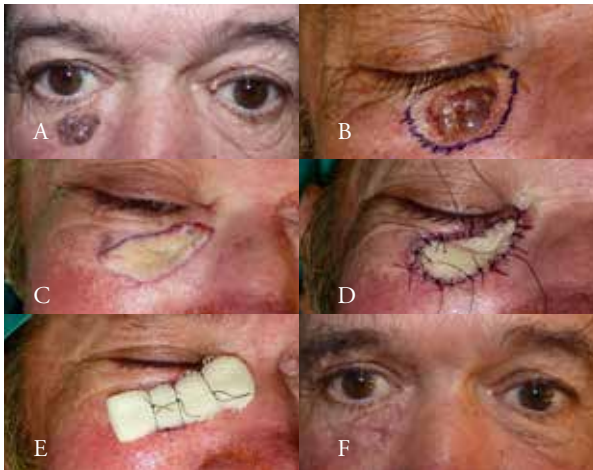

Figure 6: Use of a full-thickness skin graft to treat a partial-thickness defect in the lower lid. A – Basal cell carcinoma of lower lid; B – Incision marked; C - Postauricular skin graft sutured in place; D – Postauricular skin graft sutured into the defect; tie-over sutures left long enough to secure pressure bolster; E – Bolster of paraffin gauze; F – Two months after grafting postauricular skin into the lower lid.

If pretarsal placement is not possible, e.g. when grafting for post-burn contracture, the upper eyelid skin crease incision is used as the lower border of the graft.¹¹ In this case, the graft should be oversized by 30 % to anticipate contracture.⁶

The graft is placed at the receptor site and is secured with at least 4 interrupted 5/0 silk sutures, which are cut long and in an even number so that they can be tied together in pairs. Between the sutures, interrupted 6/0 silk sutures are placed. Paraffin gauze is applied over the graft, and the 5/0 silk sutures are tied to each other above the gauze, holding it in place to act as a bolster. The FTSG can also be secured in place using fibrin tissue glue (Fig. 7), which slightly reduces surgical time.^{12, 13}

Bush et al. suggested that the majority of periorcular grafts do not need sutured bolsters because this area is intensely irrigated and therefore the risk of graft displacement is low.¹⁴ The authors report excellent rates of graft uptake with low complication rates by applying a simple pressure pad over a silicone-based dressing for 48h, thereby saving time in suturing and bolster removal. Another option is to apply a pressure dressing of paraffin gauze, which can be molded to the shape of the area.⁷

A Frost suture is placed through lower eyelid, or an inverted Frost suture for upper eyelid grafts. This improves graft apposition and reduces premature contraction. The graft often looks dark at one week. The sutures are removed at the 7th post-operative day at both sites. The patient should avoid sun exposure and must massage the graft after two weeks for the next three months. Massaging helps to prevent thickening and contraction of the graft. Most changes in graft

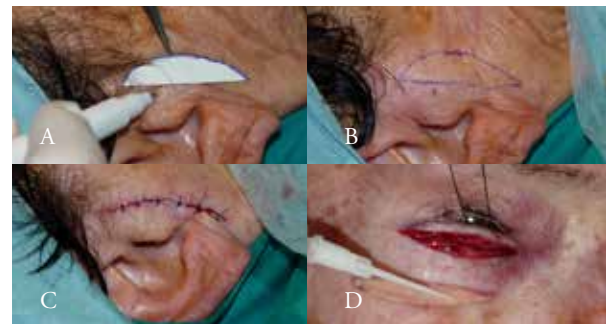

Figure 7: Use of a preauricular skin graft to treat a partial-thickness defect in the lower lid. A - Graft marked using a paper template; B - Donor site marked; C - Interrupted sutures closing the wound; D - Use of fibrin tissue glue to secure the graft.

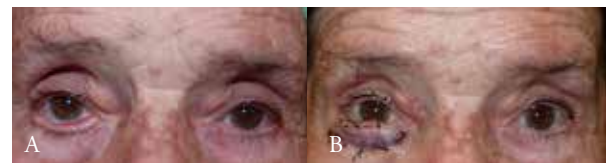


Figure 8: Use of a preauricular skin graft to correct a cicatricial ectropion of lower eyelid. A - Cicatricial ectropion of the right lower eyelid; B - One week after a preauricular skin graft (sutures in place).

size occur in the first month.⁸ Besides massaging, the graft can also be modulated, for example by intralesional steroid injections, silicone sheets and gel, dermabrasion and laser resurfacing.^{6, 15}

Host site complications in periorcular FTSG have been reported in approximately 15 % of cases.¹⁶ The most common complications are graft hypertrophy (45 %), graft contraction (29 %) and partial graft failure (13 %). Other problems are rare⁷ and include:

- subcutaneous hematoma – small incisions are made in the graft with a no. 11 blade to evacuate the hematoma, or preventatively at the end of the surgery;
- infection or suture dehiscence;
- graft necrosis: rare complication that can occur when the graft is too thick or the vascularization of the receptor bed is insufficient;
- pigmentation defects of the graft, such as hypopigmentation or hyperpigmentation (less common with upper eyelid grafts);
- post-operative lagophthalmos (if the rules of harvesting from the upper eyelid are not followed).

FTSGs have a better texture and color match than split-thickness skin grafts (STSGs) for the facial skin and they are a single-stage procedure. The disadvantages of FTSGs are a lower take rate than STSGs, the need for adequate granulation tissue before grafting in deep defects, less resistance to trauma than skin flaps and increased donor site morbidity.¹⁷

Split-thickness skin grafts

A STSGs contains epidermis and a portion of the dermis.

An STSG can be used when the skin defect is too large for an FTSG. Autologous STSG, described by Ollier in 1872 and Thiersch in 1886, is the most widely practiced form of tissue transplantation in plastic surgery today.

STSG is indicated for the skin coverage of large facial skin defects, as in the reconstruction of a large defect of the anterior lamella of the eyelid¹⁸ and exenterated socket.^{2, 19} Whether FTSG or STSG should be used for eyelid burn reconstruction is controversial. Falvey et al. uses postauricular and supraclavicular FTSG for upper and lower eyelid reconstruction and only uses STSG in sites where the skin has been burnt.⁵ Lille et al. later demonstrated that FTSGs reduce the incidence of ectropion in both the upper and lower eyelid in comparison to STSGs, probably because there is less graft contraction.⁴ The presence of more dermis means that FTSGs contract less than STSGs.¹¹ FTSGs from unaffected areas are generally recommended for both upper and lower eyelid grafting as they contract less than STSGs.^{11, 20} If viable skin is limited because of extensive burns then STSGs must be used.^{5, 20}

Common donor sites include the thigh, abdominal wall, buttock¹⁷ and the inner arm^{7, 19}. The thigh has thicker skin and is the site of choice, if available.⁷

A split skin knife (Fig. 9) or dermatome is needed (Fig. 10), which generally has a 5 cm width and an adjustable cutting thickness of 0.05 to 0.55 mm.^{7, 19} The thinner the graft, the greater the degree of contraction, but also the higher the likelihood of graft survival.

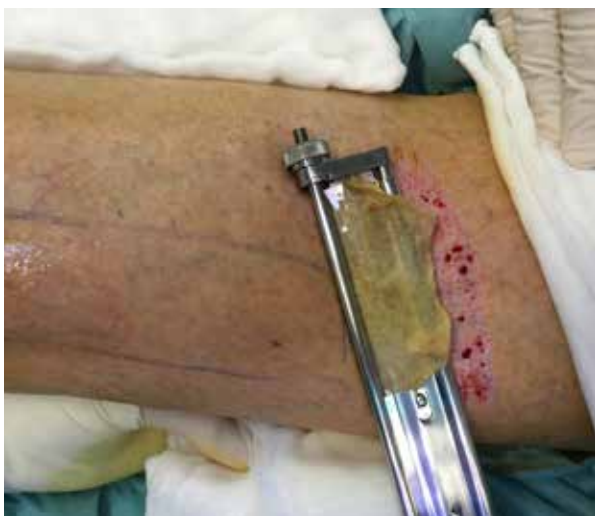

Figure 9: Harvesting of a split-thickness skin graft with a split skin knife (Courtesy of Horácio Zenha, MD).

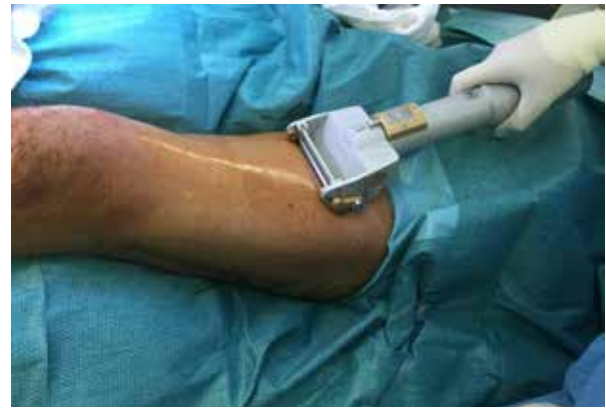

Figure 10: Taking a split skin graft with a dermatome (Courtesy of Horácio Zenha, MD).

The skin is cleaned with a bactericidal solution and allowed to dry. A thin layer of lubricating gel or mineral oil is applied to the donor site skin and to the blade of the dermatome. The dermatome is placed at approximately a 45-degree angle to the donor skin and started prior to contact with the skin. Gentle traction is applied to the donor site skin as the dermatome is smoothly applied with even pressure. This technique ensures the harvest of a good graft. Bleeding from the dermal capillary bed will be noted at the donor site.^{7, 21}

The donor site should be dressed (e.g. with alginate) and then a light pressure dressing is applied.²² The pressure dressing is usually removed after 7 to 10 days. Reepithelialization of the donor site occurs over the following 2 to 3 weeks.

STSGs may be meshed (Fig. 11) to increase their surface area (e.g. for large burns), however, this further thins the graft and may compromise the aesthetic result.²¹




Figure 11: Graft on a meshing plate (Courtesy of Horácio Zenha, MD).

The graft can be secured to the recipient site with staples, sutures or fibrin glue. The most important factor in ensuring the success of the STSG is graft immobilization and pressure over the site. The graft is immobilized for 5 to 7 days to prevent hematoma formation and shearing. A pressure dressing using a bolster or stent with tie-over sutures is helpful.

The main advantage of an STSG is that a large area of skin can be harvested because no skin closure is required. Compared to FTSGs, STSGs have a more complex harvesting procedure and the disadvantage of increased graft contraction. Additionally, STSGs have a poor color and texture match with the surrounding skin and give a lighter, more atrophic, and glistening appearance. For these reasons, and as previously mentioned, FTSGs are preferred and STSGs are rarely used in ophthalmic plastic surgery today.¹⁷

Tarsconjunctival Grafts

The use of a free tarsconjunctival (TC) graft for posterior lamella reconstruction of the lower eyelid was reported by Von Blaskovics in 1918²³ and Hughes later reported the use of contralateral upper eyelid TC graft for the same purpose.²⁴

TC grafts can be used for the reconstruction of eyelid defects (Fig. 12) and as spacers in cases of lower eyelid retraction (Fig. 13) or cicatricial entropion.^{6,25-27}

These grafts are relatively easy to harvest and provide the most similar tissue for reconstruction of the posterior lamella of the eyelid, compared to other autologous grafts.⁶ In relation to TC flaps, TC grafts offer a one-step non-occlusive alternative, with a special advantage for monocular patients, since the eye is open post operatively and there is no need for a secondary procedure to separate the eyelids.

Hawes et al. proposed guidelines for the use of TC grafts or Hughes TC flaps to repair lower eyelid defects.²⁸

The authors suggested that free TC grafts are preferred in most cases when the lower eyelid defect is from one third to three quarters of eyelid length, while Hughes TC flaps are better when the defects are larger or when poor wound healing can be anticipated (e.g. irradiated tissues). A preoperative evaluation of the everted upper eyelid is important to ensure that the tarsus has adequate height for grafting surgery.² If it does not, a hard palate graft or nasal septal chondromucosa tissue may be considered as alternatives.²⁹

TC grafts are harvested from the upper eyelid, with removal of part of the tarsus, the structure responsible for most of the eyelid's mechanical support. The average tarsal height of the upper eyelid is 10 mm in Caucasian and 8 mm in Asian patients.³⁰ Care must be taken to retain 4 mm of residual vertical tarsus to preserve the stability of the donor eyelid and its marginal vessels.³¹

In the case of a lower eyelid defect, the free TC graft

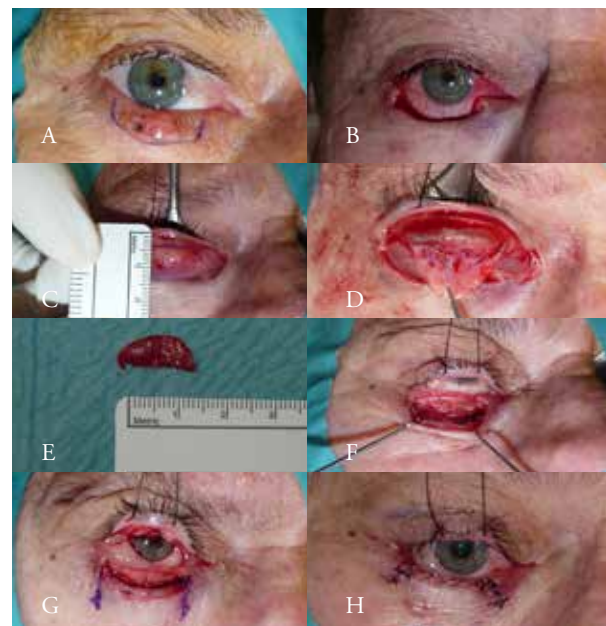

Figure 12: Tarsconjunctival graft for posterior lamella reconstruction. A - Basal cell carcinoma located on the central third of the right lower eyelid; B - Full-thickness excision of the lesion with 3 mm margins; C - Incision is marked 4 mm from the eyelid margin; D - Tarsconjunctival graft is dissected from the Müller and levator muscles; E - Free tarsconjunctival graft ready to be transplanted, with no need for preparation; F - Tarsconjunctival graft fixated in place; G - Myocutaneous advancement of the lower eyelid; H - Myocutaneous advancement sutured in place over the tarsconjunctival graft.

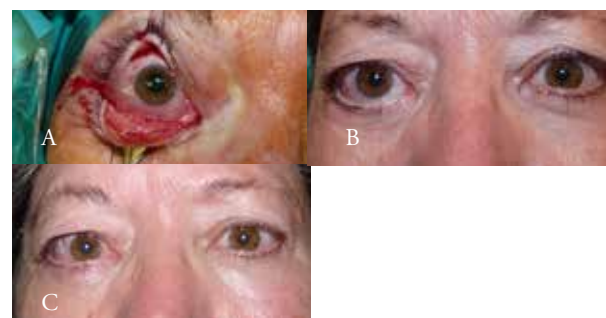


Figure 13: Tarsconjunctival graft used as a spacer of the lower eyelid. A - Tarsconjunctival graft sutured to the lower lid retractors inferiorly and to the inferior border of the tarsal plate superiorly; B - Right lower lid retraction; C - Six months after recession of the right lower lid retractors and the tarsconjunctival graft spacer.

can be harvested from the ipsilateral upper eyelid, while for an upper eyelid defect the contralateral upper eyelid is generally used.

The central region of the upper eyelid is injected with 2 % lidocaine with adrenaline. The eyelid is everted over a Desmarres retractor, with a 4/0 silk traction suture through the gray line. Anesthetic is injected subconjunctivally. The graft borders are outlined with a sterile marker pen, taking care to leave at least

4 mm of vertically remaining tarsal plate from the lid margin (Fig. 12C). The required width of the tarsus is measured, based on the reduced defect size, with a further 2 mm subtracted to avoid eyelid laxity after reconstruction.⁶ The borders of the graft are incised with a no. 15 blade and can then be dissected from the Müller muscle and levator attachments with blunt-tipped Westcott scissors. The vertical cuts are extended 2 mm superiorly through the conjunctiva. The TC graft is sutured to the receptor tarsoconjunctival layer, with 6/0 polyglactin sutures, without the need for prior thinning or preparation. The donor area is left to heal by secondary intention. A myocutaneous advancement is generally used for the reconstruction of the anterior lamella. Disadvantages of TC grafts include limitation of future reconstructive procedures by using the contralateral tarsoconjunctiva for harvesting.⁶ Free TC grafts have a limited area and can be used only for one eyelid, whereas hard palate and nasal septal chondromucosa can provide sufficient tissue for both eyelids.³² Complications at the upper eyelid donor site were reviewed in a large prospective study by Leibovitch et al.³³ Most were found to be mild or transient, with lash ptosis in 4 %, contour peaking observed in 2 %, and infection in 1 %. However, more serious complications of the donor site can occur, such as retraction or entropion of the upper eyelid and keratopathy, if the 4 mm tarsal margin rule is not respected.^{25, 27}

Hard Palate Grafts

The use of palatal mucosa for eyelid reconstruction after tumor excision was first described in 1985 by Siegel.³⁴ Today, besides its use as posterior lamellar graft in eyelid reconstruction,^{34, 35} palatal mucosa is also used for correction of eyelid cicatricial entropion,^{36, 37} eyelid retraction (Fig. 14),³⁷⁻⁴⁰ trichiasis,³⁶ facial palsy⁴⁰ and reconstruction of the contracted socket.^{2, 41-43} The use of palatal mucosa as a substitute for superior tarsal conjunctiva is controversial because its keratinized surface can cause irritation and keratopathy. However this side effect is temporary and is usually resolved after several weeks.²⁹ After grafting there is metaplasia to non-keratinized epithelium, thus limiting ocular irritation.⁴⁰ The palate is divided into two parts: the hard palate (anteriorly) and the soft palate (posteriorly). The graft should be obtained from the hard palate, behind the transverse ridges and up to the limit of the soft palate. The soft palate should be avoided to prevent contraction and complications in swallowing or fistulization to the oropharynx.⁴⁴ The median raphe should also be preserved for the proper healing of the palatal mucosa.

This surgery is best performed under general anesthesia with a Boyle-Davis retractor, although local anesthesia with sedation can also be used.

After marking the donor site (Fig. 15), local anesthesia (2 % lidocaine and adrenaline 1:100,000) is injected into the hard palate mucosa and mucoperiosteum, including the area around the greater palatine nerve and incisive foramina. Incision of the limits of the graft is made with a no. 15 blade or a disposable angle keratome. The graft is protected in a gauze swab moistened with saline and kept in a safe location. Careful hemostasis of the periosteum is performed with a bipolar forceps, but should not be aggressive due to the risk of necrosis of the underlying bone.

For the implantation of palatal mucosa in the lower eyelid, topical anesthesia is administered in the inferior conjunctival cul-de-sac. A 4/0 silk suture is passed through the gray line of the lower eyelid and the eyelid is everted over a Desmarres retractor.

The conjunctiva is incised 2 mm below and parallel to the inferior limit of the tarsus along all its extension, and the retractors are dissected.

Excess adipose tissue is removed from the posterior surface of the graft using Stevens scissors and the graft is sutured to the inferior border of the tarsal plate superiorly and to the conjunctiva and retractors inferiorly, with interrupted buried 6/0 polyglactin sutures, to prevent corneal lesions.

Oral antibiotic and analgesic treatment should be prescribed postoperatively, together with an antiseptic collutory for 2 to 3 weeks until the palatal mucosa has healed and antibiotic eye drops for 2 weeks. Food that is very hard, hot or seasoned should be avoided for the first 2 weeks. Custom-made acrylic stents can be used for greater comfort and to help cicatrization.

The most common complication of the donor site is hemorrhage, which occurs in 10% of cases^{37, 40} and can be prevented by custom-made acrylic stents.⁴⁵ Other less frequent complications are oronasal fistulas and candida infections.⁴³ Ocular complications include chronic mucous discharge from minor salivary glands located in the graft and transient corneal abrasion due to keratin.⁴⁰

A hard palate graft provides stiffness, thickness and flexibility to the eyelid and to the mucosal lining.^{34, 36, 37} The advantages of hard palate grafts over free tarsal grafts are the increased height of the graft and the avoidance of morbidity to the contralateral eye.²⁹ Another advantage is the low incidence of postoperative graft contraction. The disadvantages in relation to free tarsal grafts are the unfamiliar anatomy of the palate, the need for a second surgical field and the higher, although temporary, rate of keratopathy.²⁹

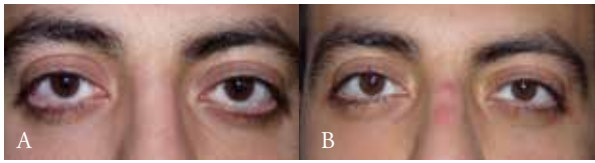


Figure 14: Hard palate graft used as a spacer of the lower eyelid. A – Bilateral lower lid retraction; B – Six months after hard palate grafting of the lower eyelids.

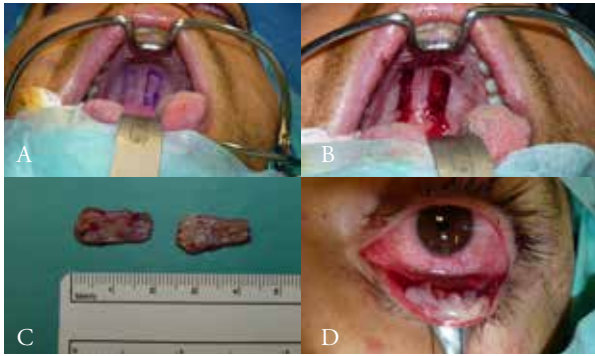


Figure 15: Harvesting of a hard palate graft. A – Incisions marked on the hard palate; B – After removal of the hard palate grafts; C - Hard palate grafts; D - Hard palate graft as a spacer of the lower lid.

Nasal Septum Chondromucosal Grafts

In 1962, Millard used a composite graft of cartilage and mucosa from the nasal septum for eyelid repair.⁴⁶ Nasal septum chondromucosa provides abundant material for composite grafts that can be used as eyelid spacers or for posterior lamella reconstruction.⁴⁷ They have been used successfully in severely cicatrized eyelid entropion in Stevens-Johnson syndrome and in total upper eyelid reconstruction after tumor excision and trauma.^{32, 48} The nasal mucosa provides a relatively well tolerated keratinized epithelium, whilst the septal cartilage provides a rigid component.⁶ Excessive rigidity and concavity of the cartilaginous component may, however, need molding and thinning before transplantation.⁴⁹

A nasal epistaxis tampon with local anesthetic and adrenaline or 5% cocaine is placed in each nostril for 10 or 5 min, respectively. A nasal endoscope is ideally used for the visualization of the nasal septum. If this is not available, exposure can be obtained using a rhinoscope and a headlight. Lidocaine with adrenaline is injected submucosally on the side of the nasal septum opposite to the extraction, until blanching is observed. This step helps both to separate the graft from the opposing mucosa and to prevent separation of the mucosa from the perichondrium within the graft.⁴⁷ An incision is made through the mucosa and septal cartilage.

The incision should be 1 cm above and parallel to the mucocutaneous junction;⁴⁷ leaving 0.8 mm of cartilage anteriorly to prevent collapse of the nasal strut.² The graft is separated from the contralateral mucoperichondrium with the blunt side of a Freer dissector (Fig. 16), which should be facilitated by the initial submucosal infiltration. The dissection should be broad, reaching the junction of the septal cartilage with the vomer and the perpendicular plate of the ethmoidal bone.⁴⁷ Vertical incisions are made perpendicular to the first incision, using blunt-tipped straight scissors. The graft is extracted after the final superior incision is carried out with a blade, and is carefully stored in a moistened swab. Nasal epistaxis tampons, coated with antibiotic ointment, are left in both nasal fossas until the following day.

The endonasal approach previously described has traditionally been used. However, for a better exposure of the area, a perialar incision can be used to reflect the ala to give a direct view of the nasal septum mucosa.⁵⁰ The incision is made on the alar nasal sulcus, which conceals the scar postoperatively. The preparation of the graft depends on its purpose (Fig. 17). When a new eyelid margin has to be created, a strip of cartilage of about 1 mm is removed from the border, permitting the relative excess of mucoperichondrium to cover the edge of the cartilage.⁴⁷ This step creates the new free eyelid border. When the graft is to be used as a posterior lamella spacer this step is not necessary, since the graft is placed between the tarsus and eyelid retractors and not at the margin.⁴⁷ When the graft is for upper eyelid reconstruction, it can be thinned or perforated with a no. 15 blade to reduce rigidity.⁴⁹ The curvature of the graft can be adapted by making vertical incisions on the surface to enable the graft to bend towards the globe.

Disadvantages of chondromucosal graft harvesting are that the technique for collecting the graft is initially challenging and executed in an area which is not routinely approached by the ophthalmologist. Complications of the donor site such as septal perforation should be avoided by careful manipulation of the remaining septal mucosa, and a meticulous suture in case of rupture. Corneal epitheliopathy may result from the rigidity of nasal septal chondromucosa, despite thinning and preparation. For this reason, some authors recommend that this type of graft is a preferable option for lower eyelid rather than upper eyelid reconstruction.⁶

Auricular Cartilage Grafts

In 1978, Zbylski et al. described the use of an autologous ear cartilage graft for the correction of

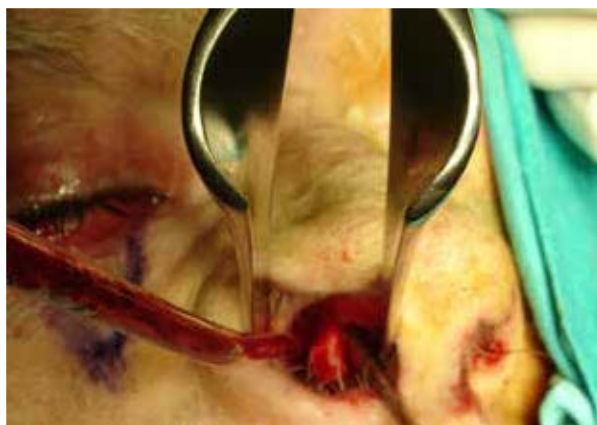

Figure 16: Separation of the nasal septum chondromucosa using a Freer dissector (Courtesy of Marco Sales-Sanz, MD, PhD).

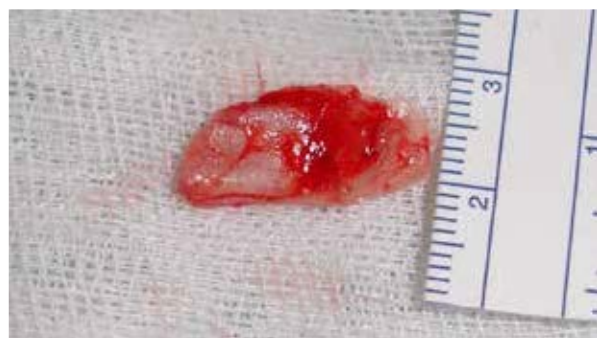

Figure 17: Nasal septum chondromucosa graft (Courtesy of Marco Sales-Sanz, MD, PhD).

lower lid ptosis in anophthalmic patients.⁵¹

Auricular cartilage grafts are most often used as lower eyelid spacers⁵² and in eyelid malposition in anophthalmic patients.⁵³⁻⁵⁵

They can be used in the upper eyelid for surgical treatment of paralytic lagophthalmos⁵⁶⁻⁵⁸ but are not generally used for full thickness upper eyelid reconstruction because they lack a mucosal covering. They can also be useful in tarsal replacement in lower and upper eyelid reconstruction (as part of a Cutler-Beard procedure) and in upper eyelid entropion surgery.² When applied to the upper eyelid, the graft should not be in direct contact with the ocular surface, due to the risk of corneal damage.

Auricular cartilage grafts have also been used to correct orbital floor fractures.⁵⁹ Composite skin and cartilage grafts have also been harvested from the helical rim.⁶⁰

The graft can be harvested from the concha^{51, 52, 61} or the scaphoid fossa^{53, 55} (Fig. 18) through an anterior curved incision. It can also be obtained from the posterior surface of the external ear. The anterior surface is more accessible, and the scar can be concealed by the auricular anti-helix (for the concha) and by the helix (for the scaphoid fossa).

The vertical height of the cartilage graft is determined

by the degree of preoperative lower scleral show (1-2 mm of height for each millimeter of lower scleral show). To harvest the graft, a mixture of 2 % lidocaine with adrenaline (1:100,000) is injected for vasoconstriction and hydrodissection of the auricular tissue. An incision is marked in the skin along the anterior rim of the helix. The skin is incised with a no. 15 blade and dissected with Stevens scissors to expose the area of cartilage needed for the graft. The size of the graft is drawn on the cartilage surface using a sterile marker. The incision is made with the no. 15 blade and completed with Stevens scissors. The graft is kept in a safe place, in a moistened swab. Hemostasis is performed with care at the donor site with a bipolar forceps. The skin of the auricular pavilion is sutured with 5/0 polypropylene or 5/0 silk, leaving long edges and tying them over a bolster of paraffin gauze. The auricular cartilage graft from the concha can be flattened with specific equipment, or with partial thickness vertical incisions to eliminate curvature.⁶¹ Cartilage obtained from the scaphoid fossa has a flat surface and does not need to be flattened further.⁵⁵ After the graft is cleaned of any overlying tissue, it is sutured to into its recipient bed with 5/0 polyglactin sutures.

Auricular cartilage can raise the retracted lower eyelid and expand the retracted conjunctival fornix, thus providing a strong support for prosthesis (Fig. 19). Auricular grafts have the disadvantages that they have a concave shape and lack a mucosal surface.

Complications are rare but can be serious: hematoma of the auricular pavilion (which can lead to necrosis and infection), and perichondritis (with necrosis and risk of perforation of the auricular cartilage).⁶¹

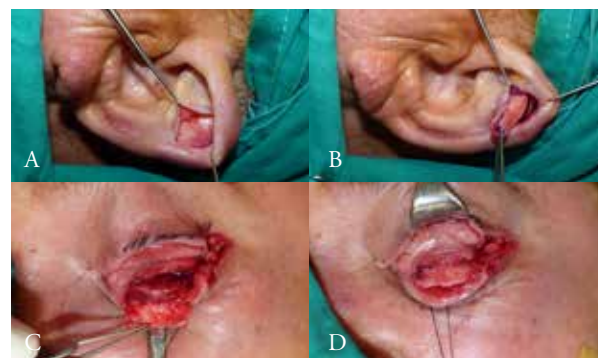


Figure 18: Auricular cartilage graft to correct eyelid malposition in anophthalmic patient. A – Incision in the scaphoid fossa; B – Harvesting of the auricular cartilage graft; C – Graft sutured to the tarsal plate superiorly; D – Graft sutured to the conjunctiva inferiorly.

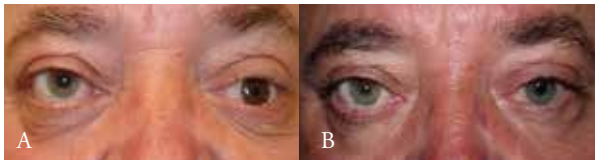


Figure 19: Use of an auricular cartilage graft in an anophthalmic patient.

A – Left lower eyelid malposition in an anophthalmic socket;
B – Six months after auricular cartilage grafting of the lower lid and exchange of the ocular prosthesis.

Oral Mucosal Grafts

An oral mucosal graft is often used during ophthalmic plastic surgeries for reconstruction of the eyelid,⁶²⁻⁶⁴ the fornix^{65, 66} and the socket^{67, 68}.

In the reconstruction of the lid margin in cicatricial ocular surface diseases, oral mucosal graft can be used to correct trichiasis, distichiasis, cicatricial entropion and symblepharon.^{62-64, 69-72}

It can also be used to replace the conjunctival surface, e.g. following tumor resection or in a recurrent pterygium. Split-thickness mucosal grafts can serve as an alternative to replace the bulbar conjunctiva with better cosmetic appearance, because it is thinner and looks less erythematous.⁷ However, since mucous membrane grafts can result in a beefy red appearance, amniotic membranes have been preferred.

Oral mucosa can be used instead of the Gunderson conjunctival flap in patients with corneal sensitivity who also require scleral shells. It can be especially useful in eyes with conjunctival scarring or a relatively large corneal diameter.⁷³

Buccal mucosa is frequently used for fornix reconstruction in contracted sockets (Fig. 20 and 21). Recently, Yoon et al documented the benefit of oral mucosa transplantation for exposed hydroxyapatite implants.⁷⁴ This type of graft can also replace the conjunctiva after evisceration, to suture the conjunctiva in a tension-free manner (Fig. 22).

Oral mucosa grafts can be obtained from the upper lip, lower lip or buccal mucosa. The lower lip is preferred since it has easier access (Fig. 23). After harvesting lip mucosa, no suture is necessary, and cicatrization occurs in 2 to 3 weeks. Up to 3.0 by 1.5 cm of lip mucosa can be collected;⁷⁵ when a larger area is needed, buccal mucosa is used (which has to be sutured).

The surgery is carried out under general anesthesia with the endotracheal tube secured to one side of the mouth so as to allow adequate exposure of the oral mucosa on the other side.

Before harvesting oral mucosa, the receptor bed should be prepared and measured. The limits of the graft should be marked on the mucosa, expanding the area by about 25 %, due to the possibility of graft retraction. The vermilion border of the lip should be

avoided anteriorly and the labial frenum, posteriorly. The parotid duct, located at the level of the second upper molar tooth, is to be avoided when harvesting buccal mucosa. The surgery can be performed under local or general anesthesia. In the latter case, the intubation tube should be placed as far as possible laterally, in order not to interfere with the surgical field. A traction suture of the inferior lip can be placed with a 4/0 silk suture.

A submucosal injection of 2 % lidocaine with 1:100,000 adrenaline is given to reduce hemorrhage and to aid graft dissection. Excision of a graft slightly larger than the defect is performed using a no. 15 blade, followed by dissection with small-toothed forceps and Westcott scissors (Fig. 23). Care must be taken to avoid graft perforation or a too deep dissection, to protect the accessory salivary glands⁷⁵ and the sensory innervation of the lip.² The graft should be kept in a safe location in a moist gauze. Bipolar cauterization is applied to the bleeding vessels. The labial mucosa donor site heals by secondary intention or can be closed by 5/0 polyglactin suture. When buccal mucosa is collected, interrupted 5/0 or 4/0 polyglactin sutures are used. The excess fat is cleaned from the stromal surface of the graft with curved Westcott scissors.

For reconstruction of the conjunctival fornix (Fig. 20), the graft is sutured with 3 deep U sutures through a silicone buckle (e.g. no. 240 for retinal detachment surgery), the periosteum and skin. When the graft is used for reconstruction of the anophthalmic socket, a rigid conformer of suitable size is placed in the cavity and when the graft is placed onto the globe a symblepharon ring is used.²

In reconstruction of the lid margin, the anterior lamella is split from the gray line, and the lid margin keratinization and tarsal scar is dissected and excised.⁷⁰ The skin muscle flap along with the margin lashes are resected and fixed 3 to 4 mm posterior to the tarsal margin onto the anterior tarsal surface using 3 or 4 stitches of 6/0 or 7/0 polyglactin. A continuous 8/0 polyglactin suture or fibrin glue is used to secure the stromal edge of the graft to the border of the tarsal defect.⁶⁹

Postoperatively, a soft diet and an antiseptic mouthwash should be prescribed for two weeks, until the donor site epithelization is complete.

Harvesting complications are rare with oral mucosa grafts. Lip retraction can occur when the limits of the inferior lip are not respected.⁷⁵

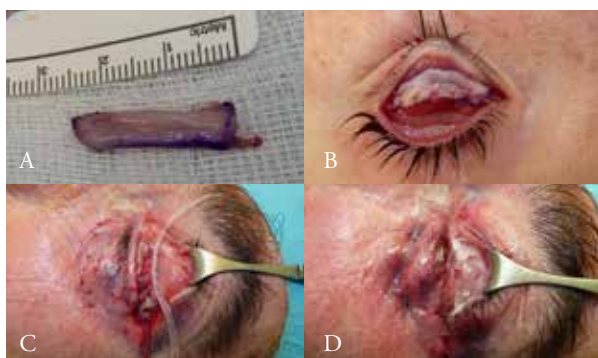

Figure 20: Use of an oral mucosal graft for lower fornix reconstruction in an anophthalmic socket. A – Oral mucosal graft; B – Oral mucosal graft inserted as a spacer into the posterior lid lamella; C – Fornix conformer with sutures in place; D – Sutures from the conformer tied to the skin over silicone strips.

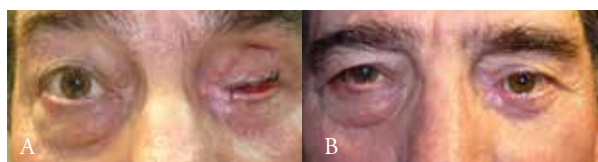


Figure 21: Anophthalmic socket with a shallow lower fornix. A – Left contracted socket; B – Six months after lower fornix reconstruction with an oral mucosal graft.

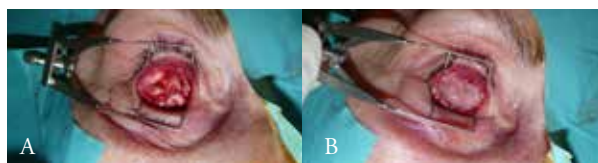


Figure 22: Oral mucosal graft used to suture the conjunctiva in a tension-free manner after evisceration. A – Anterior sclera closed after evisceration; suturing of the conjunctiva is not possible without tension; B – Oral mucosal graft sutured to Tenon's capsule and conjunctiva.

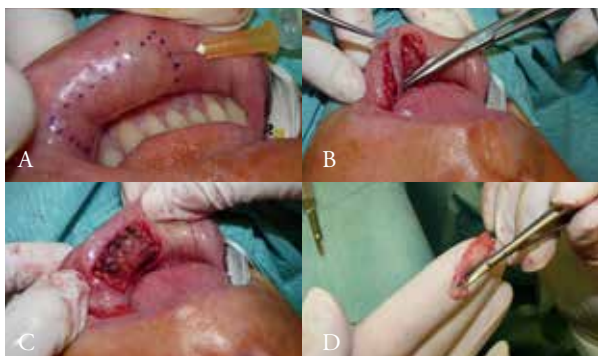


Figure 23: Harvesting of an oral mucosal graft. A – Incision marked on the mucosa of the lip and a submucosal injection of lidocaine with adrenaline; B – Graft cut in the plane of the mucosa; C – Donor site after the use of bipolar cautery; D – The graft is thinned by removal of excess fat.

Dermis Fat Grafts

Dermis fat grafts (DFGs) are autologous transplants consisting of de-epithelized epidermis with its adjacent subcutaneous fat tissue.⁷⁶ In ophthalmic plastic surgery, DFGs are predominantly used as orbital implants for volume augmentation in anophthalmic sockets in cases of enucleation, evisceration or subtotal exenteration. DFGs can also be used for eyelid filling in post-enucleation syndrome⁷⁷⁻⁷⁹ and for the treatment of orbital implant exposure.⁴³ DFG placement simultaneously with a secondary porous implant (using the rectus muscles as a host bed), has also been described for the treatment of exposed implants with conjunctival insufficiency.⁸⁰

Fat-only grafts were initially used as orbital implants, but this led to a marked volume loss of the tissue.⁸¹ In 1978, Smith et al. first described the use of DFGs for volume augmentation of the anophthalmic socket, finding that composite DFGs were less subject to atrophy.⁸² The dermal component of the graft supplies blood to the adipocytes and acts as a scaffold for the conjunctiva to grow over the surface of the implant. However, in the long term, an unpredictable amount of atrophy still remains, and therefore in developed countries synthetic implants are the primary implants of choice, while DFGs are reserved as secondary implants.⁸³ In countries where allogenic implants are not readily available, DGFs are often used for primary implantation.

The DFG can be harvested from the upper outer quadrant of the buttock, the lower lateral abdominal wall (preferably on the left side, to avoid confusion with an appendectomy scar) or from the periumbilical region.

The size of the graft is outlined on the donor skin with a central circumference and an external ellipse (Fig. 24). Lidocaine with adrenaline or saline is injected subcutaneously in the demarcated area to create a *peau d'orange* effect, as needed. The epidermis is superficially incised with a no. 15 or no. 10 blade and is dissected from the dermis layer, ideally as an entire layer. The dermis should appear pale, with multiple bleeding points and no fat should be visible. The dermis is incised and then cut with Stevens scissors. The fat layer is deeply transected to a depth of approximately 2-3 cm and removed with the overlying dermis. The donor site is closed with interrupted subcutaneous 4/0 polyglactin sutures and the skin is sutured with 4/0 polypropylene. The DFG is inserted into the receptor site with the dermal side showing, with the greatest volume of dermis and fat that can easily fit into the socket, but avoiding excessive pressure. If necessary, the fat can be trimmed. When possible, the extraocular muscles are sutured to the dermal component of the graft,

to optimize motility.⁸⁴ The conjunctiva can be closed or sutured to the borders of the dermal surface, over which it spontaneously expands over a period of 3 to 4 weeks (Fig. 25).² Suturing permits the preservation of the depth of the conjunctival fornices for posterior fitting of the prosthesis.⁸⁵ Ophthalmic ointment is placed on the surface, and a rigid conformer is inserted in the fornices. A temporary tarsorrhaphy is performed and a pressure dressing applied.

DFG grafts may also be used for eyelid filling in upper eyelid sulcus deformity in post-enucleation socket syndrome (Fig. 26). In this procedure, the graft is inserted so that the dermis is positioned against the periosteum, and sutured to this structure with 5/0 polyglactin sutures, taking care to avoid damaging the supraorbital neurovascular bundle and the trochlea.⁷⁷⁻⁷⁹

The fat component is positioned to occupy the anatomical space of the preaponeurotic fat, with a slight overcorrection to allow for some fat absorption.² The skin crease is reformed by sutures attached to the anterior part of levator muscle or aponeurosis.⁷⁷

In adults, the most common complication of DFG is graft shrinkage and secondary volume loss with enophthalmos, which may require surgical socket augmentation.⁸⁶ An atrophy of 25-35 % in the first 6 months is to be expected in primary implantation, and it is even greater in secondary implants due to the compromised vascular bed of the receptor site.⁸³

In contrast, in children DFG orbital implants appear to grow after implantation, even excessively at times, when surgical debulking is needed.^{84, 87}

Other possible complications of DFGs are the central ulceration of the graft, conjunctival granuloma, symblepharon, and keratinization or hair growth on the graft surface.^{83, 87, 88}

Nentwich et al. recently reviewed the results of a large series of DGFs as primary and secondary orbital implants. Primary DFGs had better results with good motility and fitting of the prosthesis in more than three quarters of cases. In secondary DFGs, motility was good in a third of cases, with a good fitting of the prosthesis in half. Major complications were necrosis of the transplant, which occurred in 3 % of primary and 5 % of secondary DFGs, and marked atrophy in 4 % of both primary and secondary DFGs.⁸⁵

Dermis Grafts

Dermis grafts can be used to correct lower eyelid retraction secondary to posterior lamella shortening, such as in thyroid orbitopathy, anophthalmia and cicatricial shortening of the fornices.⁸⁹ The dermis offers several advantages over other autologous material that can be used as eyelid spacers since it can be easily harvested, large amounts are available, postoperative recovery is less complicated than for hard palate grafts and

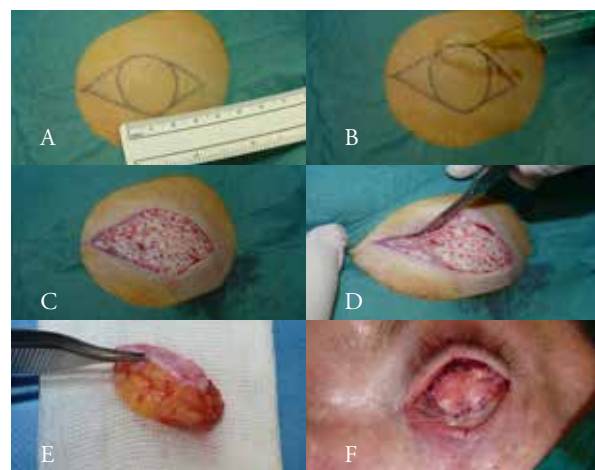


Figure 24: Harvesting of a dermis fat graft. A - Outline of graft on the donor site; B - Saline is injected into the skin to create a *peau d'orange* appearance; C - After removal of the epidermis, the dermis appears pale with multiple bleeding points and little if any fat exposed; D - Incision of dermis and fat; E - Dermis fat graft ready to be implanted; F - Dermis fat graft implanted into the anophthalmic socket.

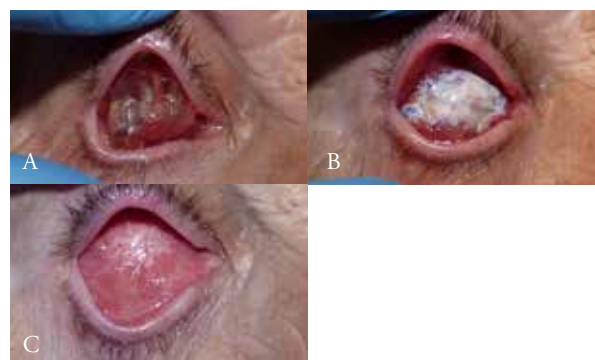

Figure 25: Use of a dermis fat graft as a secondary orbital implant. A - Preoperative appearance of extruded implant of the right socket; B - Postoperative appearance at 1 week; the graft is still pale and polyglactin sutures have not yet been absorbed; C - Postoperative appearance at 2 months. Conjunctivalization of the dermis is complete, and the graft has a healthy appearance.

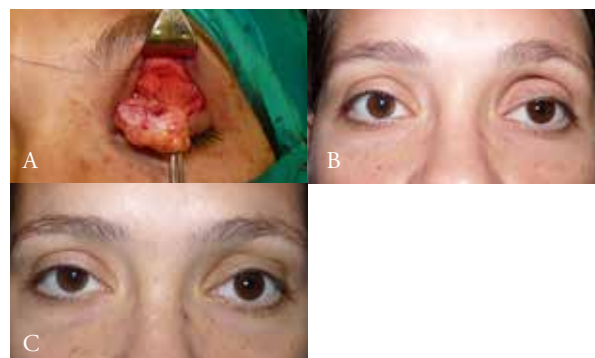


Figure 26: Use of dermis fat graft to correct a deep upper lid sulcus. A - Suturing of the dermal component of the graft to the orbital periosteum of orbital roof; B - Postenucleation socket syndrome with left upper eyelid sulcus deformity; C - Postoperative appearance after left upper eyelid filling with a dermis fat graft.

the graft has better thickness and flexibility than nasal or auricular cartilage grafts.⁸⁹ Dermis grafts of postauricular origin have been reported to be effective as posterior lamellar spacers since they have good rigidity and are sufficiently pliable to mold to the globe.⁹⁰

Brock et al. described the technique for harvesting postauricular dermis skin grafts in 2003.⁸⁹ The graft is outlined in the retroauricular space, with an ellipsoid shape whose long axis follows the postauricular crease. A mixture of topical anesthetic and adrenaline is injected in posterior auricular skin. The epidermis is removed *in situ* (for better stability), using scissors or a no. 15 blade. The dermis is incised with a no. 15 blade, as previously outlined by the marker pen, and removed with Westcott scissors. The retroauricular incision is closed with a 4/0 polypropylene suture.

Dermis grafts have also been used to treat areas of exposed orbital implants⁴³ (Fig. 27) and to assist in the closure of Tenon's capsule and conjunctiva after evisceration and enucleation.^{91, 92}

Vagefi et al. first described the use of autologous dermis grafts to replace the surface area lost by removal of the corneoscleral flap in primary evisceration and enucleation, with the aim of preserving the conjunctival fornices and to facilitate the placement of a larger implant.⁹¹ The dermis is harvested from the anterior suprailiac crest. In the case of an evisceration procedure, a corneal trephine is used to make a circular epidermal incision, after injecting local anesthetic. Since there is usually 25 % shrinkage of tissue when it is transplanted, a 14 mm diameter circle is used, as this will be close to the diameter of the cornea postoperatively. Westcott scissors are used to excise the epidermis from within the incised area. The dermis graft is placed over the closed sclera and is sutured to the edges of Tenon's capsule, while the conjunctiva is subsequently sutured to the graft's anterior surface. The use of autologous dermis grafts has also been reported to be effective in cases of secondary implantation.⁹²

In addition, split-thickness dermal grafts have been used in oculoplastic surgery. These partial thickness grafts have been used to reconstruct the exenterated orbit⁹³ and to allow a scleral shell to be fitted over a sensitive cornea, as an alternative to the Gunderson conjunctival flap in the presence of severe conjunctival scarring.⁹⁴

Complications of autologous dermis grafts include hair growth and keratinization, which can result in keratopathy if they are used to reconstruct the posterior lamella. To prevent keratin growth and remove hair follicles, the superficial dermis must undergo aggressive de-epithelisation to destroy the epithelial basement membrane and superficial hair follicles.⁹⁰

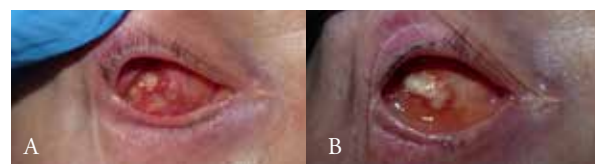


Figure 27: Use of a dermis patch graft to treat an exposed orbital implant. A - Area of exposure of about 5 mm of a hydroxyapatite implant; B - One month after a dermis graft patch.

Autogenous Fascia Lata Grafts

Payr was first to use fascia lata in the treatment of congenital ptosis in 1909, a technique that was popularized by Crawford in 1956.⁹⁵ The fascia lata graft is now considered the gold standard for frontalis suspension surgery to correct severe congenital upper eyelid ptosis (levator function of less than 4 mm – Fig. 28).⁹⁶⁻⁹⁹

Fascia lata has many other indications in ophthalmic plastic surgery:

- lower eyelid suspension in paralytic ectropion;¹⁰⁰⁻¹⁰³
- correction of senile ectropion^{7,104} and senile entropion;¹⁰⁵⁻¹⁰⁷
- cicatricial entropion¹⁰⁸ and cicatricial ectropion;¹⁰⁹
- to correct lid retraction secondary to thyroid ophthalmopathy;¹⁰⁸
- correction of paralytic lagophthalmos (elongation of the levator palpebrae superioris muscle using a fascia lata graft).⁵³

In anophthalmic cavities, fascia lata can be used to correct ectropion of the lower eyelid,^{101, 107, 110, 111} surface wrapping of orbital implants after enucleation (Fig. 29)^{112, 113} and as a patch graft in orbital implant extrusion.^{108, 114}

More recently fascia lata has been used to cover the gold weight in paralytic lagophthalmos patients.¹¹⁵ In children, 70 mm × 10 mm of fascia can be obtained before 3 years of age, and 100 mm × 20 mm after 5 years.^{116, 117}

The technique described by Crawford required a stripper, but its use is not essential.^{95, 96} Fascia lata can also be obtained using an endoscope.¹¹⁸

The surgical technique is described below, without the need of a stripper (Fig 30):

The leg is positioned with 90 to 120° of knee flexion to cause tension and for better exposure of the fascia. The location of the cutaneous incision is drawn with a sterile marker pen. The incision is 3 to 5 cm long, and is marked on an imaginary line from the lateral tibial condyle to the iliac crest to obtain the strongest fascia lata and avoid transecting the longitudinal fibres.¹¹⁹ The inferior border of the incision should be at least 4 cm from the knee, so as not to affect the epiphysis in children, nor zone of crossing fibers.^{96, 116} The incision site is injected subcutaneously with 2 %

lidocaine plus adrenaline. The skin incision is made with a no. 15 or no. 10 blade and the fascia (white glistening tissue) is exposed with malleable retractors. The subcutaneous areolar tissue is dissected with Stevens scissors. The graft size is marked on the fascia with a sterile marker pen. The fascia is cut and dissected from the underlying muscle fibers, and is kept safely in a moistened swab. A continuous suture can be applied near the borders of the fascia with 4/0 polyglactin to avoid herniation of the vastus lateralis muscle. The thigh wound is closed at the subcutaneous plane with 4/0 polyglactin, and the skin is closed with 4/0 polypropylene. A compressive dressing can be applied with a rubber ligature (from the knee to the groin area) and rest is recommended in the first postoperative week.

Before the fascia lata is used as a graft, the adherent fatty and fibrous tissue must be removed. To use the fascia for suspension of the upper eyelid to the frontalis muscle, for example, a fascial strip is created by cutting multiple Z-plasty incisions (3 mm wide) with a no. 15 blade (Fig. 31). The passage of the fascial strip is facilitated by the use of Wright's needle in the frontalis suspension or in the pre-tarsal plane for the lower eyelid fascial sling.

The advantages of using fascia lata are that it is an autologous and resistant material with a large number of applications. Its disadvantages are that surgical time is increased, two surgical sites are needed, and there are postoperative mobility restrictions and a leg scar.¹²⁰ Complications include local hematoma, herniation of the vastus lateralis muscle and an unaesthetic scar.^{2, 108} The scar can be reduced by using an endoscope¹¹⁸ or small incisions¹²¹.

Based on the publications by Crawford, the majority of authors avoid the use of fascia lata in infants under 3 years of age, due to the technical difficulty and because insufficient amounts of fascia lata are obtained.^{96, 122} In 2003 Leibovitch reported the use of fascia lata to correct congenital blepharoptosis in children under 3 years old as a feasible and effective treatment.¹¹⁷

Temporalis Fascia Grafts

The use of temporalis graft in the treatment of ptosis was described by Miller in 1980 and in 1983 by Neuhaus and Shore. The authors proposed autogenous temporalis fascia as an alternative to fascia lata, as suspension material for the correction of blepharoptosis with poor levator function.^{123, 124}

Temporalis fascia grafts show some advantages over fascia lata. Fascia temporalis harvesting can be performed in the same surgical field as for implantation, because of the proximity of the temporalis region to the orbito-palpebral region.¹²⁵

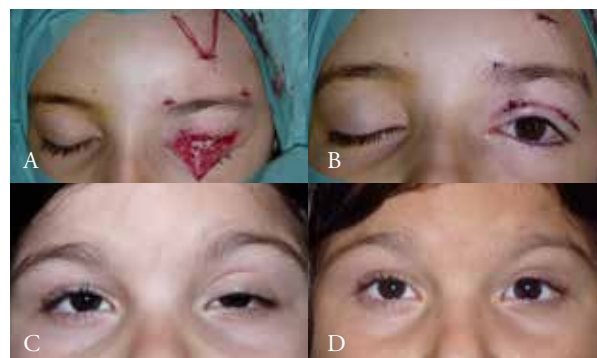

Figure 28: Left congenital eyelid ptosis corrected by upper eyelid suspension with fascia lata. A – Suture of the fascia lata to the tarsal plate; B – Immediate postoperative appearance; C – Left congenital eyelid ptosis; D – Six months after Fox brow suspension with fascia lata.

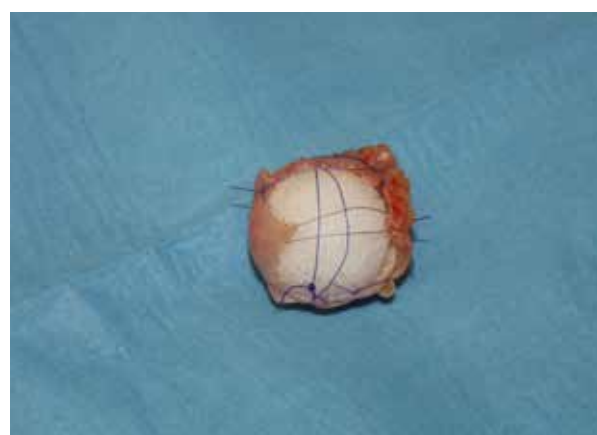


Figure 29: Fascia lata wrapping of a porous polyethylene orbital implant.

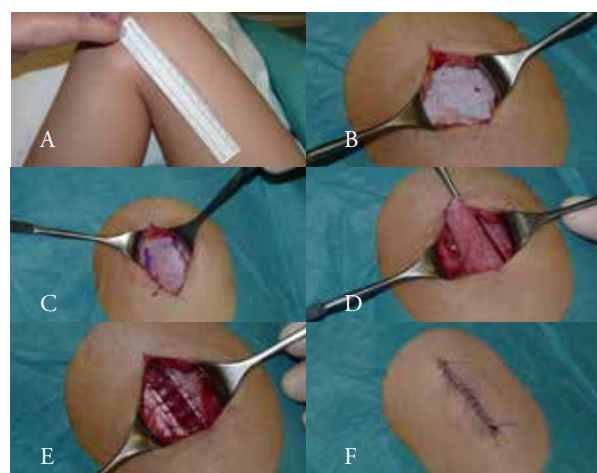

Figure 30: Harvesting of autogenous fascia lata. A – Skin incision marked above the knee in the line of the fascia lata; B – Fascia lata exposed; C – Marking of the incision on the fascia lata; D – Harvesting of the fascia lata; E – Suture of the fascia lata to prevent muscle herniation; F – Continuous interlocking suture to close the wound.

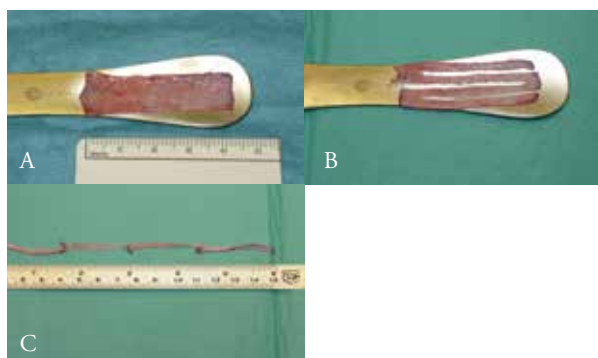


Figure 31: Creation of a pleated graft of fascia lata. A – Fascia lata graft of 4 by 1.2 cm; B – Multiple Z-plasties placed along the larger axis; C – Strip of fascia lata of 15 cm.

Donor site mobility of the temporal region is minimal and postoperative rest is not necessary, as it is after fascia lata harvesting.¹²⁶ In addition, scarring of the donor site is concealed by hair growth. However, as the temporalis fascia is slightly more fragile than fascia lata, especially in young children, its use is contraindicated under six years of age.¹²⁷

In addition to ptosis suspension material, as with fascia lata, fascia temporalis grafts can be used for eyelid reconstruction^{125, 128, 129}, the treatment of severe involutional ectropion, paralytic ectropion (Fig. 32) cicatricial ectropion¹³⁰, as a patch graft for exposed orbital implants¹³¹⁻¹³³, for surface wrapping of orbital implants and as draping in the reimplantation of extruded gold weights.¹³⁴

Trichotomy of the temporal region is optional. A supra auricular incision of 2 to 4 cm, is demarcated with a sterile pen posterior to the superficial temporal artery (located by palpation). The area is injected with lidocaine and adrenaline. The demarcated line is then incised with a no. 15 blade and soft tissues are dissected with Stevens scissors, and the superficial temporal fascia comes into view. The superficial fascia is opened to expose the deep temporal fascia, which is visible as white, glistening, fibrous tissue. Using Desmarres retractors to better expose the area, the temporalis fascia is incised with a no. 15 blade and separated from the underlying temporalis muscle using Stevens scissors. The wound is closed with subcutaneous 4/0 polyglactin sutures and the skin is closed with staples (removed 7 to 10 days later).

With a 2 cm incision, manipulation of the scalp allows a 2 by 4 cm rectangular graft to be excised.¹³⁵

The preparation of the graft depends on its purpose. To create a fascial strip from the rectangular graft, multiple Z-plasties 3 to 4 mm wide are placed along the vertical orientation of the fibers to form a pleated graft of up to 18 cm.¹³⁵

Complications include accidental bleeding from the superficial temporal artery during harvesting,

hematoma or infection at the donor site and localized alopecia.^{127, 136}

The temporalis fascia is an attractive alternative to fascia lata since only one operative field is required, there is minimal post-operative morbidity and there is no visible scar. The main disadvantage of temporalis fascia is its relative fragility compared to fascia lata in upper eyelid suspension surgery, which may result in under-correction of ptosis, especially in children.¹²⁷

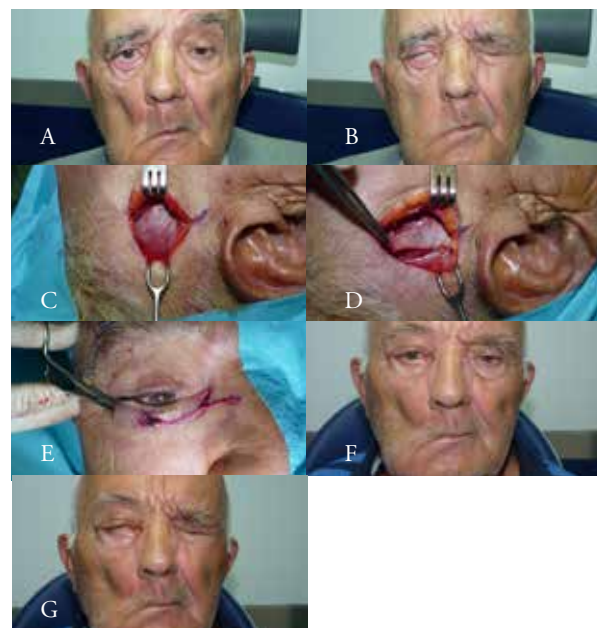


Figure 32: Use of a temporalis fascia sling in a patient with right facial palsy. A, B - Preoperative appearance with brow ptosis, paralytic ectropion of the lower eyelid and lagophthalmos; C - White, glistening appearance of the deep temporal fascia; D - Dissection of the graft from the underlying temporalis muscle; E - Temporalis fascia sling placed anteriorly to the tarsus of the lower lid, and anchored to the medial canthal tendon and to the lateral orbital periosteum to correct paralytic ectropion; F, G - Postoperative appearance after direct brow lift and correction of paralytic ectropion with a temporalis fascia sling.

Composite Eyelid Grafts

The composite eyelid graft is a useful technique for reconstructing a medium full thickness eyelid defect, usually after tumor resection.¹³⁷ It involves the excision of a full thickness pentagonal wedge from the donor eyelid, which is used to reconstruct the contralateral upper eyelid.¹³⁸ In an older patient, approximately one third of the upper eyelid can be removed without significant changes to appearance and function.²

Full thickness composite grafts were used at first, but were subsequently mostly abandoned due to insufficient graft vascularization and necrosis.^{6, 137, 139} Tarsomarginal grafts composed of posterior lamella and lid margin were later found to give better results.¹⁴⁰ Discarding the skin and orbicularis muscle

in the segment means that the vessels that grow into the graft have one less tissue plane to vascularize, thus improving the viability of the graft. The cosmetic result of the procedure can be very good, although the eyelashes rarely survive.^{2, 141} Cutaneomarginal grafts have also been described for the repair of eyelid defects of the anterior lamella following excision of neoplasms that spares the posterior lamella.¹⁴²

To harvest a tarsomarginal graft, 2% lidocaine with adrenaline is infiltrated in the upper eyelids of both eyes. Resection of a full thickness pentagonal wedge with direct closure is performed on the contralateral upper eyelid. The skin and orbicularis are removed from the graft with Westcott scissors. The graft is transplanted to the upper eyelid defect and the tarsal borders are sutured together with 5/0 polyglactin. For blood supply, local myocutaneous advancement over the graft is performed. Composite eyelid grafts can also be harvested from the lower eyelid by a similar technique, especially when there is significant lower lid laxity.¹⁴³

A modification of the composite eyelid graft technique was employed by Cannon et al. In this procedure, the skin and cilia of the graft can be preserved by dissecting the orbicularis muscle from the composite graft, and mobilizing the receptor orbicularis muscle between the tarsoconjunctiva and the skin components of the graft. The mobilization of the orbicularis oculi muscle provides a vascular bed for the grafts, and improves the mobility of the eyelid, thus enhancing the cosmetic appearance.¹⁴⁴ Of the 42 cases analyzed, cilia survival was recorded in 74 % of patients.¹³⁸

Conclusion

There are multiple anatomical locations that can be useful to harvest grafts for eyelid, periocular and anophthalmic socket reconstruction.

Skin grafts are used to correct an anterior lamellar defect. Full-thickness skin grafts contract very little and are much more commonly used in ophthalmic plastic surgery. They are preferable to split-thickness grafts whenever possible. In ophthalmic plastic surgery, most split-thickness skin grafts are used to line an exenterated socket. They have the advantages that large donor areas are available and graft take is better, but their disadvantage is increased graft contraction.

Autologous grafts for eyelid posterior lamellar reconstruction include tarsoconjunctival, hard palate chondromucosal, nasal chondromucosal, oral mucosal grafts, dermis grafts and tarsomarginal grafts.

Tarsoconjunctival grafts from the upper eyelid are excellent lamellar grafts or spacers, with a mucosal lining, when a small area is required.

Hard palate mucosa grafts are an excellent

replacement for tarsus and conjunctiva in eyelid reconstruction. The graft provides structural support as well as a mucosal surface, and contracts minimally. **Nasal septum chondromucosal grafts** are more rigid and are used mainly for the lower eyelid.

The **auricular cartilage** lacks mucosa and is consequently a better option for anophthalmic sockets.

Oral mucosal grafts are sometimes used to line a thicker flap in eyelid reconstruction, although they are commonly used for fornix reconstruction in anophthalmic sockets.

Dermis fat grafts are mostly used for volume augmentation in anophthalmic sockets, particularly as secondary orbital implants. They are also useful for eyelid filling in post-enucleation socket syndrome and as patch grafts for exposed implants.

Dermis grafts, besides being used as lower eyelid spacers, can also be used in the management of exposed orbital implants and for evisceration or enucleation, allowing the placement of a larger implant without tension on Tenon's capsule and the conjunctiva.

Fascia lata is the gold standard material for the suspension of the upper eyelid to the frontalis muscle, but it has many other indications in ophthalmic plastic surgery. The **temporalis fascia** has similar applications, with the advantage of leaving a concealed scar.

Composite eyelid grafts can be used for medium full thickness eyelid defects.

The choice of graft should be made in accordance with the pathology to be treated, the characteristics required, the accessibility of the location for harvesting and the surgeon's experience.

References

1. Mathes D, Butler P, Lee A. Transplantation in plastic surgery. In: Nelligan P, editor. Plastic Surgery. 3rd ed. Amsterdam: Elsevier; 2013. p. 814-40
2. Leatherbarrow, B. The Use of Autologous Grafts in Ophthalmic Surgery. In: Leatherbarrow, B. Oculoplastic Surgery. London: Taylor & Francis; 2002. p. 279-299
3. Custer PL, Harvey H. The arm as a skin graft donor site in eyelid reconstruction. Ophthal Plast Reconstr Surg 2001; 17(6): 427-30
4. Lille ST, Engrav LH, Caps MT, Orcutt JC, Mann R. Full-thickness grafting of acute eyelid burns should not be considered taboo. Plast Reconstr Surg 1999; 104(3): 637-45
5. Falvey MP, Brody GS. Secondary correction of the burned eyelid deformity. Plast Reconstr Surg 1978; 62(4): 564-70
6. Morley AM, deSousa JL, Selva D, Malhotra R. Techniques of upper eyelid reconstruction. Surv Ophthalmol 2010; 55 (3): 256-71
7. Tyers A, Collin J. Basic Techniques in ophthalmic plastic surgery. In: Colour Atlas of Ophthalmic Plastic Surgery. Oxford: Butterworth Heinemann. 1997; p. 37-60
8. Stephenson AJ, Griffiths RW, La Hausse-Brown TP. Patterns of contraction in human full thickness skin grafts. Br J Plast Surg 2000; 53(5): 397-402

9. Toledano Fernandez N, Moreno García-Rubio B, Riba García JS. Obtención de injerto cutáneo del párpado superior. In: Toledano Fernandez N, Martínez Grau G, Prada Sánchez C, Sanz Lopez A, Medel Jimenez R, Blanco Mateos G. Cirugía Palpebral y Periocular. LXXXV Ponencia Oficial de la Sociedad Española de Oftalmología; 2009. p. 107-110
10. Shorr N, Goldberg RA, McCann JD, Hoenig JA, Li TG. Upper eyelid skin grafting: an effective treatment for lagophthalmos following blepharoplasty. *Plast Reconstr Surg* 2003; 112(5): 1444-8
11. Malhotra R, Sheikh I, Dheansa B. The management of eyelid burns. *Surv Ophthalmol* 2009; 54(3): 356-71
12. Osborne SF, Eidsness RB, Carroll SC, Rosser PM. The use of fibrin tissue glue in the repair of cicatricial ectropion of the lower eyelid. *Ophthal Plast Reconstr Surg* 2010; 26(6): 409-12
13. Currie LJ, Sharpe JR, Martin R. The use of fibrin glue in skin grafts and tissue-engineered skin replacements: a review. *Plast Reconstr Surg* 2001; 108(6): 1713-26
14. Bush K, Cartmill BT, Parkin BT. Skin grafts in the periocular region without a bolstered dressing. *Orbit* 2012; 31(1): 59-62
15. Slomp AE, Kirschner RE. Keloids and scars: a review of keloids and scars, their pathogenesis, risk factors, and management. *Curr Opin Pediatr* 2006; 18(4): 396-402
16. Leibovitch I, Huilgol SC, Hsuan JD, Selva D. Incidence of host site complications in periocular full thickness skin grafts. *Br J Ophthalmol* 2005; 89(2): 219-22
17. Hom D, Tope W. Minimally Invasive Options and Skin Grafts for Cutaneous Reconstruction. In: Papel I, editor. *Facial Plastic and Reconstructive Surgery*. 2nd ed. Saint Charles, IL: Thieme. 2002; p. 512 – 527
18. Small RG, Sahl WJ. The use of split-thickness skin grafts for eyelid and facial reconstruction after Mohs' fresh-tissue surgery. *Ophthal Plast Reconstr Surg* 1989; 5(4): 266-70
19. Pffeifer M. Injertos Cutáneos de Espesor Parcial. In: Toledano Fernandez N, Martínez Grau G, Prada Sánchez C, Sanz Lopez A, Medel Jimenez R, Blanco Mateos G. Cirugía Palpebral y Periocular. LXXXV Ponencia Oficial de la Sociedad Española de Oftalmología; 2009. p. 103-105
20. Bouguila J et al. Management of eyelid burns. *J Fr Ophtalmol* 2011; 34(9): 655-62
21. Triana R Jr, Murakami C, Larrabee W Jr. Skin Grafts and Local Flaps. In: Papel I, editor. *Facial Plastic and Reconstructive Surgery*. 2nd ed. Saint Charles, IL: Thieme. 2002; p. 38-54
22. Geary PM, Tiernan E. Management of split skin graft donor sites--results of a national survey. *J Plast Reconstr Aesthet Surg* 2009; 62(12): 1677-83
23. Von Blaskovics L. Über die Totalplastik des unteren Lides. Bildung einer hinteren Lidplatte durch Transplantation eines Tarsus- und Bindehautstreifens aus dem Oberlide. *Zeitschrift für Augenheilkunde* 1918; 40: 222-227
24. Hughes WL. *Reconstructive Surgery of the Eyelids* 2nd ed. St Louis, Mo CV Mosby 1943; 83- 96
25. Toledano Fernandez N, Geol Saavedra I, Pujal Oregones J. Obtención de Injerto de Tarso-Conjuntiva. In: Toledano Fernandez N, Martínez Grau G, Prada Sánchez C, Sanz Lopez A, Medel Jimenez R, Blanco Mateos G. Cirugía Palpebral y Periocular. LXXXV Ponencia Oficial de la Sociedad Española de Oftalmología; 2009. p. 117-20
26. Stephenson CM, Brown BZ. The use of tarsus as a free autogenous graft in eyelid surgery. *Ophthal Plast Reconstr Surg* 1985; 1(1): 43-50
27. Ferri M, Oestreicher JH. Treatment of post-blefaroplasty lower lid retraction by free tarsoconjunctival grafting. *Orbit* 2002; 21: 281-8
28. Hawes MJ, Grove AS Jr, Hink EM. Comparison of free tarsoconjunctival grafts and Hughes tarsoconjunctival grafts for lower eyelid reconstruction. *Ophthal Plast Reconstr Surg* 2011; 27(3): 219-23
29. Leibovitch I, Malhotra R, Selva D. Hard palate and free tarsal grafts as posterior lamella substitutes in upper lid surgery. *Ophthalmology* 2006; 113(3): 489-96
30. Goold LA, Casson RJ, Selva D, Kakizaki H. Tarsal height. *Ophthalmology* 2009; 116(9): 1831-1831
31. McCord CD Jr, Nunery WR. Reconstructive Procedures of the Lower Eyelid and Outer Canthus. In: McCord CD Jr, *Oculoplastic Surgery*. New York: Raven Press; 1981. p. 194-198
32. deSousa JL, Leibovitch I, Malhotra R, O'Donnell B, Sullivan T, Selva D. Techniques and outcomes of total upper and lower eyelid reconstruction. *Arch Ophthalmol* 2007; 125(12): 1601-9
33. Leibovitch I, Selva D, Davis G, Ghabrial R. Donor site morbidity in free tarsal grafts. *Am J Ophthalmol* 2004; 138(3): 430-3
34. Siegel RJ. Palatal grafts for eyelid reconstruction. *Plast Reconstr Surg* 1985; 76(3): 411-4
35. Bartley GB, Kay PP. Posterior lamellar eyelid reconstruction with a hard palate mucosal graft. *Am J Ophthalmol* 1989; 107(6): 609-12
36. Silver B. The use of mucous membrane from the hard palate in the treatment of trichiasis and cicatricial entropion. *Ophthal Plast Reconstr Surg* 1986; 2(3): 129-31
37. Cohen MS, Shorr N. Eyelid reconstruction with hard palate mucosa grafts. *Ophthal Plast Reconstr Surg* 1992; 8(3): 183-95
38. Kersten RC, Kulwin DR, Levartovsky S, Tiradellis H, Tse DT. Management of lower-lid retraction with hard-palate mucosa grafting. *Arch Ophthalmol* 1990; 108(9): 1339-43
39. Patel BC, Patipa M, Anderson RL, McLeish W. Management of postblepharoplasty lower eyelid retraction with hard palate grafts and lateral tarsal strip. *Plast Reconstr Surg*. 1997; 99(5): 1251-60
40. Wearne MJ, Sandy C, Rose GE, Pitts J, Collin JR. Autogenous hard palate mucosa: the ideal lower eyelid spacer? *Br J Ophthalmol* 2001; 85(10): 1183-7
41. Yoshimura Y, Nakajima T, Yoneda K. Use of the palatal mucosal graft for reconstruction of the eye socket. *J Craniomaxillofac Surg* 1995; 23(1): 27-30
42. Holck DE, Foster JA, Dutton JJ, Dillon HD. Hard palate mucosal grafts in the treatment of the contracted socket. *Ophthal Plast Reconstr Surg* 1999; 15(3): 202-9
43. Kim YD, Goldberg RA, Shorr N, Steinsapir KD. Management of exposed hydroxyapatite orbital implants. *Ophthalmology* 1994; 101(10): 1709-15
44. Salcedo Casillas G, Plazola S. Obtención de Injerto de Mucosa Palatina. In: Toledano Fernandez N, Martínez Grau G, Prada Sánchez C, Sanz Lopez A, Medel Jimenez R, Blanco Mateos G. Cirugía Palpebral y Periocular. LXXXV Ponencia Oficial de la Sociedad Española de Oftalmología; 2009. p. 137-142
45. Mauriello JA Jr, Wasserman B, Allee S, Robinson L. Molded acrylic mouthguard to control bleeding at the hard palate graft site after eyelid reconstruction. *Am J Ophthalmol* 1992; 113(3): 342-4
46. Millard DR Jr. Eyelid repairs with a chondromucosal graft. *Plastic Reconstruct Surg* 1962; 30: 267-72
47. Sales Sanz M. Obtención de Injerto Compuesto Condromucoso Nasal. In: Toledano Fernandez N, Martínez Grau G, Prada Sánchez C, Sanz Lopez A, Medel Jimenez R, Blanco Mateos G. Cirugía Palpebral y Periocular. LXXXV Ponencia Oficial de la Sociedad Española de Oftalmología; 2009. p. 127-132
48. Callahan A. Correction of entropion from Stevens-Johnson syn-

- drome: use of nasal septum and mucosa for severely cicatrized eyelid entropion. *Arch Ophthalmol* 1976; 94(7): 1154-5
49. Mehrotra ON. Repairing defects of the lower eyelid with a free chondromucosal graft. *Plast Reconstr Surg* 1977; 59(5): 689-93
 50. Harashina T, Wakamatsu K, Kitazawa T. How to harvest a septal chondromucosal graft. *Ann Plast Surg* 1996; 37(6): 676-7
 51. Zbylski JR, LaRossa DD, Rich JD. Correction of lower eyelid ptosis in the anophthalmic orbit with an autogenous ear cartilage graft. *Plast Reconstr Surg* 1978; 61(2): 220-4
 52. Marks MW, Argenta LC, Friedman RJ, Hall JD. Conchal cartilage and composite grafts for correction of lower lid retraction. *Plast Reconstr Surg* 1989; 83(4): 629-35
 53. Baylis HI, Rosen N, Neuhaus RW. Obtaining auricular cartilage for reconstructive surgery. *Am J Ophthalmol* 1982; 93(6): 709-12
 54. Baylis HI, Perman KI, Fett DR, Sutcliffe RT. Autogenous auricular cartilage grafting for lower eyelid retraction. *Ophthalm Plast Reconstr Surg* 1985; 1(1): 23-7
 55. Smith RJ, Malet T. Auricular cartilage grafting to correct lower conjunctival fornix retraction and eyelid malposition in anophthalmic patients. *Ophthalm Plast Reconstr Surg* 2008; 24(1): 13-8
 56. Iñigo F, Chapa P, Jimenez Y, Arroyo O. Surgical treatment of lagophthalmos in facial palsy: ear cartilage graft for elongating the levator palpebrae muscle. *Br J Plast Surg* 1996; 49(7): 452-6
 57. Friedhofer H, Coltro PS, Vassiliadis AH, Nigro MV, Saito FL, Moura T, Faria JC, Ferreira MC. Alternative surgical treatment of paralytic lagophthalmos using autogenic cartilage grafts and canthopexy. *Ann Plast Surg*. 2013; 71(2): 135-9
 58. Pirrello R, D'Arpa S, Moschella F. Static treatment of paralytic lagophthalmos with autogenous tissues. *Aesthetic Plast Surg* 2007; 31(6): 725-31
 59. Le Faou T, Krastinova D. Reconstruction of orbital floor fractures using autologous materials. *Rv Stomatol Chir Maxillofac* 1997; 98 (4): 240-2
 60. Yildirim S, Gideroğlu K, Aköz T. Application of helical composite sandwich graft for eyelid reconstruction. *Ophthalm Plast Reconstr Surg* 2002; 18(4): 295-300
 61. Tazartes M, Plaza Mayor G. Obtención de Cartilago Auricular. In: Toledano Fernandez N, Martinez Grau G, Prada Sánchez C, Sanz Lopez A, Medel Jimenez R, Blanco Mateos G. *Cirugía Palpebral y Periocular*. LXXXV Ponencia Oficial de la Sociedad Española de Oftalmología; 2009. p. 121-125
 62. Leone CR Jr. Mucous membrane grafting for cicatricial entropion. *Ophthalmic Surg*. 1974; 5(2): 24-8
 63. McCord CD Jr, Chen WP. Tarsal polishing and mucous membrane grafting for cicatricial entropion, trichiasis and epidermalization. *Ophthalmic Surg*. 1983; 14(12): 1021-5
 64. Shore JW, Foster CS, Westfall CT, Rubin PA. Results of buccal mucosal grafting for patients with medically controlled ocular cicatricial pemphigoid. *Ophthalmology* 1992; 99(3): 383-95
 65. Kheirkhah A, Blanco G, Casas V, Hayashida Y, Raju VK, Tseng SC. Surgical strategies for fornix reconstruction based on symblepharon severity. *Am J Ophthalmol*. 2008; 146(2): 266-275
 66. Karesh JW, Putterman AM. Reconstruction of the partially contracted ocular socket or fornix. *Arch Ophthalmol* 1988; 106(4): 552-6
 67. Klein M, Menneking H, Bier J. Reconstruction of the contracted ocular socket with free full-thickness mucosa graft. *Int J Oral Maxillofac Surg* 2000; 29(2): 96-8
 68. Bowen Jones EJ, Nunes E. The outcome of oral mucosal grafts to the orbit: a three-and-a-half-year study. *Br J Plast Surg* 2002; 55(2): 100-4
 69. Fu Y, Liu J, Tseng SC. Oral mucosal graft to correct lid margin pathologic features in cicatricial ocular surface diseases. *Am J Ophthalmol* 2011; 152(4): 600-608
 70. Koreen IV, Taich A, Elner VM. Anterior lamellar recession with buccal mucous membrane grafting for cicatricial entropion. *Ophthalm Plast Reconstr Surg* 2009; 25(3): 180-4
 71. Iyer G, Pillai VS, Srinivasan B, Guruswami S, Padmanabhan P. Mucous membrane grafting for lid margin keratinisation in Stevens-Johnson syndrome: results. *Cornea* 2010; 29(2): 146-51
 72. Goldberg RA, Joshi AR, Mc Cann JD, Shorr N. Management of severe cicatricial entropion using shared mucosal graft. *Arch Ophthalmol* 1999; 117: 1255-59
 73. Ma'luf RN, Awwad ST. Mucous membrane graft versus Gunderson conjunctival flap for fitting a scleral shell over a sensitive cornea. *Ophthalm Plast Reconstr Surg* 2005; 21(5): 356-8
 74. Yoon KC, Yang Y, Jeong IY, Kook MS. Buccal mucosal graft for hydroxyapatite orbital implant exposure. *Jpn J Ophthalmol* 2011; 55(3): 318-20
 75. Toledano Fernandez N, García Sáenz S. Obtención de Injerto de Mucosa Labial. In: Toledano Fernandez N, Martinez Grau G, Prada Sánchez C, Sanz Lopez A, Medel Jimenez R, Blanco Mateos G. *Cirugía Palpebral y Periocular*. LXXXV Ponencia Oficial de la Sociedad Española de Oftalmología; 2009. p. 133-136
 76. Hintschich C. Dermis Fat Implants. In: Guthoff R, Katowitz, James A. *Oculoplastics and Orbit. Essentials in Ophthalmology*. Springer Berlin Heidelberg; 2007. p. 181-194
 77. Rose GE, Collin R. Dermofat grafts to the extraconal orbital space. *Br J Ophthalmol* 1992; 76(7): 408-11
 78. Leone CR Jr. Correction of superior sulcus defects after enucleation. *Adv Ophthalmic Plast Reconstr Surg* 1990; 8: 209-13.
 79. Van Gemert JV, Leone CR. Correction of a deep superior sulcus with dermis-fat implantation. *Archives of ophthalmology* 1986; 104:4: 604-7
 80. Lee BJ, Lewis CD, Perry JD. Exposed porous orbital implants treated with simultaneous secondary implant and dermis fat graft. *Ophthalm Plast Reconstr Surg* 2010; 26(4): 273-6
 81. Barraquer J. Enucleation with placement of fat graft in Tenon's capsule. *Adv Ophthalmic Plast Reconstr Surg* 1990; 8: 149-50
 82. Smith B, Petrelli R. Dermis-fat graft as a movable implant within the muscle cone. *Am J Ophthalmol* 1978; 85(1): 62-6
 83. Adenis JP, Robert PY, Bertin P. Greffe Dermo-Graisseuse. In: Adenis JP, Morax S. *Pathologie orbitopalpebrale*. Paris: Masson; 1998. p. 423-48
 84. Mitchell KT, Hollsten DA, White WL, O'Hara MA. The autogenous dermis-fat orbital implant in children. *J AAPOS* 2001; 5(6): 367-9
 85. Nentwich MM, Schebitz-Walter K, Hirneiss C, Hintschich C. Dermis fat grafts as primary and secondary orbital implants. *Orbit* 2014; 33(1): 33-8
 86. Shore JW, McCord CD Jr, Bergin DJ, Dittmar SJ, Maiorca JP, Burks WR. Management of complications following dermis-fat grafting for anophthalmic socket reconstruction. *Ophthalmology* 1985; 92(10): 1342-50
 87. Tarantini A, Hintschich C. Primary dermis-fat grafting in children. *Orbit* 2008; 27(5): 363-9
 88. Bosniak SL. Complications of dermis-fat orbital implantation. *Adv Ophthalmic Plast Reconstr Surg* 1990; 8: 170-81
 89. Brock WD, Bearden W, Tann T 3rd, Long JA. Autologous dermis skin grafts in lower eyelid reconstruction. *Ophthalm Plast Reconstr Surg* 2003; 19(5): 394-7
 90. Yoon MK, McCulley TJ. Autogenous dermal grafts as posterior lamellar spacers in the management of lower eyelid retraction. *Ophthalm Plast Reconstr Surg* 2014; 30(1): 64-8

91. Vagefi M et al. Autologous dermis graft at the time of evisceration or enucleation. *Br J Ophthalmol* 2007; 91(11): 1528-1531
92. Bengoa-González A, Dolores Lago-Llinás M, Martín-Clavijo A, Ling-Tan S. The use of autologous dermis grafts for the reconstruction of the anophthalmic socket. *Orbit* 2010; 29(4): 183-9
93. Mauriello JA Jr, Han KH, Wolfe R. Use of autogenous split-thickness dermal graft for reconstruction of the lining of the exenterated orbit. *Am J Ophthalmol* 1985; 100(3): 465-7
94. Khan JA. Dermal graft. Alternative to Gunderson flap allows fitting scleral shell over sensitive cornea. *Ophthalm Plast Reconstr Surg* 1990; 6(4): 260-4
95. Crawford JS. Repair of ptosis using frontalis muscle and fascia lata. *Trans Am Acad Ophthalmol Otolaryngol* 1956; 60: 672-8
96. Crawford JS. Repair of ptosis using frontalis muscle and fascia lata. A 20 year review. *Ophthalmologic Surg* 1977; 8: 31-40
97. Morax S, Benia L. Suspension of the eyelid to the frontal muscle in the surgery of ptosis. Technique and indications. *J Fr Ophthalmol*. 1986; 9(6-7): 461-70
98. Hague S, Collin R. Blepharoplasty and ptosis. *Curr Opin Ophthalmol*. 1994; 5(5): 67-73
99. Wasserman BN, Sprunger DT, Helveston EM. Comparison of materials used in frontalis suspension. *Arch Ophthalmol*. 2001; 119(5): 687-91
100. Blair VP. Operative correction of facial palsy. *South Med J* 1926; 19: 116
101. Wiggs EO, Guibor P, Hecht SD, Wolfley DE. Surgical treatment of the denervated or sagging lower lid. *Ophthalmology* 1982; 89(5): 428-32
102. Iyengar SS, Burnstine MA. Treatment of symptomatic facial nerve paralysis with lower eyelid fascia lata suspension. *Plast Reconstr Surg*. 2012; 129(3): 569-571
103. Sendul SY, et al. Effectiveness of the Lower Eyelid Suspension Using Fascia Lata Graft for the Treatment of Lagophthalmos due to Facial Paralysis. *Biomed Res Int*. 2015; 759-793
104. Brenizer AG. Skin and fascia grafting. *Am J Surg* 1940; 47: 265-79
105. Elliot RA. Correction of senile entropion of the lower lid with fascia lata graft. *Plast Reconstr Surg* 1962; 29: 698-701
106. Rizk SN, Mishra AK. Surgical correction of senile entropion of the lower lid with fascia lata sling. *Br J Ophthalmol*. 1979; 63(2): 117-9
107. Rizk SN, Mishra AK. The use of autogenous fascia lata to correct lid and orbital deformities. *Trans Am Ophthalmol Soc*. 1981; 79:227-42
108. Flanagan JC, Campbell CB. The use of autogenous fascia lata to correct lid and orbital deformities. *Trans Am Ophthalmol Soc*. 1981; 79: 227-42
109. Qian JG, Wang XJ, Wu Y. Severe cicatricial ectropion: repair with a large advancement flap and autologous fascia sling. *J Plast Reconstr Aesthet Surg*. 2006; 59(8): 878-81
110. Vitnes LM, Iverson RE, Laub DR. The anophthalmic orbit. Surgical correction of lower eyelid ptosis. *Plast Reconstr Surg* 1973; 52: 346-51
111. Nolan WB 3rd, Vistnes LM. Correction of lower eyelid ptosis in the anophthalmic orbit: a long-term follow-up. *Plast Reconstr Surg* 1983; 72(3): 289-93
112. Levine MR. Extruding orbital implant: prevention and treatment. *Ann Ophthalmol* 1980; 12(12): 1384-6
113. Moshfeghi DM, Moshfeghi AA, Finger PT. Enucleation. *Surv Ophthalmol* 2000; 44(4): 277-301
114. Oberfeld S, Levine MR. Diagnosis and treatment of complications of enucleation and orbital implant surgery. *Adv Ophthalmic Plast Reconstr Surg* 1990; 8: 107-17
115. Egemen O, Ozkaya O, Uscetin I, Akan M. Covering the gold weight with fascia lata graft in paralytic lagophthalmos patients. *Br J Oral Maxillofac Surg*. 2012; 50(4): 369-72
116. Pfeiffer M, Toledano Fernandez N, Genol Saavedra I. Obtención de Fascia Lata Autóloga. In: Toledano Fernandez N, Martinez Grau G, Prada Sánchez C, Sanz Lopez A, Medel Jimenez R, Blanco Mateos G. *Cirugía Palpebral y Periocular*. LXXXV Ponencia Oficial de la Sociedad Española de Oftalmología; 2009. p. 143-149
117. Leibovitch I, Leibovitch L, Dray JP. Long-term results of frontalis suspension using autogenous fascia lata for congenital ptosis in children under 3 years of age. *Am J Ophthalmol* 2003; 136(5): 866-71
118. Malhotra R, Selva D, Olver JM. Endoscopic harvesting of autogenous fascia lata. *Ophthalm Plast Reconstr Surg* 2007; 23(5): 372-5
119. Jordan DR, Anderson RL. Obtaining fascia lata. *Arch Ophthalmol* 1987; 105(8): 1139-40
120. Wheatcroft SM, Vardy SJ, Tyers AG. Complications of fascia lata harvesting for ptosis surgery. *Br J Ophthalmol* 1997; 81(7): 581-3
121. Kashkouli MB. A novel technique for small-incision fascia lata harvesting without a fasciatome for the frontalis suspension procedure. *Orbit* 2007; 26(3): 203-6
122. Beyer CK, Albert DM. The use and fate of fascia lata and sclera in ophthalmic plastic and reconstructive surgery. *Ophthalmology* 1981; 88(9): 869-86
123. Miller TA. Temporalis fascial grafts. *Plast Reconstr Surg* 1980; 65(2): 236-7
124. Neuhaus RW, Shorr N: Use of temporalis fascia and muscle as an autograft. *Arch Ophthalmol* 1983; 101: 262-264
125. Holt JE, Holt GR, van Kirk M. Use of temporalis fascia in eyelid reconstruction. *Ophthalmology* 1984; 91(1): 89-93
126. Dray JP, Turut P. Traitement chirurgical du ptosis majeur par suspension frontale avec l'aponévrose temporale. *J Fr Ophthalmol* 1992; 15: 544-5
127. Morax S, Herdan ML, Hurbli T, Cadion D. Temporalis fascia suspension in the treatment of ptosis. *Orbit* 1991; 10: 193-201
128. Copcu E, Sivrioglu N. The new reconstruction technique in the treatment of the skin cancers located on the eyelid: Posterior temporalis fascia composite graft. *Int Semin Surg Oncol* 2004; 11;1(1):5
129. Copcu E, Sivrioglu N, Koc B, Er S. Reconstruction of the lateral canthus with trilobed skin flap and temporalis fascia graft. *Plast Reconstr Surg* 2006; 117(7): 2514-6
130. De la Torre J, Simpson RL, Tenenhaus M, Bourhill I. Using lower eyelid fascial slings for recalcitrant burn ectropion. *Ann Plast Surg* 2001; 46(6): 621-4
131. Sagoo MS, Olver JM. Autogenous temporalis fascia patch graft for porous polyethylene (Medpor) sphere orbital implant exposure. *Br J Ophthalmol* 2004; 88(7): 942-6
132. Pelletier CR, Jordan DR, Gilbert SM. Use of temporalis fascia for exposed hydroxyapatite orbital implants. *Ophthalm Plast Reconstr Surg* 1998; 14(3): 198-203.
133. Wiggs EO, Becker BB. Extrusion of enucleation implants: treatment with secondary implants and autogenous temporalis fascia or fascia lata patch grafts. *Ophthalmic Surg* 1992; 23(7): 472-6
134. Thomas DA, Khalifa YM. Temporalis fascia in the management of gold eyelid weight extrusion. *Ophthalm Plast Reconstr Surg* 2005; 21(2): 153-5
135. Bladen, Moosajee M, Tumuluri K, Olver JM. The use of a pleated strip of autogenous temporalis fascia graft for frontalis suspension in recurrent poor levator function ptosis in adult patients. *Orbit* 2012; 31(2): 114-8
136. Ellis DS, Toth BA, Stewart WB. Temporoparietal fascial flap for orbital and eyelid reconstruction. *Plast Reconstr Surg* 1992; 89(4): 606-12

137. Callahan A. The free composite lid graft. *AMA Arch Ophthalmol* 1951; 45: 539-45
138. Cannon PS, Madge SN, Kakizaki H, Selva D. Composite grafts in eyelid reconstruction: the complications and outcomes. *Br J Ophthalmol* 2011; 95(9): 1268-71
139. Fox SA. Autogenous free full-thickness eyelid grafts. *Am J Ophthalmol* 1969; 67(6): 941-5
140. Putterman AM. Viable composite grafting in eyelid reconstruction. *Am J Ophthalmol* 1978; 85(2): 237-41
141. Werner MS, Olson JJ, Putterman AM. Composite grafting for eyelid reconstruction. *Am J Ophthalmol* 1993; 116: 11-16
142. O'Donnell BA. The cutaneomarginal eyelid graft. *Clin Experiment Ophthalmol* 2002; 30(2): 136-9
143. Hoyama E, Limawararut V, Malhotra R, Muecke J, Selva D. Tarsomarginal graft in upper eyelid coloboma repair. *J AAPOS* 2007; 11(5): 499-501
144. Doxanas MT. Orbicularis muscle mobilisation in eyelid reconstruction. *Arch Ophthalmol* 1986; 104: 910-14

EYELIDS

- 
- 8 Ectropion
 - 9 Entropion
 - 10 Blepharoptosis
 - 11 Trichiasis
 - 12 Facial Palsy and Lagophthalmos
 - 13 Eyelid Tumors
 - 14 Superior Eyelid Reconstruction
 - 15 Inferior Eyelid Reconstruction
 - 16 Cosmetic Blepharoplasty
 - 17 Periorbital Rejuvenation

8. Ectropion

Sara Ribeiro, João Aragão Rodrigues, Maria Shekhovtsova,
Antonio Augusto Velasco e Cruz

Introduction

Ectropion is an abnormal eversion (outward turning) of the lid margin. This lid malposition can affect the lower or upper lid and leads to cosmetic and functional deficits, such as corneal exposure, tearing, keratinization of the palpebral conjunctiva, chronic conjunctivitis, and in rare cases even visual loss. It can be medial or lacrimal, lateral or complete (involving the entire eyelid). For lower eyelid ectropion, the term tarsal ectropion means the complete rotation of the tarsus^{1, 2}.

Ectropion is usually classified as congenital, involutional, cicatricial, mechanical and paralytic.^{1, 2} These categories are not absolute and some cases fit

into more than one. For instance, four-lid ectropion in a newborn with lamellar ichthyosis can be regarded as congenital or cicatricial ectropion. Similarly, ectropion in a child born with an orbital cyst that mechanically pushes the lid margin, may be seen, and congenital facial palsies may cause congenital paralytic ectropion.

From a therapeutic perspective, rather than focusing on the clinical categories it is more useful to look at the underlying pathophysiological mechanism (Table 1), because the correct identification of the anatomic abnormality associated with lid margin malposition is the key to a successful surgical procedure.

Type of Ectropion	Affected Lid(s)	Pathophysiologic Mechanism
Congenital	UL, LL	Tarsus anomaly (absence and atrophy) Severe eyelid edema after birth trauma Eyelid skin retraction (cicatricial) Microphthalmus with orbital cyst (mechanical)
Involutional	LL	Horizontal lid laxity Lateral and/or medial canthal tendon laxity Tarsal and orbital septum atrophy Thinning of skin and subcutaneous tissues Senile enophthalmia Dehiscence, elongation or desinsertion of the retractors
Cicatricial	UL,LL	Shortening of the anterior lamella of the lid
Paralytic	LL	Orbicularis muscle atony
Mechanical	LL	Lesions or inflammatory disorders which cause the lid margin to roll out

Table 1 - Type of ectropion, affected lids and pathophysiologic mechanism. UL, upper lid. LL, lower lid.

Congenital Ectropion

The designation “congenital ectropion” is used for a variety of conditions with distinct pathophysiological mechanisms. A typical example is what is known as congenital upper eyelid eversion. This rare lid abnormality, usually present at birth, is characterized by eversion of both upper lid margins with prolapsed chemotic conjunctiva. It is typically symmetrical but some degree of asymmetry is not uncommon. Several factors have been implicated in its pathophysiology, including orbicularis hypotonia, birth trauma, vertical elongation of the posterior lamella, and failure of the orbital septum to fuse with the levator aponeurosis, with adipose tissue interposition. Most cases are not associated with ocular or general abnormalities. However, the incidence appears to be higher in Down syndrome. This particular form of upper lid ectropion responds well to conservative treatment such as topical ointments and lubricants, patching or temporary tarsorrhaphy.³⁻⁶

A totally different situation is that of newborns with severe forms of lamellar ichthyosis. In these patients eyelid eversion is due to severe skin contraction. All four lids may undergo a severe form of cicatricial ectropion that might require early skin grafting to prevent corneal ulceration and eye perforation. Shortening of the anterior lamella is also implicated in other syndromes associated with congenital ectropion, including blepharophimosis (lower lid, laterally)⁷, blepharocheilodontic syndrome (lower eyelids)⁸⁻¹⁰ and Down syndrome (upper and lower lids)¹¹, as well a variety of sporadic congenital anomalies including craniofacial clefting¹².

Involucional Ectropion

Involucional ectropion is the most common form of lower eyelid eversion, usually found in older patients. The Blue Mountain Eye Study assessed the prevalence and associations of ectropion in a large cohort of residents of Sydney, Australia (3654 people aged 49-97 years). Ectropion prevalence was higher in men (5.1%) than women (3.0%). The prevalence of lower eyelid ectropion has been shown to increase with age, reaching 16.7% in subjects over 80 years of age.¹³ Damasceno studied a Brazilian population of 24 565 elderly people and found similar results, with a prevalence of 17.7% in subjects aged 80 years or more.¹⁴

Several factors have been implicated in the pathogenesis of this eyelid deformity, all related to an abnormal laxity of the lid support system including tarsal and orbital septum atrophy, thinning of the skin and subcutaneous tissues, elongation of the tarsus and pretarsal orbicularis, medial and lateral canthal tendon laxity and dehiscence, and elongation or disinsertion of the lower lid retractors.² Heimmel

suggested that when these predisposing factors are present, the key to final lower eyelid position is the globe axial projection, with relatively exophthalmic eyes being more likely to develop tarsal ectropion.¹⁵ Histopathological studies have confirmed the role of age-related changes in the tarsal plate, inferior retractors, orbicularis oculi and lateral canthal tendon, in lids with involutional ectropion.^{16, 17} The affected lid shows the presence of collagen degeneration and elastosis of the tarsal plate and canthal tendons, an increased amount of adipose tissue in the distal tarsus, and focal degeneration, fibrosis, and elastosis of the pretarsal orbicularis.¹⁸⁻²⁰ In patients chronically exposed to the sun, actinic damage on the anterior lamella of the lower eyelid is an additional factor contributing to eyelid eversion in patients with involutional ectropion.²¹

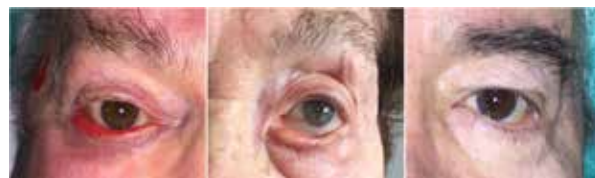

Fig. 1 - Involutional ectropion: total (left); medial (middle) and lateral (right).

The evaluation of a patient with involutional ectropion should start with the inspection of the lid margin and the position of the puncta since one of the first manifestations of lower eyelid ectropion is epiphora secondary to lacrimal punctum eversion. The patency of the puncta and lacrimal drainage system should always be examined.

The pinch test and snap back test are used to detect the presence of lower lid laxity. The result is abnormal if the lid can be distended more than 6 mm from the globe or does not briskly return to its natural position. The lateral canthus should form an acute angle and a rounded shape is indicative of lateral tendon elongation. If during traction of the lower lid there is lateral displacement of the lacrimal punctum towards the limbus, there is medial tendon laxity.^{2, 22} The condition of the lower lid skin is assessed by pulling the lower lid margin upwards. With traction the lid margin should reach a point at least 2 mm above the limbus. A relatively immobile margin indicates vertical shortening of the anterior lamella. This cicatricial component of involutional ectropion is a common finding when the ectropion has been present for a long period of time, or can be the result of mild actinic skin changes.^{2, 22}

Cicatricial Ectropion

Cicatricial ectropion is caused by anterior lamella shortening. Depending on the etiologic mechanism,

cicatricial entropion can affect the upper lids, the lower lids or both (as found in same cases of ichthyosis). It usually involves secondary eyelid scars resulting from trauma^{23, 24}, burns²⁵⁻²⁷ or from a large contingent of skin diseases such as ichthyoses^{28, 29}, discoid lupus erythematosus³⁰, inherited epidermolysis bullosa³¹, generalized eruptive keratoacanthoma³²⁻³⁴, cutaneous leishmaniasis³⁵, pityriasis rubra pilaris³⁶, and pyoderma gangrenosum^{37, 38}. Postoperative complications of eyelid tumors^{39, 40}, blepharoplasty⁴¹⁻⁴⁴ and skin resurfacing^{45, 46} are also common causes of lower lid cicatricial entropion. Other sources of skin damage resulting in entropion are radiotherapy^{47, 48} and the use of drugs such as docetaxel⁴⁹, fluorouracil⁵⁰⁻⁵², anthrax⁵³, prostaglandins^{54, 55}, brimonidine⁵⁵, betaxolol⁵⁵, dorzolamide⁵⁵, timolol⁵⁵, and iopidine⁵⁶.

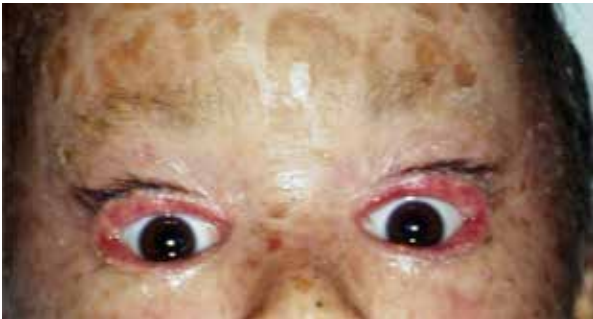


Fig. 2 – Lamellar ichthyosis. Cicatricial entropion of all lids.

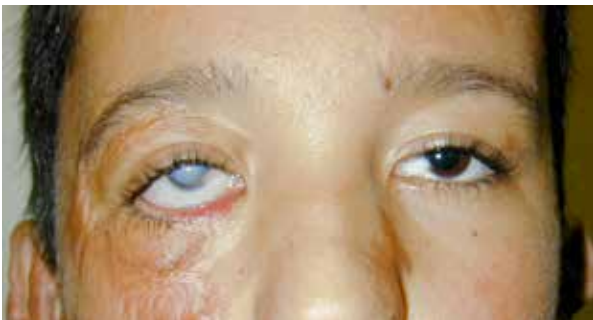

Fig. 3 - Cicatricial entropion of the lower lid caused by extensive midface burn.

Paralytic Ectropion

Paralytic ectropion is caused by the lack of normal innervation of the orbicularis muscle. Failure of normal lid closure with lower lid laxity and ectropion, upper eyelid retraction and brow ptosis are the clinical signs. The causes of seventh nerve palsy are myriad, but can be broadly divided by order of frequency into idiopathic (Bell's palsy), traumatic (birth canal trauma or forceps delivery, surgical trauma, facial and temporal bone fractures), infectious (herpes zoster, Lyme disease, HIV infection, polio, mumps, cytomegalovirus, mononucleosis, leprosy, cat

scratch fever), and neoplastic (acoustic neuroma, cerebellopontine angle tumors).⁵⁷

In paralytic ectropion due to surgical trauma, the timing for facial reanimation surgery is under debate. Watts et al. advocate that rehabilitation surgery with gold weight implantation and lateral tarsal strip should be performed immediately, at the time of facial nerve sacrifice.⁵⁸

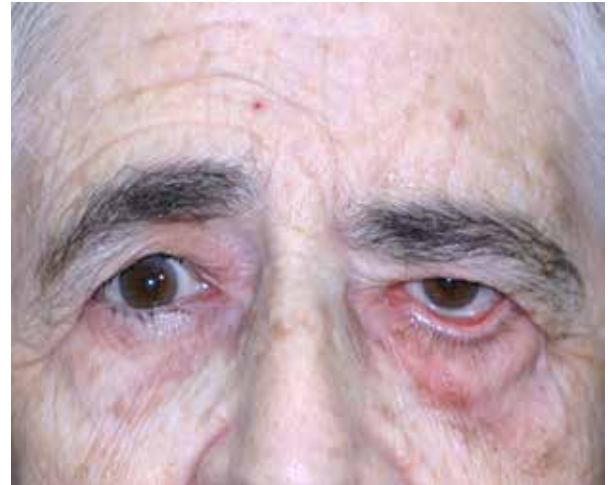


Fig. 4 – Left lower lid paralytic ectropion. Note lower lid laxity and ectropion, brow ptosis and absence of forehead wrinkles.

Mechanical Ectropion

Mechanical ectropion is caused by eyelid tumors that evert the lower lid or by inflammatory disorders that cause orbicularis spasm. Large tumors or cysts near the lid margin, acute proptosis with chemosis, eyelid and periorcular edema, significant herniated orbital fat and traction on the lower eyelid skin from spectacles can be mechanical causes of ectropion. The treatment is directed at the cause.^{2, 59-62}

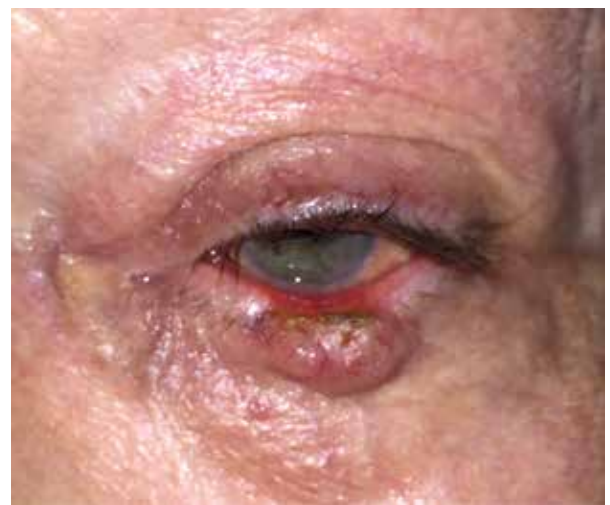

Fig.5 - Mechanical ectropion caused by a basal cell carcinoma.

Treatment

Lower or upper eyelid ectropions are usually

8. Ectropion

managed with surgery. As mentioned before, the key for a successful surgical procedure is the correct preoperative identification of the underlying etiologic factor. Depending on the mechanism causing the lid margin rotation, a variety of procedures are used to stabilize the lid margin. For instance, lower eyelid horizontal laxity with normal canthal tendon tonus can be dealt with by pentagonal full thickness eyelid resection. If the lateral canthal tendon is abnormally lax, tarsal strip procedures are indicated^{1, 2, 63, 64}. This useful procedure is a variant of the old Bick's lateral resection⁶⁵ and involves the following steps: a lateral canthotomy and cantholysis; excision of skin and conjunctiva, leaving a free strip of tarsus; fixation of the tarsal strip to the periosteum of the lateral orbital wall; and reconstruction of the lateral canthus to create the appropriate height and tension of the lower eyelid.^{63, 66} Monofilament non-absorbable sutures are generally used^{2, 64, 67, 68}, but long-acting absorbable sutures will also work without recurrence of horizontal laxity.^{66, 69, 70}

Repairing medial tendon laxity is more complicated than repairing its lateral counterpart because of the close relationship between the tendon and the canaliculi. The high rate of postoperative lacrimal problems following surgery on the medial canthus leads some surgeons to delay correction of the medial canthal tendon until laxity is advanced. Medial canthal tendon correction has been attempted by resection or plication of the tendon medial to the lower punctum, anchoring the tissue to either the anterior periosteum or the posterior lacrimal crest.⁷¹⁻⁷⁵ Lacrimal ectropion without horizontal laxity is classically treated with the excision of a diamond of conjunctiva and retractors below the punctum.^{76, 77}

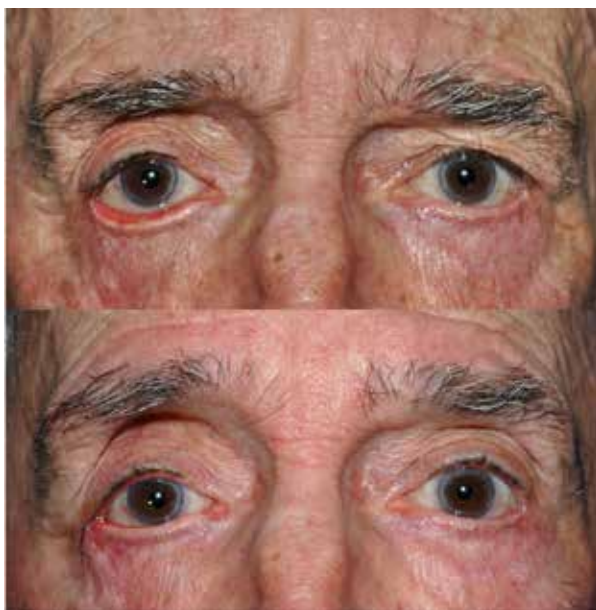

Fig. 6 - Top: Involutional lower lid ectropion with mild actinic changes. Bottom: Immediate postoperative (tarsal strip) result.

If there is horizontal laxity, a full-thickness wedge excision of the lid margin can be associated with the pentagon excision creating a lazy-T procedure.^{76, 77} The wedge excision can be displaced laterally or be replaced by a tarsal strip.

In both procedures, the role of lower lid retractor plication has been emphasized.⁷⁸⁻⁸⁰ Advanced tarsal ectropion requires a large excision of the conjunctiva and retractors via a posterior approach, combined with everting sutures and horizontal tightening.

Since cicatricial ectropion is due to an anterior lamella deficiency, various surgical techniques can be used to lengthen the underlying deformity. Z-plasties can be used to manage linear scars.^{1, 2, 81} Large shortages of skin require local flaps^{26, 82-85} or skin grafts^{27, 48, 86}.

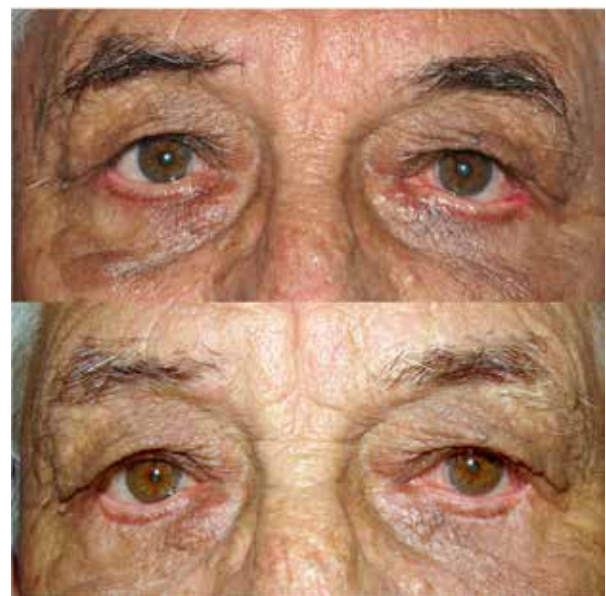


Fig. 7 – Top: Residual left lateral ectropion following tarsal strip. Bottom: Postoperative results after refixation of the left lateral canthus.

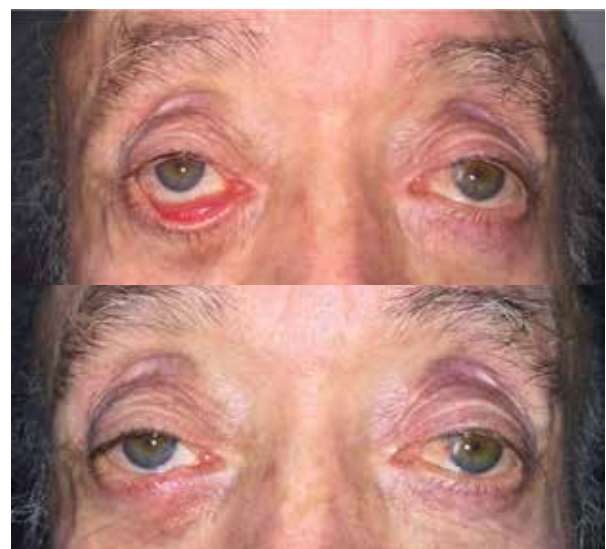

Fig.8 - Lacrimal ectropion of the right lower eyelid (top) corrected by a Lazy-T procedure (bottom).

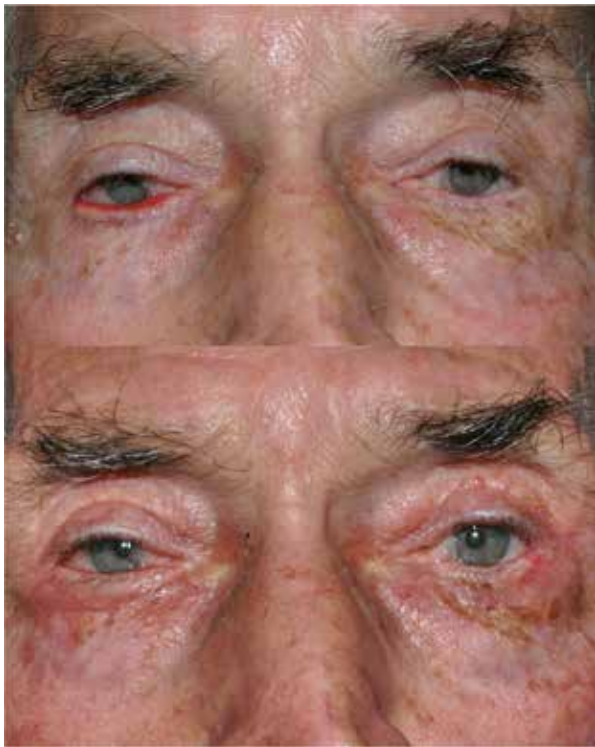

Fig. 9 – Top: Cicatricial right lower lid ectropion. Bottom: Postoperative result following anterior lamella lengthening with an upper lid skin flap.

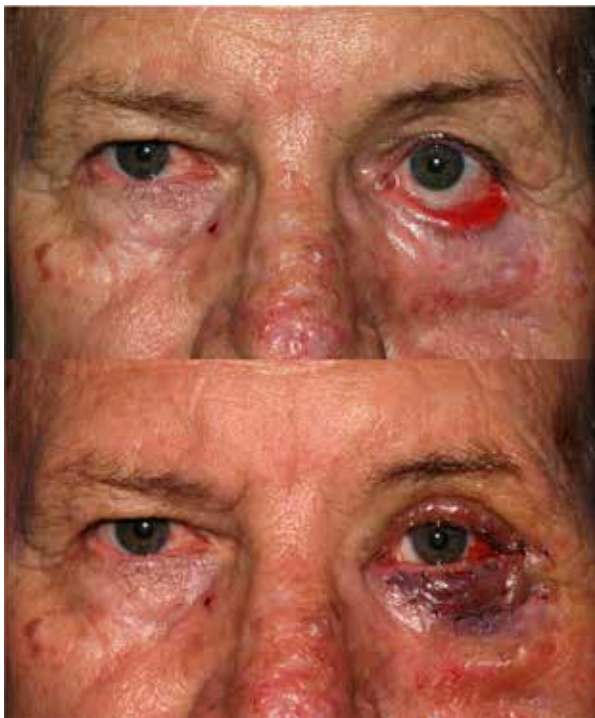


Fig. 10 – Top: severe left lower lid cicatricial ectropion. Note the normal lid position after skin graft and tarsal strip (bottom).

There are a large variety of flaps that can be used to correct lower and upper ectropions depending on the location and extension of the cicatricial process. Free skin grafts can be collected from the upper lid, retroauricular region, supraclavicular area or inner aspect of the upper arm.^{1, 2, 81}

In severe lower eyelid ectropion, there is often inadequate muscle support for the pretarsal lower eyelid. When the pretarsal orbicularis muscle is damaged, a fascia lata sling is another option for supporting the lower lid.⁸⁴

Conclusion

Successful functional and cosmetic correction of ectropion depends on understanding that ectropion is not a single type of eyelid malposition, but in fact represents a group of conditions that can affect the lateral, central or medial portion of the upper or lower eyelid, alone or in combination. Surgery to correct these eyelid deformities must tackle the underlying anatomic factors responsible for the malposition. The correct identification and management of these conditions and factors that cause lid instability will lead to the proper procedure being selected and, most importantly, to a successful outcome for the patient.

References

1. Hintschich C. Correction of entropion and ectropion. *Dev Ophthalmol*. 2008;41:85-102.
2. Bedran EG, Pereira MV, Bernardes TF. Ectropion. *Semin Ophthalmol*. 2010;25(3):59-65.
3. Dohvoma VA, Nchifor A, Ngwanou AN, Attha E, Ngounou F, Bella AL, et al. Conservative management in congenital bilateral upper eyelid eversion. *Case Rep Ophthalmol Med*. 2015;2015:389289.
4. Krishnappa NC, Deb AK, Poddar C. Congenital total eversion of upper eyelids in a newborn with Down's syndrome. *Oman J Ophthalmol*. 2014;7(2):98-9.
5. Ibraheem WA. Bilateral congenital upper eyelid eversion: the clinical course and outcome of conservative management. *Pan Afr Med J*. 2014;17:215.
6. Fasina O. Management of bilateral congenital upper eyelid eversion with severe chemosis. *J Ophthalmic Vis Res*. 2013;8(2):175-8.
7. Sandramouli S, Betharia SM. Blepharophimosis syndrome: an atypical case. *Eye (Lond)*. 1994;8 (Pt 4):482-4.
8. Gorlin RJ, Wiedemann HR. Blepharo-cheilo-dontic (BCD) syndrome. *Acta Ophthalmol Scand Suppl*. 1996(219):22.
9. Guion-Almeida ML, Rodini ES, Kokitsu-Nakata NM, Bologna-Amantini D. Blepharo-Cheilo-Dontic (BCD) syndrome: report on four new patients. *Am J Med Genet*. 1998;76(2):133-6.
10. Yen MT, Lucci LM, Anderson RL. Management of eyelid anomalies associated with Blepharo-cheilo-dontic syndrome. *Am J Ophthalmol*. 2001;132(2):279-80.
11. Sellar PW, Bryars JH, Archer DB. Late presentation of congenital ectropion of the eyelids in a child with Down syndrome: a case report and review of the literature. *J Pediatr Ophthalmol Strabismus*. 1992;29(1):64-7.
12. Iida A, Narai S, Takagi R, Ono K, Ikeda N. Blepharo-cheilo-dontic (BCD) syndrome: case report. *Cleft Palate Craniofac J*. 2006;43(2):237-43.
13. Mitchell P, Hinchcliffe P, Wang JJ, Rohtchina E, Foran S. Prevalence and associations with ectropion in an older population: the Blue Mountains Eye Study. *Clin Experiment Ophthalmol*. 2001;29(3):108-10.
14. Damasceno RW, Osaki MH, Dantas PE, Belfort R, Jr. Involutional entropion and ectropion of the lower eyelid:

- prevalence and associated risk factors in the elderly population. *Ophthal Plast Reconstr Surg*. 2011;27(5):317-20.
15. Heimmell MR, Enzer YR, Hofmann RJ. Entropion-ectropion: the influence of axial globe projection on lower eyelid malposition. *Ophthal Plast Reconstr Surg*. 2009;25(1):7-9.
 16. Chua J, Choo CT, Seah LL, Fong KS, Chee SP, Chuah CT, et al. A 5-year retrospective review of Asian ectropion: how does it compare to ectropion amongst non-Asians? *Ann Acad Med Singapore*. 2011;40(2):84-9.
 17. Bashour M, Harvey J. Causes of involutional ectropion and entropion--age-related tarsal changes are the key. *Ophthal Plast Reconstr Surg*. 2000;16(2):131-41.
 18. Kocaoglu FA, Katircioglu YA, Tok OY, Pulat H, Ornek F. The histopathology of involutional ectropion and entropion. *Can J Ophthalmol*. 2009;44(6):677-9.
 19. Damasceno RW, Osaki MH, Dantas PE, Belfort R, Jr. Involutional ectropion and entropion: clinicopathologic correlation between horizontal eyelid laxity and eyelid extracellular matrix. *Ophthal Plast Reconstr Surg*. 2011;27(5):321-6.
 20. Damasceno RW, Heindl LM, Hofmann-Rummelt C, Belfort R, Schlotzer-Schrehardt U, Kruse FE, et al. Pathogenesis of involutional ectropion and entropion: the involvement of matrix metalloproteinases in elastic fiber degradation. *Orbit*. 2011;30(3):132-9.
 21. Marshall JA, Valenzuela AA, Strutton GM, Sullivan TJ. Anterior lamella actinic changes as a factor in involutional eyelid malposition. *Ophthal Plast Reconstr Surg*. 2006;22(3):192-4.
 22. Frueh BR, Schoengarth LD. Evaluation and treatment of the patient with ectropion. *Ophthalmology*. 1982;89(9):1049-54.
 23. Desciak EB, Eliezri YD. Surgical Pearl: Temporary suspension suture (Frost suture) to help prevent ectropion after infraorbital reconstruction. *J Am Acad Dermatol*. 2003;49(6):1107-8.
 24. Salgarelli AC, Bellini P, Multinu A, Landini B, Consolo U. Tarsal strip technique for correction of malposition of the lower eyelid after treatment of orbital trauma. *Br J Oral Maxillofac Surg*. 2009;47(4):298-301.
 25. Astori IP, Muller MJ, Pegg SP. Cicatricial, postburn ectropion and exposure keratitis. *Burns*. 1998;24(1):64-7.
 26. Kostakoglu N, Ozcan G. Orbicularis oculi myocutaneous flap in reconstruction of postburn lower eyelid ectropion. *Burns*. 1999;25(6):553-7.
 27. Mandrekas AD, Zambacos GJ, Anastasopoulos A. Treatment of bilateral severe eyelid burns with skin grafts: an odyssey. *Burns*. 2002;28(1):80-6.
 28. Cruz AA, Menezes FA, Chaves R, Pinto Coelho R, Velasco EF, Kikuta H. Eyelid abnormalities in lamellar ichthyoses. *Ophthalmology*. 2000;107(10):1895-8.
 29. Craiglow BG, Choate KA, Milstone LM. Topical tazarotene for the treatment of ectropion in ichthyosis. *JAMA Dermatol*. 2013;149(5):598-600.
 30. Kopsachilis N, Tsaousis KT, Tourtas T, Tsinopoulos IT. Severe chronic blepharitis and scarring ectropion associated with discoid lupus erythematosus. *Clin Exp Optom*. 2013;96(1):124-5.
 31. Fine JD, Johnson LB, Weiner M, Stein A, Cash S, Deleoz J, et al. Eye involvement in inherited epidermolysis bullosa: experience of the National Epidermolysis Bullosa Registry. *Am J Ophthalmol*. 2004;138(2):254-62.
 32. Consigli JE, Gonzalez ME, Morsino R, Guidi A, Chappuis JM, Papa M, et al. Generalized eruptive keratoacanthoma (Grzybowski variant). *Br J Dermatol*. 2000;142(4):800-3.
 33. Oakley A, Ng S. Grzybowski's generalized eruptive keratoacanthoma: remission with cyclophosphamide. *Australas J Dermatol*. 2005;46(2):118-23.
 34. Anzalone CL, Cohen PR. Generalized eruptive keratoacanthomas of Grzybowski. *Int J Dermatol*. 2014;53(2):131-6.
 35. Chaudhry IA, Hylton C, DesMarchais B. Bilateral ptosis and lower eyelid ectropion secondary to cutaneous leishmaniasis. *Arch Ophthalmol*. 1998;116(9):1244-5.
 36. Durairaj VD, Horsley MB. Resolution of pityriasis rubra pilaris-induced cicatricial ectropion with systemic low-dose methotrexate. *Am J Ophthalmol*. 2007;143(4):709-10.
 37. Procianny F, Barbato MT, Osowski LE, Bocaccio FJ, Bakos L. Cicatricial ectropion correction in a patient with pyoderma gangrenosum: case report. *Arq Bras Oftalmol*. 2009;72(3):384-6.
 38. Thampy RS, Al-Niaimi F, Lyon C, Duff CG, Leatherbarrow B. Management of cicatricial ectropion secondary to pyoderma gangrenosum. *Orbit*. 2014;33(2):129-31.
 39. Rubin P, Mykula R, Griffiths RW. Ectropion following excision of lower eyelid tumours and full thickness skin graft repair. *Br J Plast Surg*. 2005;58(3):353-60.
 40. Salgarelli AC, Francomano M, Magnoni C, Bellini P. Cicatricial iatrogenic lower eyelid malposition in skin cancer surgery: results of a combined approach. *J Craniomaxillofac Surg*. 2012;40(7):579-83.
 41. Botti G. Blepharoplasty: A classification of selected techniques in the treatment and prevention of lower lid margin distortions. *Aesthetic Plast Surg*. 1998;22(5):341-8.
 42. Morax S, Tuitou V. Complications of blepharoplasty. *Orbit*. 2006;25(4):303-18.
 43. Patrocinio TG, Loredó BA, Arevalo CE, Patrocinio LG, Patrocinio JA. Complications in blepharoplasty: how to avoid and manage them. *Braz J Otorhinolaryngol*. 2011;77(3):322-7.
 44. Mack WP. Complications in periocular rejuvenation. *Facial Plast Surg Clin North Am*. 2010;18(3):435-56.
 45. Demas PN, Bridenstine JB. Diagnosis and treatment of postoperative complications after skin resurfacing. *J Oral Maxillofac Surg*. 1999;57(7):837-41.
 46. Fife DJ, Fitzpatrick RE, Zachary CB. Complications of fractional CO2 laser resurfacing: four cases. *Lasers Surg Med*. 2009;41(3):179-84.
 47. Tarallo M, Rizzo MI, Monarca C, Fanelli B, Parisi P, Scuderi N. Optimal care for eyelid contraction after radiotherapy: case report and literature review. *J Oral Maxillofac Surg*. 2012;70(10):2459-65.
 48. Kim HJ, Hayek B, Nasser Q, Esmaeli B. Viability of full-thickness skin grafts used for correction of cicatricial ectropion of lower eyelid in previously irradiated field in the periocular region. *Head Neck*. 2013;35(1):103-8.
 49. Kaya AO, Buyukberber S, Coskun U, Yildiz R, Ozturk B, Yaman E, et al. Acute erythema and edematous skin reaction and ectropion following docetaxel in a patient with non-small cell lung cancer. *Cutan Ocul Toxicol*. 2008;27(4):327-31.
 50. Lewis JE. Temporary ectropion due to topical fluorouracil. *Int J Dermatol*. 1997;36(1):79.
 51. Obi EE, McDonald A, Kemp E. A bilateral cicatricial ectropion and bilateral upper lid shortening caused by 5-fluorouracil toxicity in a patient with dihydropyrimidine dehydrogenase deficiency. *Cutan Ocul Toxicol*. 2011;30(2):157-9.
 52. Nikkhah D, Abood A, Watt D. Cicatricial ectropion: a complication of topical 5-fluorouracil. *J Plast Reconstr Aesthet Surg*. 2012;65(1):e9-10.
 53. Soysal HG, Kiratli H, Recep OF. Anthrax as the cause of preseptal cellulitis and cicatricial ectropion. *Acta Ophthalmol Scand*. 2001;79(2):208-9.
 54. Altieri M, Ferrari E. Do prostaglandin analogs affect

- eyelid position and motility? *J Ocul Pharmacol Ther.* 2011;27(5):511-7.
55. Hegde V, Robinson R, Dean F, Mulvihill HA, Ahluwalia H. Drug-induced ectropion: what is best practice? *Ophthalmology.* 2007;114(2):362-6.
56. Britt MT, Burnstine MA. Iopidine allergy causing lower eyelid ectropion progressing to cicatricial entropion. *Br J Ophthalmol.* 1999;83(8):992-3.
57. Mavrikakis I. Facial nerve palsy: anatomy, etiology, evaluation, and management. *Orbit.* 2008;27(6):466-74.
58. Watts TL, Chard R, Weber SM, Wax MK. Immediate eye rehabilitation at the time of facial nerve sacrifice. *Otolaryngol Head Neck Surg.* 2011;144(3):353-6.
59. Ashfaq I, Kyprianou I, Ahluwalia H. A large kissing (divided) naevus presenting with complete mechanical ptosis and lower lid ectropion. *J Plast Reconstr Aesthet Surg.* 2009;62(5):e87-8.
60. Kampp JT, Kouba DJ, Fincher EF, Moy RL. Basal cell carcinoma masquerading as the chronic ectropion of lamellar ichthyosis. *Dermatol Surg.* 2008;34(7):963-7.
61. Baker HE, Berry-Brincat A, Zaki I, Cheung D. Three different consecutive manifestations of morphoeic BCC in the same patient: presenting first as ectropion, then entropion, and finally medial canthal dystopia with epicanthus inversus. *Orbit.* 2008;27(3):183-5.
62. Evans M, Chang E, Yu DL, Rao NA. Granular cell tumour: a rare caruncle lesion. *Br J Ophthalmol.* 2006;90(2):246-7.
63. Anderson RL, Gordy DD. The tarsal strip procedure. *Arch Ophthalmol.* 1979;97(11):2192-6.
64. Della Rocca DA. The lateral tarsal strip: illustrated pearls. *Facial Plast Surg.* 2007;23(3):200-2.
65. Bick MW. Surgical management of orbital tarsal disparity. *Arch Ophthalmol.* 1966;75(3):386-9.
66. Jordan DR, Anderson RL. The lateral tarsal strip revisited. The enhanced tarsal strip. *Arch Ophthalmol.* 1989;107(4):604-6.
67. Kam KY, Cole CJ, Bunce C, Watson MP, Kamal D, Olver JM. The lateral tarsal strip in ectropion surgery: is it effective when performed in isolation? *Eye (Lond).* 2012;26(6):827-32.
68. Tenzel RR, Buffam FV, Miller GR. The use of the "lateral canthal sling" in ectropion repair. *Can J Ophthalmol.* 1977;12(3):199-202.
69. Hsuan J, Selva D. The use of a polyglactin suture in the lateral tarsal strip procedure. *Am J Ophthalmol.* 2004;138(4):588-91.
70. Meyer DR. The use of a polyglactin suture in the lateral tarsal strip procedure. *Am J Ophthalmol.* 2005;139(4):758-9; author reply 9.
71. O'Donnell BA, Anderson RL, Collin JR, Fante RG, Jordan DR, Ritleng P. Repair of the lax medial canthal tendon. *Br J Ophthalmol.* 2003;87(2):220-4.
72. Moe KS, Kao CH. Precaruncular medial canthopexy. *Arch Facial Plast Surg.* 2005;7(4):244-50.
73. Sullivan TJ, Collin JR. Medial canthal resection: an effective long-term cure for medial ectropion. *Br J Ophthalmol.* 1991;75(5):288-91.
74. Francis IC, Wilcsek GA, Sharma S, Coroneo MT. Transcaruncular medial orbitotomy for stabilization of the posterior limb of the medial canthal tendon. *Clin Experiment Ophthalmol.* 2001;29(2):85-9.
75. Edelstein JP, Dryden RM. Medial palpebral tendon repair for medial ectropion of the lower eyelid. *Ophthalm Plast Reconstr Surg.* 1990;6(1):28-37.
76. Manners RM. Surgical repair of medial ectropion. *Eye (Lond).* 1995;9 (Pt 3):365-7.
77. Smith B. The "lazy-T" correction of ectropion of the lower punctum. *Arch Ophthalmol.* 1976;94(7):1149-50.
78. Ferguson AW, Chadha V, Kearns PP. The not-so-lazy-T: a modification of medial ectropion repair. *Surgeon.* 2006;4(2):87-9.
79. O'Donnell B. Age-related medial ectropion of the lower eyelid. *Aust N Z J Ophthalmol.* 1994;22(3):183-6.
80. Fong KC, Mavrikakis I, Sagili S, Malhotra R. Correction of involutional lower eyelid medial ectropion with transconjunctival approach retractor plication and lateral tarsal strip. *Acta Ophthalmol Scand.* 2006;84(2):246-9.
81. Miletic D, Elabjer BK, Bosnar D, Busic M. Our approach to operative treatment of lower lid ectropion. *Acta Clin Croat.* 2010;49(3):283-7.
82. Xue CY, Dai HY, Li L, Wang YC, Yang C, Li JH, et al. Reconstruction of lower eyelid retraction or ectropion using a paranasal flap. *Aesthetic Plast Surg.* 2012;36(3):611-7.
83. Xu JH, Tan WQ, Yao JM. Bipedicle orbicularis oculi flap in the reconstruction of the lower eyelid ectropion. *Aesthetic Plast Surg.* 2007;31(2):161-6.
84. Qian JG, Wang XJ, Wu Y. Severe cicatricial ectropion: repair with a large advancement flap and autologous fascia sling. *J Plast Reconstr Aesthet Surg.* 2006;59(8):878-81.
85. Manku K, Leong JK, Ghabrial R. Cicatricial ectropion: repair with myocutaneous flaps and canthopexy. *Clin Experiment Ophthalmol.* 2006;34(7):677-81.
86. Lau CK, Huang S, Cormack G. Minimising the risk of ectropion when full thickness skin grafting lower eyelid defects. *J Plast Reconstr Aesthet Surg.* 2008;61(12):1562-4.

9. Entropion

María Angélica Salazar Román, Diana Carolina Ortegáte Páez

Lid entropion is the condition where the eyelid margin is inverted towards the eyeball. Depending on the etiopathogenic mechanism, entropion can be classified as:

1. congenital,
2. acquired or spastic,
3. involutional,
4. cicatricial.

The most common is the involutional type, predominantly in the lower eyelid; it can be unilateral or asymmetric bilateral³, and is often found in elderly women (over 60 years old). It differs in frequency, being less frequent in afro-americans and one explaining theory is that melanin may protect against normal actinic skin changes such as aging⁴.

Cicatricial entropion is the second commonest. It mainly affects middle-aged men (30-40 years), due to traumatic accidents, in developing countries, Africa, Asia, Middle East, areas of Australia and Latin America. Cicatricial entropion mostly tends to occur in trachoma endemic regions⁴.

Clinical Overview

This condition creates contact between the eyelashes and adjacent skin and the cornea and bulbar conjunctiva. This causes irritation symptoms such as foreign body sensation, itching, burning of the ocular surface, blurred vision, eyelid fatigue and palpebral heaviness. Physical examination reveals conjunctival hyperemia (Fig. 1), edema of the tarsal conjunctiva, tearing, surface punctate keratitis (Fig. 2), single or confluent areas of trichiasis (Fig. 3 and 4) which can lead to symptoms as severe as corneal ulceration, microbial superinfection and ocular perforation. There may be other clinical signs such as blepharoptosis and blepharospasm^{4, 5, 6, 7}.

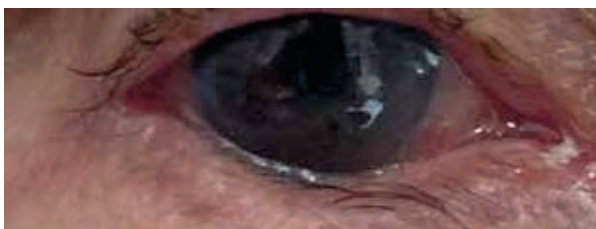


Fig. 1. (Conjunctival hyperemia, secondary tearing to lower right eyelid entropion).

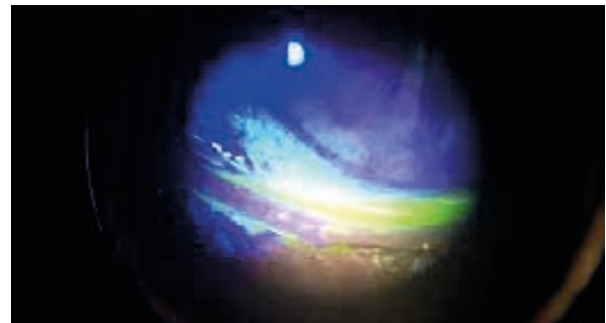


Fig. 2. Lower dotted keratitis for trichiasis of lower right eyelid.

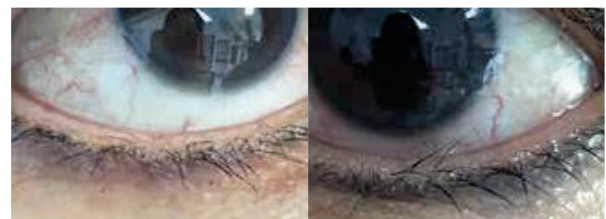


Fig. 3 and 4. Lower eyelid trichiasis.

Congenital Entropion

Congenital entropion is manifested mainly in the lower eyelids with very few cases being observed in the upper eyelids. It can be classified as primary or secondary.

Primary congenital entropion: It is mainly caused by hypertrophy of the tarsal orbicularis muscle fibers, as proposed by Leblond in 1907⁹.

Other factors are involved in its development such as:

- dysgenesis of retractors, described by Tse and later reconsidered by Bartley, when describing several cases of congenital entropion with intact inferior retractors;
- structural defects of the tarsal plates;
- relative shortening of the posterior lamella³.

Secondary congenital entropion: Is the most common, most often found in Asians, its nature is mechanical and is associated with epiblepharon, microphthalmia or anophthalmia. It is caused by the pressure generated by the lower eyelid fold (epiblepharon) when this is excessive skin, or by the loss of support to the lid, in cases where the eye is small or absent.

It is important to differentiate these two conditions because primary entropion is progressive, becoming

9. Entropion

more evident, and it usually requires early surgery. On the other hand, the epiblepharon can decline with facial growth and usually disappears during the first two years of life. A significant epiblepharon must be continually evaluated. However, as it can be associated with corneal irritation phenomena and blepharospasm, in some cases surgical correction is required.

Medical treatment:

Some cases have been treated conservatively with topical antibiotics, corticoids and lubrication, plus soft contact lenses for upper eyelid entropion. However, it has been demonstrated that in some patients the actual source of this entropion was spastic⁸.

The use of botulinum toxin has also been suggested. It is administered in a single dose of 5 U to weaken the tarsal orbicularis muscle and thus treat the entropion and corneal damage. Since this treatment is transient, several applications are needed⁹.

Surgical treatment:

The surgical procedures used depend on the pathogenesis in each case. Patients with primary congenital entropion should only require a refixation of the tarsal orbicularis hypertrophic muscle. In most cases it is the only treatment needed to keep the lid margin in position. Surgery involves releasing the orbicularis strip from its attachments to the tarsus so that it can be moved and fixed to the septum immediately below the tarsus (Wheeler's technique). In cases of congenital entropion due to epiblepharon, two procedures may be performed. The first only uses sutures to correct the lower epiblepharon, where sutures are inserted inferior to the tarsus and are directed to the top fold margin of the epiblepharon in order to try to keep the two lamellae in position (Fig. 5). The second procedure is to remove the skin and lower orbicularis muscle, suturing the lower eyelid retractor with the lower edge of the tarsus and skin (Hotz's technique) (Fig. 6, 7, 8). Another method for correcting secondary entropion in Asian children has been described as a modification of the Hotz technique. It involves removing a triangular piece of skin, fishtail shaped, on the epicanthus. The subciliary incision is extended to the side then the central part is sutured generating an L-shape rather than a C-shape in the epicanthus, which eventually leads to a relaxation of the orbicularis¹².

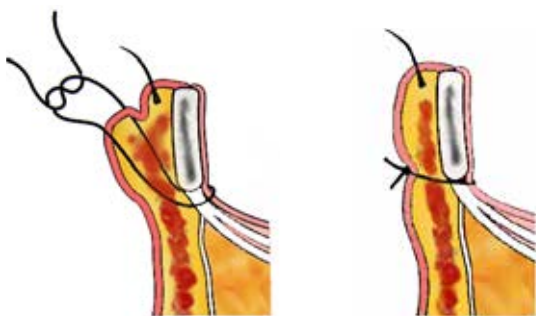


Fig. 5. Sutures.

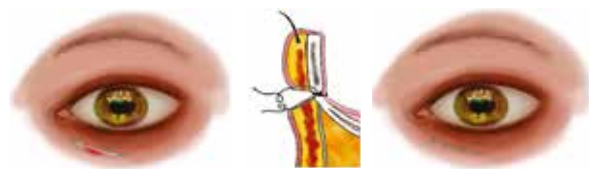

Fig. 6, 7 and 8. Hotz technique.

Acquired or Spastic Entropion

Its pathophysiological cause is a sustained contraction of the orbicularis muscle in its preseptal portion, which overlaps the pretarsal portion, with irritation or inflammation of the eyeball surface (Fig. 9), e.g. after intraocular surgery, chronic corneal irritation, etc.

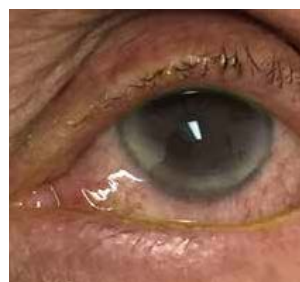

Fig. 9. Spastic entropion of lower left eyelid.

A type of intermittent spastic entropion is described. The suspicious clinical finding of this pathology is an intermittent foreign body sensation. On examination there is evidence of intermittent conjunctival hyperemia and central superficial punctate keratitis. The diagnosis is made with the test of induced entropion (Wilson's TIE), in which the preseptal orbicularis muscle is forced to override its pretarsal portion and in so doing induce the eyelid to turn inward. This test is performed as follows:

1. Topical anesthesia. Ask the patient to look down all the time or to lift the chin.
2. Pinch the lower eyelid with the index finger and thumb.
3. Lift the skin and roll it over the tarsal edge, pressing it against the eyeball.
4. Spread the eyelid against the eyeball by straightening out the finger and thumb.
5. Release the eyelid, and observe the result.

If an entropion is induced, make sure it is stable with eye movements and blinking. The entropion is stable if it lasts for more than 3 minutes, suggesting that a surgical correction must be performed, not only the control of the irritation of the corneal surface⁶.

Another type of spastic or acquired entropion is the entropion associated with facial paralysis. In adults, after facial paralysis it is more common to find an ectropion but children with facial paralysis more often develop isolated entropion instead. The loss of balance between the orbicularis oculi and eyelid retractors plus the hyperactivity of the previously paralyzed periocular muscles is the pathophysiological cause of this type of entropion.

Medical treatment:

The basis of the treatment for this type of entropion is to protect the ocular surface from eyelashes irritation with a soft contact lens, lubricants, topical antibiotics, corticoids or other medicines^{6,9}. Injection of botulinum toxin can provide temporary relief for 3-4 months by weakening the muscle tone of the lower eyelid. A dose of 5-10 U of botulinum toxin is injected into the tarsal orbicularis oculi and preseptal orbicularis according to the degree of severity. The lowest effective dose must be used with treatment intervals of at least three months, without any booster injections. This alternative management has fewer complications and adverse effects than surgery⁹.

Involitional Entropion

This type of entropion is the most common and usually affects the lower eyelids, generally in people aged over 60 years. It is more common in women than in men⁴.

The physiopathogenesis of involitional entropion is secondary to the weakening of preseptal orbicularis muscle attachment to the septum and to the dehiscence or detachment of the lower eyelid retractors from the tarsus.

The vertical support of the lid is thus reduced and the action of the pretarsal orbicularis is increased, which tends to reverse the lid margin. The preseptal orbicularis, which is not firmly attached to the septum tends to slip to a higher level strengthening pretarsal orbicular muscle contractile action. (Fig. 10). The weakening of the lateral canthal tendon reduces the eyelid's horizontal support and also contributes to the formation of the entropion.

Clinically, we can find:

1. horizontal eyelid laxity,
2. retractor attenuation,
3. redundant preseptal muscle,
4. retractor disinsertion:
 - a) subconjunctival white line below the lower tarsal margin,
 - b) lower eyelid higher than normal,
 - c) little or no movement of the eyelid under infraduction³.

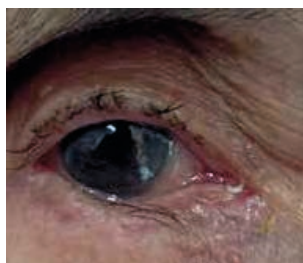

Fig. 10. Involitional entropion of lower right eyelid.

Involitional entropion is diagnosed through tests:

- Snap-back test: Is performed by pinching the lower-eyelid skin toward the inferior orbital rim and releasing the lid. If there is a slow return or if it doesn't return at all to its original position unless the

patient blinks, a weak muscle tone is present.

- Distraction test: The skin of the middle portion of the eyelid is pinched gently with your index finger and thumb and pulled away from the eyeball. If it can be pulled 8 mm or more, this suggests a lax lower lid.

In conclusion, aging changes that require correction can be summarized as:

- lamellar dissociation,
- weakening of the lower eyelid retractor,
- horizontal lid laxity.

Medical treatment:

Perform a cicatrization on the anterior lamella, through a controlled CO2 laser burn. This generates an immediate contracture caused by the ablation of water molecules from the epidermis, or thermal coagulation of proteins within the dermis. The long term postoperative dermal thickening and contracture could be related to temperature changes, i.e. the temperature applied in a range of 55-60° induces the release of growth factors, the production of collagen by fibroblasts with a modification of the extracellular matrix, causing a permanent effect.

Prophylactic treatment with topical antibiotics and antivirals should be administered. The procedure begins with local anesthesia and ocular globe protection with a corneal lens; in the first session a controlled rectangular burn of 5mm is made vertically, away from the lash line and in a second session a 6,5mm burn is performed near the lash line, with 200MJ energy. The ablated area is covered with Tegaderm™.

This technique may help patients with systemic comorbidities that contraindicate a prolonged anesthetic procedure⁷.

The effect of botulinum toxin in the management of involitional entropion is temporary, with a median duration of 11 weeks, and is correlated with the amount of horizontal lid laxity found at the time of injection.

Cyanoacrylates are liquid monomers that can be quickly polymerized to form a strong adhesive. They have been used with apparent safety and efficacy for over 30 years in ophthalmology, for cornea, sclera, eyelid skin, grafts in reconstruction of orbit and daily application for severe blepharoptosis. 2-octyl cyanoacrylate is a simple, safe and effective wound adhesive for the temporary treatment of involitional entropion, with a duration of three days, until surgery can be performed. There are no proven dermatological or ocular reactions¹¹.

Surgical treatment

The treatment must take into account the patient findings that contribute to the formation of the entropion in order to define the best surgical technique for each individual.

Given that both the horizontal and vertical laxity must be corrected¹³, the main techniques include:

Sutures

They can be used transversely in cases of lamellar

9. Entropion

dissociation to prevent upward movement of preseptal orbicularis muscle (Fig 11), or as everting sutures when the aim is to adjust the lower eyelid retractors. They are usually temporary procedures, which are used in patients with any medical contraindication that prevent definitive surgical correction. In most cases 4-0 absorbable sutures are used, which are removed 2-3 weeks later.

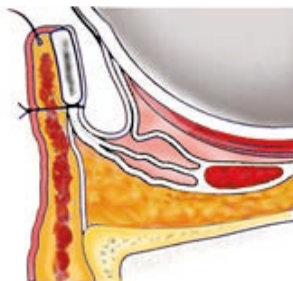


Fig. 11. Sutures.

Wies Procedure

Indicated in cases where there is mainly a lamellar dissociation with retractor weakness of the lower eyelid, with no horizontal laxity. In this procedure, a fibrous barrier is generated by creating a scar at orbicularis muscle level to prevent its upward movement and everting sutures are placed to shorten the lower eyelid retractor (Fig. 12). In mild cases it is only necessary to place an everting suture in the middle 1/3 of the eyelid at the central axis of the pupil. This achieves an eversion of approximately 25°, even though recurrence rates of 16% have been reported¹³.

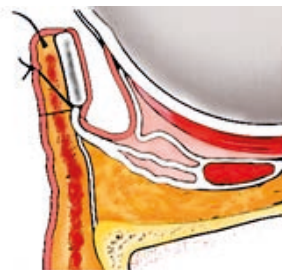


Fig. 12. Wies procedure.

Quickert Procedure

This procedure covers three entropion associated conditions. A transverse scar is made to prevent upward movement of the orbicularis muscle, associated with the placing of everting sutures and horizontal eyelid shortening (Fig. 13, 14 and 15). The procedure has reasonable duration (more than 18 months) and good results in the non-Asian population, but with recurrence rates of 9%, although recent studies have shown benefits in eastern population¹⁴.

Jones Procedure

This procedure usually only generates a reinsertion of the retractor with a resection of skin and preseptal orbicularis muscle (Fig. 16, 17). Recurrence rates of 5% have been reported¹⁵. The above procedure has

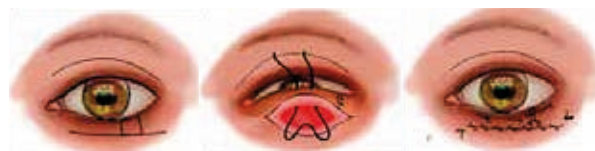

Fig. 13, 14, 15. Quickert procedure.

been modified with respect to the surgical approach, via trans-cutaneous or trans-conjunctival route to reinsert the lower eyelid retractors. A new approach is described using the sagittal route, performing a lateral canthotomy and inferior cantholysis to surgically isolate the retractors with lateral to medial tissue dissection. In some cases this technique is combined with tarsal strip. Surgical combinations have been used where the three pathogenetic factors are involved, thus improving success rates and reducing recurrence of the involutional entropion^{13,15}.

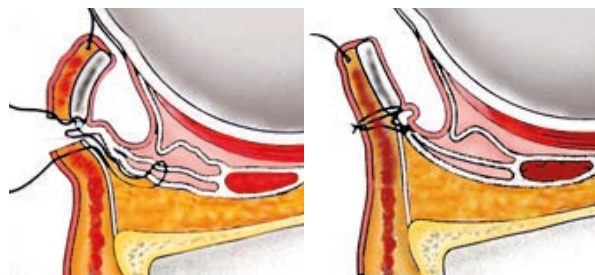


Fig. 16, 17. Jones procedure.

Cicatricial entropion

Cicatricial entropion can be caused by any condition that leads to vertical shortening of the posterior lamella (Fig 18). The commonest causes of entropion include:

- inflammation: cicatricial pemphigoid, Stevens-Johnson's Syndrome;
- infection: trachoma, herpes zoster;
- mechanical trauma, burns and surgical complications³.

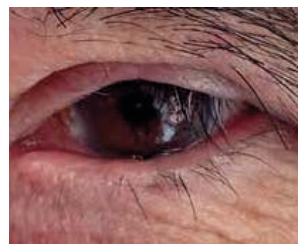

Fig. 18. Left upper eyelid entropion.
The diagnosis is clinical when trying a digital eversion, it fails.

Treatment:

Treat the systemic cause by controlling the autoimmune diseases, using antibiotics and systemic corticoids for mild cicatricial entropion, along with topical treatment with lubricants. In moderate to severe cases, surgical alternatives indicated for lower eyelid cicatricial entropion are:

Tarsal Fracture

This is used when entropion is mild, with inferior scleral exposure of less than 1.5 mm below the limbus. A posterior horizontal incision in the middle and through the tarsus is performed, without orbicularis compromise, and everting sutures are placed from the tarsus lower part running superior and anteriorly, emerging close to the eyelashes. (Fig. 19, 20)

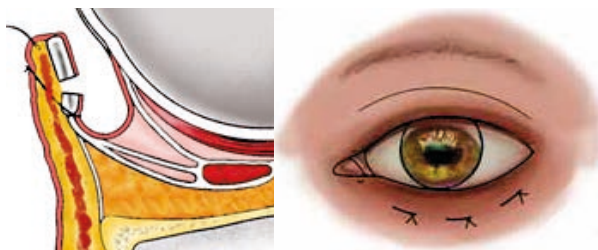


Fig. 19, 20. Tarsal fracture.

Posterior Lamellar Grafts

Indicated in cases where there is a significant loss of tissue of the posterior lamella and greater scleral exposure, more than 1.5 mm. The most used grafts are mucosal or palate grafts. (Fig. 21)

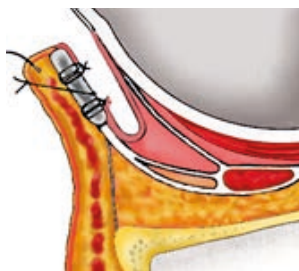


Fig. 21. Posterior lamella grafts.

Gray-Line Split with Retractor Reposition

Used in cases where there is a co-existing trichiasis but without significant eyelid retraction. The lid is divided at the grey line and the entire anterior lamella is released from its previous adherence to the tarsus. Sutures are placed to reinforce the retractor and emerge just below lash line, to achieve the correct eversion of the eyelid margin. (Fig. 22, 23)

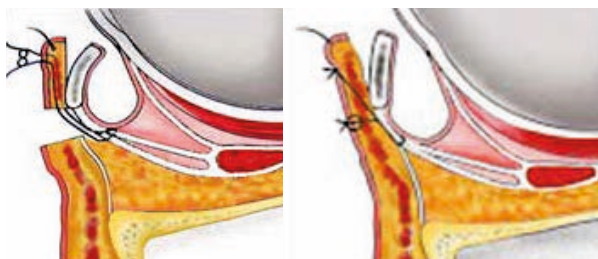


Fig. 22, 23. Gray-line split with retractor repositioning.

Upper Lid Entropion

When treating cases of entropion in upper eyelids, there are several aspects to take into account before deciding a surgery, such as:

- **Severity**

Mild cases of entropion may not be associated with the eyelashes rubbing against the cornea. Such cases can usually be corrected by performing a replacement of the anterior lamella, where a portion of muscle and skin is resected and sutured to a higher level of the tarsus. (Fig. 24, 25)

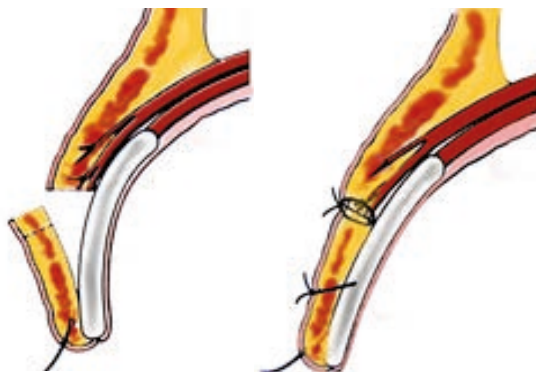


Fig. 24, 25. Anterior lamella repositioning.

- **Tarsal Thickness**

Underlying pathology can cause a thickened tarsal plate, as found in trachoma patients, or a thinned one in patients with Stevens-Johnson's syndrome. If a tarsal thickening is present, the tarsal wedge resection can be used, along with the replacement of the anterior lamella. The lid margin is again divided at the gray line level and the tarsal wedge resection is performed after making an incision through the eyelid fold. The fibrous tissue with Müller's muscle must be resected to allow advancement of the subsequent lamella. (Fig. 26, 27)

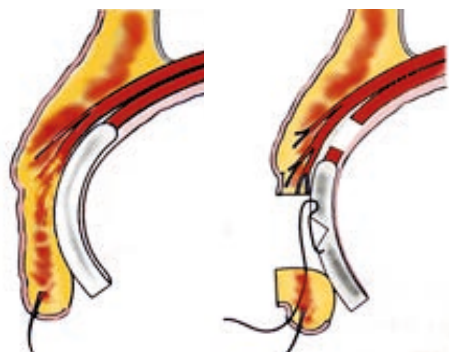


Fig. 26, 27. Tarsal wedge resection.

In case of a thinned tarsus, lamellar division and the use of mucosal graft at lid crease level are indicated; the advanced posterior lamella is sutured in a lower position, usually leaving a portion of tarsus exposed. (Fig 28) According to the surgeon's preference, this exposure can be left for granulation tissue formation, or it can be covered with mucosal graft.

9. Entropion

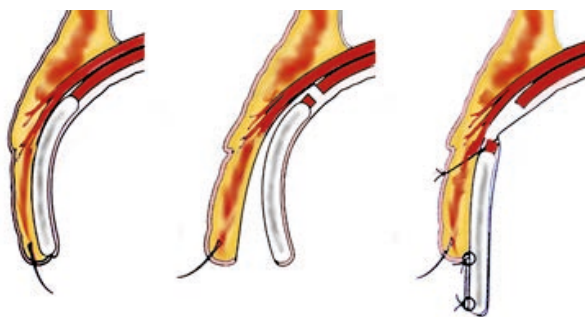


Fig. 28. Lamella division with or without graft.

• Keratinization of The Tarsal Conjunctiva

Healing processes can generate metaplastic changes such as keratinization, which can generate corneal wounds. When this finding is present, the terminal tarsus must be rotated. An incision is made at the level of the lower tarsus, throughout the eyelid extent to enable rotation of 180 degrees, suturing the free end on the same advanced tarsus (Fig. 29, 30).

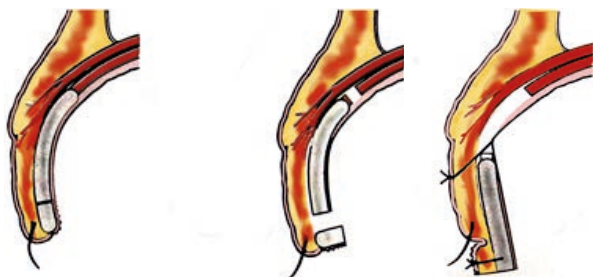


Fig. 29, 30. Rotation of terminal tarsus.

• Lid Retraction

Any shortening of the posterior lamella can generate eyelid retraction. In mild cases, it can be handled simply by releasing the conjunctiva and Müller's muscle and any scar tissue. More severe cases will require subsequent conjunctival grafts, taken from hard palate mucosa, or nasal septal cartilage. (Fig. 31, 32).

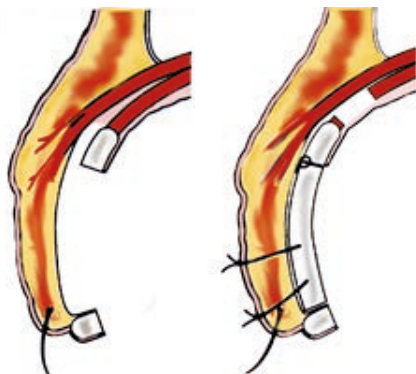


Fig. 31, 32. Posterior lamella graft.

References

1. Soares Eduardo, Moura Eurípedes, Gonçalves João. *Cirurgia Plástica Ocular*. First Edition. 1997
2. J.R.O. Collin. *A Manual of Systematic Eyelid Surgery*. Third Edition.
3. John Bryan Holds, Md. "Órbita, párpados y aparato lagrimal". American Academy of Ophthalmology. 1st Edition. El Servier. (2007-2008).
4. Bolanle G. Balogun, Bola J. Adekoya, Modupe M. Balogun, Rosemary V. Ngwu, Olugbemisola Oworu. "Ectropion and entropion in sub-Saharan Africa: How do we differ?". *Annals of African Medicine* (2013), Vol. 12, No. 4.
5. AH Alsuhaibani, TM Bosley, RA Goldberg and YH Al-FakY. "Entropion in children with isolated peripheral facial nerve paresis". *Eye* (2012) 26, 1095–1098.
6. Sidney Julio Faria-e-Sousa, Monike de Paula Gomes Vieira, Jailton Vieira Silva. "Uncovering intermittent entropion". *Clinical Ophthalmology* (2013):7 385–388.
7. Orhan Babuccu. "An alternative approach for involutional entropion: a preliminary study". *Lasers Med Sci* (2012) 27:1009–1012.
8. Nicholas J. R. Maycock, BSc (Hons), MRCOphth Debendra N. Sahu, MRCSEd Peter M. Mota, BSc, BM Hannah Gaston, DM, FRCS, FRCOphth, Peter R. Hodgkin. "Conservative Management of Upper Eyelid Entropion". *Journal of Pediatric ophthalmology & Strabismus* (2008) vol 45 • no 6, p 377-378.
9. S Cillino, G Raimondi, N Guépratte, S Damiani, M Cillino, F Di Pace and A. Casuccio. "Long-term efficacy of botulinum toxin A for treatment of blepharospasm, hemifacial spasm, and spastic entropion: a multicentre study using two drug-dose escalation indexes". *Eye* (2010) 24, 600–607.
10. Gregory Christiansen, MD, Brian G. Mohny, MD, Keith H. Baratz, MD, and Elizabeth A. Bradley, MD. "Botulinum Toxin for the Treatment of Congenital Entropion". *Journal Ophthalmol* 2004;138:153–155.
11. Teissy Osaki, Midori Hentona Osaki, Tammy Hentona Osaki. "Temporary management of involutional entropion with octyl-2-cyanoacrylate liquid bandage application". *Arq Bras Oftalmol*. 2010;73(2):120-4.
12. Siew-Yin Then, Aysha Salam, Hirohiko Kakizaki, Raman Malhotra. "A Lateral Approach to lower Eyelid Entropion Repair". *Ophthalmic Surgery, lasers & imaging*. 2011. Vol. 42, No. 6.
13. Min Soo Park, Mi Jung Chi, Se Hyun Back. "Clinical Study of Single – Suture Inferior Retractor Repair for Involutional Entropion". *Ophthalmology*. 2006; 220; pag 327-331.
14. Tatsuro Miyamoto, Hiroshi Eguchi, Takashi Katome, Toshihiko Nagasawa, Yoshinori Mitamura, Geoffrey Crawford. "Efficacy of the Quickert procedure for involutional entropion: the first case series in Asia". *The journal of Medical Investigation*. 2012 Vol. 59. Pag. 136-142.
15. Didem Serin, Ibrahim Bulent Buttanri, Safak Karslioglu, Mehmet Sahhin Sevim, Bahtinur Buttanri, Muslime Akbaba. "The efficacy of the Combined Procedure in Involutional Entropion Surgery: A comparative Study". *Korean J. Ophthalmol*. 2013; 27 (6); pag. 405 – 408.

10 . Blepharoptosis

Guilherme Castela

Definition

Abnormal lowering or drooping of the upper lid secondary to structural abnormalities (muscular or aponeurotic) or neurogenic problems¹. (Fig. 1)



Fig. 1: Ptosis of the left eye.

Classification

Ptosis has multiple classifications based on age of onset, disease etiology and frequency.

The most commonly used classifications are based on age of onset (congenital or acquired) and etiology (myogenic, neurogenic, aponeurotic or traumatic)^{1,2}. The most common type in childhood is isolated congenital ptosis, whereas in adults aponeurotic involutional ptosis is the most common. It should be borne in mind that most cases of congenital ptosis are myogenic and most acquired ptosis is aponeurotic.

Congenital ptosis

Congenital ptosis accounts for 75% of ptosis cases^{2,3}. (Fig.2) Congenital ptosis can be isolated or associated with oculomotor abnormalities or facial malformations. When ptosis is linked with oculomotor abnormalities, the most common cases are those associated with paresis of the superior rectus muscle, Marcus Gunn syndrome and congenital fibrosis of extraocular muscle syndrome. Elevation paresis which accounts for 5% of cases, often occurs because the levator and superior rectus muscles have the same origin. Bell's phenomenon is impaired in such cases. The commonest form of congenital ptosis associated with facial malformations is the blepharophimosis syndrome³.

Simple congenital ptosis is the commonest form of ptosis in childhood. With a myogenic etiology, it results from dysgenesis in the levator palpebrae muscle, often with infiltration of fibroadipose tissue, which causes severely decreased muscle function. In congenital ptosis, contraction and relaxation of the levator muscle are poor³. Ptosis remains constant throughout life.

Most cases are unilateral, and they are asymmetrical when bilateral. It is characterized by a weak or absent eyelid crease, and high lid position on infraversion. Furthermore, it is associated with frontalis muscle contraction and compensating torticollis (raised chin), most frequently in bilateral cases (Fig. 3).



Fig.2: Congenital ptosis.

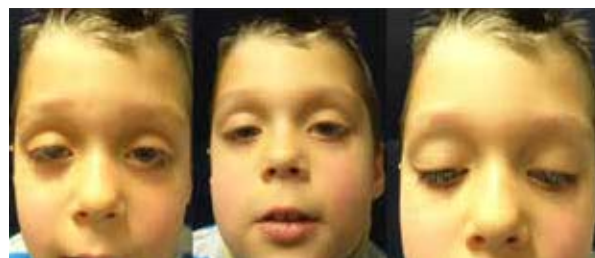

Fig. 3: Bilateral congenital ptosis; compensating torticollis; high lid position on infraversion.

Amblyopia can develop in up to 20% of congenital ptosis cases. Rather than being caused by occlusion of the axis, it is usually due to anisometropia caused by the high astigmatism, because of the weight of the eyelid in an immature cornea. Convergent strabismus can also be associated and is a possible cause for amblyopia. When present, early ptosis surgery is mandatory.

With a 5% frequency, the Marcus Gunn syndrome is the most common type of synkinetic ptosis. It is usually sporadic and unilateral. Marcus Gunn syndrome is caused by an aberrant connection between the fibers of the V cranial nerve and the superior branch of the III cranial nerve, which innervates the levator muscle⁴. It is characterized by ptosis that disappears with jaw movements. Treatment is very difficult because there is no definitive solution for synkinesis. Synkinesis may diminish during puberty (Fig. 4).

In the congenital fibrosis of the extraocular muscles syndrome, ptosis is bilateral and severe, with poor levator muscle function. It shows familial autosomal



Fig. 4: Marcus Gunn syndrome.

inheritance, with variable incidence. The levator muscle and all the extraocular muscles are fibrotic¹. Children usually present with a fixed gaze on infraduction and compensating torticollis (Fig.5.)

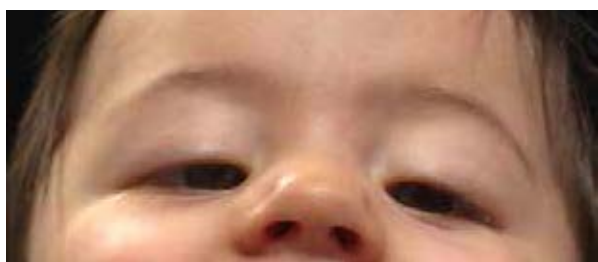

Fig. 5: Child with congenital fibrosis of the extraocular muscles syndrome.

Blepharophimosis syndrome has autosomal dominant inheritance, but can also be sporadic. It is characterized by ptosis, epicanthus inversus, telecanthus². It usually causes symmetrical bilateral ptosis with poor levator muscle function. Furthermore, blepharophimosis syndrome is associated with temporal ectropion of the lower lids due to lack of elasticity/tight skin (Fig. 6).

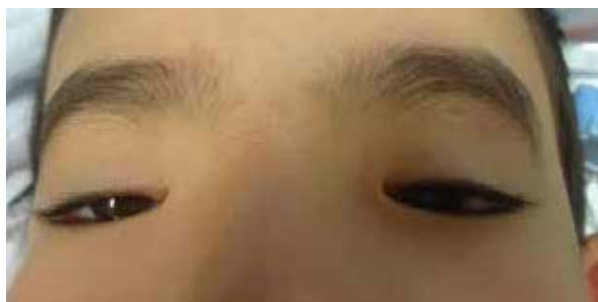

Fig. 6: Blepharophimosis syndrome.

Aponeurotic ptosis

This is the most prevalent type of acquired ptosis, usually appearing after the age of 60. It results from detachment, dehiscence or thinning of the levator aponeurosis^{1,4,5,6}(Fig. 7).

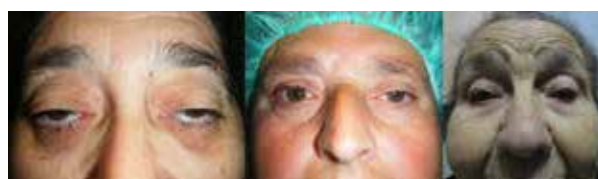

Fig. 7: Aponeurotic ptosis.

Age and tissue laxity are the main etiopathogenic factors. Risk factors are cataract surgery, wearing contact lenses, inflammation and eyelid trauma. Aponeurotic ptosis is characterized by high eyelid crease and good levator muscle function (Fig. 8). Unlike congenital ptosis, the eyelid droops more than the normal eyelid when looking down. Detachment causes the crease to lift; thus, the eyelid becomes thinner and vertically longer, and the eye can be seen through it (cadaveric sulcus)^{1,2}(Fig. 9). There is an inherited form of late-acquired aponeurotic ptosis, and there may be a relatively high percentage of congenital aponeurotic ptosis.

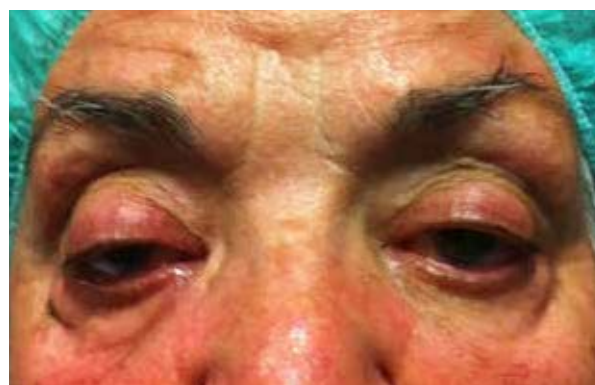

Fig. 8: Aponeurotic ptosis with high eyelid crease.

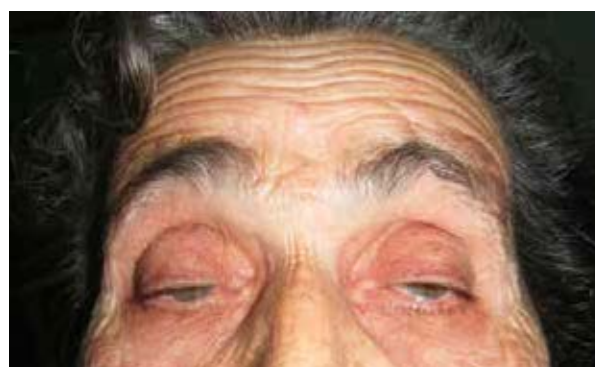

Fig. 9: Aponeurotic ptosis with cadaveric sulcus.

Neurogenic ptosis

Third nerve pair palsy

This is characterized by an association of ptosis, exotropia and mydriasis^{1,2,4}.

There are congenital forms of unknown cause associated with abnormal embryo development, but they can also be related to labor. Transient forms in childhood occur through viral infections or after vaccination. They do not usually affect the pupil and extrinsic motility impairment varies.

Acquired forms tend to have a sudden onset and may affect the pupil. The most common cause is ischemic mononeuropathy associated with diabetes

and hypertension. Here, the pupil is rarely affected and resolution occurs in 3-4 weeks. Other causes can be compressive (posterior communicating artery aneurism) or mesencephalic (tumors, infarction, demyelinating damage) injuries as well as cavernous sinus thrombosis.

Concomitant aberrant regeneration can occur. Typically, the regeneration results in eyelid retraction associated with eye adduction and depression.

Horner's syndrome

Horner's syndrome is an oculosympathetic palsy typically characterized by the triad of ptosis, miosis and anhidrosis. An injury of the sympathetic fibers causes paresis of Müller's muscle, resulting in mild, 1-2-mm ptosis^{1,2,4,7}.

Horner's syndrome can be idiopathic and congenital, caused by injury to the brachial plexus during labor or by uterine neuroblastoma. Congenital forms often show heterochromia of the iris, with an ipsilateral lighter colored iris (Fig. 10 and Fig.11).

Acquired forms may develop in different locations along the sympathetic chain. There are preganglionic lesions at the cervical first-order neuron, such as the occlusion of the vertebral artery in the cervical spine; thoracic lesions at the second-order neuron, such as a Pancoast tumor or aortic aneurysm; and postganglionic lesions at the third-order neuron in the neck, base of the skull, cavernous sinus or eye socket.

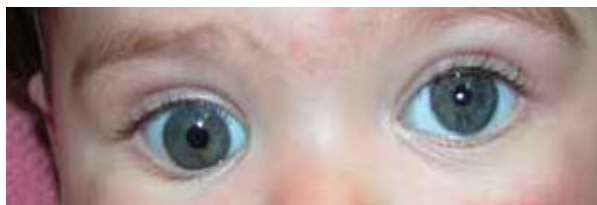

Fig. 10: Congenital Horner's syndrome with heterochromia of the iris.

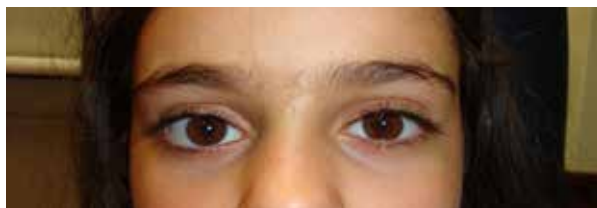

Fig. 11: Horner's syndrome caused by injury of the brachial plexus, with minimal left superior ptosis.

Neurogenic ptosis (acquired forms)

Acquired myogenic ptosis is rare and usually results from muscular conditions such as myasthenia gravis, progressive external ophthalmoplegia, myotonic dystrophy and oculopharyngeal muscular dystrophy^{1,2,4,6,7}.

Progressive external ophthalmoplegia

This is a progressive mitochondrial myopathy which causes bilateral ptosis and progressive ophthalmoplegia affecting the extrinsic, but not intrinsic, muscles. Fifty per cent of cases are inherited and start to manifest in childhood. Clinically, it is characterized by bilateral ptosis and extrinsic muscle changes with primary position in hypotropia. With disease progression, muscles become totally motionless and cause severe ptosis. (Fig. 12)

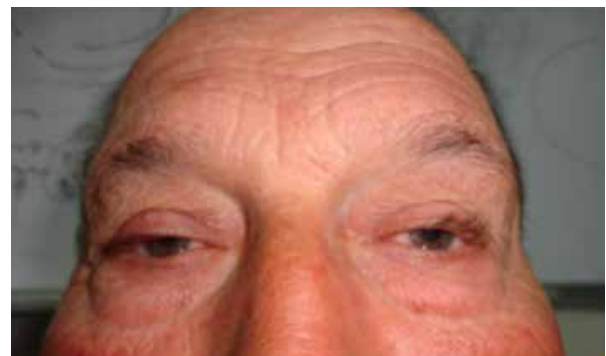

Fig. 12: Severe bilateral ptosis in progressive external ophthalmoplegia.

Myasthenia gravis

Myasthenia gravis is an autoimmune disease characterized by the presence of antibodies against acetylcholine muscarinic receptors at the neural plate, thus preventing neurotransmission.

It presents as variable asymmetrical bilateral ptosis with associated oculomotor disturbances (diplopia, oculomotor paresis). Intrinsic ocular motility is always spared (Fig. 13). At first, symptoms increase at the end of the day and resolve with rest. Ptosis is often aggravated by fasciculations when the patient is asked to gaze steadily upwards. Ptosis may be the first manifestation of myasthenia gravis.

Diagnosis can be made easily at an appointment, using the cold test. An ice pack is applied to the eyelids for 5 minutes, which makes ptosis disappear.

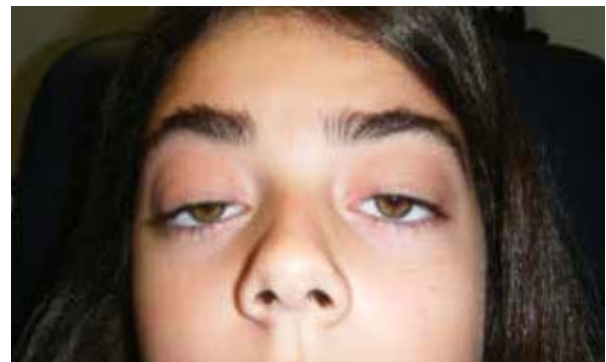

Fig. 13: Child with Myasthenia gravis with no associated oculomotor disturbances.

10 . Blepharoptosis

The cold acts upon the motor plate by reducing acetylcholinesterase activity, increasing the efficiency of existing acetylcholine. A diagnosis is made in 90% of myasthenic ptosis cases.

The diagnosis can be confirmed with the Tensilon test (edrophonium chloride) or the Prostigmin test.

Mechanical ptosis

Mechanical ptosis results from an increase in palpebral weight and volume. Early mechanical ptosis can cause aponeurotic detachment and so become aponeurotic ptosis as well. Any inflammatory, infectious, tumor or scarring process can cause mechanical ptosis^{1,2,4} (Fig. 14,15).

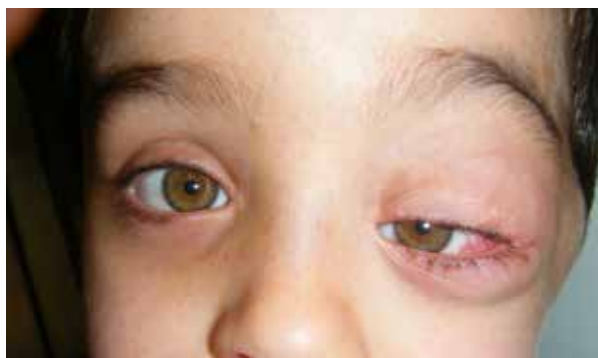

Fig. 14: Mechanical ptosis in a child with a plexiform neurofibroma.

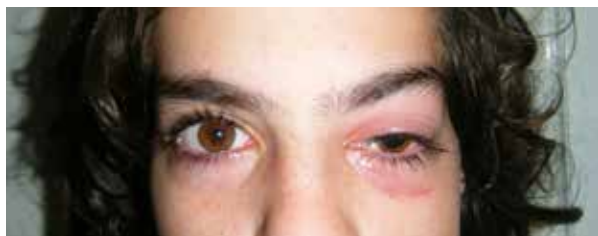

Fig. 15: Mechanical ptosis in a child with orbital inflammatory syndrome.

Traumatic ptosis

Traumatic ptosis can have different etiologies: neurogenic, myogenic or aponeurotic¹.

The most common cause is work accidents, followed by road accidents, sports accidents, assaults and domestic accidents (Fig. 16,17).

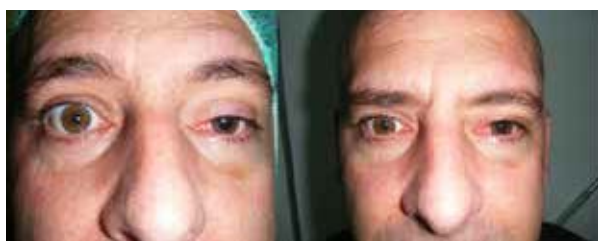

Fig. 16: Left traumatic ptosis before and after surgery.

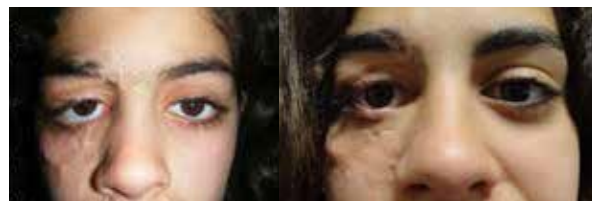

Fig. 17: (1) Traumatic ptosis secondary to burn; (2) post operatory.

Clinical assessment

The clinical history is the key to the study of ptosis. It should be determined whether ptosis is congenital or acquired; if acquired, the mode of onset (sudden vs. progressive), progression and variation in time must be ascertained. It is also important to obtain the personal, family, general and ophthalmologic history. In case of doubt, old photographs can help establish the type of ptosis^{1,2,7,8}.

First, the patient is examined for head position, eyelid position (whether ptotic or resulting from an attempt to suppress diplopia), and presence of proptosis or changes in oculomotor balance. In unilateral cases, the eye should be compared with the contralateral eye; many cases are bilateral but asymmetrical. The presence or absence of associated frontal compensation should always be determined.

Ptosis is assessed with the patient seated in front of the clinician. All it takes is a ruler and a source of light.

Proper ptosis assessment is essential to selecting the optimal technique and thus to achieving good outcomes.

Before classifying the type of ptosis, we must not forget the standard eyelid values:

- Palpebral fissure: Vertical N10-12 mm; Horizontal N30-31 mm;
- Upper lid height: N1.5 mm below the limbus;
- Margin-reflex distance 1 (MRD1): N4-4.5 mm;
- Margin-reflex distance 2 (MRD2): N5 mm;
- Eyelid crease position: N8-10 mm;
- Lower lid position: N0.

The palpebral fissure is measured in the highest area, usually slightly nasal to the pupil. In newborns, the palpebral fissure is often larger and nearly circular.

The upper eyelid crease results from the insertion of levator muscle aponeurosis fibers in the skin. It may be absent or poorly defined, such as in congenital ptosis, and can be duplicated, asymmetrical or high, in aponeurotic disinsertion. In Asian people, the crease is lower and can be hidden at times. In women, the eyelid crease is usually higher, 9-10 mm from the eyelid limbus.

The position of the lower lid is important when planning surgery. Eyelid retraction carries a risk of enlarged palpebral fissure and postoperative lagophthalmos. (Fig.18)

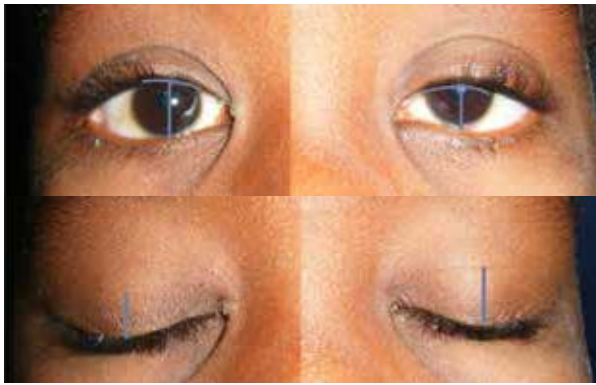


Fig.18: Patient with a left aponeurotic ptosis, left MRD1 of 0, high eyelid crease.

Ptosis grade

- Mild ptosis: ≤ 2 mm, at the upper pupillary border (Fig.19)
- Moderate ptosis: 3-4 mm, partially covers the pupil (Fig.20)
- Severe ptosis: >4 mm, the pupil is fully covered (Fig.21)

Ptosis is graded with the patient sitting in front of the clinician, eyes in primary position, with no elevation of the chin and a relaxed front. The assessment is difficult in children, so the patient is often asked to look at the lantern light to facilitate the assessment. Measurement is taken on a non-dilated pupil of approximately 4 mm.

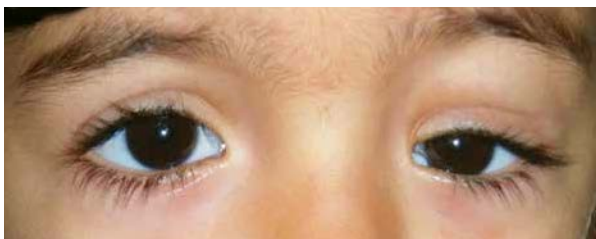

Fig. 19: Mild ptosis.

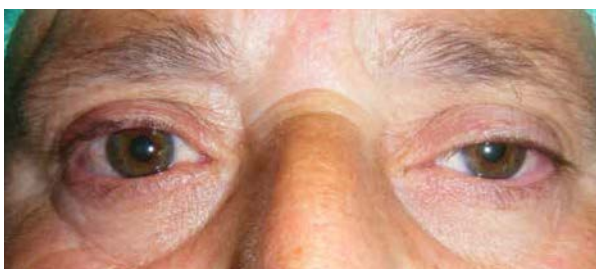

Fig. 20: Moderate ptosis.

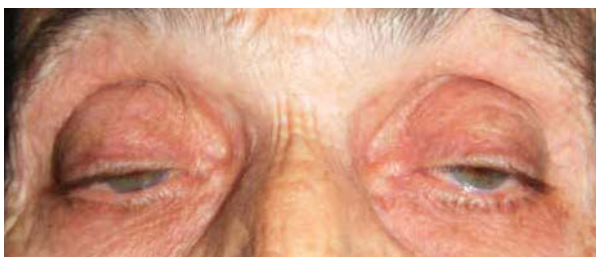

Fig. 21: Severe ptosis.

Palpebral levator muscle function

This is a very important measurement for surgical planning. This value will determine the selection of the surgical technique.

It is measured by assessing upper eyelid excursion from downgaze to upgaze, while blocking frontalis muscle action. Levator function is usually >15 mm (Fig.22).

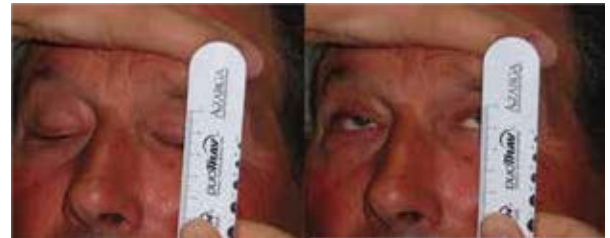

Fig. 22: Moderate ptosis with a Palpebral levator muscle function of 10mm.

The assessment is difficult in children, and often only an approximate value is obtained.

Palpebral levator muscle function can be classified in several ways. The function is good for values >10 mm, moderate between 8 and 10 mm, weak between 5 and 7 mm and poor when <4 mm.

Head position

It is important to assess head position. Ptosis often presents with a compensating torticollis with chin elevation. Torticollis in bilateral ptosis reduces the probability of amblyopia.

Marcus Gunn synkinesia

Five per cent of congenital ptosis cases have Marcus Gunn synkinesia. This can be explored by asking parents to give the child a pacifier or asking them to chew. Determining the presence of Marcus Gunn synkinesia is important because it can influence surgical decisions. An unstable eyelid position greatly hinders surgical programming, often requiring subcorrection. Synkinesia generally improves with age and becomes less severe.

Bell's phenomenon

Bell's phenomenon is the upward movement of the ocular globe at the time of eyelid closure. It is measured by asking the patient to close their eyes while the clinician secures the eyelids with the fingers. This allows the upward eye movement to be seen. If absent, hypocorrection is mandatory at surgery to avoid corneal exposure. Bell's phenomenon is often absent in mitochondrial myopathy and ophthalmoplegia.

Palpebral closure

Lagophthalmos can predispose to postoperative complications. Surgical hypocorrection is essential in such cases.

Eyelash position

In children, eyelash verticalization may be associated with some aponeurotic disinsertion; in adults, with eyelid laxity.

Ocular motricity

Ocular motor assessment is important to detect associated ocular motor paralysis, abnormal development of the superior rectus/levator muscles, and acquired lesions, such as myasthenia gravis, progressive external ophthalmoplegia and aberrant regenerations.

In 5% of the cases, ptosis may be associated with elevation paresis caused by superior rectus muscle debility. Bell's phenomenon is often reduced in such cases.

Ptosis may mask strabismus, especially if vertical. A cover test will diagnose pseudoptosis due to hypotropia. In these cases, the eyelid rises when the hypotropic eye is fixating.

Any associated strabismus should be corrected before ptosis.

Pupillary examination

Pupillary examination is important to detect associated congenital or acquired pupillary abnormalities.

Visual acuity

Patients should be screened for amblyopia and refraction should be conducted to determine whether anisometropia is present. The presence of severe amblyopia may require earlier treatment, before the age of one year.

Corneal sensitivity

Corneal sensitivity should definitely be assessed, because in hypoesthesia or anesthesia it is important to reinforce postoperative corneal lubrication. Furthermore, it can often lead to a planned surgical hypocorrection.

Tear film assessment

Reduced tear film can predispose to postoperative complications.

Phenylephrine test

A drop of a 10% phenylephrine solution is instilled and eyelid position is assessed after 10 minutes. This test will identify a functional Müller muscle. The test is positive when the eyelid rises to a normal and symmetrical position when compared with the contralateral eye. In positive cases, a surgical technique to resolve ptosis can be performed on the Müller muscle. It is also an important test in asymmetric cases to identify a bilateral ptosis. The compensating frontalis contraction can normalize one of the eyelids in cases of asymmetric bilateral ptosis, which can lead us to identify only a unilateral ptosis in initial assessment. Phenylephrine is applied in the ptotic eye and if the

opposite eyelid lowers, bilateral ptosis is confirmed and a bilateral procedure should be done for a satisfactory result¹. (Fig. 23)

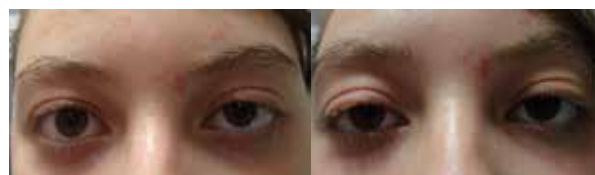

Fig. 23: (1) Apparent unilateral left ptosis, (2) After phenylephrine in the left eye, the contralateral eyelid drops, thereby identifying a bilateral ptosis.

Imaging

In changed pupillary reflexes, suspected third-pair injury and acute ptosis, it is mandatory to perform an imaging examination for etiological diagnosis, particularly of compressive lesions.

Treatment

Indications

Ptosis treatment is always surgical. It is a challenging treatment, since it involves both eyelid elevation and esthetically acceptable symmetry. Therefore, indications for ptosis treatment are both functional and esthetic. Ptosis causes visual field reduction, ocular fatigue, asthenopia symptoms and a feeling of heavy eyelids. Esthetically, ptosis causes image and self-esteem changes and can cause isolation and depressive symptoms^{2,5}.

There is no optimal age for surgical treatment in children. In the absence of amblyopia, surgery can wait until 4-5 years of age (preschool). At this age, children already cooperate in preoperative assessment, including in assessing levator muscle function, which is a determining factor for a good surgical outcome. If visual acuity is compromised, surgery should be conducted in the child's first months.

In neurogenic or traumatic ptosis, it is best to wait at least 6 to 9 months before embarking on surgery.

Anesthesia

Local anesthesia with sedation is the standard in ptosis surgery. It provides improved esthetic and functional intra-operative outcomes. Children are the only exception. Local anesthesia should be tried even in adolescence.

The author uses a combination of 50% of 1% lidocaine with adrenaline and 0.5% bupivacaine. This association combines the benefits of lidocaine's rapid onset of action with bupivacaine's long-lasting effect.

Surgical technique

The best surgical technique is the one acting on the levator muscle aponeurosis, because it is more

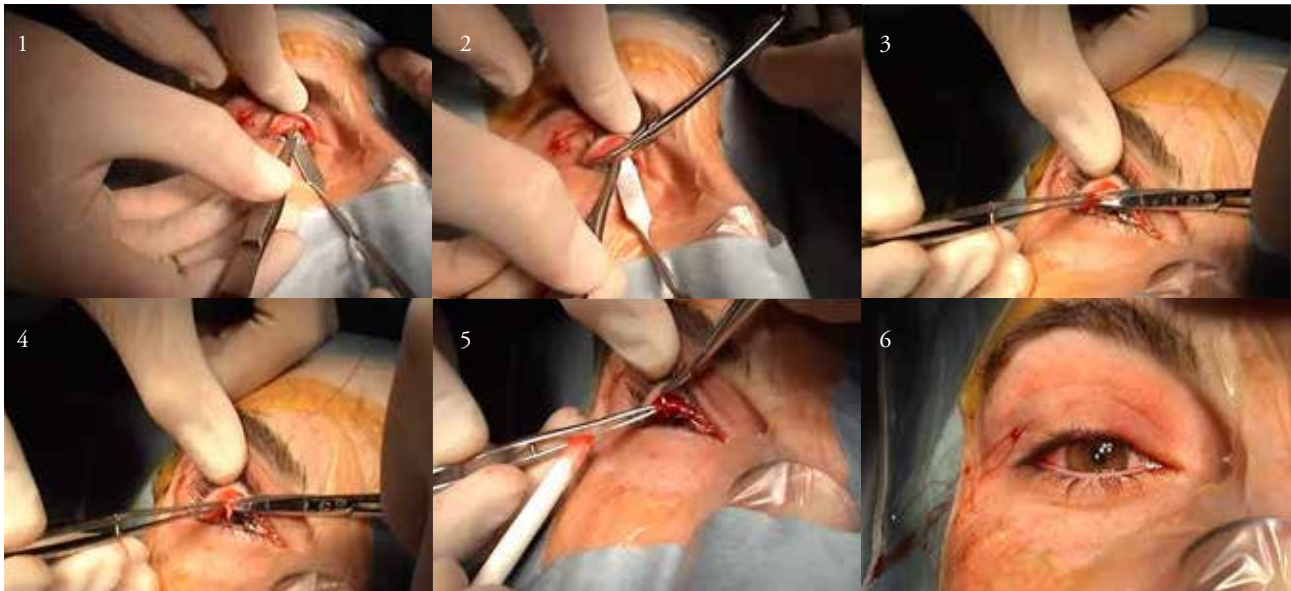


Fig. 24: Conjunctival-Müllerectomy technique: (1) Eversion of the superior eyelid; (2) hemostatic clamp securing the conjunctiva and the Müller's muscle; (3,4) conjunctiva and Müller's muscle are excised; (5,6) suture of conjunctiva and the Müller's muscle to the tarsus with an absorbable 6-0 externalized suture.

physiological. Even when levator muscle function is weak, the aponeurosis should be used (Fig. 23). In such cases, supramaximal resection is performed.

The choice of technique depends on levator muscle function and the type of ptosis. Different techniques are indicated according to the millimeters of eyelid levator muscle function:

- 1 to 3mm: frontal suspension;
- 4 to 7 mm: aponeurosis resection (cutaneous resection);
- 7 to 12mm: aponeurosis resection (cutaneous or conjunctival route).

In aponeurotic ptosis, only aponeurosis reinsertion is required, with no resection. This repositioning can be performed using a cutaneous or conjunctival approach. Procedures on Müller's muscle are indicated in 1-2 mm mild ptosis, with good levator muscle function and positive phenylephrine test⁷. They can also be used in mild hypocorrection after other surgical procedures.

Procedures on Müller's muscle

Conjunctival-Müllerectomy

Techniques on the Müller muscle were first conducted by Fasanella and Servat in 1961⁹. They consisted of a tarsal-conjunctival resection. Later, in 1975, Putterman describes the conjunctival Müllerectomy technique in which only the conjunctiva and the Müller muscle were resected, without tarsal resection⁹. Technique (Fig. 24):

- The upper lid is everted.
- With a caliper, half of the planned resection is marked (3, 4 or 5mm) from the upper tarsal margin.

- A hemostatic clamp is used to secure the conjunctiva and the Müller muscle to be excised.
- Conjunctiva and Müller's muscle are excised.
- The conjunctiva and the Müller muscle are connected to the tarsus using an absorbable 6-0 externalized suture.

Several tables correlate the resectable amount in millimeters either with the phenylephrine test or with millimeters of ptosis. A simple rule of thumb used by the author is: if the phenylephrine test places the eyelid in a normal position, resect 8 mm; in hypocorrection, resect 9-10 mm; in hypercorrection, resecting 6-7 mm is enough.

Aponeurosis resection

Cutaneous approach

The cutaneous route is more anatomical and is therefore easier to perform. It can be used in resections even with low levator muscle function.

Technique:

- The crease is marked. In unilateral ptosis, mark the crease at the same level as the contralateral eye. In bilateral ptosis, mark between 8 and 10 mm.

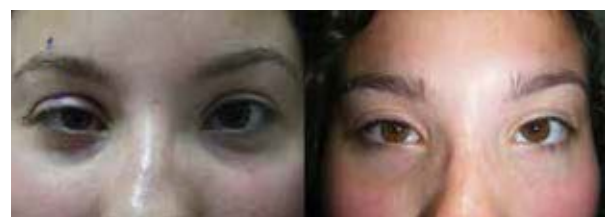
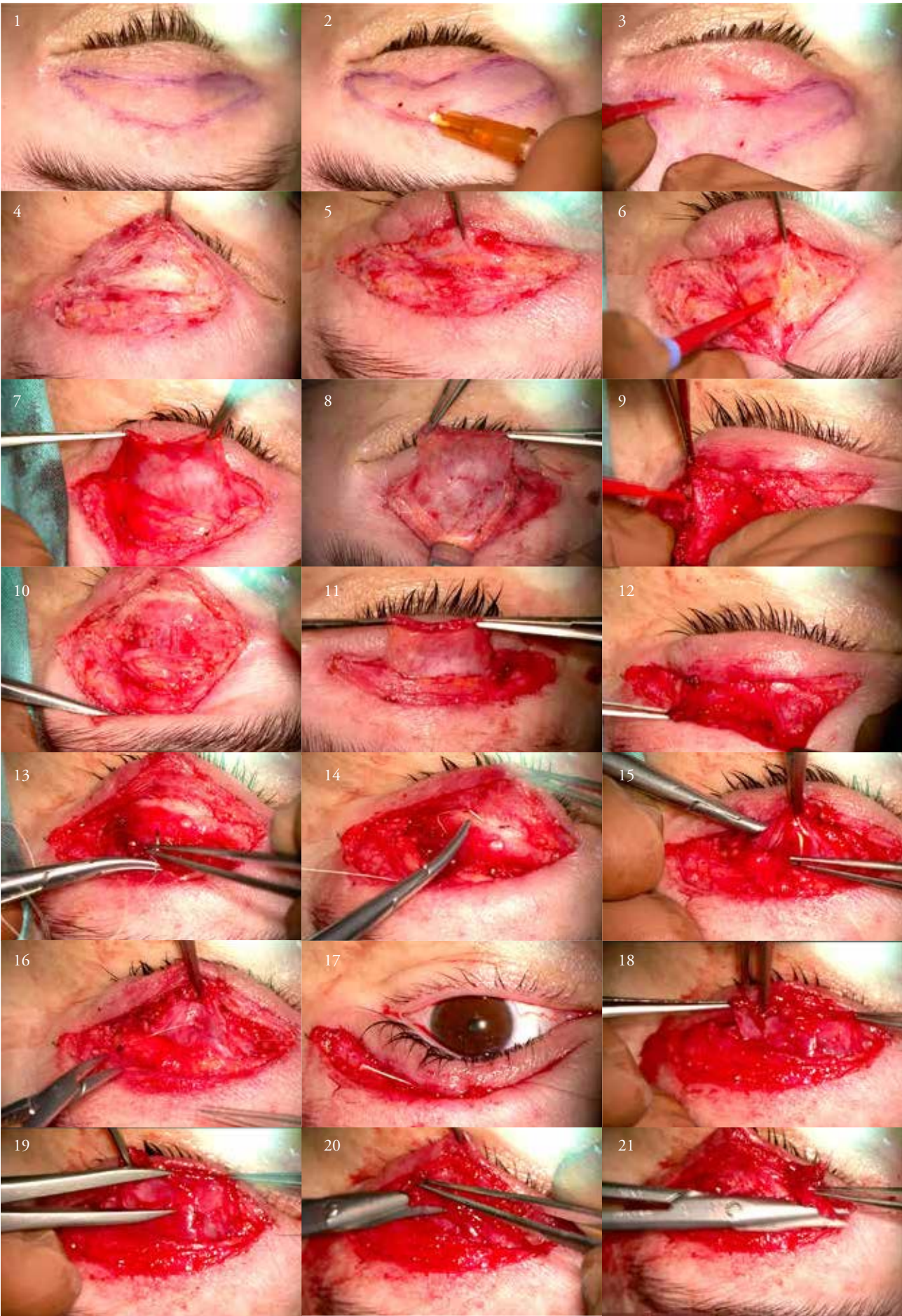
Fig. 25: Ptosis of the right superior eyelid treated with conjunctival-Müllerectomy.



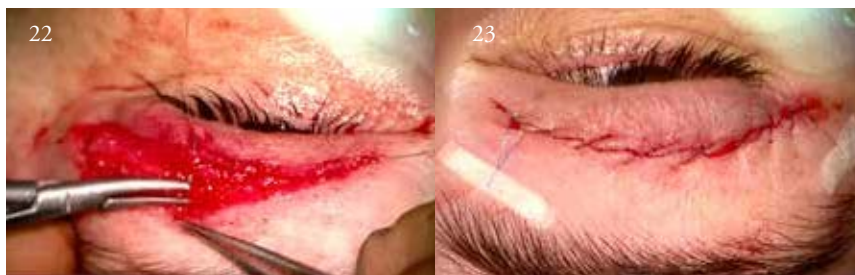

Fig. 26 (previous and current page). Aponeurosis resection, cutaneous approach technique: (1) skin is marked out with a marking pen; redundant skin is also marked to perform blepharoplasty if necessary; (2) 2-3 ml of anesthetic is injected subcutaneously; (3) cutaneous-muscular incision; (4) dissection of the orbicularis as far as the tarsus; (5) identification of the aponeurosis with dissection between the plane of the aponeurosis and the orbicularis; (6) opening the septum; (7) aponeurosis is released from its lateral insertions; (8) total extension of the aponeurosis exposed as far as Whitnall's ligament; (9) connection between aponeurosis and Müller's muscle; (10) dissection between the aponeurosis and Müller's muscle; (11) Müller's muscle exposed; (12) aponeurosis exposed before resection; (13) (14) (15) U suture of 6/0 polyglactin is placed at the presumably desired position in the aponeurosis and sutured approximately 3 mm from the upper margin of the tarsus; (17) the position and eyelid contour are tested; (18) the aponeurosis is definitively sutured using 3 polyglactin stitches, one central to the pupil, one medial and one lateral; (19) the aponeurosis anterior to the suture is measured; (20) (21) the excising aponeurosis is resected; (22) the orbicularis is sutured with 6/0 polyglactin suture; (23) the skin is sutured with 6/0 polypropylene.

- 2-3 ml of anesthetic is injected subcutaneously, adding 1-2 ml subconjunctivally, if necessary.
- A cutaneous-muscular incision is made at the upper eyelid crease.
- If necessary, redundant skin is resected (blepharoplasty).
- The orbicularis oculi muscle is dissected as far as the tarsus, identifying the aponeurosis.
- The plane between the orbicularis oculi muscle and the aponeurosis is dissected until the septum is identified. The septum is opened, with preaponeurotic fat herniation. The aponeurosis is released from its lateral insertions, to isolate it.
- Lower dissection between the aponeurosis and Müller's muscle is conducted.
- A first stitch (6/0 absorbable) is placed at the presumably desired position in the aponeurosis and sutured approximately 3 mm from the upper margin of the tarsus. The position and eyelid contour is tested.
- If the position of the eyelid is satisfactory, the aponeurosis is definitively sutured using 3 stitches of the same absorbable suture.
- The aponeurosis anterior to the stitches is resected.
- The skin and the orbicularis oculi muscle are sutured in planes. The orbicularis is sutured with 6/0 absorbable suture and the skin with 6/0 polypropylene or nylon. To mark the eyelid crease, 2-3 stitches can be placed in the orbicularis muscle - aponeurosis - orbicularis muscle, with the objective of fixating the aponeurosis.

The amount of aponeurosis/muscle to be resected depends on the degree of ptosis and elevator function. Two factors should nonetheless be considered: Bell's phenomenon and the orbicularis oculi muscle's strength. Cases of weakness should be hypocorrected.

There are several tables that relate the number of millimeters to be resected to the degree of ptosis and the levator muscle function^{1,2,4,5}. However, the surgeon's experience is the most important factor for determining the extent of resection. Traditionally, it is accepted that with good levator function 3 mm is resected for each millimeter of ptosis; with reasonable function, 4 mm per millimeter, and in poor function cases 5 mm should be resected per millimeter of ptosis. The author bases the amount of resection on the intra-operative upper eyelid height:

- Levator function up to 7-8 mm: free margin at 0;
- Levator function of 8-12 mm: free margin + 1;
- Levator function over 12 mm: free margin +2.

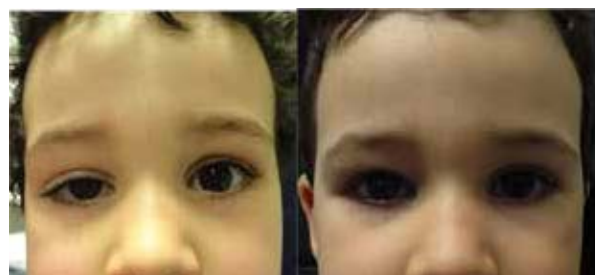

Fig. 27: Unilateral congenital ptosis; cutaneous approach.



Fig. 28: Unilateral congenital ptosis; cutaneous approach.

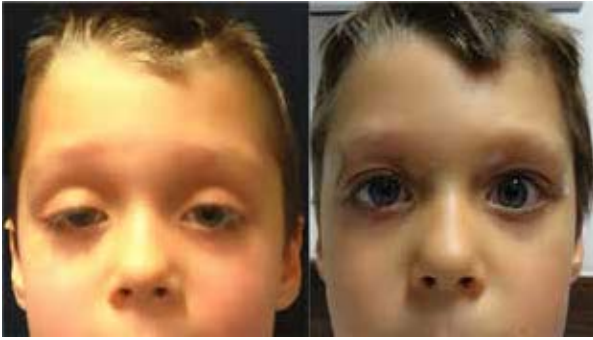

Fig. 29: Bilateral congenital ptosis; cutaneous approach.

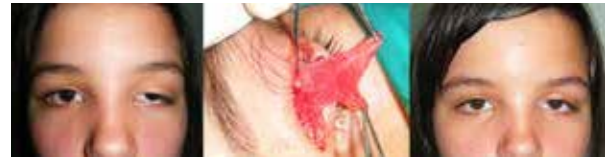

Fig. 30: Unilateral congenital ptosis with supramaximal resection.

Conjunctival approach

This technique is effective in any ptosis with good to moderate levator muscle function. It is ideal for treating senile aponeurotic ptosis with good levator muscle function. Moreover, it enables resection and

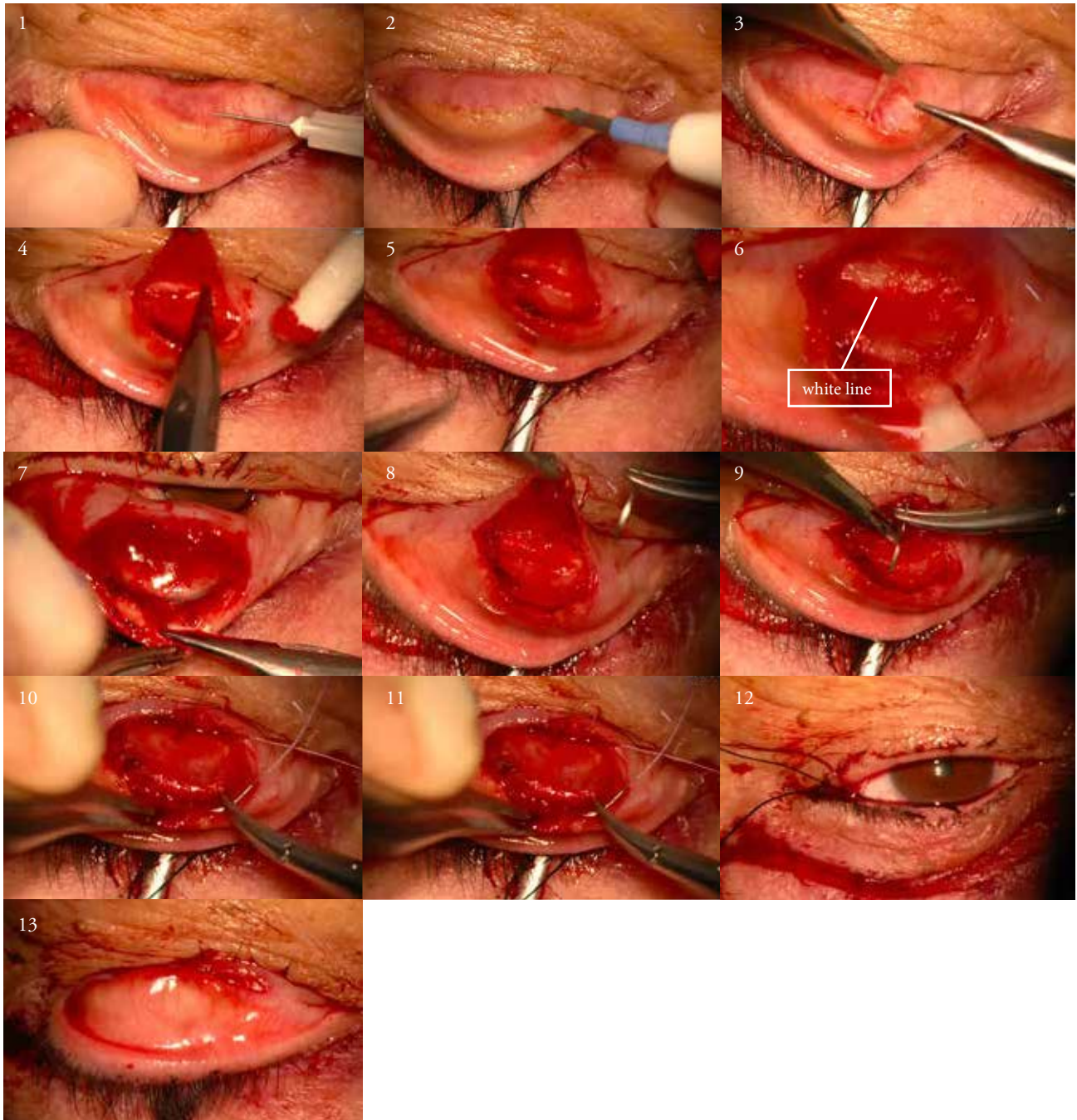


Fig. 31. Conjunctival approach technique: (1) infiltration of the anesthetic between the Müller muscle and the aponeurosis; (2) incision along the upper tarsal border; (3) (4) dissection in the plane between conjunctiva/Müller muscle and the aponeurosis up to about 1 cm superiorly; (5) (6) identification of the aponeurosis distal posterior surface (white line); (7) dissection of anterior tarsal surface; (8) (9) (10) (11) the aponeurosis distal posterior surface is sutured on the anterior tarsal surface; (12) the position and eyelid contour are tested (13) Müller's muscle and conjunctiva are not sutured.

does not prevent an associated blepharoplasty. The posterior approach route is quick and simple, with no external scar and faster postoperative recovery. It provides more predictable physiological height and eyelid contour than the cutaneous approach. It does not require a positive phenylephrine test^{1,9,10}.

It consists of advancing the aponeurosis distal posterior surface (white line) without resecting the Müller muscle or the conjunctiva.

Technique (Fig. 31):

- 1 ml anesthetic is infiltrated subcutaneously at the eyelid crease.
- The eyelid is everted with a Desmarres retractor and a 4/0 silk traction suture.
- 0.5 ml anesthetic is infiltrated into the plane between the Müller muscle and the aponeurosis.
- The conjunctiva and the Müller muscle are incised along the upper tarsal margin.
- The dissection of the conjunctiva/Müller muscle from the aponeurosis is performed up to about 1 cm superiorly.
- The aponeurosis distal posterior surface (white line) is easily identified by slightly releasing retractor traction.
- The anterior tarsal surface is dissected up to one-half of its vertical length.
- With or without resection, the aponeurosis distal posterior surface is sutured with 2-3 stitches (6/0 absorbable suture) on the anterior tarsal surface. One stitch is often enough.
- There is no need to suture the Müller muscle or the conjunctiva.

Frontalis muscle suspension techniques

The aim is to directly or indirectly exert traction on the upper tarsus with the frontalis muscle^{1,2,3}. This technique is indicated in ptosis with poor/non-existent levator function⁷. Generally, it is also used in myogenic ptosis with severe muscular dystrophy, Marcus Gunn syndrome, blepharophimosis syndrome, and in extra-ocular muscle fibrosis syndrome.

The materials can be either heterologous, such as Gore-Tex (PTFE), silk or silicone, or autologous (fascia lata and temporal fascia). Synthetic materials are associated with a higher risk of infection and extrusion. The use of the fascia is associated with better-lasting results.

Before 3 years of age, heterologous compounds such as Gore-Tex or silicone should be used, since the fascia is still not fully developed. In all other situations, it is always better to use the fascia, and temporal fascia does not result in another visible scar, and accelerates postoperative recovery.

Temporal fascia harvest (Fig. 35)

Temporal fascia is harvested by making a 5-6 mm vertical incision on the scalp, following the bitemporal line between the ears. The advantage is that it leaves no scar. Strips 8 cm long and 3 mm wide are collected.

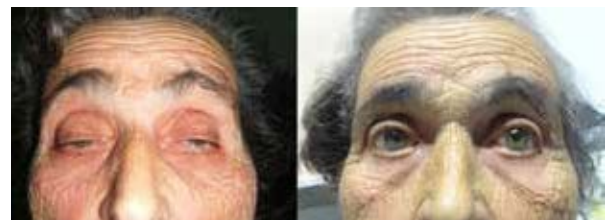

Fig. 32: Bilateral aponeurotic ptosis; Conjunctival approach.

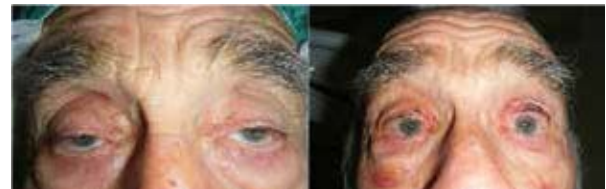

Fig. 33: Bilateral aponeurotic ptosis; Conjunctival approach.



Fig. 34: Unilateral congenital ptosis; Conjunctival approach.

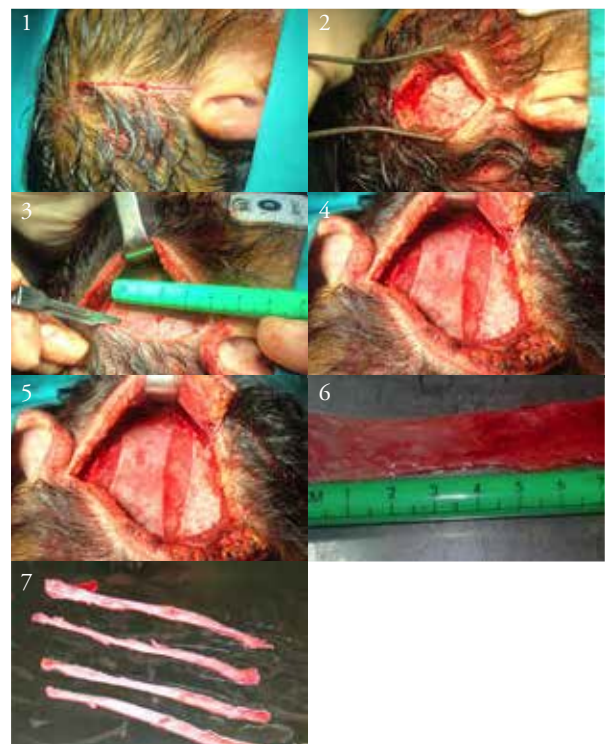

Fig. 35: Temporal fascia harvest: (1) 5-6 mm vertical incision on the scalp; (2) (3) dissection as far as the fascia plane; (4) (5) collect a rectangle of fascia measuring 8 by 1.5-2 cm; (6) (7) cut 4 strips 8 cm long and 3 mm wide.

Fascia lata harvest (Fig. 36)

The fascia lata is collected from the outer side of the thigh, 8 cm above the lateral tibial condyle, with the knee bent at 90°. The fascia lata can be collected using a fasciotome.

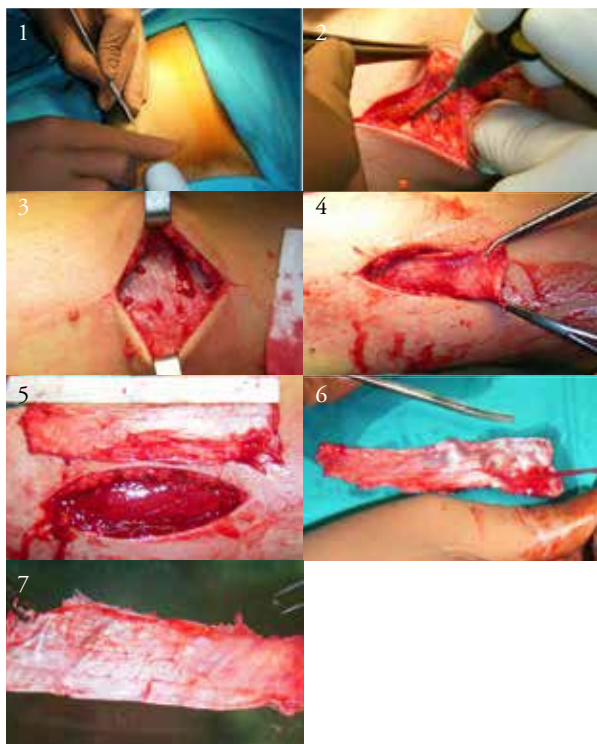


Fig. 36: Fascia lata harvest: (1) 6-8 cm vertical incision; (2) (3) dissection as far as the fascia plane; (4) (5) collect a rectangle of fascia measuring 8 by 1.5-2 cm; (6) (7) remove the fascia muscle remains.

Fox technique

Fox's technique is favored when placing heterologous material such as Gore-Tex and silicone⁴. (Fig. 37)

- Two cutaneous incisions are made 4 mm from the eyelid margin as far as the tarsus, one medial and one lateral.
- Three supraciliary cutaneous incisions are made as far as the periosteum: 2 lateral just above the brow and 1 medial, 8 mm from the brow.
- The PTFE/silicone is passed through the incisions. The silicone sling uses a stainless steel needle and the PTFE is passed with the Wright needle.
- The strips are stretched until the eyelid margin reaches the desired height. Then they are secured with a silicone rod break.
- The brow incisions are sutured with absorbable sutures. The eyelid incision don't need to be sutured.

Modified Crawford technique

This technique consists of making two isosceles triangles and is mostly used to place temporal fascia or fascia lata. The fascia should be placed deeply below the orbicularis oculi muscle. (Fig. 40) In the original Crawford technique, a third, higher, central brow incision was performed connecting both triangles⁴. Two Strips of fascia (8 cm by 3 cm) are needed for each eyelid.

- Three skin incisions are marked 4 mm from the free eyelid margin, one central incision aligned with the pupil and two lateral incisions.

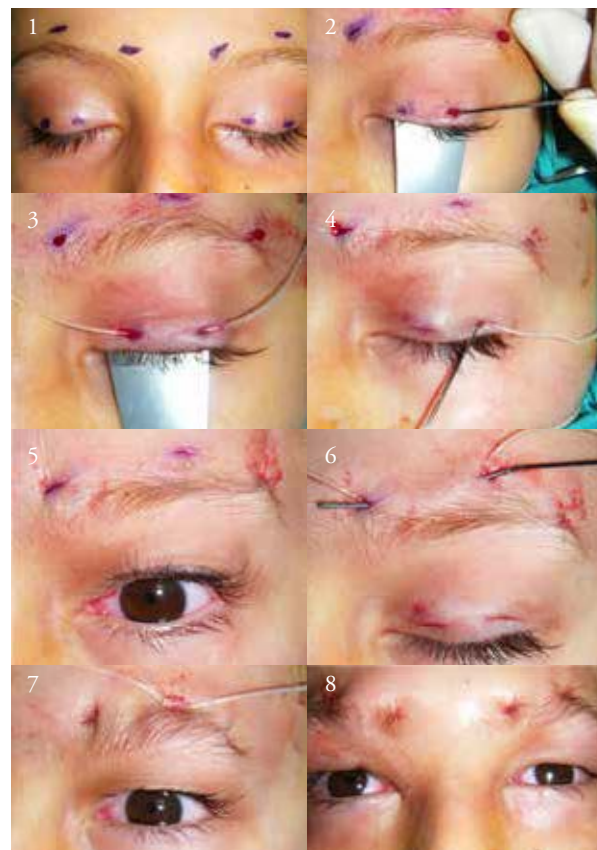

Fig. 37: Fox technique: (1) incisions are marked; (2) (3) the silicone with the needle is passed in the two eyelid margin incisions; (4) (5) the silicone is then passed below the orbicularis muscle to the medial and lateral brow incisions; (6) the needle with the silicone is passed to the central brow incision; (7) the strips are stretched until the eyelid margin reaches the desired height, and secured with a silicone rod break; (8) the brow incisions are sutured with 6/0 polyglactin.

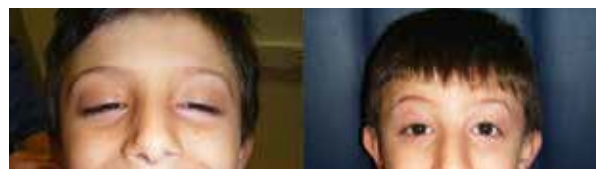

Fig. 38: Bilateral congenital ptosis; frontalis muscle suspension with silicone sling.

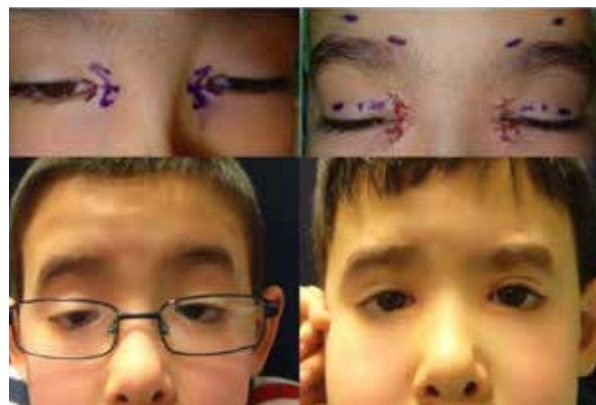

Fig. 39: Blepharophimosis syndrome; Mustardé procedure to both medial canthus; frontalis muscle suspension with silicone sling.

- Two supraciliary incisions are marked at the level of the eyelid sides.
- The fascia is passed through the incisions using a Wright needle.
- Eyelid position is adjusted by strip traction.
- Fascia knots are tied at the supraciliary incisions and secured using a resorbable suture.
- Brow skin incisions are closed with absorbable or non-absorbable 6/0 sutures (polyglactin/polypropylene).

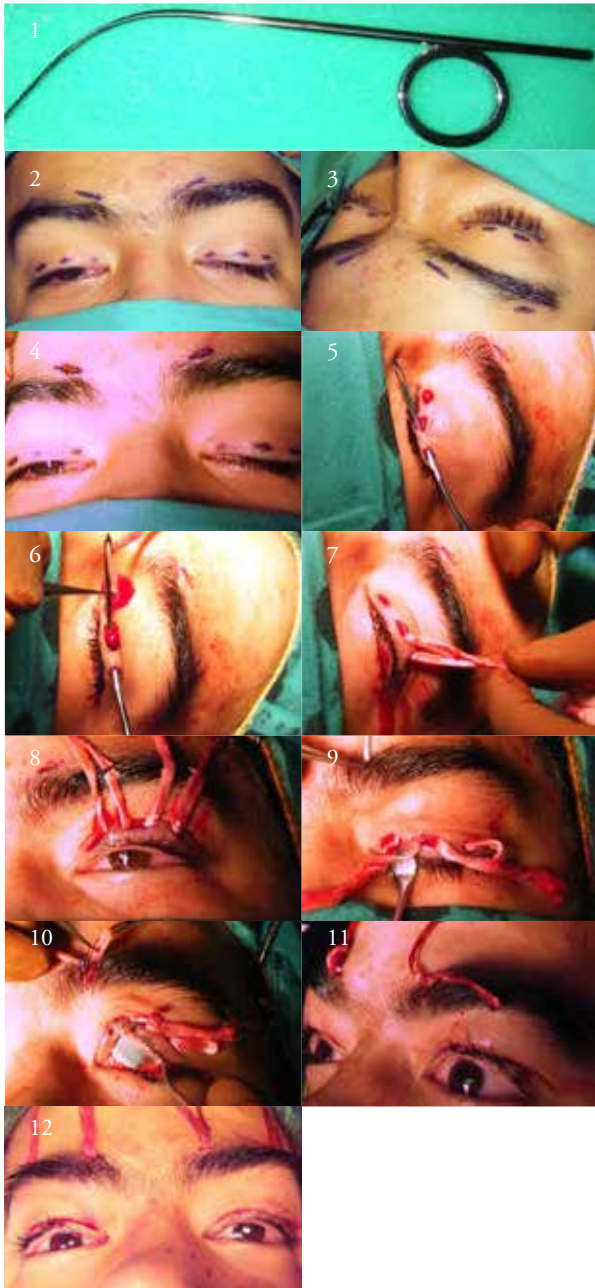

Fig. 40: Modified Crawford technique: (1) Wright needle (2) (3) incisions are marked, 3 incisions in the eyelid and 2 incisions in the brow; (4) brow incisions are deep, reaching the periosteum; (5) (6) (7) (8) each fascia is passed through the eyelid incisions with the wright needle; (9) (10) (11) the fascia is then passed to the brow incisions making the two isosceles triangles; (12) fascia knots are tied at the supraciliary incisions, adjusting the desired eyelid height.

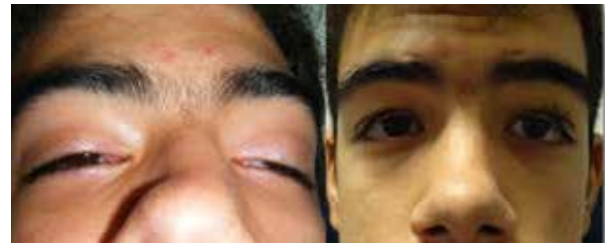

Fig. 41: Bilateral congenital ptosis; frontalis muscle suspension with temporal fascia.

Postoperative care

In myogenic ptosis with major resection or in frontal suspension procedures, it is important to insert a Frost suture for approximately 24 hours to avoid immediate postoperative corneal exposure. (Fig. 42) Postoperative lagophthalmos is common and often persists for several months, so abundant lubrication is essential. Many authors argue that nocturnal occlusion should be used until the lagophthalmos resolves. In the first 48 hours, ice should be applied locally four times a day for approximately 30 minutes. Topical antibiotic eye drops, either in association with an anti-inflammatory drug nor not, are prescribed four times a day for one week.

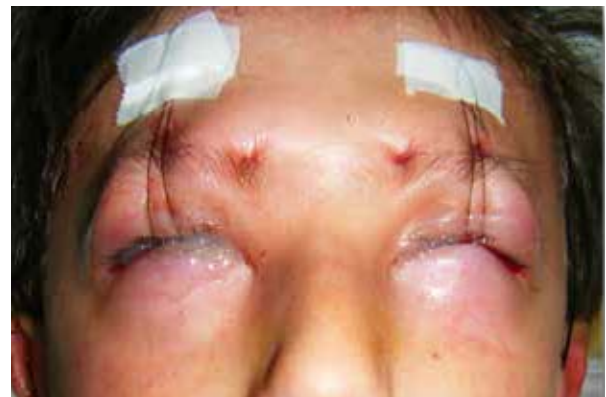

Fig. 42: Frost suture.

Complications

Hypocorrection

This is the most frequent complication⁸. Hypocorrection is usually due to insufficient aponeurosis resection^{4,7}. It is more common in myogenic ptosis, because levator function is usually very poor. Such cases often require reoperation. (Fig. 43) Procedures on the Müller's muscle are the technique of choice for mild hypocorrections of approximately 2 mm.

Postoperative bruising and inflammation can cause transient ptosis, which resolves spontaneously. (Fig. 44) Hypocorrection can be necessary in orbicularis impairment or poor Bell's phenomenon.

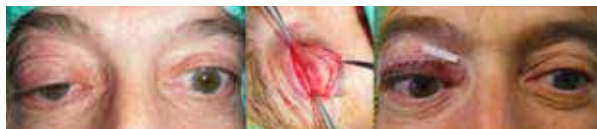

Fig. 43: Bilateral aponeurotic ptosis with right hypocorrection; reoperation by cutaneous approach.



Fig. 44: (1) Hypocorrection due to hematoma in the first day of post operatory; (2) Third day of post operatory with desired eyelid height and contour.

Hypercorrection

Hypercorrection is more common in aponeurotic ptosis, and most cases do not require reoperation¹. These patients present with eyelashes pointing vertically and corneal epithelial conditions due to severe lagophthalmos. Immediate postoperative maneuvers, such as palpebral massage, eversion with a Desmarres retractor or Frost suture may resolve up to 2-3 mm of hypercorrection⁷. These maneuvers weaken the aponeurosis insertion into the tarsus. When reintervention is needed, it is often enough to remove one of the stitches that connects the aponeurosis to the tarsus. (Fig. 45)

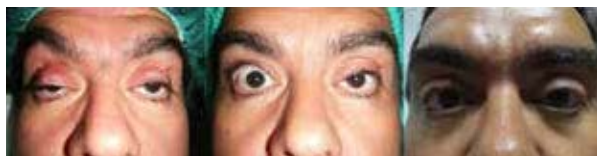

Fig. 45: (1) Bilateral congenital ptosis treated previously with frontalis muscle suspension with nylon suture, presenting a palpebral levator muscle function superior to 10 mm bilaterally; (2) Hypercorrection of the right eyelid after a bilateral aponeurosis resection and the removal of the nylon suture; (3) post operatory after the reoperation of the right eyelid.

Other complications

Other complications may include asymmetrical upper eyelid crease, eyelid mispositioning such as ectropion and entropion, infections and reactions to the aloplastic material⁴. The most common rejection complications are granulomas at the incision sites in frontalis muscle suspension, often associated with Gore-Tex. (Fig. 46, Fig. 47) Lagophthalmos is also a complication, but it is transient in most cases. In some cases, such as in major resections or frontalis suspension procedures, lagophthalmos may last for several months or even forever^{4,8}.

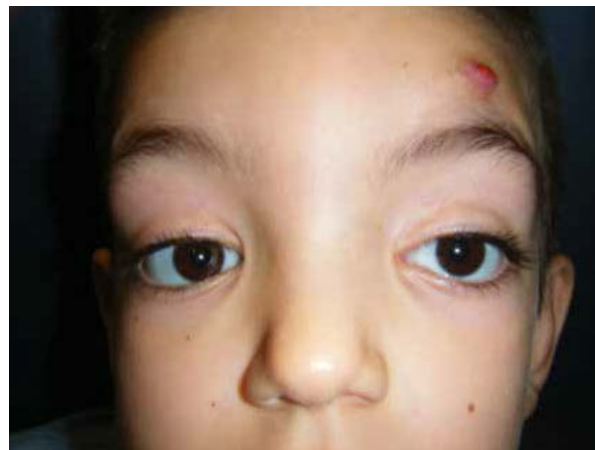

Fig. 46: Granuloma in the supraciliary incision site.

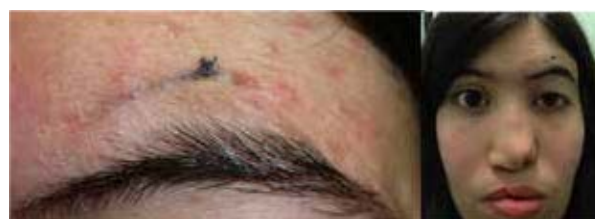

Fig. 47: Suture exposure .

References

1. Pimentel de Figueiredo AR. Blepharoptosis. *Seminars in Ophthalmology* 2010;25(3): 39-51
2. Sánchez EM. Ptosis palpebral: tipos, exploración y tratamiento quirúrgico. 2005; Ergon
3. SooHoo JR, Davies BW, Allard FD, Durairaj VD: Congenital ptosis. *Survey of ophthalmology* 2014; 59(5):483-492
4. Leatherbarrow B. *Oculoplastic Surgery*. 2002. Chapter 2: 21-47; Martin Dunitz Ltd
5. Nerad JA. *Techniques in ophthalmic plastic surgery. A personal tutorial*. 2010. Chapter 8: 201-236; Elsevier Saunders
6. Sudhakar P, Vu Q, Kosoko-lasaki O, Palmer M. Upper eyelid ptosis revisited. *American Journal of Clinical Medicine*. 2009;6:5-13
7. Dutton JJ. *Atlas of oculoplastic and orbital surgery*. 2013. Chapter G: 80-103; Lippincott Williams and Wilkins
8. Ahmad SM, Della Rocca RC. Blepharoptosis: evaluation, Techniques, and Complications. *Facial Plastic Surgery* 2007;23:203-216
9. Patel V, Salam A, Malhotra R. Posterior approach white line advancement ptosis repair: the evolving posterior approach to ptosis surgery. *Br J Ophthalmol* 2010; 94:1513-1518
10. Ichinose A, Tahara S. Transconjunctival levator Aponeurotic Repair Without Resection of Muller's Muscle. *Aesth. Plast. Surg* 2007;31:279-284

11 . Trichiasis

Ana Magriço, Ana Amaro, Ana Cabugueira

Definitions

Trichiasis: lid margin disorder in which the eyelashes arising from their normal position are misdirected against the ocular surface while the eyelid is in a normal position.^{1,2}

Distichiasis: lid margin disorder in which a second row of eyelashes arising from meibomian gland orifices are misdirected against the ocular surface while the eyelid is in a normal position.¹

Metaplastic lashes: lid margin disorder in which eyelashes arising from an abnormal position are misdirected against the ocular surface while the eyelid is in a normal position.¹

Entropion: the eyelid margin is turned inward, causing eyelashes to touch the eye.

Classification

According to the amount of misdirected eyelashes^{3,4}

- Minor Trichiasis: fewer than 5 cilia
- Major Trichiasis: 5 or more cilia

According to the extent of eyelid involvement^{3,4}

- Segmental (nasal, central or temporal): affects 1/4 to 1/3 of the lid margin
- Diffuse: the whole extent of the lid margin
- Focal: few eyelashes

According to the cause^{4,5}

- Congenital

Epiblepharon: an extra roll of eyelid skin pushes the eyelashes towards the ocular surface. Most commonly found in Asian children, it usually involves more than half of the lower eyelid. Symptoms are usually minimal and in some cases the contact occurs only in downgaze.^{4,5}

Distichiasis: an extra row of eyelashes arises from the meibomian gland orifices. The row is often incomplete and lashes can be fully formed or be smaller and less pigmented. It is a rare autosomal-dominant disorder with variable expression that has been associated with strabismus, ptosis, cleft palate, congenital ear defects,

trisomy 18, and mandibulofacial dystosis.^{4,5}

- Acquired: ^{4,5}

Marginal entropion: type of cicatricial entropion in which the lid itself is grossly in normal position except for the lid margin, which shows an anterior migration of the mucocutaneous junction and rounding of the lid margin. The parallel orientation and regular spacing between lashes are preserved. It is the most common cause of trichiasis in adults.⁵

Trauma: misdirected lashes that occur as sequelae to previous injury or surgery. They tend to point in random directions and the spacing is often irregular.⁵

Metaplasia: chronic irritation and inflammation (e.g., chemical injuries, posterior blepharitis, Stevens-Johnson syndrome, ocular cicatricial pemphigoid, trachoma) can produce metaplastic changes within the meibomian glands, resulting in aberrant hair growth. Often lashes are shorter and less pigmented.⁵

Clinical Features

The majority of patients are symptomatic. Frequent complaints are foreign body sensation, burning, pain, photophobia, tearing, discharge, recurrent infection, blepharospasm and conjunctival congestion. Ocular surface damage can range from epitheliopathy to abrasions, corneal ulceration, vascularization, scarring, loss of vision and, ultimately, blindness.^{3,6}

Evaluation

This condition may be overlooked by primary health care providers. For a correct diagnosis it is important to examine the patient with slit-lamp biomicroscopy when they have not epilated the eyelashes for 2 to 3 weeks.⁴ Ocular examination shows the misdirected cilia and can highlight superficial punctate keratopathy, corneal abrasion, vascularization, opacities and infection.⁷ All misdirected or misplaced eyelashes should be detected and mapped. Attention should be paid to margin position, horizontal laxity and conjunctiva (fornix scars or symblepharon formation).

Relevant Anatomy

Knowledge of eyelid margin and cilia anatomy is important to help evaluate and treat trichiasis better. The eyelid margin is the confluence of the mucosal surface of the conjunctiva, the edge of the orbicularis and the cutaneous epithelium. From anterior to posterior, the visible structures include the skin edge, the lashes, gray line, meibomian gland orifices, and the mucocutaneous junction.⁵

The gray line or sulcus intermarginalis of Graefe is an isolated section of pretarsal orbicularis muscle (Riolan) just anterior to the tarsus and is an important landmark for eyelid surgery.^{7, 8}

The eyelid margin may be divided into anterior and posterior lamella. The anterior lamella is comprised of skin, cilia, muscle and glands. The posterior lamella consists of the tarsal plate, meibomian glands, and conjunctiva.⁹

A distinguishing feature of the anterior lamella is the cilia. The cilia are arranged in irregular rows and are slightly more numerous in the upper (approximately 100-150) than in the lower lid (approximately 50-75).^{2, 5}

Each cilium lasts for approximately five months and then it is shed from its follicle. Unless the follicle is destroyed, a new cilium will begin to generate as soon as the old one is shed.^{10, 11} They originate from the anterior lamella, arise anterior to the grey line, and are directed away from the globe.⁵

The superior cilia curl outward and up, while the lower ones curl outward and down, to avoid interlacing when blinking. Their length varies between 8 and 12 mm in the upper lid and from 6 to 8 mm in the lower lid. The growth rate of cilia is approximately 120-130 $\mu\text{m/day}$.¹²

Various glands are located in the eyelids. The meibomian glands are sebaceous glands located in the upper and lower lid tarsal plates. The orifices for the meibomian glands are located on the lid margin posterior to the gray line. Meibomian glands contribute to the lipid layer of the tear film. Sebaceous glands of Zeis open into each follicle, while Moll glands are located behind and between the follicles.^{7, 9}

Besides its protective role, the complex structure of the eyelid is responsible for the production and distribution of the tear film, and for allowing drainage of the tear film through the nasolacrimal system.

The cilia also provide protection by catching airborne debris before it touches the ocular surface.⁹

The movements of the eyelid are mediated by the orbicularis oculi and levator palpebrae muscles.

Management Options

Trichiasis is always a challenging condition even with a systematic approach, because recurrences are not unusual. An accurate evaluation of the eyelid margin position

is very important. Differentiating true trichiasis from entropion and associated entropion-trichiasis is the basis for selecting the most appropriate treatment. Any entropion or other eyelid margin malposition must be corrected with appropriate surgery, and true trichiasis should be treated with lash ablation procedures or surgery in selected cases. If there is entropion and trichiasis, the elected treatment should address both conditions.^{1, 3}

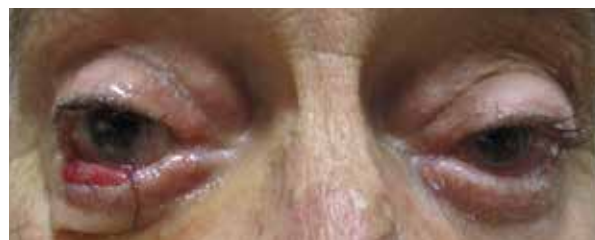

Fig. 1: Bilateral trichiasis and metaplastic lashes with inferior symblepharon. 1 week post-operative image after oral mucosa graft of the right eye.

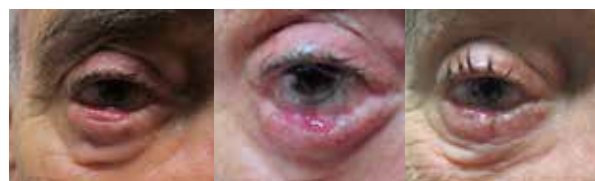

Fig. 2: Three weeks, 2.5 months and 5 months after oral mucosa graft.

Treatment is recommended if the patient is symptomatic and/or the corneal surface is disturbed. Strategies for treatment are based on the etiology and the number and distribution of the misdirected eyelashes.⁷

Short term measures improve the patient's comfort and include eye lubricants, contact lenses, and mechanical epilation (if the hair breaks it can be more aggressive and recurrence occur after 2 to 6 weeks, often with shorter and stiffer new lashes).

Definitive trichiasis treatments include laser ablation, radiofrequency ablation, bipolar electrolysis, cryotherapy and surgical procedures.

Laser Ablation

It can be used to treat minor trichiasis. In major trichiasis, surgical procedures have better results and the laser can be used as an adjunctive therapy.

Argon laser cilia ablation (514 nm) was first described by Berry in 1979 and depends on the absorption of argon laser by pigment. It is useful to mark the eyelash base with a blue skin marker pen or black mascara in hypopigmented lashes.^{13, 14} Success rates vary from 37 to 59 % with one session and 100 % with two or more procedures, but the treatment can cause lid notching, scarring and hypopigmentation.^{14, 15, 16, 17}

Technique

- Topical anesthesia or subcutaneous infiltration.
- The lid is everted so that the eyelash root is coaxial to the laser beam and laser burns are applied sequentially, directed to each bulb to a depth of 2-3 mm involving the follicle.⁶ A beam size of 50-100 μm , for a duration of 0.1-0.3 second and energy levels of 0.2 to 1.5 W according to the eyelash pigment are suggested.^{14,18}

Other types of laser such as diode (810 nm) and ruby (694 nm) lasers, have recently proven to be effective to treat trichiasis. They provide better penetration and more specific absorption than argon laser.^{6,7}

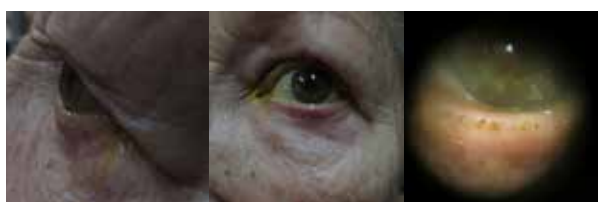

Fig. 3: Laser ablation of trichiasis: pre-treatment and immediate post treatment.

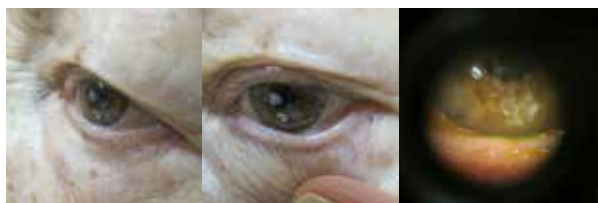

Fig. 4: 15 days after laser cilia ablation.

Radiofrequency Ablation

It can be used to treat minor trichiasis.

The radiofrequency waves selectively destroy the follicles and approximately 0.5 mm of adjacent tissue.¹⁹ The success rate is approximately 65 % after one treatment and 100 % after two or three additional procedures. The complications include eyelid edema, erythema and thickening of the lid margin.⁷

Technique

- Subcutaneous anesthesia.
- Under operating microscope magnification the electrolysis tip is inserted alongside the lash, 3 to 4 mm down to the bulb and the current is applied for 1 to 2 seconds and reapplied until bubbling or frothing is seen at the base of the eyelash.

Bipolar electrolysis

It can be used to treat minor and segmental trichiasis. It involves an electric current being passed through an ultrafine needle put in contact with at least 95 % of the eyelash follicle. It is difficult to ensure that the needle does, in fact, accurately reach and destroy only the hair bulb.¹ The success rate of approximately 40 %

could improve if additional procedures are adopted and if an ultrafine needle of 55 μm thickness is used. Complications include eyelid inflammation, eyelid notching, eyelid scarring, secondary deformities and hyper or hypopigmentation.

Technique

- Subcutaneous anesthesia.
- Under operating microscope magnification an ultrafine needle is inserted down hair follicle to hair bulb, to a depth into the skin of 1.4 mm in the lower lid and 2.4 mm in the upper lid. An electric current is applied for 1 or 2 seconds to burn the eyelash. The eyelid should be pulled away from the globe to protect the cornea. Antibiotic ointment is applied to the lid for a week.

Cryotherapy

It can be used to treat segmental and diffuse trichiasis. It is based on the principle that the hair follicles are more sensitive than the skin and conjunctiva to the destructive effects of freezing.³ The cryodestructive effect is enhanced by the rapidity of the freeze, the duration of the thaw and the number of freeze-thaw cycles.¹ The objective is to reduce the temperature at the follicles to about -20°C as quickly as possible, to allow the tissue to thaw as slowly as possible, and to repeat the freeze-thaw cycle. The double rapid freeze and slow thaw produces ice crystals that disrupt cell membranes and bring about cellular destruction.⁷ The success rate after a single treatment ranges from 56 %-90 % and increases after successive procedures. It is not effective in fine, non-pigmented cilia. Complications include loss of normal adjacent eyelashes, lid notching, meibomian gland dysfunction, necrosis, skin depigmentation, symblepharon and entropion.

Technique

- Topical and subcutaneous anesthesia (with epinephrine).
- Insert the thermocouple needle close to the anomalous lashes through the skin and orbicularis muscle and superficial to the tarsal plate. The appearance of the tissues when frozen is no guide to the actual temperature at the lash follicles.
- Protect the globe with a corneoscleral shell.
- Place a drop of gel or artificial tear on the lid.
- Apply the tip of the nitrous oxide-loaded probe to the lashes or to the tarsal conjunctiva 2 to 3 mm from the margin. The tissues are frozen until the appropriate temperature is achieved and the ice ball is allowed to thaw spontaneously. The cycle is repeated in a double freeze-thaw method.
- Antibiotic ointment is applied to the lid for a week.

11 . Trichiasis

Surgery Procedures

Surgical treatment is available for minor and major trichiasis, although it is often indicated for diffuse or segmental trichiasis and relapsing cases.

Excision of trichiatic eyelash bulbs

It can be used to treat minor trichiasis.

A microtrephine is used to extract the follicle using the lash as a guide inside the lumen of the trephine and then penetrating 2 mm into the lid margin of the abnormal lash.³

Lash root exposure and direct destruction

It can be used to treat minor trichiasis.

A small, vertical, linear and partial thickness incision is made through the eyelid tissues along the line of the hair follicle. The hair bulb is destroyed by direct electrolysis or cautery.¹

Anterior lamella excision

It can be used to treat minor and segmental trichiasis confined to the anterior lamella or more extensive involvement of the lid margin in patients with severe and recurrent trichiasis, where success is more important than an esthetic result.¹

The lid margin is split at the gray line behind the area of trichiasis to a depth of about 3mm. The anterior lamella including the lash roots is excised. The bare anterior surface of the tarsus is cauterized to stop bleeding and destroy any eyelash roots which may have been left behind. The tarsal plate can be left to granulate spontaneously.^{1,20} An everting suture can be placed through the skin into the tarsus at a higher level, which helps to prevent a localized area of skin touching the globe when the tarsal plate granulates and reepithelializes.¹

Full thickness pentagonal wedge resection

It can be used to treat segmental trichiasis that affects less than a third of the eyelid.

A pentagon is marked and should extend 2 to 3 mm beyond the abnormal lashes. An incision is made perpendicular to the lid margin and straight scissors are used to excise the pentagon. The lid margins are then aligned with a 6-0 silk suture passed through the gray line. A second suture can be placed to align the eyelashes. The tarsal plate is sutured with 5-0 vicryl sutures and the skin is closed with 6-0 interrupted silk sutures. When performed carefully this procedure has the advantages of good cosmesis and few complications.³

Anterior lamella repositioning

It can be used to treat extensive trichiasis.

The skin and orbicularis are first removed in

blepharoplasty fashion. Pretarsal skin and muscle are dissected toward the lid margin and fixated superiorly to the tarsus. The margin is incised along the gray line and left to granulate.

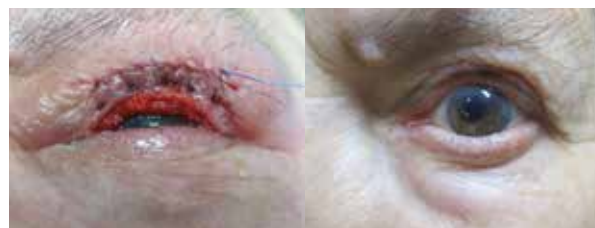

Fig. 5: Superior trichiasis and anterior lamella repositioning. Immediate post-operative image and 1.5 months later.

Mucocutaneous Graft

It can be used to treat extensive trichiasis.

This technique consists of splitting the eyelid margin into anterior and posterior lamellae and interposing a mucocutaneous graft, which forms a barrier between the anomalous eyelashes and the globe.³ The gray line incision is extended 2 mm beyond the trichiatic area and the lamellae are dissected 4 mm deep. The graft can be obtained from the contour of the lip or from the superior margin of the tarsus on the upper lid and it is placed on the receptor area with a continuous suture using 8-0 or 9-0 nylon. There is no need for sutures in the tarsoconjunctival area.

Antibiotic ointment is applied to the lid for 7-10 days until the sutures are removed.²¹

Tarsal Fracture operation

This technique is used for cases of trichiasis that involve the majority of the lid margin. It is most commonly used for the lower eyelid.

It is used to correct marginal entropion and involves a horizontal fracture of the tarsal plate and eyelid marginal rotation. A horizontal incision is made approximately 3-4 mm of the margin through tarsal conjunctiva and tarsal plate with a no. 15 blade or Colorado needle, which should extend 2 to 3 mm laterally beyond the area of the entropion. The margin is rotated outward with everting sutures. Double armed 6-0 vicryl sutures are placed in the inferior border of the tarsal plate and passed through the orbicularis and skin, exiting just under the lashes. Three or four sutures are placed along the incision. Slight overcorrection should be achieved at the end of the procedure.^{3,5}

Treatment of epiblepharon

It is indicated if epiblepharon does not resolve in the first two years of life and causes eyelashes to abrade the cornea, producing ocular surface symptoms and damage.

Surgical technique consists of excision of the extra

and redundant skin and muscle, in an ellipse shape, and suturing the lower lid skin edges to the retractors and lower border of the tarsal plate with interrupted long-acting 6-0 absorbable sutures. The amount to be excised should be carefully assessed, as there can be recurrence or ectropion can ensue if too much tissue is removed.^{1,5}

Treatment of distichiasis

Treatment of a few lashes can be successful with ablation procedures. Extensive areas can involve a lid splitting procedure combined with cryotherapy applied to the posterior lamella.

References:

1. Collin J.R.O., A Manual of Systematic Eyelid Surgery. 3^a ed. United Kingdom: Butterworth Heinemann; 2006; 3.
2. Kanski, J, Clinical ophthalmology: A systematic approach. 7^a ed. Oxford: Butterworth-Heinemann 2007.
3. Ferreira I, Bernardes T, et al. Trichiasis. Seminars in Ophthalmology 2010; 25 (3), 66-71.
4. Fea A, Turco D, et al. Ectropion, entropion, trichiasis. Minerva Chirurgia 2013; 68: 27-35.
5. Chen W.P., Oculoplastic Surgery: the essentials. New York: Stuttgart; 2001; 5.
6. Moore J, et al. Ruby laser for the treatment of trichiasis. Lasers Med Sci. 2009 Mar; 24(2):137-9
7. Bradley J, Rodney A, et al. Trichiasis: Characteristics and Management Options. Tile Journal of Ille American Society of Ophthalmic Registered Nurses 2011; Vol. XXXVI, 2.
8. Cantor L, Rapuano C, et al. Orbit, Eyelids and Lacrimal System; 2014-2015: 7.
9. Levin, L, Nilsson, S, et al, Adler's Physiology of the Eye: Expert Consult, Saunders 2011, 11th ed.
10. Bron J, Tripathi C. Tripathi J. Wolff's anatomy of the eye and orbit. 8th ed. London: Arnold 1997.
11. Oyster CW The Human Eye. Structure and Function. Sunderland, MA: Sinauer Assoc. Inc. 1999.
12. Thibaut S, De Becker E, Caisey L, et al. Human eyelash characterization. Dermatol 2009; 162(2): 304-310.
13. Berry J. Recurrent trichiasis treatment with laser and photo-coagulation. Ophthalmic epidemiologic 2007; 14: 273-277.
14. Sahni J, Clark D. Argon laser and trichiasis: a helpful tip. Br J Ophthalmol. 2001 Jun; 85(6):762.
15. Campbell C. Thermoablation treatment for trichiasis using the argon laser. Aust NZ J Ophthalmol 1990; 18:427-30.
16. Yung W, Massicote J, et al. Argon laser treatment of trichiasis: a clinical and histopathologic evaluation. Ophthalmol Plast Reconstr Surg 1994; 10: 130-136.
17. Phan R, Biesman B, et al. Treatment of trichiasis using 810 nm diode laser: an efficacy study. Ophthalmol Plast Reconstr Surg 2006; 22 (6): 445-447.
18. Al-Bdour M, Al-TillM. Argon Laser: A Modality of Treatment for Trichiasis. International journal of Biomedical science 2007.
19. Kormann R, Moreira H. Eletrólise com radiofrequência no tratamento da triquíase. Arq Bras Oftalmol 2007; 70(2): 276-280.
20. Moosavi A et al. Simple surgery for severe trichiasis. Ophthalmol Plast Reconstr Surg 2007; 23(4): 296-297.
21. Figueiredo A, Soares E, Dantas R. Triquíase. Cirurgia e Plástica Ocular. Rocca 1997; 185-192.

12 . Facial Palsy and Lagophthalmos

Nadia Lopes, Guilherme Castela

INTRODUCTION

The incidence of peripheral facial nerve palsy (FNP) is 30–40 persons per 1000 000 per year. Peripheral FNP can have an idiopathic etiology (Bell's palsy) or be secondary to trauma, cerebrovascular accidents, tumor, infectious and immune –mediated causes (table 1). In 75% of cases, the etiology is idiopathic and about 80–85 % of the patients with Bell's palsy recover spontaneously and completely within 3 months.

Peripheral facial nerve paralysis has functional and cosmetic sequelae for patients. Ophthalmic manifestations are caused by paralysis of the upper and lower eyelid. Paralysis of the upper eyelid (figure 1) results in loss of the blink reflex, disruption of the lacrimal apparatus, lagophthalmos and upper lid retraction. The main consequences of paralysis of the lower eyelid (figure 2) are ectropion, epiphora and lagophthalmos. All these factors contribute to corneal exposure (figure 3).

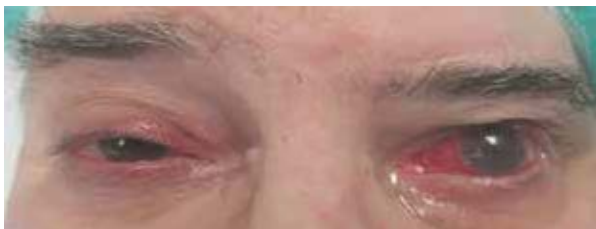

Fig. 1: A patient with upper eyelid retraction.

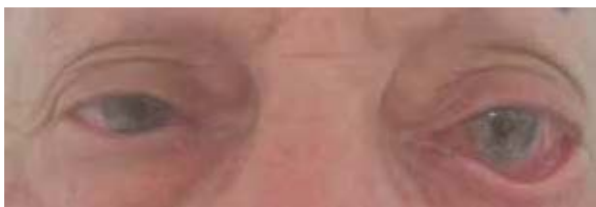

Fig. 2: A patient with a paralytic ectropion.

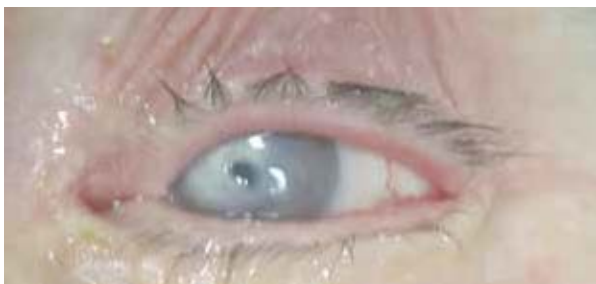

Fig. 3: Corneal exposure in patient with facial palsy.

Another less severe ophthalmic problem is eyebrow ptosis, which can cause limitation of the superior visual field. (figure 4)

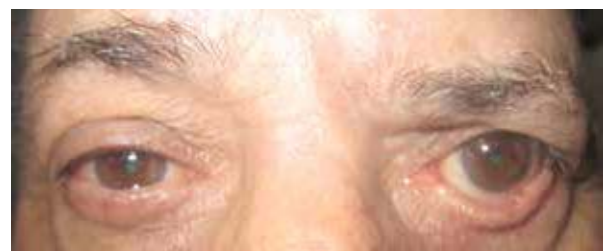

Fig. 4: Eyebrow ptosis.

A rarer complication is aberrant regeneration. This sequel occurs more often after complete facial paralysis. In these patients the incidence can reach 34%. Aberrant regeneration results in synkinesis, which are involuntary movements accompanying voluntary movements. The main patterns of synkinesis are: ocular to oral synkinesis, eyelid to masseter synkinesis, brow to oral synkinesis and gusto-lacrimal reflex.

Medical treatment is essential in the early stages of paresis and surgery is reserved for patients who do not respond to supportive treatment or those in whom the paralysis is permanent.

MEDICAL TREATMENT

Lubrication of the cornea is fundamental in both the acute and chronic phase. The lubricant must be applied at least hourly, particularly in the acute phase and a more viscous ointment should be used overnight. The lubricant is preservative-free to prevent corneal toxicity.

Eye occlusion can be achieved by taping the upper and lower eyelid with strips of paper or applying a pressure patch or eyelid suture. However, patching the eye can result in abrasive trauma of the cornea.

Protective devices such as contact lenses and moisture chambers are used to prevent tear evaporation. Contact lenses are particularly useful for patients with a neurotrophic cornea.

12 . Facial Palsy and Lagophthalmos

Trauma	Birth injury, Temporal bone fracture
Cerebrovascular	Ipsilateral pontine infarction and hemorrhage
Tumor	Malignant parotid neoplasms, facial nerve neurinoma, leukemia, lymphoma, tumors of the petrosal bone and middle ear
Infectious	Ramsay Hunt syndrome, Lyme disease, Hansen's disease, herpes simplex infection, varicella zoster infection, influenza viruses, parotitis, syphilis, otitis media
Immune	Guillain-Barré syndrome, Miller Fisher syndrome, myasthenia gravis
Drug	Interferon, linezolid
Others	Sarcoidosis, parkinson, diabetes mellitus, pregnancy, multiple sclerosis, Möbius syndrome, Melkersson-Rosenthal syndrome, autism

Table 1: Facial palsy etiology

Botulinum toxin

The chemical denervation of the levator muscle with botulinum toxin is an alternative treatment for upper eyelid retraction. The main complication is paresis of the superior rectus resulting in hypotropia and reduction of Bell's reflex. The toxin (7.5-15 U) is injected into the supratarsal fold and the anterior placement of the toxin prevents superior rectus muscle underaction. Yucel et al have reported the effect of botulinum toxin on patients with facial palsy. The peak action of botulinum toxin was 6+/- 3 days and ptosis duration was 11+/- 3 weeks. Botulinum toxin is also used in the management of synkinetic movements (figure 5).

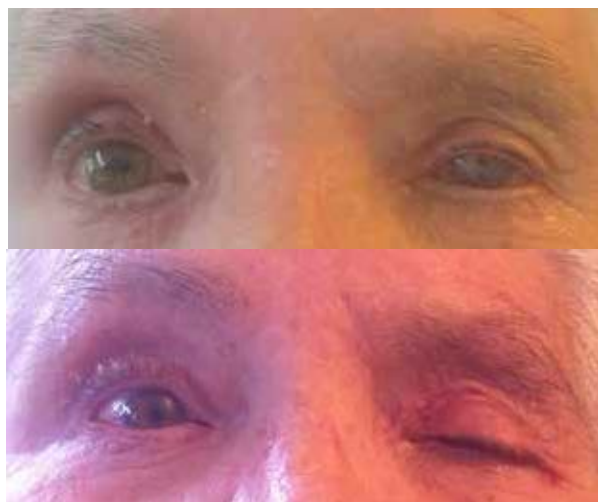

Fig. 5: Botulinum toxin injection in patient with corneal exposure.

Hyaluronic acid

More recently, the use of hyaluronic acid has been advocated for corneal protection by several authors. A small amount of hyaluronic acid is injected deep into orbicularis muscle using a 30 gauge needle, along the length of the upper eyelid and avoiding the area adjacent to the upper canaliculus.

Steroid and oral acyclovir

In case of Bell's palsy, the use of oral steroid during the first 3 days increases the probability of facial nerve recovery. The benefit of oral acyclovir has not been established and if there is benefit, it is modest.

SURGICAL TREATMENT

Upper Eyelid Retraction

The procedures for upper eyelid retraction treatment are classified into static and dynamic (table 2).

Static	Dynamic
- Eyelid loading	- Temporal Muscle Transfer
- Tarsorrhaphy	- Palpebral Spring
- Mullerectomy	- Arion Sling

Table 2: Superior eyelid procedures

Lid loading

Lagophthalmos can be corrected by the placement of a rigid weight under the skin of the upper eyelid. This method was first described in 1950, modified in 1966 and popularized in 1974.

The high density and excellent side-effect profile of gold and platinum led them to become the established implant material. Platinum has a better biocompatibility profile and a higher density than gold, so a smaller implant can be used. Gold weights are only available in the rigid form, while platinum implants exist as a chain. Platinum chain implants are flexible, which allows an optimal pretarsal fit, thus providing better cosmetic results, but they are more expensive.

To choose the correct weight, a range of test weights are attached to the superior eyelid and the patient is asked to open and close the eye, in the supine position. The ideal weight should produce a complete voluntary closure and opening of the lids without ptosis when the eye is open (figure 6).

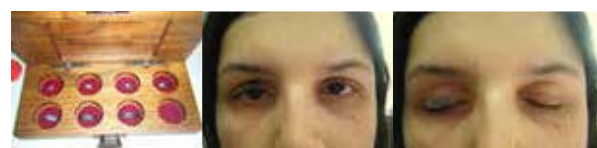

Fig. 6: Pre operative evaluation.

Surgical technique: (figure 7)

- skin incision is made in the palpebral crease;

- the orbicularis muscle is dissected to expose the tarsal plate;
- the weight is placed at the point of maximal lagophthalmos, which is the mid-pupillary line or between the mid-pupillary line and the medial limbus;
- the weight is fixed to the tarsal plate by suturing with polypropylene 5-0;
- the orbicularis muscle and the skin are sutured in two different planes (with polyglactin 6-0 and polypropylene 6-0, respectively).

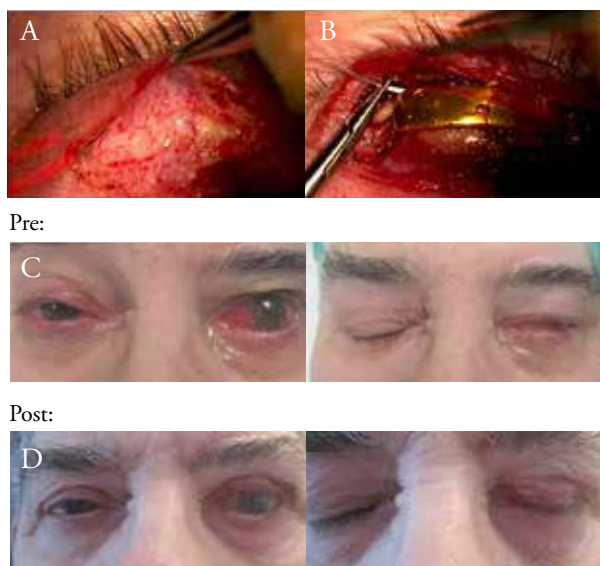


Fig. 7: a): The orbicularis is dissected until the tarsal plate. b): The weight is fixed to the tarsal plate. c): Pre: a patient with retraction of the upper eyelid. d): Post: 6 months after the gold weight implantation.

Different techniques for weight implantation

High weight implantation

The weight may be implanted in the levator aponeurosis or the orbital septum.

Retroseptal insertion was described by Rosen et al. With this technique, the weight placement is deeper, which reduces the visibility, the exposure and entropion, but a heavier weight is needed.

Implantation in the orbital septum is not effective because this anatomical structure is inserted in the orbital rim and so the weight is transferred to the orbital rim.

Posterior implantation

In this technique, a small vertical tarsal incision is made and a pocket created between the tarsal plate and the orbicularis. The weight is inserted in the pocket without a tarsal suture. The advantage of this technique is the maintenance of the anterior lamella, which reduces the rate of extrusion.

Implant covering

More recently implant wrapping procedures with temporalis and fascia lata have been used to reduce the rate of migration and extrusion (figure 8).

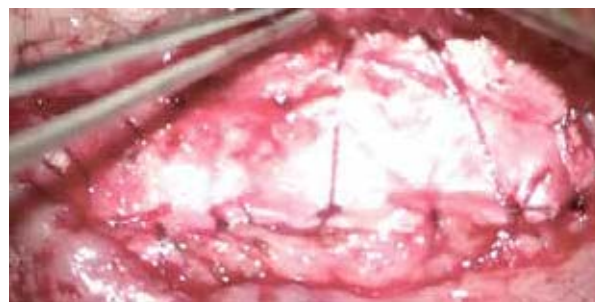

Fig. 8: Implant covering, using temporal fascia.

Complications:

The main disadvantage of lid loading is the dependence on gravity. Furthermore, It does not remove the need for nocturnal corneal protection with eye patches or ointments.

The main complications of the weight implantation are:

- extrusion, (figure 9)
- migration,
- ptosis,
- residual lagophthalmos,
- astigmatism
- visible implant.(figure 10)

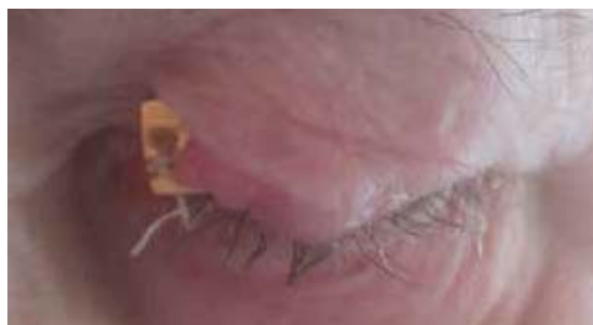

Fig. 9: Weight extrusion.

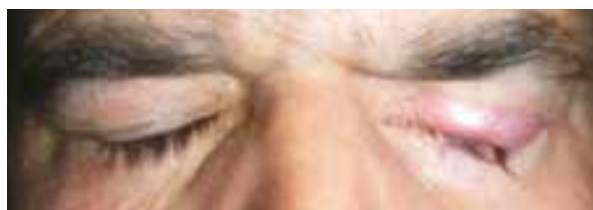

Fig. 10: A visible implant.

Tarsorrhaphy

The tarsorrhaphy is an easy and inexpensive technique which provides protection of the cornea on a permanent or temporary basis.

Tarsorrhaphy is indicated:

- when surgical procedures have failed,
- in cases of neurotrophic ulcer,
- in patients with a trigeminal nerve deficit,

12 . Facial Palsy and Lagophthalmos

- in patients with acute facial palsy unable to comply with the supportive measures.

Surgical Technique:

Temporary lateral tarsorrhaphy:

- 2 parallel incisions 1 mm deep are made in the gray line of the upper and lower eyelid;
- the lid margin posterior to incision, is excised;
- the tarsorrhaphy is closed with a 4/0 non-absorbable double-armed suture which passes through the cut edges and through tarsorrhaphy tubing;
- the sutures are removed after 2-3 weeks.

Permanent lateral tarsorrhaphy: (figure 11)

- separation of the anterior and posterior lamella in the upper and lower eyelid;
- vertical cut at the medial end of the tarsal plate, in the upper and lower eyelid;
- excision of a triangle of lower tarsal plate;
- double-armed 4/0 non absorbable suture placed between the tarsal plate of the lower and upper eyelid.

Complications:

- cosmetic disfigurement, (figure 12)
- limitation of visual field,
- trichiasis.

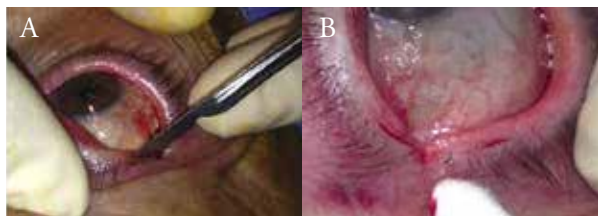
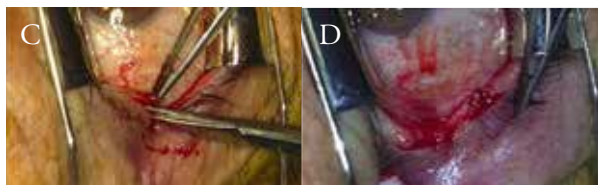
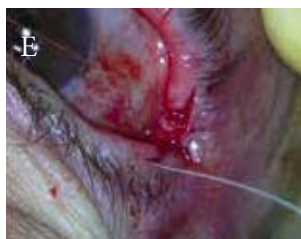

Fig 11. a-b): Incisions. Separation of the anterior and posterior lamella.



c-d): Excision of a triangle of inferior tarsal plate and a superior tarsal triangle is performed.



e): The tarsorrhaphy is closed with a 4/0 non-absorbable double armed suture.

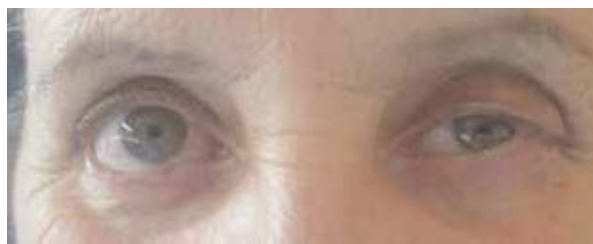

Fig. 12: A patient with a lateral tarsorrhaphy.

Mullerectomy and levator transection

The mullerectomy was introduced in 1965 as a treatment for upper eyelid retraction due to Graves eye disease. The mullerectomy improves the balance between protractor and retractor tone, resulting in a lower eyelid position and a better closure. It provides 1 to 2 mm of additional eyelid closure. The main advantages of this technique are: no foreign material implantation (thus reducing infection, extrusion and chronic inflammation), and a physiological closure. However, the eyelid closure is limited.

Surgical Technique: (figure 13)

- Dissection of the conjunctiva/Müller from the levator aponeurosis superiorly, for 15 mm;
- The Müller muscle is transected near its origin and removed from the conjunctiva.

The levator transection is used when other therapeutic measures have failed. With this technique, the ptosis induced is equivalent to that obtained with botulinum toxin.

Dynamic Procedures

The palpebral spring is a steel device which is implanted and secured to the superior orbital rim and the pretarsal area. The palpebral spring is prone to exposure and extrusion.

With the temporal muscle transfer, two temporal muscle flaps are placed around the upper and inferior eyelids and fixed to the medial canthus. When the patient clenches the jaw, tension is placed on the eyelid causing it closure.

The Arion Sling was first described in 1972. With this technique, a silicone sling is introduced around the upper and inferior eyelids. The main complications are the migration and the weakening of the silicone rod. The authors use a temporalis fascia sling with good functional and aesthetic results.

Lower eyelid paralysis

In lower eyelid paralysis there is a loss of the active eyelid support provided by the orbicularis muscle, causing eyelid ectropion with horizontal laxity. Over time, the anterior lamella can contract and result in cicatricial ectropion.

The treatment of paralytic ectropion can be complex and sometimes it is necessary to combine procedures (Table 3).

Loss of support		
Medial	Lateral	Total
Medial canthoplasty	Lateral tarsal strip	Lateral tarsal strip
Sling	Tarsorrhaphy	Sling
Tarsorrhaphy		

Hemifacial ptosis	Cicatricial ectropion
Midface lift	Cutaneous and mucosal grafts

Table 3: Surgical treatment of the inferior eyelid paralysis

Medial canthoplasty

This technique reduces the vertical palpebral aperture. First, an incision is made in the myocutaneous junction between the lacrimal punctum and the canthal angle; the inferior and superior orbicularis and the skin are sutured in two different planes.

Complications:

- canalicular lesions,
- alterations of the medial angle,
- horizontal shortening of the eyelid,
- a poor aesthetic result. (figure 14)

Lower eyelid sling

In this technique a sling is passed through the inferior eyelid and fixed to the medial canthal tendon and lateral orbital rim, thereby providing support to the inferior eyelid. Several materials – fascia lata, silicone, temporalis fascia - have been used, but we prefer the temporalis fascia because it is a strong, biocompatible material. The scar is hidden by the hair and its proximity to the orbital regional allows a single surgical field.

Surgical technique: (figure 15)

- A 10 mm skin incision is made to the medial canthal tendon;
- the medial canthal tendon is exposed by blunt dissection;

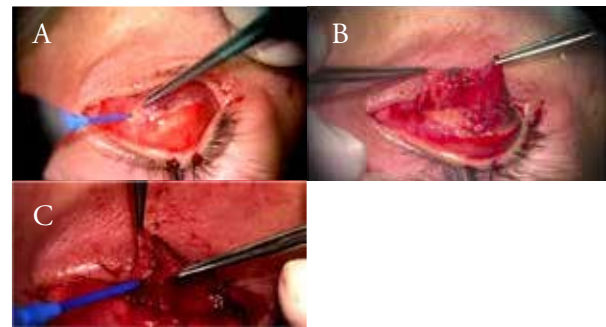
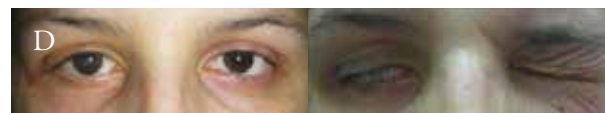
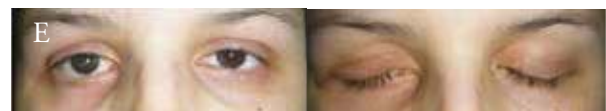
Fig. 13 a): A incision is done in the superior border of the tarsus. b): Dissection of the conjunctiva/muller from the levator aponeurosis superiorly. for 15mm. c): The muller muscle is transected near its origin and removed from the conjunctiva.



d): Pre: a patient with upper eyelid retraction.



e) Post: 4 months after a mullerectomy procedure.

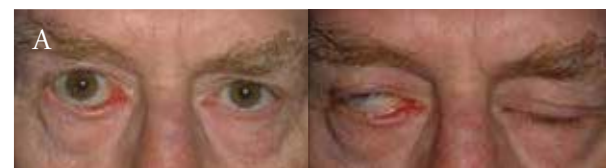
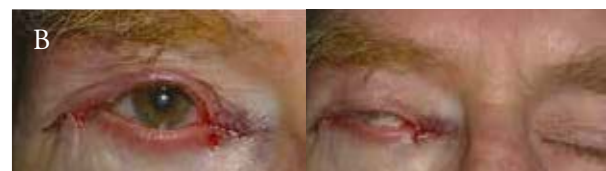
Fig. 14 a): Pre: a patient with medial ectropion.



b) Post: 6 months after a medial canthoplasty procedure.

- the fascia is secured to the medial canthal tendon by a 5-0 nylon suture;
- the tissues over the lateral orbital rim are dissected and an osteal tunnel is created;
- the fascia is threaded through the lower lid, via a mid palpebral subciliary incision, using a Wright needle, and beneath the osteal tunnel, pulling the lid laterally and upwards.

Complications:

- long surgical time,
- canalicular lesions.

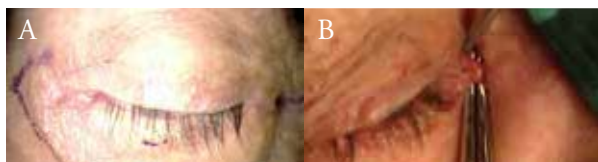
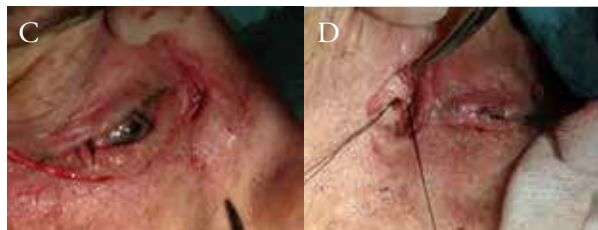
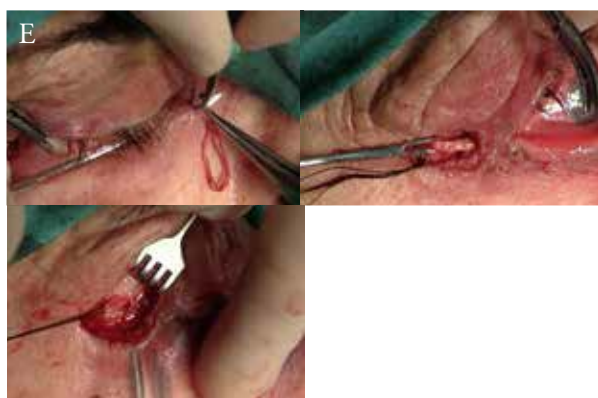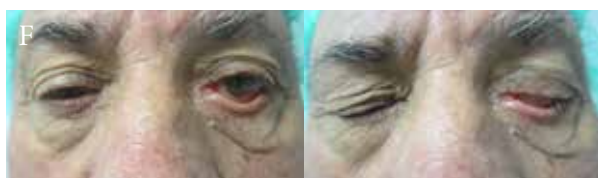Fig. 15 a) A skin incision is done, 10mm to the medial canthal tendon. b) The medial canthal tendon is exposed.



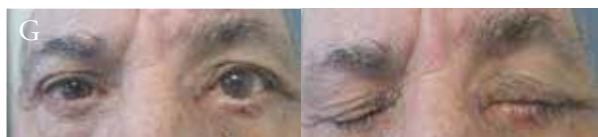c) The fascia is sutured to the medial canthal tendon. d) An osteal tunnel is created.



e) The fascia is threaded through the lower lid using a Wright needle (15e1 and 15e2). The fascia passes through the osteal tunnel (15e3).



f) Pre: A patient with paralytic ectropion.



g) Post: 12 months after the lower eyelid sling.

Lateral tarsal strip

The lateral tarsal strip (LTS) was described 30 years ago by Anderson and Gordy. This technique is the gold standard for ectropion correction. The procedure reduces the vertical palpebral aperture but maintains normal horizontal length.

Surgical technique:

See the ectropion chapter.

Complications:

- it is difficult to restore the canthal angle;
- the procedure is often insufficient.

Midface lift

In patients with hemifacial ptosis, the eyelid can only be elevated (figure 16) if the cheek is elevated simultaneously. The superficial musculoaponeurotic system of the face is continued to the orbit, therefore the elevation of the midface prevents the descent of the lower eyelid. The dissection can be subperiosteal or preperiosteal. The preperiosteal approach seems preferable because the elevation of the periosteum does not prevent the lowering of facial soft tissues.

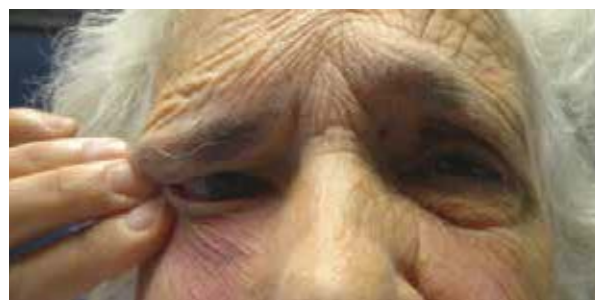

Fig. 16: Hemifacial ptosis.

Surgical technique: (figure 17)

- Canthotomy and cantholysis are performed.
- A posterior transconjunctival incision is made 3-4 mm below the tarsus. The incision runs 1 mm lateral to the caruncle to the lateral canthus.
- The dissection is performed up to the inferior rim, in the preperiosteal plane.
- A blunt dissection is completed inferiorly, avoiding the infraorbital neurovascular bundle, to the level of the nasolabial fold medially and the gingival sulcus inferiorly.
- The soft tissues are sutured to the periosteum of the inferior orbital rim using one/two 4-0 suture(s).
- A lateral canthoplasty is performed using the lateral tarsal strip technique.

Complications:

- distortion or puckering beyond the lateral corner of the eye,
- chemosis in 20% of cases,
- infraorbital nerve lesion,
- middle lamellar scarring with cicatricial ectropion.

Skin and mucosal grafts

Cicatricial ectropion can cause contraction in all the layers of the lower eyelid.

Treatment of anterior retraction includes the resection of the scar tissues and the placement of myocutaneous flap or skin graft.

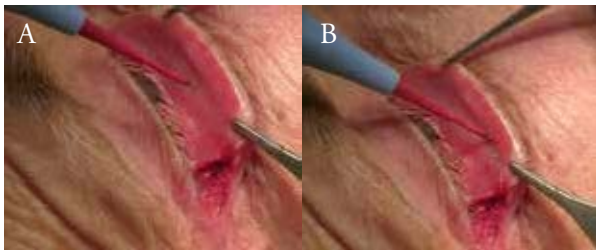
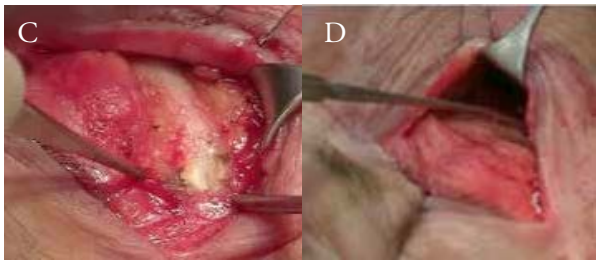
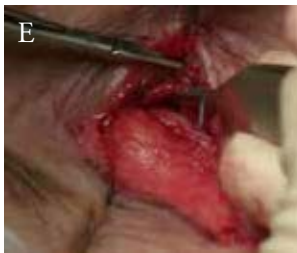

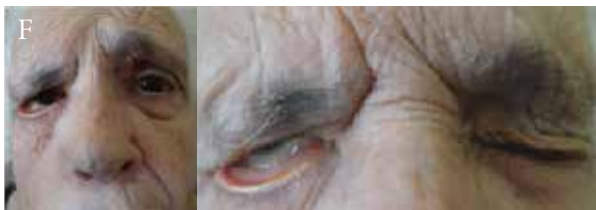Fig. 17 a) A cathotomy and cantholysis are performed. b) A infra-tarsal incision is performed.



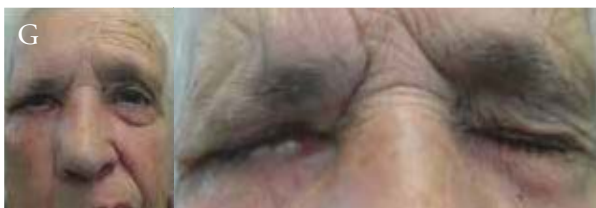c) The dissection is performed until the inferior rim, in the preperiosteal plane. d) A blunt dissection is completed inferiorly.



e) The soft tissues are sutured to the periosteum of the inferior rim.



f) Pre: a patient with paralytic ectropion.



g) Post: 4 months after the midface lift.

In the case of middle and posterior lamellae, a graft is often necessary. The graft materials used include hard palate, ear cartilage, and dermis fat graft. Alloderm, which is a matrix derived from human cadaveric dermis, has been used with success.

Brow ptosis

Brow ptosis correction improved patient cosmesis and visual fields and it should be performed when the lagophthalmos is resolved, when the cornea is suitably protected.

Direct brow lift with fixation to the periosteum is the most common technique used, and we believe that, over time, this technique is the most effective and lasts longest.

Surgical technique: (figure 18)

- The amount of brow ptosis is assessed preoperatively with the patient seated.
- The skin to be excised is marked, with the superior border of the eyebrow being the lower limit of the incision. The brow is pulled up to the intended position, and the pen held in this position. Let the brow descend and drop the pen onto the skin to mark the upper limit of the incision. The incision can be elliptical or take the form of a zigzag.
- Excision of the tissues: skin incision along the mark; the incision is made with a no. 15 blade and is deep, at the level of the frontal muscle. The frontal muscle lateral to the supraorbital notch rim is excised.
- Closure: the tissues are closed in two layers. The subcutaneous tissues are closed with 4/0 monofilament absorbable sutures. The sutures should pass through the periosteum. The epidermis is closed with a monofilament 4/0 non-absorbable suture.

Complications:

- scar,
- forehead paresthesia,
- the brow may descend again.

The scar is the main disadvantage of this technique. In a survey conducted by Booth et al, the authors found a high level of satisfaction with the cosmesis of the scar. The carefully layered wound closure and zigzag incision result in a smooth scar (figure 19).

Transblepharoplasty browpexy involves elevating the brow through a blepharoplasty incision. The dissection is done in the preseptal fat plane and the brow is fixed to periosteum 1-2 cm above the superior orbital rim. Brow elevation is limited with this approach, however.

With endoscopic forehead lift the incisions are smaller with less sensory disturbance, less alopecia

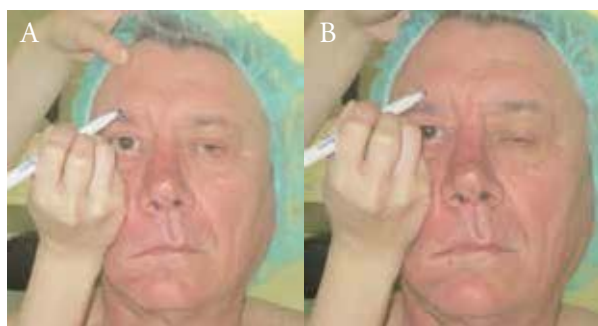
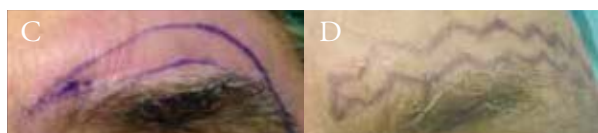
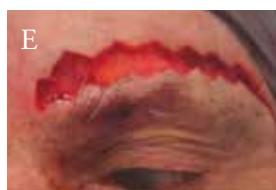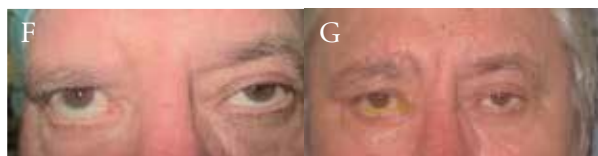Fig. 18: Demarcation of the skin to be excised. a) The brow is pulling up to the intend position and hold the pen in this position. b) Allow the brow to descend and drop the pen onto the skin to mark the upper limit of the incision.



c) An elliptical incision. d) A zigzag incision.



e) Excision of the tissue at the level of the frontal muscle.



f)Pre : a patient with browptosis.

g) Post: 8 months after the browlift (using a zigzag incision).

and faster recovery. Longer operating times, specialized training, expensive equipment and a high failure rate are disadvantages of this approach.

Conclusion

The management of facial palsy remains challenging and several factors need careful consideration such as patient age, the degree of lagophthalmos and Bell's reflex. The main goal of the treatment is to maximize corneal protection and facial cosmesis. Several therapeutic options are available and each patient must be treated individually.

Bibliography

1. Rahman I, Sadiq A. Ophthalmic Management of facial nerve palsy: A review. Survey of ophthalmology, vol 52, n°2: March April 2007
2. Adour K, Swanson P. Facial paralysis in 403 consecutives patients: emphasis on treatment response in patients with Bell's palsy. Trans Am Acad Ophthalmol Otolaryngol 75: 1284-301,1971
3. Bergeron C, Moe K. The evaluation and treatment of lower eyelid paralysis. Facial plastic surgery. Vol 24, n°2, 2008,

- 231-240
4. Bergeron C, Moe K. The evaluation and treatment of upper eyelid paralysis. Facial plastic surgery. Vol 24, n°2, 2008, 220-230
5. Mark May, Barry Shaitkin. Facial Paralysis, Rehabilitation Technique. Thieme Editor 2003, p.133-137
6. K Boboridis, N Ziakas, C Bunce, N Georgiadis, N Stangos. Management of lagophthalmos in Facial Nerve Palsy. Investigative Ophthalmology and visual science 2002;43
7. MN Naik, N Gangopadhyay, M Fernandes, R Murthy, SG Honavar. Anterior chemodeneration of levator palpebrae superioris with botulinum toxin type-A to induce temporary ptosis for corneal protection. Eye (London. 2008 Sep;22(9):1132-6
8. Vasquez LM, Medel R. Lagophthalmos after facial palsy: Current Therapeutic Options. Ophthalmic Res;52:165-169
9. Yucel OE, Artuk N. Botulinum toxin-A- induced protective ptosis in the treatment of lagophthalmos associated with facial paralysis. Ophthal Plast Reconstr Surg. 2012 Jul-Aug;28(4):256-60
10. R. Mancini, M Taban, A. Lowinger, B. Nakra, A. Tsirbas, R. Douglas, N. Schorr, R. Goldberg. Use of Hyaluronic Acid Gel in the Management of Paralytic Lagophthalmos: The Hyaluronic Acid Gold Weight. Ophthal Plast Reconstr Surg 2009; 25:23-26
11. Baugh RF, Basura GJ, Ishii LE, Schwartz SR, Drumheller CM, Burkholder R, et al: Clinical practice guideline: Bell's palsy executive summary. Otolaryngol Head Neck Surg 2013;149: 656–663.
12. Gronseth GS, Paduga R: Evidence-based guideline update: steroids and antivirals for Bell palsy: report of the Guideline Development Subcommittee of the American Academy of Neurology. Neurology 2012;79:2209–2213
13. Jobe RP. A technique for lid-loading in the management of lagophthalmos in facial palsy. Plast Reconstr Surg. 53:29-31, 1974
14. Bladen JC1, Norris JH, Malhotra R. Cosmetic comparison of gold weight and platinum chain insertion in primary upper eyelid loading for lagophthalmos. Ophthal Plast Reconstr Surg. 2012 May-Jun;28(3):171-5.
15. Rozen, S, Lehrmen. Upper Eyelid Postseptal Weight Placement for Treatment of Paralytic Lagophthalmos. Plastic & Reconstructive Surgery: June 2013 - Volume 131 - Issue 6 - p 1253–1265
16. Filipe José Pereira; Felipe Eing; Francisco Azevedo Marquard; Rodrigo Cavalheiro; Antonio Augusto Velasco e Cruz. Posterior approach to gold weight implant. Arq. Bras. Ophthalmol. vol.71 no.5 São Paulo Sept./Oct. 2008
17. Bulam H1, Öztürk O, Ünlü E, Uslu A, Yilanci S, Bali Y, Igde M. Treatment of migration and extrusion of the gold weight eyelid implant with fascia lata sandwich graft technique. J Craniofac Surg. 2015 Jan;26(1):e10-2.
18. Ralph E. Wesley MD, Kimberly A. Klippenstein MD, Michael E. Glascock MD, C. Gary Jackson MD, John P. Fezza MD. Lateral tarsorrhaphy in management of facial palsy. Annals of Ophthalmology. Summer 2000, Volume 32, Issue 2, pp 95-97
19. Hassan As, Frueh Br, Elner VM. Mullerectomy for upper eyelid retraction and lagophthalmos due to facial nerve palsy. Arch Ophthalmol. 2005 Sep; 123(9):1221-5
20. Sendul S, Huseyin H, BioMed Research InternationalVolume 2015 (2015), Article ID 759793, 7 pages <http://dx.doi.org/10.1155/2015/759793>
21. S. Yekta Sendul,H Huseyin Cagatay, B Dirim, M Demir, Z Acar, A Olgun, E Can, D Guven. Effectiveness of the Lower Eyelid Suspension Using Fascia Lata Graft for the Treatment of Lagophthalmos due to Facial Paralysis.. BioMed Research

International Volume 2015 (2015), Article ID 759793,

22. Chang L, Oliver J. A useful augmented lateral tarsal strip tarsorrhaphy for paralytic ectropion. *Ophthalmology*. 2006 Jan; 113(1):84-91
23. Marshak H, Morrow D, Dresner S. Small Incision preperiosteal midface lift for correction of lower eyelid retraction. *Ophthal Plast Reconstr Surg* 2010; 26: 176-181
24. Schwarcz R, Kotlus B. Complications of lower blepharoplasty and midface lifting. *Clin Plastic Surg* 42 (2015) 63-71
25. Korn BS, Kikkawa DO, Cohen SRL. Treatment of lower eyelid malposition with dermis fat grafting. *Ophthalmology* 2008;115: 744 –51.
26. Tyers G. Brow lift via the direct and trans-blefaroplasty Approaches. *Orbit* 2006, 25:261-265
27. Booth AJ, Tyers AG. The direct browlift: efficacy, complications and patients satisfactions. *Br J Ophthalmol*. 2004 May; 88(5):688-691
28. Meltzer N, Byrne P. Management of the brow in facial paralysis. *Facial Plastic Surgery*, vol 24, n°2, 2008: 216-19

13. Eyelid Tumors

José Costa, Filipa Ponces

The close relationship between the eyelids, ocular and vital structures such as the central nervous system means that the ophthalmologist must remain alert for the early detection of neoplasms so that inward spread, vision loss and invasion of the orbital region can be prevented.

The most common eyelid malignancies are slowly growing painless lesions that don't raise suspicions for either the patient or the physician. Therefore, the successful management of eyelid tumors requires a thorough knowledge of their broad clinical spectrum. As a rule of thumb, a biopsy should be performed whenever a patient has an atypical presentation of a typical diagnosis.

EPIDERMAL TUMORS

Squamous Papilloma

Squamous papilloma is the most common benign lesion of the eyelid,¹ presenting as a flesh-colored pedunculated or sessile papule. It is commonly found in areas of increased friction, such as the neck and axillae. In the facial region, it typically appears in the eyelid margin and multiple lesions can be present.

Histologically, a squamous papilloma consists of projections of a fibrovascular core covered by acanthotic and hyperkeratotic squamous epithelium. Simple excision can be performed in lesions that are affecting the vision or causing ocular irritation, or for cosmetic purposes. (Fig. 1,2,3)

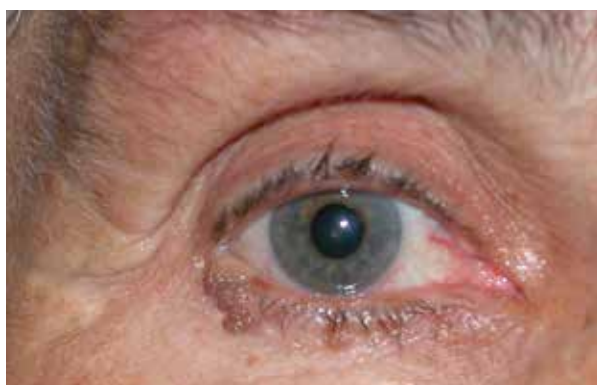


Fig. 1 - Sessile papilloma of inferior eyelid.

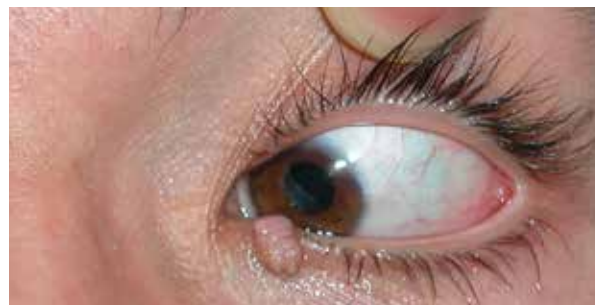

Fig. 2 - Pedunculated papilloma of the inferior eyelid.

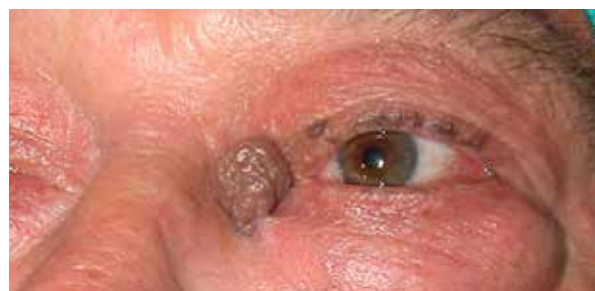


Fig. 3 - Inner canthus, pedunculated papilloma.

Seborrheic Keratosis

Seborrheic keratosis (SK) is a common epidermal tumor, usually affecting the elderly. Genetics, sun exposure and Human Papilloma Virus (HPV) infection have been implicated in its origin.² SK commonly presents as a painless plaque with well-defined borders that becomes papular as it grows and gradually takes on a verrucous, stuck-on appearance. It is usually tan but various pigmentation degrees can be found, ranging from white to brown. Occasionally, these lesions can become irritated. (Fig. 4)

Although it is not a premalignant lesion, the sudden appearance of multiple, eruptive SKs, the Leser-Trélat sign, can occur in the presence of a malignant visceral tumor. Multiple lesions in the periorbital and malar region, usually in dark-skinned patients, are also found in dermatosis papulosa nigra.

Various histologic variants exist, but hyperkeratosis, acanthosis, and papillomatosis are hallmark findings. Treatment is simple excision.

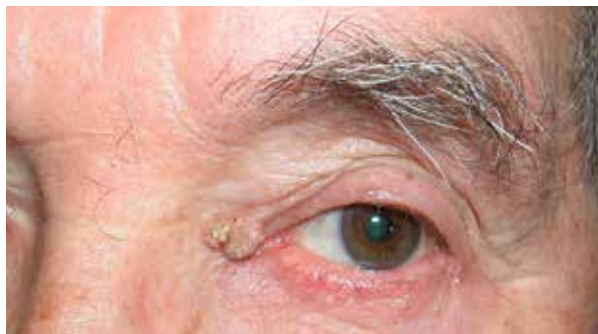

Fig. 4 – Seborrheic keratosis in the inner canthus.

Keratoacanthoma

Keratoacanthoma (KA) is an epithelial tumor typically appearing in sun-exposed sites of older, light-skinned individuals. It begins as a papule surrounded by areas of actinic damage that grows rapidly over a few weeks. A central keratotic core then develops, surrounded by raised edges that give it an umbilicated appearance. The KA slowly regresses over a period of a few months, eventually forming a hypopigmented scar. (Fig. 5)

The histologic appearance depends on the tumor stage. A fully developed KA shows a keratin core surrounded by acanthotic squamous epithelium. Lesions can exhibit squamous cell carcinoma (SCC) differentiation, and the differential diagnosis between the two lesions can be difficult, especially if punch biopsy, and not complete excision, is performed.³ Some authors consider KA a low-grade SCC, with a tendency to involute.⁴ There are reports of metastatic and invasive KAs, but whether these were true KAs or unrecognized SCCs is an ongoing debate.⁵

A wait-and-see approach might be acceptable in a typical, solitary tumor. Still, most authors recommend therapeutic intervention in all cases, not only because the differentiation between KA and SCC is unreliable, but also for cosmetic reasons, to prevent local destruction of ocular structures and to avoid secondary ectropion or ptosis due to scarring.⁶ Complete surgical excision is the first line of treatment. Other options include radiotherapy, cryosurgery and intralesional chemotherapeutic agents.

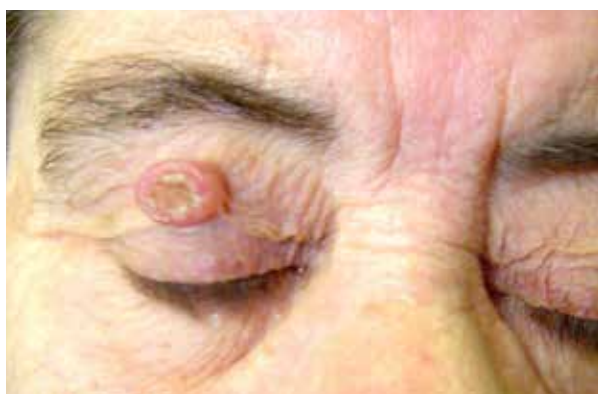

Fig 5 – Keratoacanthoma of the superior eyelid.

Epidermoid Cysts

An epidermoid cyst (EC), also known as epidermal inclusion cyst (or sebaceous cyst, a misnomer), is the most common cutaneous cyst. It is secondary to the proliferation of epidermal cells within a circumscribed dermal space. An EC can be congenital or acquired. Congenital ECs are thought to arise from entrapped epidermal remnants along a fusion line of embryonic plates, and are commonly located in the lateral portion of the upper lid or in the eyebrow. Acquired ECs are sometimes caused by the dermal implantation of epidermis following trauma, and more often by the occlusion of pilosebaceous units following follicular inflammation.

Classically, ECs present as a slow growing, mobile, skin-colored to white nodule, usually less than 1-2 cm in diameter. A central punctum might be seen, representing the plugged pilosebaceous unit, and expression of the cyst can release a foul-smelling cheesy material. Milia are multiple small, pearly-white ECs, caused by the occlusion of pilosebaceous follicles, with secondary retention of keratin. ECs are often asymptomatic, but rupture of the cystic wall produces a granulomatous inflammatory reaction, with tenderness. Bacterial infection of the cyst may also occur. (Fig. 6,7)

Treatment is complete excision. Simple incision and drainage is not sufficient - the cyst lining has to be removed to prevent recurrence. Inflamed ECs can be treated with intralesional corticosteroids, and surgical removal should be deferred until the inflammation has resolved.

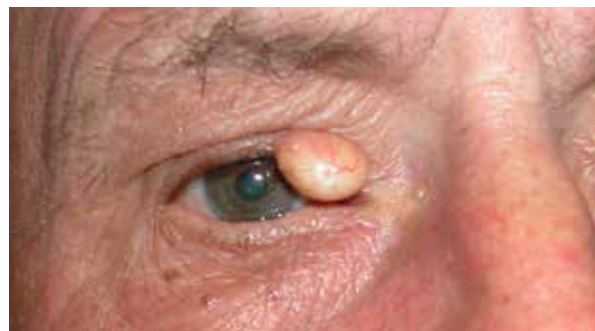

Fig 6 – Epidermal cyst of the superior eyelid with a central punctum.

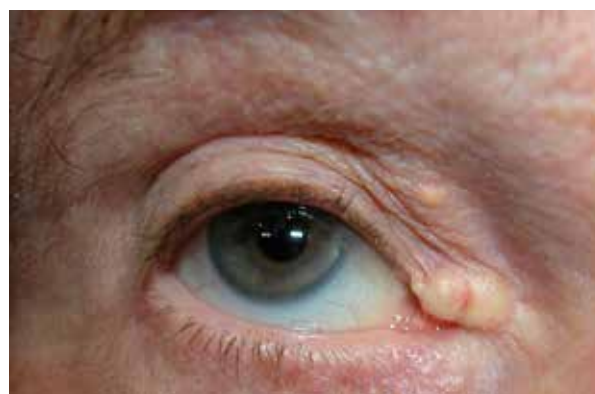


Fig 7 – Epidermal cyst of the inner canthus.

ADNEXIAL TUMORS

Hidrocystoma

Hidrocystomas are benign cysts secondary to the proliferation of eccrine or apocrine sweat glands. They tend to appear in adulthood. Hidrocystomas are usually small, solitary, flesh-colored translucent lesions, with a predilection for the medial canthus. Occasionally, they have a blue tinge or pigmentation. Eccrine hidrocystomas differ from apocrine hidrocystomas in that they tend to increase in size in hot weather, probably due to increased perspiration. Treatment is excision of the cyst along with its wall and is usually only necessary for cosmesis. (Fig. 8,9)

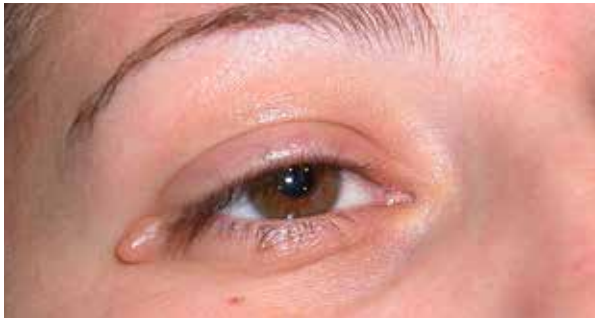

Fig. 8 – Hidrocystoma of external canthus.

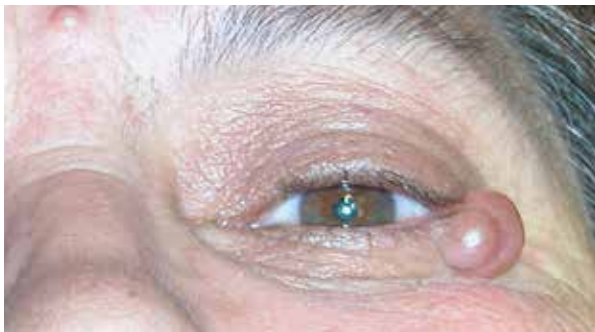

Fig. 9 – Volumous hidrocystoma of the external canthus.

Syringoma

The syringoma is a dermal tumor composed of well-differentiated eccrine ducts. It is unclear if these lesions are true adnexal neoplasms or a hyperplastic response to an inflammatory reaction⁷. They are typically found in healthy young women, but there is also an increased frequency in Down's, Marfan's, and Ehlers Danlos' syndromes.⁸ A syringoma presents as multiple, small (1-3 mm diameter), firm, yellowish or skin-colored papules, with a smooth surface. There are usually numerous lesions distributed symmetrically on the cheek and lower eyelid. Treatment is purely for cosmetic purposes. A number of options are available (such as excision, dermabrasion and cryotherapy), but the risk of scarring and recurrence limits their use, as the final result might be even less cosmetically acceptable to the patient. (Fig. 10)

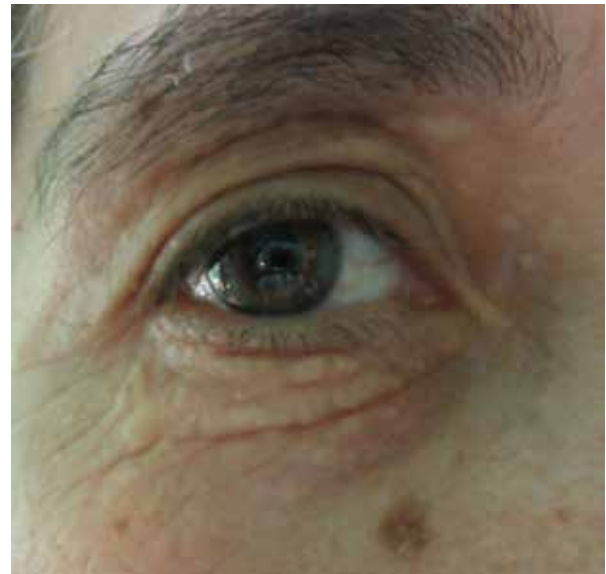

Fig. 10 – Periorcular syringoma.

NEURAL TUMORS

Neurofibroma

Neurofibromas are tumors of the distal end of a nerve, consisting of Schwann cells, axons and endoneural fibroblasts. They can be isolated, in sporadic cases, or associated with Type 1 Neurofibromatosis (NF1). In NF1, neurofibromas are usually multiple and typically appear by the 2nd decade of life, which is earlier than sporadic cases. Neurofibromas can appear at any cutaneous site, including the eyelids. They are slowly growing, flesh-colored, soft papules or nodules, occasionally pedunculated. Although most lesions are asymptomatic, some patients report intense pruritus. (Fig. 11)

The plexiform neurofibroma, characteristic of NF1, is a variant involving a large peripheral nerve and its branches. It infiltrates the surrounding soft tissues, possibly causing periorcular deformation, amblyopia and mechanical ptosis. The irregular rope-like structure of the tumor gives rise to a wormy feeling on palpation. Isolated lesions can be surgically excised if there is a functional or cosmetic concern. Plexiform neurofibromas are harder to manage due to their highly infiltrative nature, often making complete resection impossible. Clinical trials are in progress to evaluate the efficacy of chemotherapy in these cases.^{9, 10}

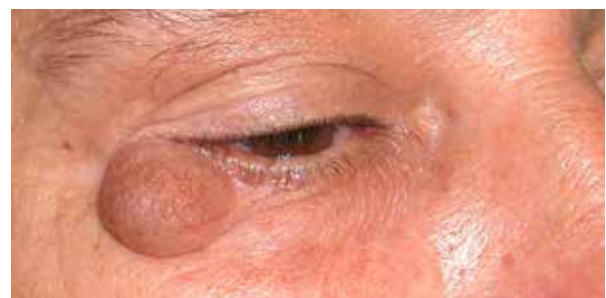

Fig. 11 – Isolated neurofibroma of the inferior eyelid.

13. Eyelid Tumors

MELANOCYTIC TUMORS

Melanocytic Nevus

Melanocytic nevi (MN) are benign lesions composed of melanocytes that colonize the epidermis or dermis. Eyelid nevi can be congenital or acquired. Acquired nevus appears in childhood in the basal epithelium and gradually deepens so that later in life it is localized in the dermis.

The appearance of eyelid nevi can range from a non-pigmented lesion (amelanotic) (Fig. 12A,B,C) to a variable pigmented lesion (Fig 12D). Nevi of the margin can extend to the conjunctiva and surround the punctum. These lesions are not usually associated with madarosis and can have a smooth or a verrucous surface. MN are classified as junctional, compound and intradermal. A junctional nevus is composed of nests of melanocytic cells at the basal level of the epidermis. Melanocytic cells in the dermis are a characteristic feature of the intradermal nevus.

When the fibrotic component is considerable nevi can resemble neurofibromas.⁴⁴

Management consists of periodic observation with excision if suspected features appear like rapid growing or changing in pigmentation.

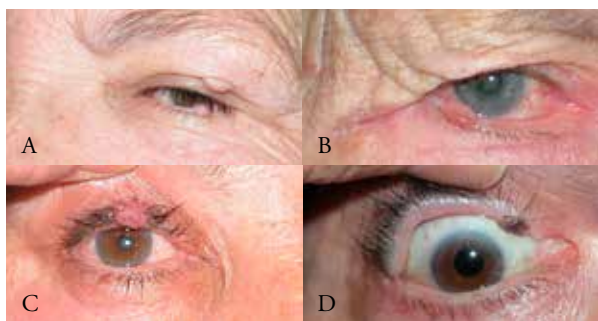


Fig. 12 – A, B and C) Amelanotic nevi. D) Pigmented nevus of the eyelid.

VASCULAR TUMORS

Cherry Hemangioma (senile or acquired hemangioma)

Cherry hemangioma (CH) is a common cutaneous lesion in elderly and middle aged adults. The number may vary but the lesions are usually small and often neglected. Solitary hemangioma of the eyelid presents as a red dome shaped nodule that can bleed with trauma. Clinically, it is similar to a pyogenic granuloma. Histopathologically, it is very similar to the congenital capillary hemangioma of infancy, with numerous newly formed capillaries arranged in lobules.

These lesions are usually benign and can be managed with periodic observation. For cosmetic purposes or if

suspected features appear, the lesions can be excised. (Fig. 13,14)

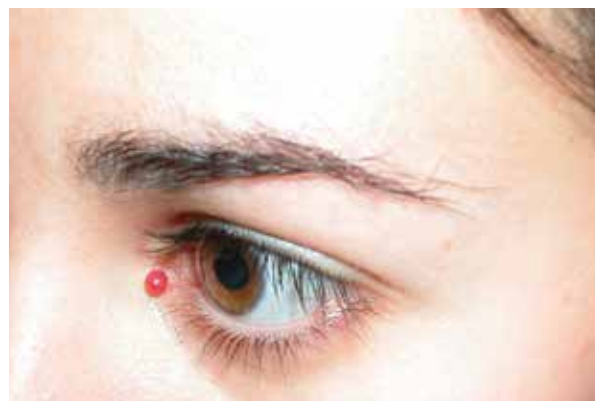

Fig. 13 – Cherry hemangioma of the inner canthus.

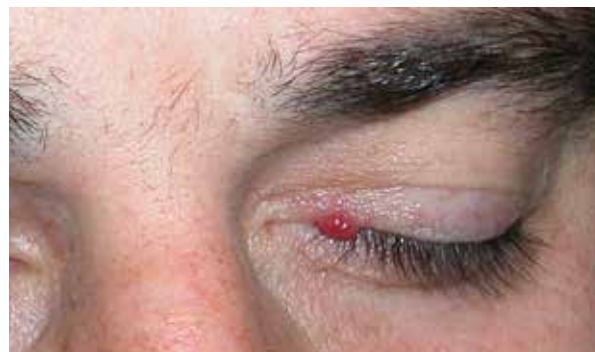

Fig. 14 – Cherry hemangioma of the superior eyelid.

INFECTIOUS LESIONS

Verruca vulgaris

Verruca vulgaris, or common wart, is caused by an epidermal infection with the human papillomavirus. Incidence increases in school-aged children and young adults, peaking at 12-16 years.¹¹ They present as hyperkeratotic papules with an irregular surface. The filiform variant has fingerlike hyperkeratotic projections and is more common in the eyelids. If lesions are located on the lid margin, virus particles can be shed into the tear film, resulting in secondary subacute papillary conjunctivitis. These patients often experience foreign body sensation and photophobia. A punctate epithelial keratopathy can also occur, with or without conjunctivitis. If untreated, chronic inflammation can lead to the development of peripheral corneal neovascularization¹². Most cases are self-limiting, and observation is recommended, as attempted excision can spread the infection.

Molluscum Contagiosum

Molluscum contagiosum is a common, benign,

self-limiting skin infection caused by a DNA poxvirus. Infection first occurs by direct contact and subsequently by autoinoculation. It typically affects healthy young children, aged 1-4 years, but sexually active adults and immunocompromised patients are also at an increased risk.¹³ (Fig. 17)

Lesions can be found anywhere on the body, except on the palms of the hands and soles of the feet.¹⁴ The eyelid is the most commonly involved periocular site, but conjunctival cases have been reported.^{15,16} Lesions are typically small, multiple, appearance. (Fig. 15, 16) umbilicated papules, with a pearly appearance. Immunocompromised patients may present with giant, disseminated lesions. Similarly to the common warts, lesions at the lid margin may cause secondary papillary conjunctivitis. Papules at the inner canthus can result in punctual occlusion. Other ocular sequelae include superficial epithelial keratitis and conjunctival scarring. The diagnosis is usually clinical owing to the distinctive appearance of the papules. Most lesions resolve spontaneously after a few months, but treatment may be necessary if ocular complications occur. Options include excision, incision and curettage, or cryotherapy.

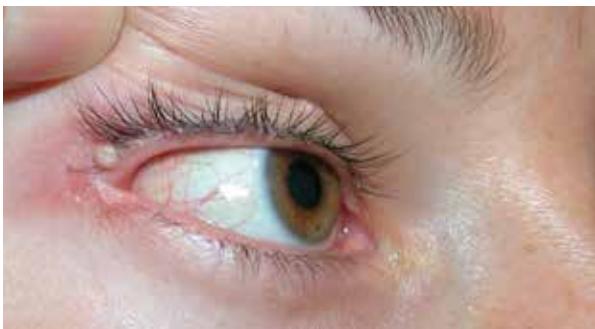

Fig. 15 – Two *Molluscum contagiosum* lesions in the superior eyelid.

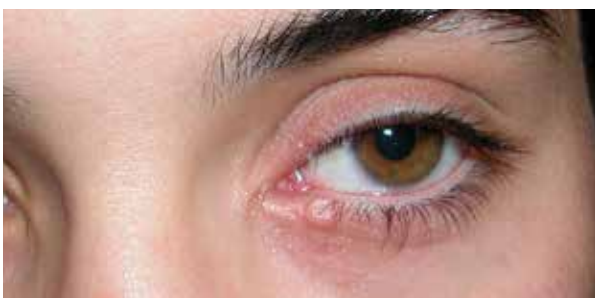

Fig. 16 – *Molluscum contagiosum* lesion in the inferior eyelash line.

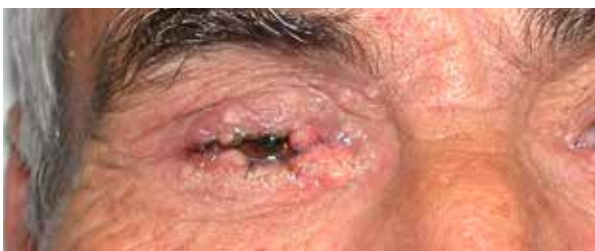

Fig. 17 – Multiple lesions of *Molluscum Contagiosum* in a HIV patient.

XANTHOMATOUS LESIONS

Xanthelasma

A xanthelasma is a tumor composed of lipid-rich foam cells located in the superficial dermis. It presents as sharply demarcated, soft, yellowish plaques that progress and coalesce. The upper eyelid and inner canthus are the most commonly involved sites, but the four eyelids can be simultaneously involved. (Fig. 18) Case studies show a female predominance and a peak incidence in the 4th and 5th decades of life. Mean concentration of cholesterol and triglycerides is higher in patients with xanthelasmas, and hyperlipidemia occurs in up to 50% of patients.¹⁷ Therefore, lipid plasma screening is warranted. Regardless of the lipid levels, xanthelasmas have been reported to be risk predictors of myocardial infarction, ischemic heart disease, severe atherosclerosis, and death in the general population.¹⁸

Xanthelasmas rarely cause a functional impact, and treatment is usually sought for esthetic reasons. Treatment options include surgical excision and ablation with various lasers, such as carbon dioxide and Nd-YAG. Nevertheless, recurrence is common.¹⁹

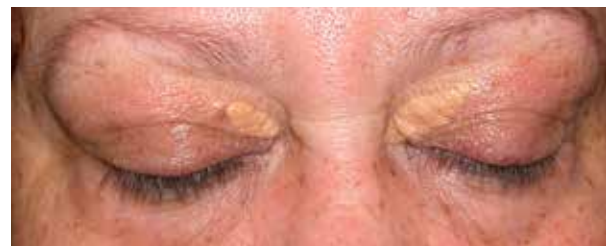

Fig. 18 – Xanthelasmas of the medial 1/3 and inner canthus of both superior eyelids.

INFLAMMATORY LESIONS

Chalazion

A chalazion is a lipogranulomatous inflammatory lesion arising from an obstructed sebaceous gland, usually the meibomian glands. Initially, the retained sebaceous secretions may cause an acute sterile inflammatory reaction, with lid redness and edema. If left untreated it usually progresses to a chronic lesion, presenting as a painless nodule located within the tarsal plate. Marginal chalazia are caused by the obstruction of a gland of Zeiss. (Fig. 19, 20)

Blepharitis is an important risk factor, and rosacea is associated with multiple, recurrent chalazia. Atypical or recurrent chalazia should be biopsied to rule out an underlying malignancy, such as a sebaceous gland carcinoma.

Acute lesions may respond to conservative treatment using hot compresses to incite drainage, but only

13. Eyelid Tumors

46 % resolve.²⁰ Expression can be tried in newly formed lesions. The standard treatment for chronic chalazia has been incision and curettage. Intralesional triamcinolone acetonide injection has emerged as a less invasive alternative, with similar efficacy to curettage.²¹

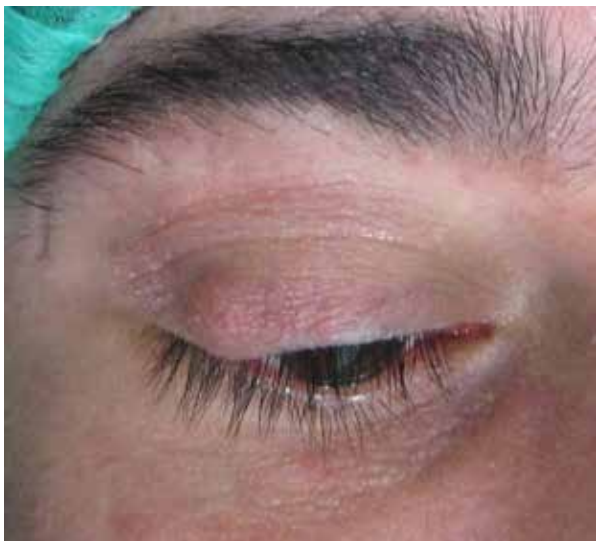

Fig 19 - Superior eyelid chalazion (cutaneous view).

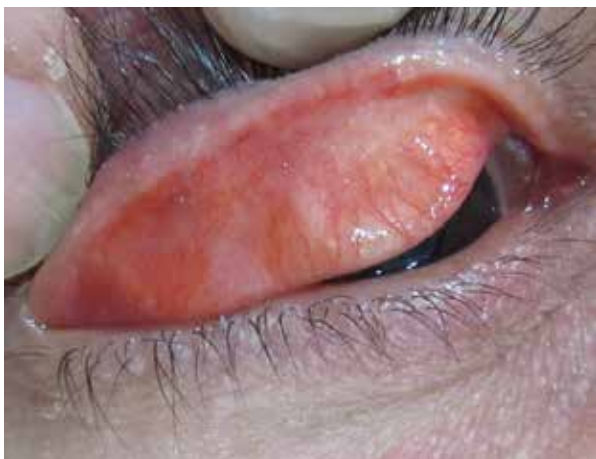

Fig 20 - Chalazion (tarsal view).

Hordeolum

A hordeolum is an acute focal pyogenic lesion of the eyelid, usually caused by *Staphylococcus aureus*. It involves either a cilium follicle and the surrounding Zeiss and Moll glands (external hordeolum) or, less commonly, the meibomian glands (internal hordeolum). An external hordeolum usually presents as a painful nodule at the eyelid margin; a pustule may be seen. Similarly, internal hordeola lead to a localized abscess in the posterior tarsal surface, with pain and edema.

Spontaneous discharge frequently occurs, leading to symptom relief and lesion resolution within the first week. Topical antibiotics and warm compresses expedite the healing process and prevent infection

spread – unresponsive lesions can be surgically drained. Oral antibiotics are reserved for diffuse infections, such as secondary cellulitis.

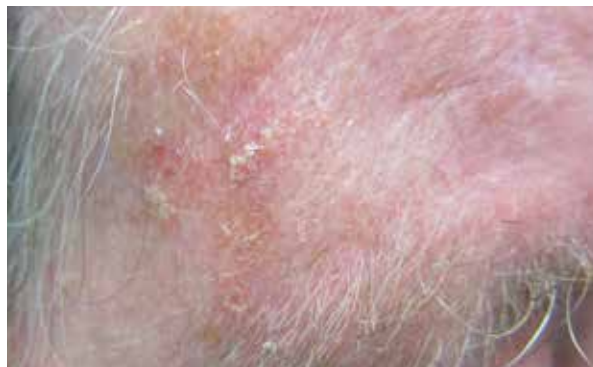

Fig. 21 – Lesions of actinic keratosis in the frontal region.

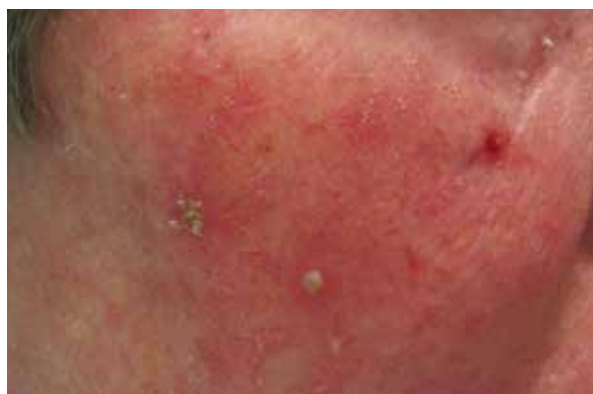

Fig. 22 – Actinic keratosis lesions in the cheek.

PRE MALIGNANT LESIONS

Actinic Keratosis

Actinic Keratosis (AK) is a UV-induced precancerous epithelial lesion, frequently seen in older, fair-skinned individuals on the head, neck and forearms. AK typically appears as multiple flat, scaly, erythematous papules, sometimes associated with pruritus, pain and bleeding.

Histologically, actinic keratosis is characterized by focal or confluent parakeratosis overlying an epidermis of variable thickness. Atypical keratinocytes appear in the deeper epidermal layers and form buds that protrude to the superficial dermis²⁹.

AK is part of a continuum in photodamaged skin that could lead to squamous cell carcinoma (SCC). Risk of progression of AK to primary SCC (invasive or in situ) is 0.60 % at 1 year and 2.57 % at 4 years.³⁰ Although the transformation risk is low, most physicians agree that preemptive treatment is warranted to decrease the morbidity associated with SCC, as well as for symptomatic relief. Treatment options include lesion-targeted destruction such as surgical excision and liquid nitrogen cryosurgery, or field therapies targeting areas of photodamaged skin, usually reserved for patients

with multiple and/or large lesions. FDA-approved topical agents include 5-fluoracil, 5% imiquimod cream and 3% diclofenac gel.

MALIGNANT TUMORS

5-10 % of all skin cancers occur in the eyelids. Basal cell carcinoma is the most common malignant eyelid tumor, followed by squamous cell carcinoma, sebaceous gland carcinoma, and malignant melanoma.²²

Basal Cell Carcinoma

Basal cell carcinoma (BCC) is by far the most common malignancy affecting the eyelids, accounting for 90 % of cancers at this site. It typically affects fair-skinned individuals in the 5th decade and beyond. Excessive ultraviolet exposure is the most important risk factor; exposure to arsenic, coal tar derivatives and irradiation also plays a role.²³ BCC is rare in black-skinned individuals due to the inherent photoprotection of melanin and melanosomal dispersion.²⁴ The lower eyelid is the most commonly involved site (50-60 %), followed by the medial canthus, upper eyelid and lateral canthus. BCC arises from a pluripotent cell in the basal layer of the epidermis. The cells proliferate inwards and eventually differentiate to give rise to various clinical manifestations:

1. Noduloulcerative BCC – a slowly growing, painless, firm, pearly/pink nodule with telangiectatic vessels in its surface. As it grows, central ulceration occurs and is surrounded by rolled edges with telangiectasias. (Fig. 23A, B)
2. Pigmented BCC – a brown/black lesion, otherwise similar to noduloulcerative BCC. (Fig. 23c)
3. Sclerosing BCC – a flat, indurated, pink or ivory-white infiltrative plaque. The margins are difficult to delineate, but palpation usually reveals an extensive lesion, larger than inspection might suggest. It is an aggressive subtype of BCC, and its unremarkable clinical appearance makes it harder to diagnose. (Fig. 23D)
4. Superficial BCC – an erythematous patch resembling eczema, most commonly found on the trunk. (Fig. 23E)

BCC is a locally invasive slow growing tumor; doubling time is between 6 months and 1 year. Metastization is extremely rare and usually arises from large, facial, locally invasive and destructive, ulcerated, long-standing, treatment-resistant and histologically aggressive tumors.²⁵

Treatment options include Mohs micrographic surgery

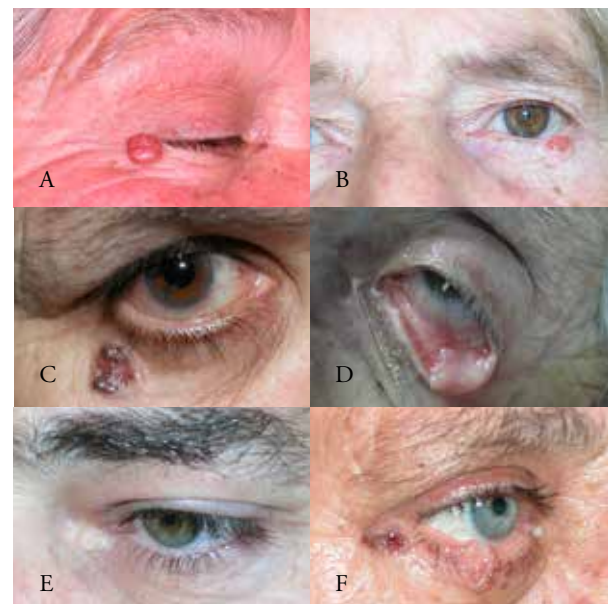

Fig. 23 – A and B) Nodular basal cell carcinoma; C) Pigmented basal cell carcinoma; D) Sclerosing basal cell carcinoma; E) Superficial basal cell carcinoma; F) Mixed nodular and pigmented basal cell carcinoma.

(MMS), standard surgical excision, radiotherapy and cryosurgery; five-year recurrence rates for these procedures are 1.0 %, 10.1 %, 8.7 % and 7.5 %, respectively.²⁶ The low recurrence rate after MMS makes it the treatment of choice for recurrent BCCs and for cases in which maximal tissue sparing is desired.¹⁴ This is particularly useful in aggressive BCCs that affect the medial canthus and which may exhibit subclinical extension to the orbital bones or sinuses²⁷. Tumor regression has been reported with topical chemotherapy, such as imiquimod and 5-fluoracil.²⁸ It is usually reserved for low-risk BCCs, when surgery is contraindicated or undesired.

Squamous Cell Carcinoma

Squamous cell carcinoma (SCC) is an epidermal tumor, usually arising from actinic lesions. As previously noted for AK, it usually affects older, fair-skinned individuals. Risk factors include UV, ionizing radiation and carcinogens such as arsenic and aromatic hydrocarbons. Some genodermatoses, such as Xeroderma Pigmentosum, are also associated with an increased risk of developing SCCs due to defective DNA repair mechanisms.¹⁴

SCC usually presents as a firm, erythematous and keratotic plaque or papule, with indistinct margins; ulceration is variable. The lower eyelid is the most commonly affected periocular site.³¹ (Fig. 24)

Unlike BCCs, local invasion and metastization are frequent. The prevalence of lymph node metastasis may be as high as 24 %.³¹ The presence of concomitant strabismus is suggestive of orbital and perineural spread. In these cases, orbital exenteration is needed

13. Eyelid Tumors

to achieve cure.³² Localized SCCs, similarly to BCCs, can be treated with MMS, standard surgical excision and cryosurgery.

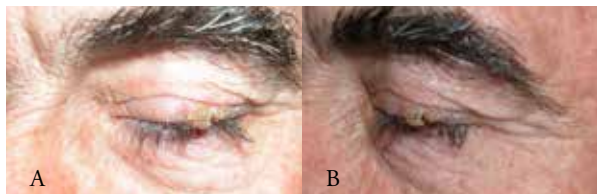


Fig. 24 – a and b) Squamous cell carcinoma of the superior eyelid.

Sebaceous Gland Carcinoma

Sebaceous Gland Carcinoma (SGC) is a rare, highly aggressive tumor that arises from the meibomian glands and, less commonly, from the Zeiss and other periorbital sebaceous glands. It usually affects individuals in the 6th and 7th decade, with a slight male predisposition.³³ Reported risk factors include radiation (i.e. after radiotherapy for retinoblastoma) and Muir-Torre syndrome.^{34,35}

In contrast to BCC and SCC, SGC is most commonly found in the upper eyelid, where meibomian glands are more frequent. Moreover, it may affect any periorbital site, including the caruncle.³⁶

Eyelid SGCs typically present as a painless, indolent, subcutaneous nodule. It might have a yellowish aspect, thus mimicking a chalazion. A less common presentation is a spreading variant, with diffuse infiltration and thickening of the eyelid, causing eyelash distortion and madarosis.

Owing to its non-specific appearance, a clinical diagnosis is rare.¹ SGC is a masquerade syndrome as it might resemble various common ophthalmologic conditions, such as recurrent chalazia, chronic blepharoconjunctivitis and cicatricial pemphigoid.

SGC is highly invasive: distant metastases occur in up to 25 % of patients, and overall 5-year survival is 75 %.^{33,37} Treatment is surgical excision with wide margins. Maximal tissue conservation can be achieved with MMS.³⁷ Radiotherapy is not recommended as a primary treatment.³⁷ Multicentric SGC may occur, and therefore excisional biopsy should be accompanied by map biopsies of both the tarsal and bulbar conjunctiva. Sentinel lymph node biopsy should be performed for tumors larger than 1 cm and in those that involve the full lid thickness.³⁸ Exenteration is usually reserved for large, invasive tumors or for those with significant bulbar conjunctival involvement. (Fig. 25, 26)

Merkel Cell Carcinoma

Merkel cell carcinoma (MCC) is a rare cutaneous neuroendocrine carcinoma that is associated with regional and distant metastasis, local recurrence

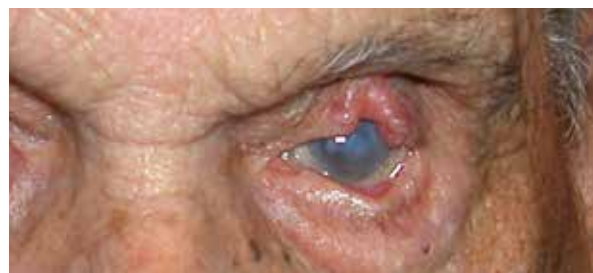


Fig. 25 – Sebaceous gland carcinoma of the superior eyelid.

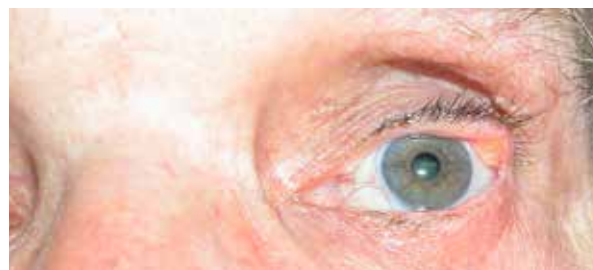


Fig. 26 – Sebaceous gland carcinoma of the superior eyelid.

and a significant mortality rate. MCC of the eyelid has a better prognosis because it is detected earlier. Immunosuppression, ultraviolet radiation and polyomavirus³⁹ are important predisposing factors. It occurs most commonly in fair skinned patients, older than 50 years, on sun exposed skin.

MCC often presents as a rapid growing, firm, red to violaceous papule or nodule. (Fig. 27)

Diagnosis is made by incisional biopsy and immunohistochemistry.

Patients usually present with a localized disease but it can spread rapidly to regional nodes and distant sites, very often to distant lymph nodes followed by the liver, lung, bone and brain.⁴³ The regional draining nodes are the most common site of recurrence⁴⁰ and metastasis.

Treatment is based on the stage of the disease. Primary treatment consists of a wide lesion excision (5 mm margin⁴¹) with margin control, or Mohs micrographic surgery with or without adjunctive radiotherapy. Sentinel lymph node biopsy should be performed routinely on MCC patients.⁴²

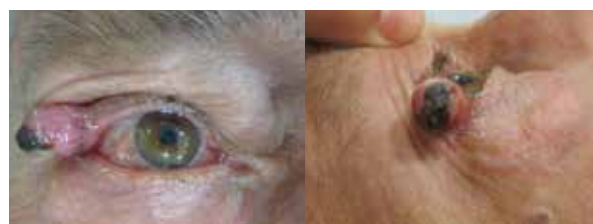

Fig. 27 –Merkel cell carcinoma of the superior eyelid: a) Front view, b) Lateral view.

Bibliography

- Deprez M, Uffer S. Clinicopathological features of eyelid skin tumors. A retrospective study of 5504 cases and review of literature. *The American Journal of dermatopathology*. 2009 May;31(3):256-62.
- Goldsmith LA, Fitzpatrick TB. *Fitzpatrick's dermatology in general medicine*. New York: McGraw-Hill Professional; 2012. Available from:
- Cribier B, Asch P, Grosshans E. Differentiating squamous cell carcinoma from keratoacanthoma using histopathological criteria. Is it possible? A study of 296 cases. *Dermatology*. 1999;199(3):208-12.
- Sanchez Yus E, Simon P, Requena L, et al. Solitary keratoacanthoma: a self-healing proliferation that frequently becomes malignant. *The American Journal of dermatopathology*. 2000 Aug;22(4):305-10.
- Mandrell JC, Santa Cruz D. Keratoacanthoma: hyperplasia, benign neoplasm, or a type of squamous cell carcinoma? *Seminars in diagnostic pathology*. 2009 Aug;26(3):150-63.
- Karaa A, Khachemoune A. Keratoacanthoma: a tumor in search of a classification. *International journal of dermatology*. 2007 Jul;46(7):671-8.
- Dutton JJ, Gayre GS, Proia AD. *Diagnostic atlas of common eyelid diseases*. New York, NY London: Informa Healthcare ; Taylor & Francis distributor; 2007.
- Goldsmith LA, Fitzpatrick TB. *Fitzpatrick's dermatology in general medicine*. Eighth edition. ed.
- Weiss B, Widemann BC, Wolters P, et al. Sirolimus for progressive neurofibromatosis type 1-associated plexiform neurofibromas: a Neurofibromatosis Clinical Trials Consortium phase II study. *Neuro-oncology*. 2015 Apr;17(4):596-603.
- Kebudi R, Cakir FB, Gorgun O. Interferon-alpha for unresectable progressive and symptomatic plexiform neurofibromas. *Journal of pediatric hematology/oncology*. 2013 Apr;35(3):e115-7.
- Silverberg NB. Human papillomavirus infections in children. *Current opinion in pediatrics*. 2004 Aug;16(4):402-9.
- Krachmer JH, Mannis MJ, Holland EJ. *Cornea*. 3rd ed. St. Louis, Mo. ; London: Mosby; 2010.
- Olsen JR, Gallacher J, Piguet V, et al. Epidemiology of molluscum contagiosum in children: a systematic review. *Family practice*. 2014 Apr;31(2):130-6.
- Fitzpatrick TB, Wolff K, Carucci JA. *Fitzpatrick's dermatology in general medicine*. 7th ed. New York: McGraw-Hill Medical; 2008.
- Schulz D, Sarra GM, Koerner UB, et al. Evolution of HIV-1-related conjunctival molluscum contagiosum under HAART: report of a bilaterally manifesting case and literature review. *Graefes's archive for clinical and experimental ophthalmology = Albrecht von Graefes Archiv fur klinische und experimentelle Ophthalmologie*. 2004 Nov;242(11):951-5.
- Ingraham HJ, Schoenleber DB. Epibulbar molluscum contagiosum. *American journal of ophthalmology*. 1998 Mar;125(3):394-6.
- Rohrich RJ, Janis JE, Pownell PH. Xanthelasma palpebrarum: a review and current management principles. *Plastic and reconstructive surgery*. 2002 Oct;110(5):1310-4.
- Christoffersen M, Frikke-Schmidt R, Schnohr P, et al. Xanthelasmata, arcus corneae, and ischaemic vascular disease and death in general population: prospective cohort study. *Bmj*. 2011;343:d5497.
- Lee HY, Jin US, Minn KW, et al. Outcomes of surgical management of xanthelasma palpebrarum. *Archives of plastic surgery*. 2013 Jul;40(4):380-6.
- Goawalla A, Lee V. A prospective randomized treatment study comparing three treatment options for chalazia: triamcinolone acetonide injections, incision and curettage and treatment with hot compresses. *Clinical & experimental ophthalmology*. 2007 Nov;35(8):706-12.
- Ben Simon GJ, Rosen N, Rosner M, et al. Intralesional triamcinolone acetonide injection versus incision and curettage for primary chalazia: a prospective, randomized study. *American journal of ophthalmology*. 2011 Apr;151(4):714-8 e1.
- Cook BE, Jr., Bartley GB. Treatment options and future prospects for the management of eyelid malignancies: an evidence-based update. *Ophthalmology*. 2001 Nov;108(11):2088-98; quiz 99-100, 121.
- Crowson AN. Basal cell carcinoma: biology, morphology and clinical implications. *Modern pathology : an official journal of the United States and Canadian Academy of Pathology, Inc*. 2006 Feb;19 Suppl 2:S127-47.
- Gloster HM, Jr., Neal K. Skin cancer in skin of color. *Journal of the American Academy of Dermatology*. 2006 Nov;55(5):741-60; quiz 61-4.
- Nongrum HB, Bhuyan D, Royte V, et al. Metastatic basal cell carcinoma to the lungs: Case report and review of literature. *Indian dermatology online journal*. 2014 Nov;5(Suppl 1):S26-9.
- Rowe DE, Carroll RJ, Day CL, Jr. Long-term recurrence rates in previously untreated (primary) basal cell carcinoma: implications for patient follow-up. *The Journal of dermatologic surgery and oncology*. 1989 Mar;15(3):315-28.
- Yanoff M, Duker JS. *Ophthalmology*. 4th edition. ed.
- Sullivan TJ. Topical therapies for periorbital cutaneous malignancies: indications and treatment regimens. *Current opinion in ophthalmology*. 2012 Sep;23(5):439-42.
- Yanoff M, Sassani JW. *Ocular pathology*. Seventh edition. ed.
- Criscione VD, Weinstock MA, Naylor MF, et al. Actinic keratoses: Natural history and risk of malignant transformation in the Veterans Affairs Topical Tretinoin Chemoprevention Trial. *Cancer*. 2009 Jun 1;115(11):2523-30.
- Faustina M, Diba R, Ahmadi MA, et al. Patterns of regional and distant metastasis in patients with eyelid and periocular squamous cell carcinoma. *Ophthalmology*. 2004 Oct;111(10):1930-2.
- Soysal HG, Markoc F. Invasive squamous cell carcinoma of the eyelids and periorbital region. *The British journal of ophthalmology*. 2007 Mar;91(3):325-9.
- Dasgupta T, Wilson LD, Yu JB. A retrospective review of 1349 cases of sebaceous carcinoma. *Cancer*. 2009 Jan 1;115(1):158-65.
- Kivela T, Asko-Seljavaara S, Pihkala U, et al. Sebaceous carcinoma of the eyelid associated with retinoblastoma. *Ophthalmology*. 2001 Jun;108(6):1124-8.
- Kyllo RL, Brady KL, Hurst EA. Sebaceous carcinoma: review of the literature. *Dermatologic surgery : official publication for American Society for Dermatologic Surgery [et al]*. 2015 Jan;41(1):1-15.
- Shields JA, Shields CL, Marr BP, et al. Sebaceous carcinoma of the caruncle. *Cornea*. 2006 Aug;25(7):858-9.
- Snow SN, Larson PO, Lucarelli MJ, et al. Sebaceous carcinoma of the eyelids treated by mohs micrographic surgery: report of nine cases with review of the literature. *Dermatologic surgery : official publication for American Society for Dermatologic Surgery [et al]*. 2002 Jul;28(7):623-31.
- Esmaeli B, Nasser QJ, Cruz H, et al. American Joint Committee on Cancer T category for eyelid sebaceous carcinoma correlates with nodal metastasis and survival.

13. Eyelid Tumors

- Ophthalmology. 2012 May;119(5):1078-82.
39. Feng H, Shude M, Chang Y, Moore PS. Clonal integration of poliovirus in human Merkel cell carcinoma, Science 2008;319:1096-100
 40. Agelli M, Clegg LX. Epidemiology of primary Merkel cell carcinoma in the United States. Journal of American Academy of Dermatology. 2003;49(5):832-41
 41. Peter et al. Management and prognosis of Merkel cell carcinoma of the eyelid. Ophthalmology, 2001
 42. Merkel cell carcinoma Chapter 30, AJCC Cancer staging manual, 2009 Springer
 43. Voog E, Biron P, Martin JP, Blay JY. Chemotherapy for patients with locally advanced or metastatic Merkel cell carcinoma. Cancer. 1999;85(12):2589-95.
 44. Jerry Shields, Carol Shields. Eyelid, conjunctival and orbital tumors. An atlas and textbook. 3rd ed 2016 Wolters Kluwer.

14. Superior Eyelid Reconstruction

João Cabral, Mara Ferreira

As a unique and complex area, the periocular region has many important anatomic, functional and aesthetic particularities that can easily be affected and distorted by tumors, trauma or other factors. The periocular region is divided into aesthetic-functional units, one of which is the superior eyelid. Superior eyelid reconstruction is often complementary to cancer surgery in which a malignant lesion is excised with tumor-free margins, or trauma situations with soft tissue defect. Less frequently, other conditions may require this surgical intervention, such as necrosis or post-infectious cicatricial retraction, radiotherapy, thermal burns and colobomas that can lead to eyelid defects. Visual and aesthetic consequences of varying degrees of severity can arise in any of these cases. Regardless of the cause, superior eyelid defects are approached with the same methods.

Surgically, the following priorities must be taken into account: in the presence of a malignant oncologic condition we must first ensure a tumor-free margin; second, we must preserve the eyelid's protective function, maintaining stability and adequate mobility without interfering with the eyeball; finally, we must achieve a good aesthetic result. All these steps present a great challenge.¹⁻⁵

Eyelid reconstruction sets out to reestablish its normal anatomy and function. Naturally, it is essential to have a thorough knowledge of the eyelid, ocular, lacrimal and orbital anatomy and physiology, as well as the reconstruction techniques. Otherwise, it is impossible to achieve an acceptable anatomic and functional outcome that is also a comfortable solution for the patient.

Eyelids are internally covered by conjunctiva. This mucous membrane is essential to maintain ocular lubrication and prevent corneal irritation. Rigid tarsal support helps the eyelid keep its shape and allows its vertical movements. A stable eyelid margin is necessary to keep the eyelashes and skin from damaging the cornea and at the same time permits good lipidic and aqueous lacrimal function. Proper fixation of the inner and outer corners is essential to maintain eyelid shape and position adjacent to the

ocular surface. Canthal tendons form the structural support of the orbicularis muscle, responsible for the eyelid closure that is required for proper eye protection; the levator palpebrae superioris muscle is primarily responsible for satisfactory eye opening, which is essential for a good visual field. Finally the skin surface should be thin and redundant enough to ensure that blinking is easy and effortless. Largely due to its sparse dermis, the eyelid skin is the thinnest skin of the body. This characteristic allows rapid wound healing but can also pose a difficulty when finding skin donor sites with similar color characteristics, texture and thickness.

Given the unique characteristics of the eyelids, caution must be used in defect reconstruction. Repair should not cause harm to the eye. Bearing that in mind, one must first look for a solution that uses residual eyelid tissue before thinking about seeking substitutes.^{4,6,7}

Usually, patients with eyelid margin lesions (which are generally full-thickness) go to an ophthalmologist, while those with lesions in other locations, which may be partial thickness defects (anterior lamella), go to a dermatologist. In these cases the eyelid margin is not involved by a tumor, but reconstruction can affect it and produce anatomic and physiological periocular and ocular repercussions.⁷ Therefore, all reconstructions that might affect the eyelids directly or indirectly should be performed by an ophthalmologist with comprehensive knowledge of ocular anatomy and physiology.

Before advancing to reconstruction, a thorough assessment of the structures involved (especially in trauma cases) is required since it is essential to determine the integrity of the five basic eyelid components: anterior lamella (skin and orbicularis muscle), posterior lamella (tarsus and conjunctiva), canthal tendons (medial and lateral), canaliculus and levator palpebrae superioris muscle.

More important than being aware of the techniques described in various books, the surgeon must have clear general concepts about eyelid reconstruction, and decide on the most appropriate technique in

14. Superior Eyelid Reconstruction

each particular case.^{1,2,6}

Defect size does matter when performing an ocular-facial reconstruction, but its location is the most important feature. The reconstruction will depend on defect configuration and depth, taking into account the patient's age and skin margin condition, as well as the surgeon's experience. In all the available reconstructive surgical techniques, it is appropriate to use eye protection and a surgical microscope for better structure identification.

Generally, small anterior lamella defects can be corrected via direct suture, with or without adjacent debridement; larger defects may require myocutaneous flaps or grafts. Extensive defects usually need large myocutaneous advancement flaps, rotational flaps or large free grafts. Flaps have several advantages over free skin grafts, as discussed below.

Scar appearance depends on three factors: superficial tension of the sutured tissues, characteristics of the tissues used to repair the defect, and location of skin incisions.

To minimize suture tension it is important to know the relaxed skin tension lines (Fig. 1), which indicate lowest tension direction in the relaxed skin. Incisions parallel to these lines produce the lowest possible tension; perpendicular to them are lines with the greatest tissue distensibility. Fusiform skin excisions parallel to skin tension lines simultaneously provide maximum distensibility tissue and minimum tension at the suture, leading to better healing. Debridement and deep sutures might be needed at the periocular region so that tissue tension is lower.

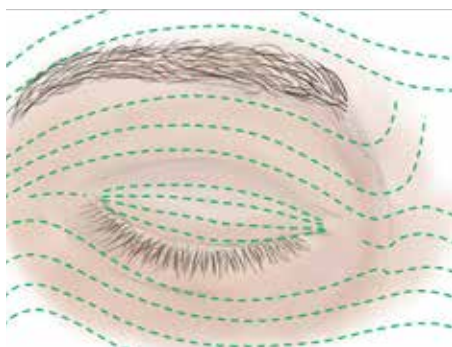


Fig. 1 – Periocular relaxed skin tension lines

Tissue characteristics are also important to conceal scars since the more similar they are in texture and thickness, the smaller the differences between the used tissues.

Finally, incisions are better disguised when placed in grooves, natural wrinkles of the skin or at aesthetic unit junctions. In young people these lines may not be spontaneously visible; for them to be exposed, ask the patient to laugh or close the eyes tightly. When it is not possible to perceive these lines, drawing curved incisions makes them less visible and less retractable

than straight ones. When possible, make incisions away from the central zone of the face, where they are more visible.

Subcutaneous tissues and muscles should be sutured with simple stitches of resorbable sutures; skin should be sutured with simple stitches, to allow better alignment and eversion of wound edges.^{1,2,5}

Full thickness defects of the eyelid (up to 1/3 of its margin) can be easily repaired with direct closure, as in the eyelid margin transfixive wound closure technique. Small lateral canthus defects can be corrected with a canthoplasty technique, canthopexy or lateral tarsal strip. Medial canthus defects are more complex to repair because of the lacrimal drainage system. If the eyelid edge's apposition generates great tension, which often occurs with defects larger than 1/3 of the margin, canthotomy and cantholysis will be necessary to allow the lateral portion of the lid to slide. Large, full-thickness defects require special techniques for closure, such as Cutler-Beard technique.^{1,4}

Anterior Lamella Reconstruction

Anterior lamella or partial thickness defects are skin and muscle defects that do not reach the posterior lamella. The various treatment possibilities depend on the location and extent of the defect and on the quality and elasticity of the neighboring skin, often associated with patient age. Thus, when planning to repair a defect, assessment of the possibility of performing a simple suture is needed; if it is not possible, debridement of the adjacent tissues could be required. If this is still not enough, we need to determine the existence of neighboring areas of relative laxity (skin reservoirs) that could provide a flap. The final alternative would be skin grafting or secondary intention healing (granulation). Sometimes these techniques are used in combination.

Secondary intention healing - granulation

Some periocular defects can be left to heal with good functional and aesthetic results. This is the case of wounds on concave surfaces such as the medial canthus. In clinical practice, this is only used in wounds less than 1 cm in diameter, as this healing method causes great skin retraction and possible cicatricial ectropion. It also requires daily wound care for weeks, which is not always practical.

Direct closure

Reconstructing small partial thickness defects with direct closure is the best option and it can be easily achieved when there is redundant skin adjacent to the defect. This often occurs in older people, except for those chronically exposed to sunlight or undergoing radiotherapy. The defect closure must

be oriented so that it induces little distortion of the eyelid and periocular tissues, and the scar is as concealed as possible, using skin folds, wrinkles and relaxed skin tension lines. Sometimes it is necessary to excise some redundant skin to convert the defect into a fusiform shape and improve healing. Since the surrounding tissues move perpendicularly along the axis of the fusiform defect, traction is maximal when the ellipse is parallel to the eyelid margin. So, we should generally seek vertical scars when the defect is near the eyelid margin. Retraction is prevented by closing the suture vertically so that the tensile forces are horizontal, not vertical (Fig. 2). A: In medial and lateral canthus, ellipses according to relaxation lines reduce tension. B: Small ellipses parallel to eyelid margin can often be closed with acceptable tension. C: The ellipses near the lid margin, when perpendicular (with tension vector parallel to the margin), induce minimal distortion. D: Placing sutures parallel to the lid margin (arrows) allows tension to be eased in non-parallel defects. E: Curving ellipse endings to be perpendicular to eyelid margins (as in S-plasty) also diminishes tension. F: Eyebrow ellipses must be drawn towards each other on the upper edges and bottom, thus keeping the vertical dimension of the eyebrow.

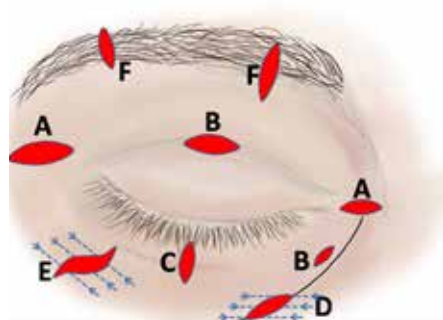


Fig. 2 - Fusiform defects direct closure

Direct closure with debridement

Direct closure with debridement is usually used in myocutaneous defect approaches away from the eyelid margin. Debridement should be performed in different layers, according to the lesion location. Inside the orbital rim, debridement should reach preseptal tissues and outside the orbital rim it should be subcutaneous. When performing this technique, caution is needed between the preauricular area and the eyebrow tail, because the facial nerve crosses the zygomatic arch, near the surface. In the frontal region, debridement should be performed between the thick subcutaneous tissue and frontalis fascia. Debridement should be enough to reduce suture closure tension. You might need deep sutures to the periosteum of the orbital rim so that the tension is

achieved at depth and not in the superficial layers.

When under no tension, skin sutures can be performed with simple stitches that allow greater alignment and margin eversion. Continuous sutures can be used where the scar can be predicted to match a natural skin groove.¹

Technically, closure with debridement can be considered as closure with small sliding flaps (Fig. 3).

Myocutaneous flaps

The redundant skin that is often present in the upper eyelid, enables small fusiform defects to be easily repaired by direct suture, with good aesthetic results.

The best option to repair anterior lamella major defects is an advancement or rotational flap obtained from the surrounding skin. Flaps from the periocular area are formed by skin and orbicularis muscle, debrided from the septal layer, and advanced or rotated to the anterior lamella defect.

There are many advantages over the free grafts because they are formed from local tissues of similar color and texture. They retain the original innervation and vascularization and thus can be placed over areas with little or no vascularization, such as bone or grafts. When creating a major flap, it is useful to choose natural skin grooves to conceal the scars, designing it to be slightly overcorrected to get the lowest possible tension at closure (if necessary using deep anchorage stitches), and compensate for posterior scar retraction.¹ Whenever possible, the flaps should have an inferior base so as to prevent chronic lymphatic edema due to drainage difficulty. If flaps have a superior base, depth and debridement should be limited to prevent this complication (Fig. 7). Most importantly, flaps must be designed to avoid tension in the free eyelid margin and other surface structures. Before making any skin incision, always assess the tension resulting from flap displacement to the primary defect, to find out how to correct the secondary defect.

Many types of flap can be used. Those most commonly used on the upper eyelid are:

- **Sliding flap:** when the surrounding skin, after debridement, is shaped to an ellipsoid defect and uniformly dragged from all directions to close the defect (Fig. 3);
- **Advancement flap:** When the neighboring skin is dissected and is advanced in its own longitudinal axis to close the defect; may be in L, M and U or double U shape (Fig. 4) or in V-Y shape (Fig. 12).
- **Rotational Flap:** when the nearby dissected skin is lifted and rotated over itself to cover the defect (Fig. 5).
- **Transposition Flap:** when the skin covering the defect is not directly adjacent. Like the glabella flap example (Fig. 13).

14. Superior Eyelid Reconstruction

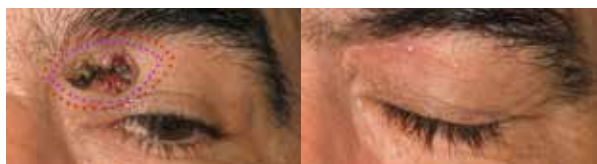

Fig. 3 - Sliding myocutaneous flap. A: Tumor (BCC) with excision margins (violet) and debridement margins (red). B: Outcome after 5 months.

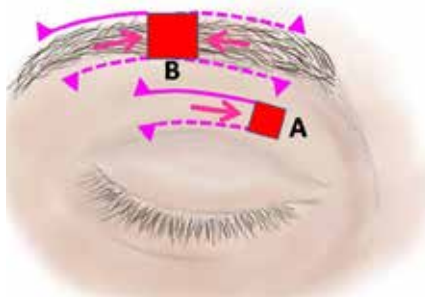


Fig. 4 - Myocutaneous advancement flaps. A: Start with upper branch of the flap incision (solid line), which is often suitable for loose skin areas, forming an L-shaped flap. For increased maneuverability, the lower branch can also be incised to form a U shaped flap. B: If necessary, add another flap, an opposite U, forming an H flap.

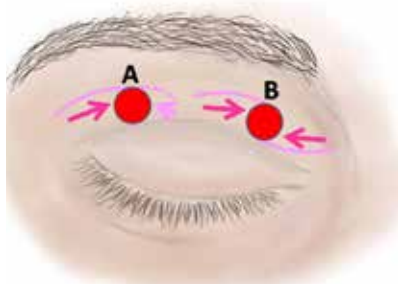


Fig. 5 - Myocutaneous rotation flaps. A: Flaps with simple rotation, which can be completed by another one, opposite, forming an A-T flap. B: Double rotation flap O-Z.

- **Rhomboid/Limberg flap:** Form of transposition flap that repairs a rhomboid defect with a triangular flap, which when rotated acquires a rhomboid shape. It is widely used in the periocular region (Fig. 6). Create a rhomboid primary defect formed by two equilateral triangles with adjacent bases. The flap has the shape of one of the triangles with one side on the line separating the two triangles on the primary defect. The primary defect does not have to be exactly rhomboidal since the flap can take many shapes (circular, oval, triangular, etc.). When close to the lid margin, the maximum tension lines (green in Fig. 6A) must be parallel to the relaxed skin lines and the palpebral edge to avoid ectropion.
- **Bilobed flap:** Originally described with two lobes, which make an angle with the same pedicled skin, this flap can have more lobes of decreasing size. Proximal and distal lobes must have same height

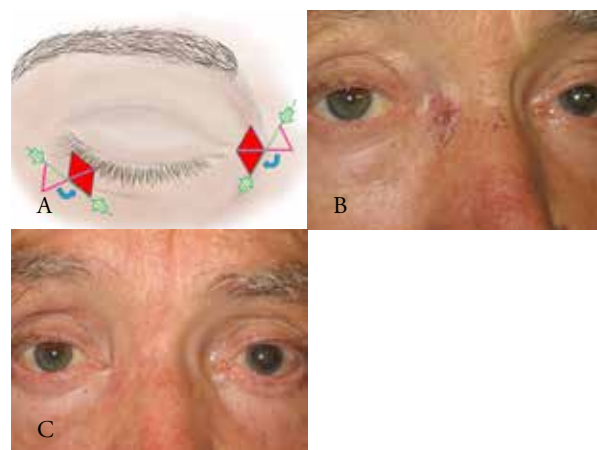


Fig. 6 - Myocutaneous transposition flaps – rhomboid/Limberg flap. A: Flap design. B: Medial canthus recurrent tumor (BCC) and design of the rhomboid flap. C: Outcome after 2 months.

as the defect, but 20-40 % narrower than the adjacent defect to be covered (Fig. 7). The first flap covers the primary defect (PD), the second flap covers the secondary defect (SD), and so on, so that the last defect is closed directly. The angle may vary between 30 and 120° and should use areas of lax skin and follow the lines of cutaneous relaxation.

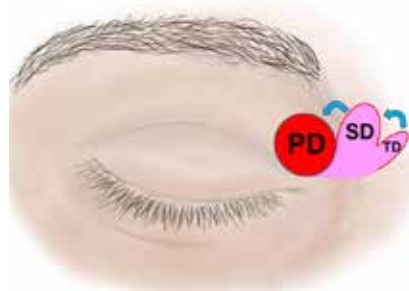


Fig. 7 - Myocutaneous bilobed flap.

- **Island pedicle flap:** when vascular supply is provided by a pedicle, sometimes formed solely by muscle, and when it is transposed under a skin bridge. The flap must be smaller than the defect to be covered. The remaining defect can be closed directly or with another flap or graft (Fig. 8).

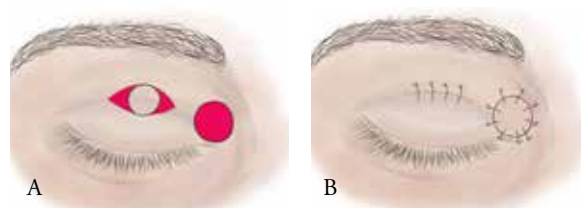


Fig. 8 - Island pedicle flap. A: primary defect and flap formation, taking advantage of excess skin from the center of the upper eyelid. B: Closure.

- **Bipedicle flap:** when it is formed by two pedicles (Fig. 14).

Free skin grafts

Free skin grafts are removed from a donor area, and placed to cover an anterior lamella defect. The vascular contribution is provided by the receptor area bed. Free skin grafts can be used alone or in combination with other reconstructive techniques. Usually used in upper eyelid defects, total skin grafts consist of epidermis and dermis layers, with all their characteristics. The donor area must therefore be a hairless skin. The most common sites are: upper eyelid skin from the opposite eye (if it has redundant tissue, it is the best option for upper eyelid), retro-auricular skin, pre-auricular, supraclavicular or inner side of the arm. Whenever possible, the donor area should be the same color, texture and thickness as the receptor area. The viability of the total skin graft depends on the vascular supply quality in the receptor area (they don't do well on bone). The graft is usually black at the end of the first week, but its normal color returns after a few weeks. It can be predicted that a slight retraction will occur (less than in thin skin grafting).

Despite the advantages, thin skin grafts are rarely used in eyelid reconstruction. They can be extensively harvested (without needing to close the donor area, as their deep dermal layer will help healing by secondary intention in weeks). They also take well over the bone (especially spongy bone), but these aspects are not often necessary in eyelid reconstruction. To remove a thin skin graft, a dermatome or a grafting knife is needed. The color, texture and thickness rarely adapt to eyelids skin. For all this, they are only used in severe myocutaneous defects, without flaps or total skin grafts possibility.^{1,2}

Reconstruction of full-thickness defects

There are several possibilities for reconstructing full-thickness defects, depending on their location and extent. The options vary from direct closure with or without debridement, the use of myocutaneous flaps, tarsal free grafts or cartilage. Although the technique depends on the defect, the ultimate decision is made in the operating room, when assessing the effective tissue elasticity. Thus, it is best to first confirm whether it is possible to perform a direct closure. If direct closure induces a very tense upper eyelid, a canthotomy and cantholysis might be necessary. If it is still not enough, a Tenzel inverted rotation flap can be an option. If the defect involves most of the upper eyelid, consider a posterior lamella graft and anterior lamella flap (advancement or bipedicle), a free skin graft, or even the Cutler-Beard technique.

Many of these techniques are similar to those used

in reconstruction of the lower eyelid. But in any case, given the functional characteristics of the upper eyelid, it is recommended that its reconstruction is performed by someone with great experience.

The reconstruction of eyelid margin defects requires strict alignment of the structures. Tension sutures must be applied on the tarsus, and margin stitches should induce its eversion so that, after complete healing, it prevents a localized depression of the margin which has potential consequences for the lacrimal physiology (although this aspect is more important when repairing the lower eyelid).¹

Generally, the technique varies according to the horizontal extent of the defect:

- 1 – up to 1/3: direct closure with or without canthotomy and cantholysis;
- 2 – up to 1/2: semi-circular flap;
- 3 – more than 1/2: special techniques.

However, these indications are not rigid: for a correct approach, in addition to size, we have to take into account the patient's age, skin condition (elasticity, scars, wrinkles, etc.) and visual performance of both eyes.⁵

1- Up to 1/3 of the eyelid length

Direct closure of the eyelid margin

Usually a direct closure of a full-thickness defect is performed when its length is less than 1/3 of the total eyelid length. The procedure is similar to that used in the lower eyelid, with the difference that for normal functioning with easy eyelid movement the upper eyelid does not support tension as much as the lower eyelid. Moreover, because the tarsus is higher, incisions perpendicular to the eyelid margin should be made throughout the entire tarsus height (forming a large pentagon), otherwise there is risk of creating an incorrect eyelid contour (Fig. 9).

We usually begin with 2 stitches on the eyelid margin (in front and at the back of the gray line and using the lash lines and orifices of the meibomian glands as markers for implantation) with 6-0 or 5-0 silk sutures, to align the eyelid edges. These sutures should be placed about 1.5-2.0 mm from the margin of the eyelid, so that when we tighten them a good eversion of the wound edges can be obtained. It can be useful to pass the two stitches with the two halves of the suture, and pull each one in an opposite direction to draw the lid edges closer and align them, and thus confirm the possibility of direct closure, and then assess the tension in the tissues (Fig. 9-B). It also facilitates the procedure to pass and tie 3 to 4 stitches of a resorbable 5-0 or 6-0 suture before tying these two sutures, which will join the two edges of the tarsus (outnumbering the classic 2-3 stitches that are used in the lower tarsus). We must ensure that

14. Superior Eyelid Reconstruction

a significant portion of the tarsus is involved (these are the sutures that will give tension to the eyelid), but keep the sutures from involving the conjunctiva thus injuring the cornea (Fig. 9-C). If it is not affected, there is no need to intervene in the levator palpebrae muscle. Finally, the two silk sutures on the edge are tied, leaving them with longer ends to be incorporated in the skin suture in order to minimize edema, immediate postoperative entropion and prevent corneal injury (Fig. 9-D).^{1,2,6}

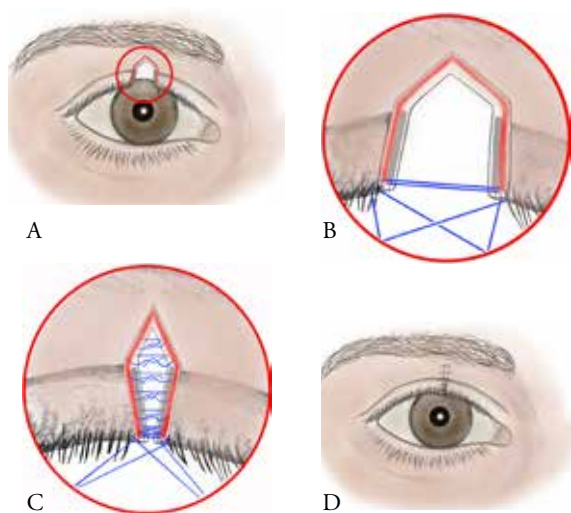


Fig. 9 - Direct closure of minor defects. B: Sutures on the lid margin. C: Sutures on the tarsus and orbicularis. D: Final outcome.

Canthotomy, cantholysis and closure of the eyelid margin

In eyelid defects in which a direct closure is not possible a canthotomy and, if necessary, cantholysis can be performed to allow complete mobilization of the lid's outer portion (Fig. 10). For canthotomy, after compression with hemostat tweezers placed horizontally (slightly downwards, to follow the inverted Tenzel flap direction, when necessary) 5 mm from the lateral canthus, full thickness tissue is cut with straight scissors in the compression site (Fig. 10-B). This canthotomy can release too few millimeters of the upper eyelid. If so, subsequent cantholysis can be done by tractioning the upper eyelid away from the eyeball and cutting the upper branch of the lateral canthal tendon with scissors through the canthotomy incision (Fig 10-C). This tendon is easily identified between the skin and conjunctiva as the scissors advance, and the tendon feels like a guitar string when tractioned. For good mobilization a complete section of the tendon is required. This maneuver can now close the eyelid defect without tension, with direct closure. Finally, canthotomy closure begins with suture of the inferior lateral canthal tendon to the subcutaneous tissues and orbicularis muscle that will form the new lateral canthus, using 6-0 resorbable suture. Finally, the skin is closed (Fig. 10-D).^{2,5,6}

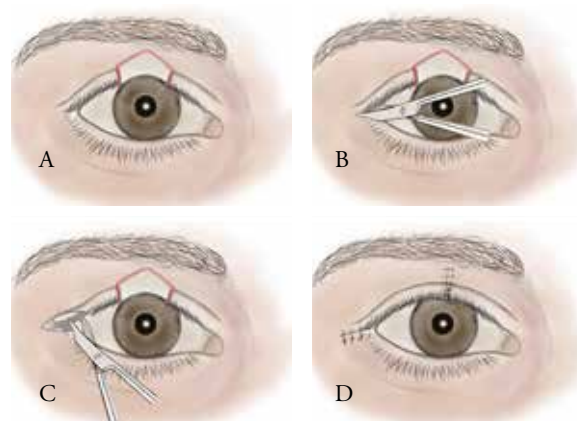


Fig. 10 - Closing mid-sized defects. B: Canthotomy. C: Cantholysis. D: Final outcome.

2- Until 1/2 of the length of the eyelid

For a full-thickness eyelid defect in which a direct closure is not possible, even with canthotomy and cantholysis, we must always repair both eyelid lamellae: the anterior (skin and orbicularis) and posterior one (tarsus and conjunctiva). To perform this reconstruction, one of the lamellae has to be responsible for vascular supply to ensure the survival of both: i.e. at least one has to be reconstructed in a flap form, while the other can be a graft.

For the upper eyelid, and for reconstruction of its anterior lamella, the most common flaps are: rotation flap of the temporal region (inverted Tenzel) (Fig. 11); U or V-Y shaped flap in the temporal region (Fig. 12); pedicle flap of the contra-lateral upper eyelid; rotation flap of the glabellar region (Fig. 13), and pedicle of the frontal region. For the anterior lamella grafts, we favor the redundant skin from the same upper eyelid or from the opposite one, retro- or pre-auricular skin, and supraclavicular region skin.

For posterior lamella flaps, we use tarsal-conjunctival flap from ipsilateral lower eyelid. In some cases we can accomplish some tarsal-conjunctival flaps obtained in own eyelid (more complex technique). For posterior lamella grafts, we can use the tarsal conjunctival free graft, hard palate, or nasal chondro-mucosal tissue.

The technique to use in each case will depend on the availability and characteristics of the implied tissues.²

Inverted Tenzel flap (between 1/3 and 1/2)

For defects between 1/3 and 1/2 of the length of the eyelid upper eyelid, an inverted Tenzel flap may be performed, similar to the one used in lower eyelid defects, but executed in reverse. It consists of an extended canthotomy and cantholysis, in which the canthotomy is elongated to form a semicircular advancement-rotation flap.

To achieve this, after canthotomy and cantholysis

the incision is extended, drawing a semi-circular flap with a 2 cm diameter upper concavity (vertical diameter larger than the horizontal diameter, e.g. 22-18 mm) (Fig. 11-A). The flap is dissected through the subcutaneous layer (debridement of the conjunctival lateral canthus is also executed) and is moved and anchored to the periosteum with deep absorbable sutures. Overlying skin should be sutured without any tension (Fig. 11-B). The formation of the new canthus is identical to that described after canthotomy and cantholysis (Fig. 11-C).^{2,4-6}

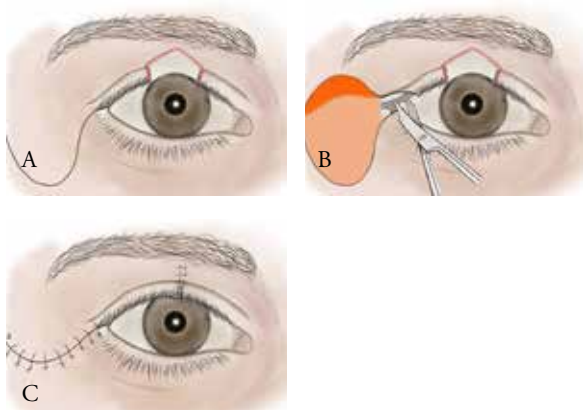


Fig. 11 – Inverted Tenzel flap. A: Drawing. B: Canthotomy, cantholysis, and flap debridement. C: Final outcome.

U or V-Y flap of temporal region

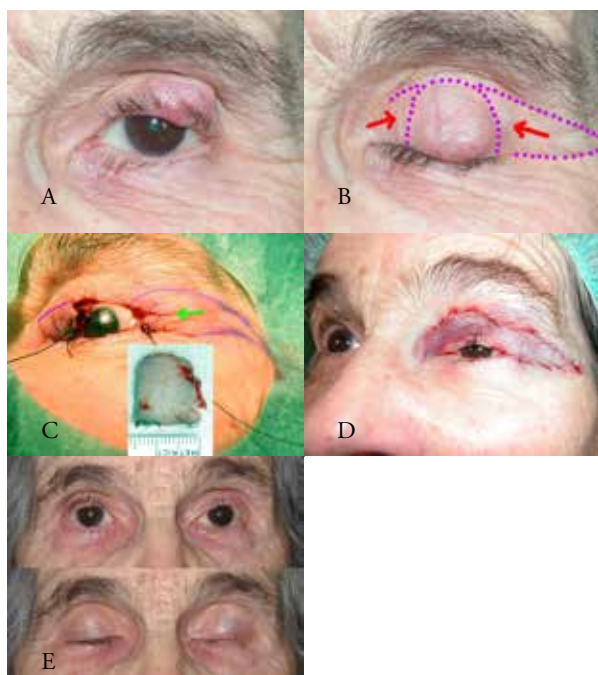


Fig. 12 - Myocutaneous advancement VY and U flaps. A: Tumor (sebaceous cell carcinoma). B: Marking area to excise, lateral advancement V-Y flap and medial in U. C: Intraoperative and excised tissue. D: Immediate postoperative period. E: Outcome after 5 years.

Rotation flap from the glabellar region

The glabella flap is often used for medial canthus and inner half defects of the upper lid. It is designed as an inverted V form, with a 60 ° angle in the glabella area between eyebrows. The base width of the drawn V covers the height of the defect and the V height covers the defect width. After rotating and suturing, the donor area is closed on V-Y (Fig. 13).

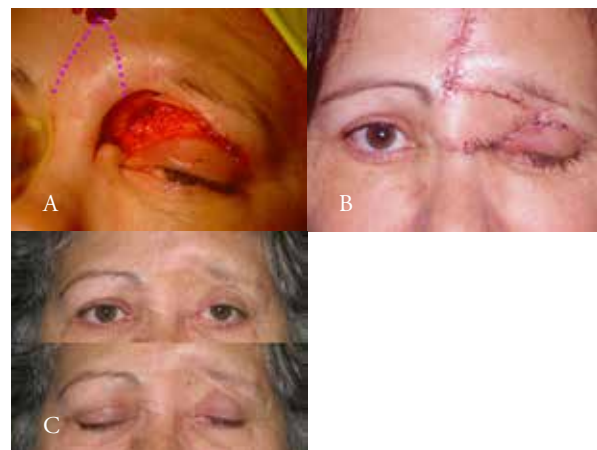

Fig. 13 - Myocutaneous transposition flaps – glabella flap. A: defect caused by tumor excision and design of glabella flap. B: Early post-operative period. C: Outcome after seven years.

3 - More than half the length of the eyelid: Special Techniques

Tarsal-conjunctival graft (between 1/3 and 2/3) and myocutaneous flap

Defects up to two-thirds of the upper eyelid margin can be reconstructed with tarsal conjunctival graft from the contralateral upper eyelid to recreate the posterior lamella, and the anterior lamella can be reconstructed using a myocutaneous advancement, U/VY or bipedicle flap, which provides blood supply to the graft.

Defect edges are gently brought closer to determine the size of graft to harvest. To collect the graft, after 4-0 silk traction stitch on the central portion of the lid margin, the eyelid is everted on a Desmarres retractor to expose the tarsal conjunctival surface. The graft is then marked, maintaining a minimum of 4 mm intact eyelid margin to ensure stability and prevent posterior entropion. The incision is made with a no. 15 blade on the conjunctiva and through the entire tarsus thickness, which causes a spontaneous elevation of the graft that greatly helps its separation from the levator muscle aponeurosis. The remaining base of the graft is cut from the conjunctiva and Müller muscle with straight scissors, leaving about 2 mm of conjunctiva attached to the graft. The donor area heals by secondary intention, sometimes with complete reformation of the tarsus.

The collected tarsoconjunctival graft is placed on

14. Superior Eyelid Reconstruction

the defect site with the conjunctival surface facing the globe and the upper edge of the graft, plus the attached 2 mm of conjunctiva, positioned to reconstruct eyelid margin. The lateral edges of the graft are sutured to the corresponding edges of the defect with 5-0 or 6-0 resorbable sutures.

The anterior lamella is reconstructed with myocutaneous U/VY advancement flap from the upper lateral canthus skin (Fig. 12) or from the remaining upper eyelid skin, if it is redundant. Otherwise, the anterior lamella can be recreated with a bipedicle flap (Fig. 14) and the skinless area created covered with a free skin graft. The excess conjunctiva in the new eyelid margin is folded forward and sutured to the skin of the myocutaneous flap to prevent keratinization at the newly formed eyelid margin, and corneal injury.^{4,5,7}

Bipedicle flap in the inferior eyebrow region

The bipedicle flap between the eyebrow and the pre-septal skin of the upper eyelid is often used for anterior lamella reconstruction. The induced defect can be covered with a total free skin graft (Fig. 14).⁷

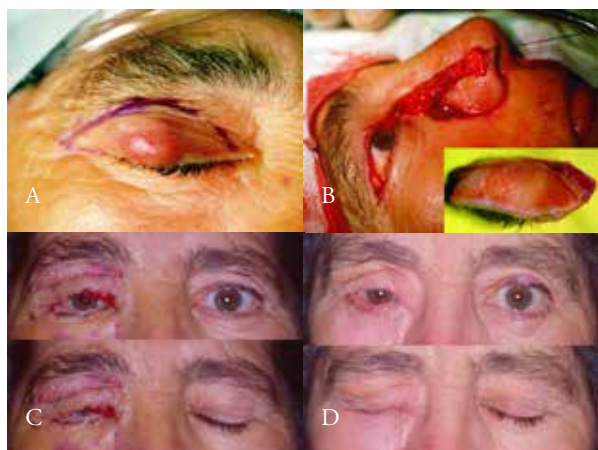

Fig. 14 - Myocutaneous bipedicle flap. A: Relapsed tumor (Merkel cell carcinoma) and indication of the area to excise. B: Excision of the entire upper eyelid and posterior lamella reconstruction with nasal chondro-mucosal flap. C: Early Postoperative. D: Outcome after 1 year.

Cutler-Beard technique:

The Cutler-Beard technique is used to repair large full thickness defects of the upper eyelid, especially central ones. It is a technique with a two-step operating approach and uses the inferior eyelid without altering its margin. A portion of the inferior eyelid below the tarsus is advanced to fill the upper eyelid defect, thus causing closure of palpebral fissure, which is reopened several weeks later. This technique has undergone several modifications but is still indicated when there are no other alternatives. It has advantages over the Abbé-Mustardé technique because no significant reconstruction of the lower eyelid is required. However, it has the drawback of enforcing

eye occlusion for several weeks (which worsens the situation if it is the only functioning eye) and the aesthetic result is not particularly good as the upper eyelid will be missing eyelashes.

The width of the defect in the upper eyelid is determined as the measure of lower eyelid marking, made with two blade incisions vertical to the defect borders. A 4-0 silk suture is placed to traction the lid margin and eye protection is applied. A horizontal skin incision is then made 2 mm below the lower edge of the tarsus (about 5 mm from the eyelid margin) to maintain tarsus integrity and avoid injury to the marginal vascular arcade. The incision must be completed with scissors to full thickness (Fig. 15-A). The conjunctiva is dissected from the orbital septum and lower eyelid retractors, advanced, and sutured with 6-0 or 7-0 absorbable sutures to the limit of the conjunctiva and the upper eyelid levator fascia. A modification of this technique that prevents upper eyelid instability caused by lack of tarsal support, a tarsoconjunctival graft or cartilage can be used to give greater consistency to the new eyelid. Debridement of the skin and orbicularis flap should be performed up to the orbital rim and advanced under the eyelid margin bridge, to be sutured to the skin and upper orbicularis. There is no need to close the skin of the lower eyelid (Fig. 15-B).

After 6-8 weeks, the time required for the tissues to distend, we proceed with the separation of the lids. The lower eyelid is sectioned into bezel form, leaving 2 mm of superior conjunctiva for the new eyelid margin (to be folded on the new margin and sutured to the skin); the rest of the lower eyelid is sutured to the lower edge of the bridge (Fig. 15-C).

Recovery can be quite slow due to the lymphatic edema caused by deep incisions in the lower eyelid. Further small reintervention might be necessary. Ectropion, which can be caused by denervation of the lower eyelid, is corrected with a lateral tarsal strip. Entropion can also arise on the upper eyelid as the levator aponeurosis tends to traction the posterior lamella of the new eyelid more than the previous one. Therefore, a tarsoconjunctival or cartilage graft have more advantages (Fig. 15-D).^{1-6,8}

Abbé-Mustardé technique (flap switch):

It is a reconstruction technique with a single layer of a total thickness rotation flap of the lower eyelid. Like the Cutler-Beard technique, it is a two-stage procedure, with the advantage of partly saving the upper eyelid lashes, with more natural aesthetic results. However, it has several disadvantages: it requires secondary reconstruction of the donor area on the lower lid and, as with many eyelid sharing procedures, it needs ocular occlusion in the weeks between surgeries and there is the potential for

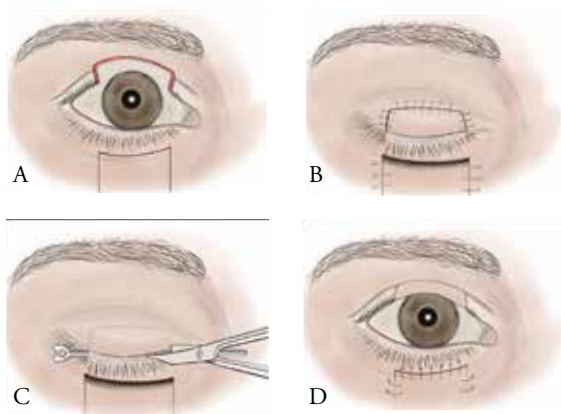


Fig. 15 - Cutler-Beard technique for large defects of the upper eyelid. A: Marking the incisions. B: Suturing the advancement flap under the lower eyelid margin bridge. C: Lid opening after 6-8 weeks. D: Reconstruction of the lower eyelid and final outcome.

corneal injury by flap transposition.

A full thickness horizontal incision is made in the lower eyelid, 5-8 mm from the margin, allowing sufficient height to close the upper lid defect (at least 4 mm, to include the marginal vascular arcade). A vertical cut is made from the free edge to the medial end of the incision, forming a lower eyelid flap that includes the margin with the base on the lateral canthus, where the blood supply and lymphatic drainage take place. The flap is rotated and sutured in layers to the outer edge of the defect in the upper eyelid. The inferior margin flap is sutured in layers to the upper edge of the defect. In the second stage, after 3-6 weeks, the inferior margin of the flap is cut and then completely sutured to the upper eyelid defect, and the lower eyelid is also reconstructed.²⁵

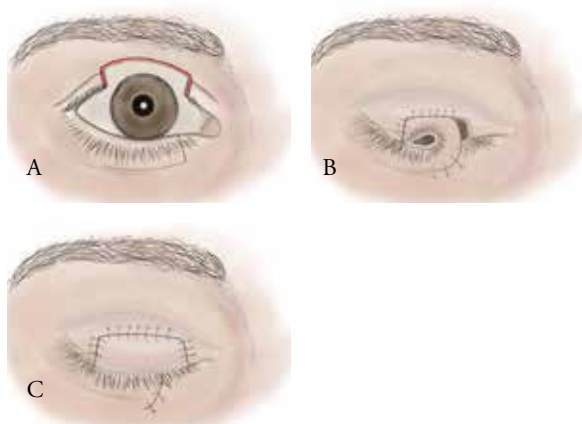


Fig. 16 - Abbé-Mustardé technique. A: Flap designing. B: Rotation and suture. C: Second operative time.

Postoperative care

Postoperative care is the same as for eyelid surgery in general: bandages (that should not be too compressive, so as not to compromise flap irrigation); antibiotic ointment twice a day (to avoid maceration

of the skin), until stitches are removed (usually after a week or more, mainly in special techniques involving flap formation). Where flaps are used, it is best not to apply ice or cold thermal mask to reduce edema because this can compromise circulation. Also, prevent from making effort and performing the Valsalva maneuver. After 4 weeks, and for better cosmetic scar outcome, massage with vitamin E cream is helpful.

Bibliography

1. Nera JA. Techniques in ophthalmic plastic surgery. A personal tutorial. 2010. Chap 12: 325-354; Elsevier Saunders.
2. Toledano Fernández N, Martínez Grau G, Prada Sánchez C, Sanz López A, Medel Jiménez R, Blanco Mateos G. Cirugía palpebral y periocular. Ponencia oficial de la Sociedad Española de Oftalmología. 2009. Chap 39: Reconstrucción palpebral de defectos de espesor total: 413-430. Chap 40: Reconstrucción de defectos de espesor parcial y de la lámina anterior del párpado y perioculares: 431-448. Ed S.E.O.
3. Krishnamurthy A, Vaidhyanathan A. 'Switch Flap' for full thickness upper eyelid reconstruction. J Cutan Aesthet Surg. 2011 May-Aug; 4(2): 148-150.
4. Tse DT. Color atlas of oculoplastic surgery. 2nd Ed. Philadelphia: Lippincott Williams & Wilkins. 2011.
5. Collin JRO. A manual of systematic eyelid surgery. 3rd Ed. United Kingdom: Elsevier. 2006.
6. Gladstone GJ, Black EH, Myint S, Brazzo BG. Oculoplastic surgery atlas: eyelid disorders. New York. Springer-Verlag. 2002.
7. Harris GJ. Atlas of oculo-facial reconstruction. Principles and techniques for the repair of periocular defects. U.S.A. Williams & Wilkins. 2009.
8. Actis AG, Actis G. Reconstruction of the upper eyelid with flaps and free grafts after excision of Basal Cell Carcinoma. Case Rep Ophthalmol. 2011;2:347-353.
9. Rahmi D, Mehmet B, Ceyda B, Sibel O. Management of the large upper eyelid defects with Cutler-Beard flap. J Ophthalmol. 2014;2014:424567.
10. Adenis JB, Morax S. Rapport de la Société Française d'Ophtalmologie, Pathologie orbito-palpébrale. Paris: Masson. 1998.
11. Bowman PH, Fosko SW, Hartstein ME. Periocular Reconstruction. Seminars in Cutaneous Medicine and Surgery, Vol 22, No 4 (December), 2003: pp 263-272.
12. Melo Cardoso A, Goulão J, Cardoso J, Marques N, Miranda A, Pereira M, Campos N. Reconstrução da pálpebra superior com retalho de Cutler-Beard modificado. 2014. Oftalmologia - Vol. 38: pp.53-60

15. Inferior Eyelid Reconstruction

Filipa Ponces

The need to reconstruct the eyelid is most often related to trauma situations, defects after tumor excision or congenital anomalies. The basic aims of eyelid reconstruction are to restore eyelid anatomy, obtain adequate motility to avoid lagophthalmus and create the best cosmetic result. Small and medium superficial defects aren't usually difficult to repair so the aesthetic component should be emphasized. How well a surgical scar is hidden depends on three factors: the tension on the wound; the quality of the tissue used to close the defect, and the placement of the skin incisions. The periocular region is fortunate because the surrounding tissues have good mobility, thus allowing sutures without tension and better healing. To minimize tension on the suture, the cutaneous incisions should be made parallel to relaxed skin tension lines (RSTLs). These lines often correspond to natural wrinkles, and perpendicular to them are the areas with maximum extensibility, which means that a fusiform defect along an RSTL will be sutured with less tension and the healing process will result in an optimal scar. Finally, the quality of the tissue chosen to hide a defect is very important. A good cosmetic result is more likely if the skin used matches the colour and thickness of the skin of the defect to attenuate the transition between the new skin and the surrounding skin. For this reason direct closure or skin flaps from the neighbouring area to repair a defect are aesthetically ideal.

Conventionally, the inferior eyelid is divided into the anterior lamella, composed of skin and orbicular muscle, and posterior lamella, with tarsus and conjunctiva, and its reconstruction is always a challenge due to its anatomical complexity. The choice of surgical technique to reconstruct inferior eyelid defects will depend on factors like the extent and depth of the defect, that is, on whether it is a partial thickness defect involving only skin and muscle or a full thickness defect from the skin to the conjunctiva, affecting the eyelid margin.

Many surgical techniques can be used to reconstruct the eyelids and each surgeon should define a plan to reconstruct a defect based on their experience and

preferred surgical technique.

Basic rules to reconstruct the eyelid:

- a) Approach the borders of the defect under moderate tension to assess the real dimension of the horizontal defect to reconstruct.
- b) Assess which lamella is missing and reconstruct it with tissues with similar characteristics.
- c) Defects that compromise both lamellae should be reconstructed with a combination of graft-flap or flap-flap to ensure adequate vascular supply.
- d) The posterior surface of the eyelid should be smooth and soft and follow the globe curvature.
- e) The eyelid margin should be regular and stable.
- f) Avoid vertical tension on the eyelid; it favours lid retraction.
- g) Provide good canthal fixation.
- h) Use suspension suture (Frost suture) to counteract the downward tension on the lid margin during healing.

A) PARTIAL THICKNESS EYELID DEFECTS

The surgical method to be used depends on the extent of the partial defect and the options are:

- 1) second intention healing,
- 2) direct or primary closure,
- 3) skin flap,
- 4) full thickness skin graft (FTSG).

A.1) SECOND INTENTION HEALING

In small and superficial defects of the inferior eyelid, and mostly in the inner canthus, this method can be a good option, although there is a risk of eyelid retraction and ectropion (Fig. 1,2,3,4,5)

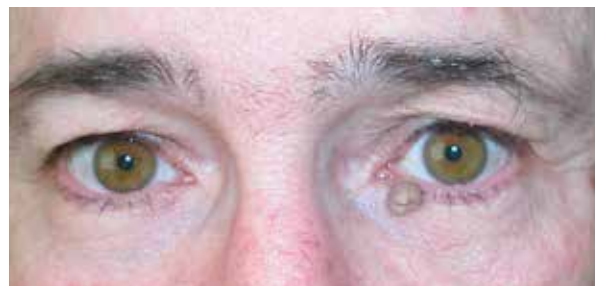

Fig. 1- Inferior eyelid papilloma.

15. Inferior Eyelid Reconstruction

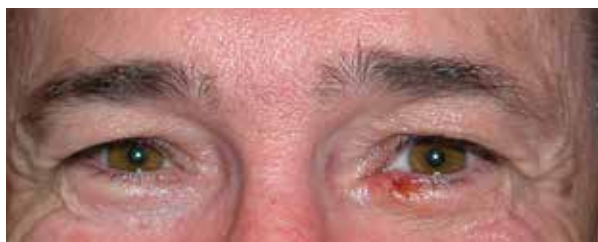

Fig. 2 – Simple excision with cautery.

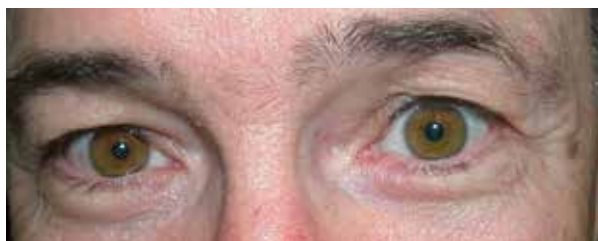

Fig. 3 one month after second intention healing.

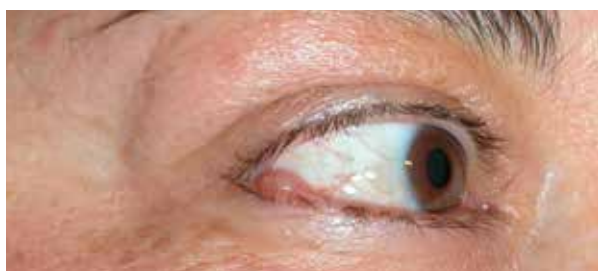

Fig. 4 - Melanocytic nevus in the inferior eyelid margin.

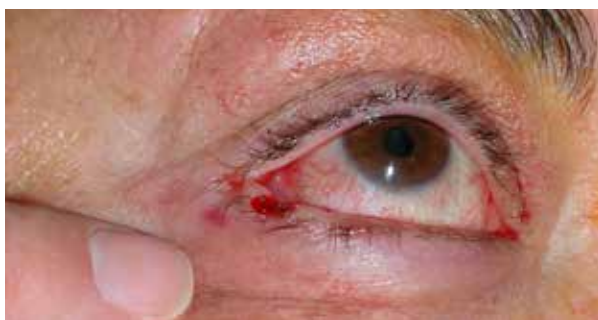

Fig. 5 – Shaving with cautery of the lesion.

A.2) DIRECT OR PRIMARY CLOSURE

Direct closure refers to direct apposition, side by side, of the borders of the defect. It is the preferred method to repair small defects, although the borders of the wound might have to be undermined to suture without tension. When suturing a circular defect, the apposition of the borders in the central area will cause the skin to pucker at each end of the suture, also known as dog ears. These can be prevented if, when planning a skin lesion excision, the area to be excised is elliptical or has a fusiform shape. As a rule, the length of an ellipse should be roughly three times its maximal width and should be marked over or parallel to a wrinkle or an RSLT. When closing an elliptical defect the surrounding tissue moves perpendicularly to the major axis of the ellipse, which means that if the ellipse is drawn parallel to the eyelid the

tension increases in the margin, thereby predisposing to ectropion (Fig. 6,7).

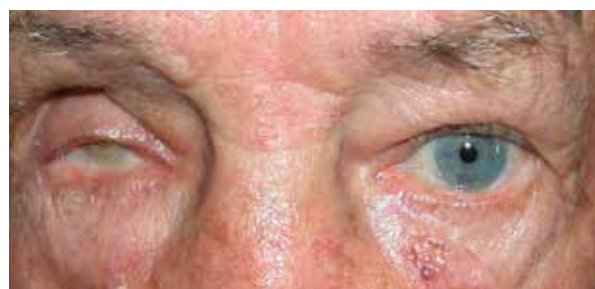

Fig. 6 – Basocellular carcinoma of the inferior eyelid.

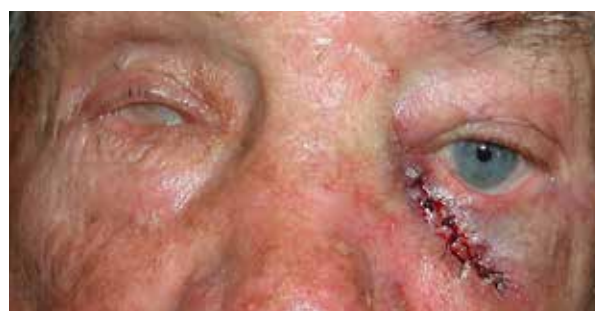

Fig. 7 – Direct suture after tumour excision with ectropion of the inferior eyelid.

To prevent this, the elliptical defect in inferior eyelid must be perpendicular to the eyelid margin so that the tension forces exercised by the suture are parallel to the margin. However, to obtain a better cosmetic result, the ellipse can be marked within a wrinkle (which is often parallel to the margin) and the tip of the fusiform defect is curved as it approaches the eyelid margin to end up perpendicular to it. In older people with redundant skin and relatively small defects it is often possible to make incisions parallel to the eyelid margin without major problems (Fig 8,9,10,11,12,13).

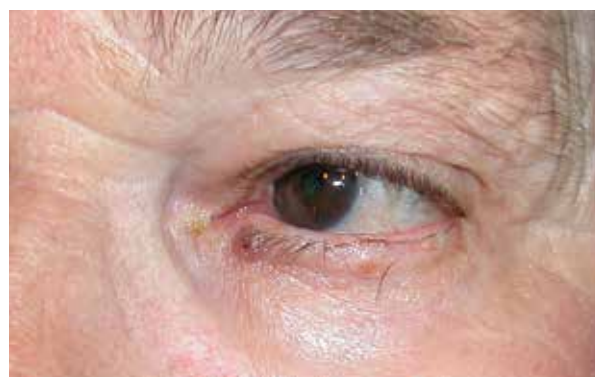

Fig. 8 – Melanocytic nevus in the inferior eyelid.

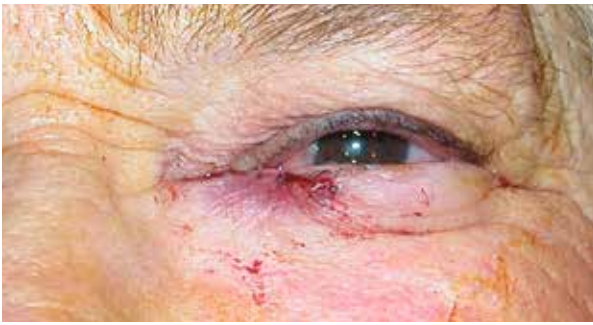

Fig. 9 – Elliptical excision with direct suture.

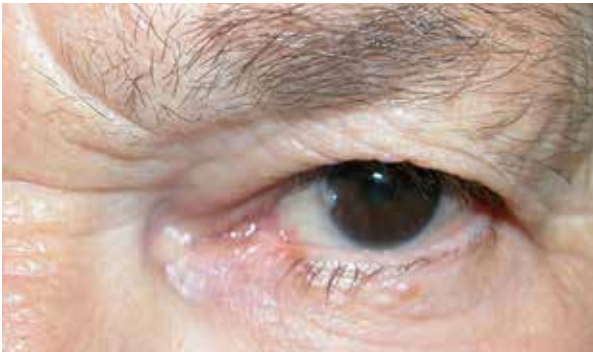


Fig. 10 – One month after excision.

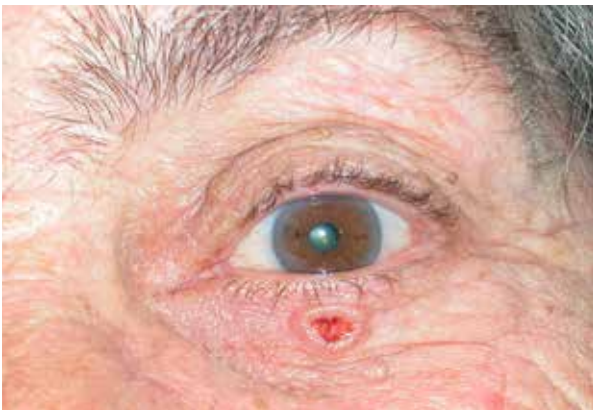


Fig. 11 – Basal cell carcinoma of the inferior left eyelid.

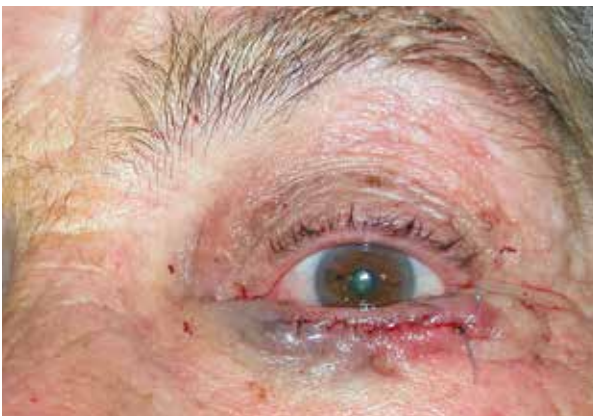

Fig. 12 – Elliptical excision with direct suture.

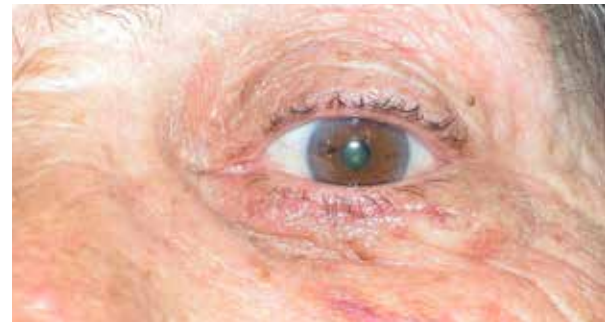


Fig. 13 – One month after excision.

In deep defects, the deeper layers must first be closed with single absorbable sutures to give support to the skin that is going to repair the defect,

A.3) SKIN FLAP

A skin flap is a portion of skin obtained from a surrounding area with a vascular supply. Therefore, not only is there less chance of it undergoing ischemic necrosis and contraction than a skin graft, but it also offers a better aesthetic result because it usually matches the colour and the texture of the skin that is missing.

In deeper defects a myocutaneous flap can be useful. It is a thicker flap with a layer of muscle. When planning to repair a defect with a flap, the surgeon must assess the surrounding areas that have greater laxity and use them to get the flap. In the periocular region those reservoirs of tissue are more pronounced in older people and can be found in the glabella, the upper eyelid, and temporal and malar regions. A flap in the lower eyelid should be inferiorly based to avoid chronic lymphedema and positioned so that, when sutured, the traction forces are exerted horizontally.

SKIN FLAP TYPES

ADVANCEMENT FLAPS

- Rectangular plasty or U-plasty – This flap is created by drawing and incising parallel lines from one side of the defect, dissecting and advancing the skin along its major axis to cover the defect (Fig.14).



Fig. 14 – From one side of the defect two parallel incisions are made and the skin is dissected and advanced.

15. Inferior Eyelid Reconstruction

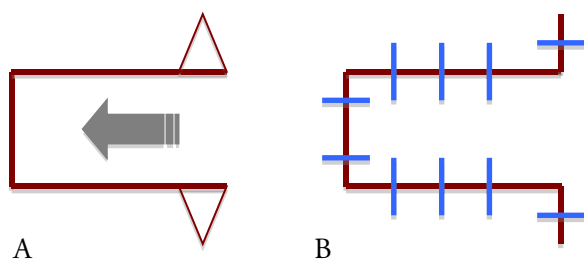


Fig. 15 – a) At the base of the flap two cones of redundant skin appear (dog ears). b) These should be excised as Burow triangles. The final suture has a rectangular shape.

At the skin surrounding the base of the flap, the traction exerted causes two cones (dog ears) of redundant skin appear that may be excised (Burow's triangle) to allow the perfect advancement of the skin (Fig. 15). In the face, the length of an advancement flap should be at most 3 or 4 times the width of the pedicle. The flap should be thick enough to cover the defect, and consist of the subdermal layer with its vascular supply. Its thickness should increase towards the pedicle. To improve flap mobility and distribute the tension forces that occur during healing it is useful to undermine the borders of the defect. When repairing the lower lid, the zygomatic tissues must always be dissected above the subcutaneous fat layer to avoid damaging the motor innervation. This must be accompanied by a balanced haemostasis to prevent hematoma formation and ensure flap vascular supply.

- **H-plasty or bilateral rectangular advancement flap** – two parallel lines perpendicular to the border of the defect are drawn on each side of the defect to mark out 2 rectangles. These are dissected and brought closer to cover the defect, defining an H. It is recommended in zones with horizontal wrinkles like the frontal region and supraciliary zone, but it can be used in the lower eyelid with more curved incisions to fit the RT-SLs or pre-existing wrinkles (Fig. 16,17,18).

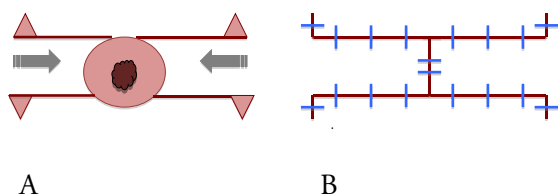


Fig. 16 – a) Two parallel incisions are made from each side of the defect. The tissues underneath are dissected and the two rectangular flaps are brought together. At the base of each flap two cones of redundant skin (dog ears) appear and these can be excised (Burow triangles). b) The final suture has an H shape.

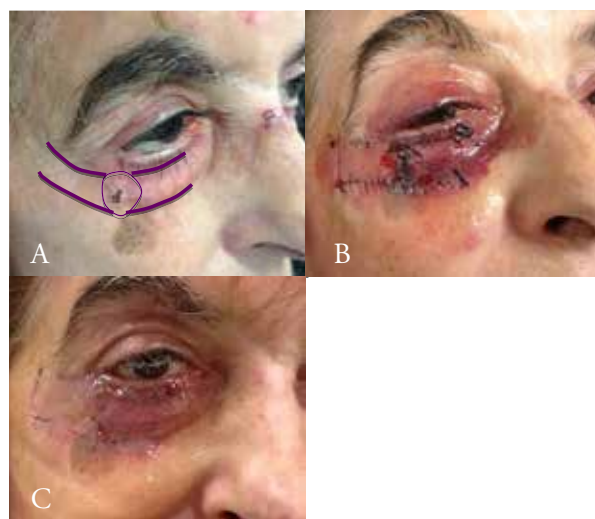

Fig. 17 – a) Drawing of the area to excise and the H-plasty flap to reconstruct the defect. b) Flap sutured 3 days after the surgery. c) After suture removal 1 week later.

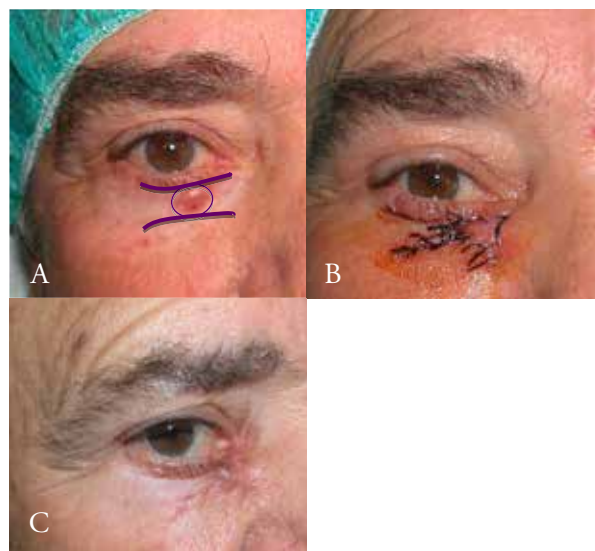


Fig.18 – a) A nodular basal cell carcinoma in the inferior eyelid with the planned excision and H-plasty reconstruction. b) One week post tumor excision. c) One month later.

- **T Plasty** – It is a bilateral advancement flap that turns a triangular defect, A or V, or an oval defect, into a T. A circular defect must be drawn into a V or A shape with a length twice the diameter of the defect, and two opposed incisions must be made at the base of the defect, the same length as the diameter of the defect (Fig. 19). The flaps must be widely dissected to allow good mobility and tension-free suture. During the repair process it is usual to notice some skin redundancy along the base of the flaps that can be eliminated by excising a Burow's triangle or distributing the excess tissue in the suture, following the rule of halves.

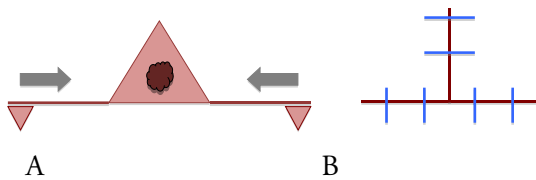


Fig. 19 – a) From the base of a triangular defect two horizontal incisions the length of one diameter of the defect are made. The flaps are dissected and brought together. A skin redundancy may appear at the base of the flaps. This can be eliminated by excising Burow triangles or distributing the excess tissue in the suture. b) The final suture has a T shape.

ROTATION FLAPS

The design of a classical rotation flap utilizes a curvilinear incision along an arc adjacent to a triangular defect. This semicircular flap rotates around a pivotal point to cover the defect. Similar to advancement flaps, the secondary motion of the flap causes a dog ear at the base of the flap, at a pivotal restriction point. It can be excised anywhere along the arc of the flap. When rotation occurs there is a functional loss of height of the flap and as the primary defect is closed a secondary defect develops. To prevent this phenomenon the height of the leading edge of the flap should be longer than the height of the defect (Fig. 20). The arc of the flap should be large enough so that on rotation the edge of the flap extends beyond the distal end of the defect (Fig. 20). Undermining the borders of the defect, the incision lines and the pivotal restriction point facilitates the suture of the defect without tension. A back cut may be made at the end of the flap to facilitate its rotation, but this shortens the base of the flap and may compromise its vascular supply. This is a useful flap to close medial eyelid defects because it can mobilize large reservoirs of loose tissue in the cheek. Inferior eyelid defects can also be closed with rotational flaps that recruit tissue from the temple (Fig. 21).

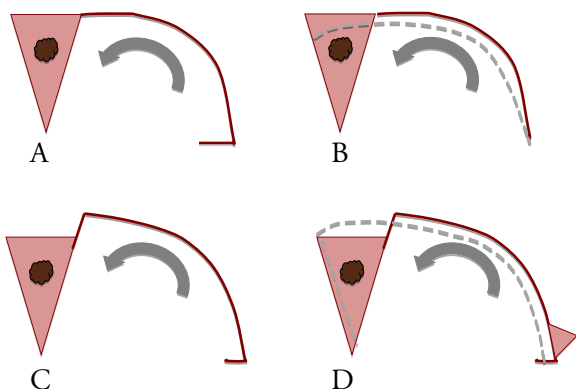


Fig. 20 – a) A curvilinear incision is made adjacent to a triangular defect. The tissue is dissected and rotated to cover the defect. At the base of the defect a horizontal incision may be done to facilitate rotation. b) When the rotation occurs there is a functional loss of the height of the flap. c,d) To prevent this, the height of the semi-circular curve should be greater than the height of the defect. A dog ear may appear at the base of the flap; it can be disguised in the suture or excised as a Burow's triangle.

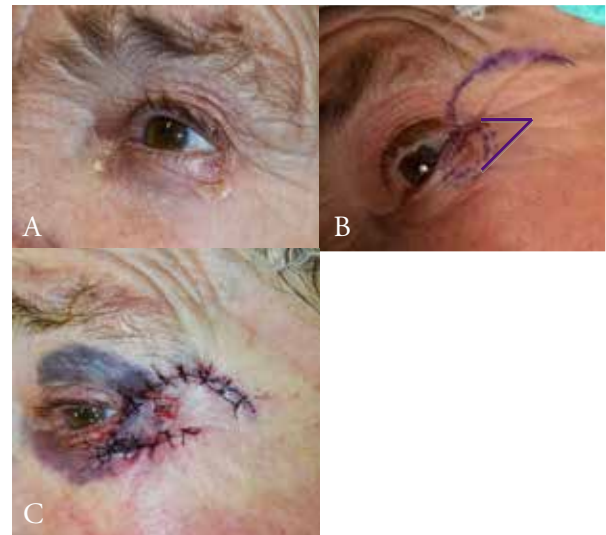


Fig 21 – a) Basal cell carcinoma of the inferior eyelid. b) Drawing of the limits of the area to excise and of the rotational flap. c) The flap sutured with 6/0 silk. In the middle of the flap there is an anchorage suture to the deeper tissues.

- **O-Z flap** - is created by designing similar opposing and inverted rotational flaps on each side of a circular defect. As in advancement flaps, dog ears will appear near the pivotal restriction points of each rotation flap and they should be excised to achieve adequate flap contour. This kind of flap is used in inferior eyelid defects.

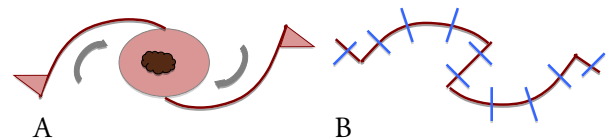


Fig. 22 – a) Two inverted and opposed rotational flaps are designed on each side of the round defect. The skin is dissected and the flaps are brought together. b) A dog ear can appear at the base of the flaps. It might have to be excised for the contour to adapt b). The final suture has a Z shape.

TRANSPOSITION FLAPS

Transposition flap is a flap that borrows skin laxity from an adjacent area in order to fill a defect in an area with little skin laxity. During the movement of the flap it is lifted over a segment of good skin and transposed into place. Transposition flaps are used when there is insufficient laxity in the immediate surrounding area of closure or when tension vectors need to be redirected. They are very useful to reconstruct lateral and medial canthi and cheek.

- **Limberg/rhomboid flap** - convert a primary defect in a four-sided parallelogram with sides of equal length and opposed angles of 60° and 120°. Draw a line from the angle of 120° of the same length as

15. Inferior Eyelid Reconstruction

each side of the rhombus and from its free end draw a parallel line and of the same length to the nearest side of the rhombus (Limberg/rhomboid flap). Incise the created rhombus, lift it and transpose it over the defect. The tip angle of the flap is 60°. The tension vector will be directed to the closure of the secondary defect, which is 90° from the primary defect closing tension vector (Fig 23,24).

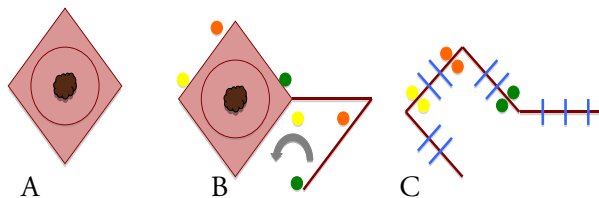


Fig. 23 –Limberg rhomboid flap. a) A round defect is turned into rhomboid defect with opposed angles of 60° and 120°. b) A line of the same length as the side of the rhombus is drawn from one of the 120° angles, and from the free end of this a second line is drawn parallel to one side of the rhombus. The skin is dissected. c) The flap is transposed to align the sides of the flap with the sides of the defect (colours matched).

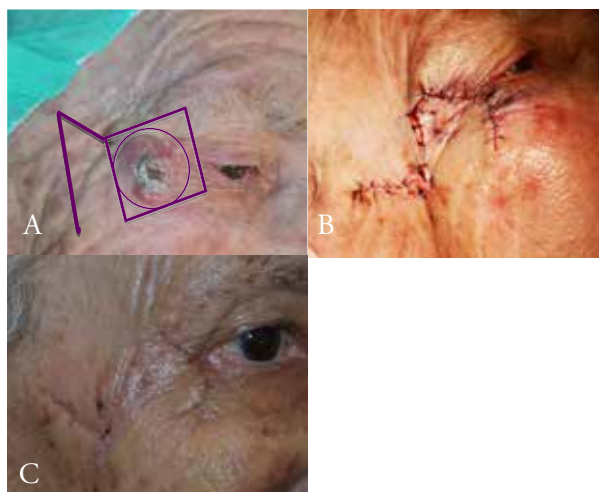


Fig 24 – a) A basal cell carcinoma of the malar region. A transposition flap is designed to repair the rhomboid defect. b) The transposition rhomboid flap is sutured. c) After removing the sutures, one week after surgery.

- **Dufourmental flap** – a variant of the anterior flap, it is designed by drawing a line bisecting the angle formed by the extension of one side of the rhombus and the first line drawn in a classic rhomboid flap (which extends from the short axis of the rhombus) with the length of the side of the rhombus. The second line begins at the free end of the first line and is parallel to the long axis of the rhomboid (Fig. 25).

A.4) FREE FULL-THICKNESS SKIN GRAFT (FTSG)

Free full-thickness grafts are composed of epidermis and full thickness of dermis. They exhibit minimal wound contraction and require a rich blood supply,

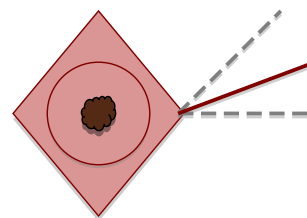


Fig 25 – Dufourmental flap.

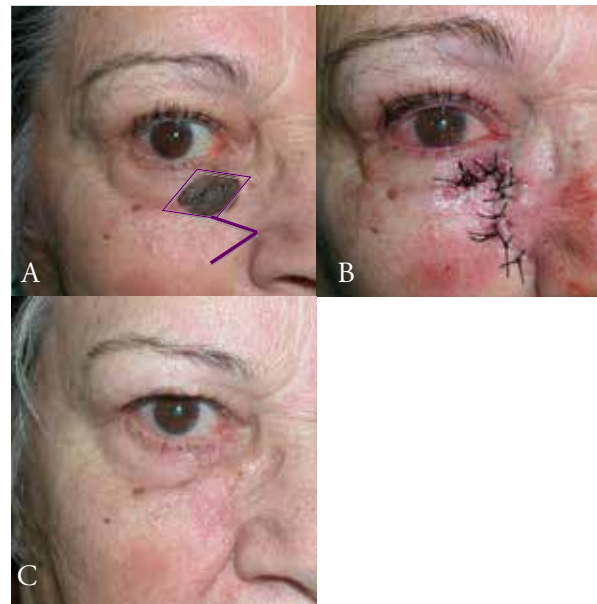


Fig. 26 – a) Seborrheic keratosis in the inferior eyelid. Area to excise marked as a rhombus and Dufourmental flap designed to reconstruct the skin defect. b) Flap sutured. c) One month after lesion excision.

which can be compromised in diabetics, cigarette smokers and patients with nutritional and vitamin deficiencies. Bleeding disorders, uncontrolled hypertension, antiplatelet and anticoagulant drugs predispose to bleeding or clot formation and graft failure. Matching the skin and thickness of the donor and recipient site is essential for a good result. Whenever possible, a regional approach should be used to repair defects in the same region. For example, defects in the lower eyelid can be repaired with upper eyelid skin grafts (Fig. 27). When there is a lack of skin near the defect and thin skin is needed, it is possible to harvest skin from the post-auricular region (Fig. 28). If thicker skin is needed, a graft should be harvested from pre-auricular, supraclavicular cervical or upper inner arm skin.

The healing process of a skin graft occurs as follows: the first 24h is the ischemic period (Fig. 28b), where the graft becomes pale, after 48 to 72h vessel anastomoses begin to form, and normal circulation is restored after 4 to 7 days. Patients should be advised to not to smoke or engage in vigorous exercise and any activity that may elevate their blood pressure.

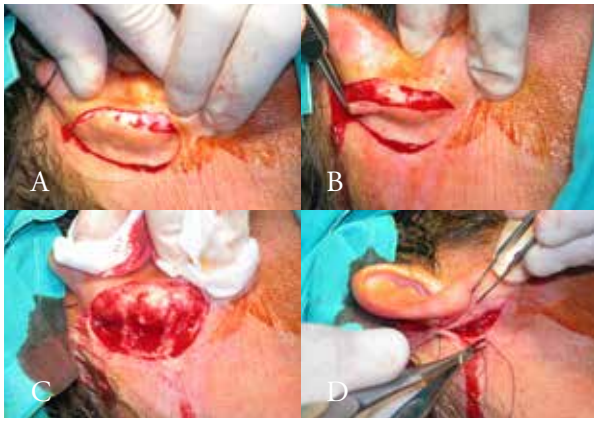


Fig. 27 - a) Incision of the retroauricular skin. b) Dissection of the tissue underneath the skin. c) Retroauricular defect after removing the graft. d) Direct suture with 4/0 silk.

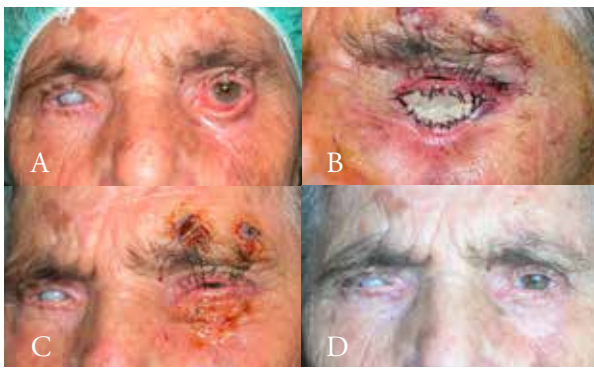


Fig. 28 -a) Cicatricial ectropion of the left inferior eyelid post excision of a skin tumour. b) 3 days after a retroauricular full-thickness skin graft (ischemic phase) with Frost sutures. c) 1 week post surgery after suture removal. d) 3 months after surgery.

B) FULL-THICKNESS EYELID DEFECTS

To reconstruct these defects, at least one of the lamellae should have a natural vascular supply, which means that if one is a graft the other must be a flap.

B.1) Up to 20 % of the length of the eyelid in younger individuals or up to 30 % in elder individuals – usually the defect can be repaired with a direct primary closure or direct closure after a lateral canthotomy or cantholysis.

- **Direct primary closure:** place a 6/0 silk suture through the gray line on both sides of the defect margin and leave the suture with long ends. Place the next suture through the eyelash line. Suture the tarsal plate with two 6/0 absorbable sutures avoiding the conjunctiva. Tie the gray line suture. Suture skin and muscle with 6/0 silk sutures. Use the eyelash suture and the first skin suture to tie the long ends of the gray line suture (Fig. 29).
- **Canthotomy and cantholysis** – make a horizontal cut 5 mm long from the lateral canthus to the orbital rim (canthotomy)(Fig. 30b). Pull the lid to feel the traction of the inferior limb of the lateral canthal tendon, separate it from the orbicularis muscle and the conjunctiva and cut it completely

with scissors (cantholysis). The canthotomy may heal by second intention or may be sutured after the direct primary closure of the defect. Start with a 6/0 absorbable suture that runs through the inferior tarsus at the new external canthus and pass it through the correspondent position at the superior tarsus. After that suture the skin with 6/0 silk or 6/0 monofilament.

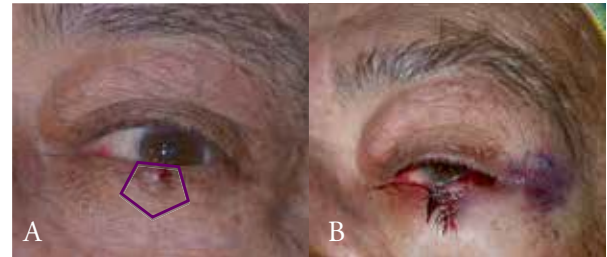


Fig. 29 – a) Small basal cell carcinoma in left inferior eyelid (defect after excision involving 30% of the length of the eyelid). b) Full thickness direct 6/0 silk suture with one suture in the gray line, another in the lash line and multiple skin and muscle sutures. Note that the gray line suture is tied in the knot of the lash line sutures. The tarsus is sutured with two 6/0 absorbable sutures.

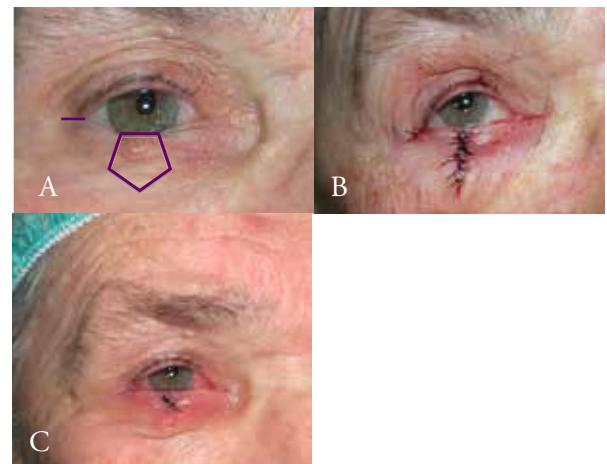


Fig. 30 – a) Small basal cell carcinoma (defect after excision approximately 30 % of the eyelid length). b) Full thickness direct suture with canthotomy. The canthus might repair by second intention healing or it can be sutured. In this case an absorbable 6/0 suture is placed from the superior canthal tendon to the subcutaneous tissue of the lateral end of the inferior lid and the skin is closed with a 6/0 silk suture. c) 1 week after skin and lash line suture removal. The gray line suture is removed 2 weeks after surgery.

B.2) 25 % to 50 % of the length of the eyelid margin - the defect can be repaired with a semicircular Tenzel's skin flap or with a graft for the posterior lamella and an advancement skin flap if there is enough skin in the inferior eyelid.

- **Semicircular Tenzel's flap** – is a semi-circular flap that is marked with a curved line beginning at the lateral canthus, as a continuation of the eyelid to be reconstructed, defining a semicircle with

15. Inferior Eyelid Reconstruction

the same diameter as the length of the defect and with the concavity oriented inferiorly. The superior limit of the flap should not cross the eyebrow. This flap does not reconstruct the posterior lamella. Dissect the flap deep to the orbicularis muscle and proceed with cantholysis of the inferior limb of external canthal tendon (ECT). Close the lower eyelid defect in the usual way. The deeper tissue of the flap should be anchored to the periosteum of the lateral orbital rim with a 4/0 absorbable suture to create a new canthus. Suture the skin with a 6/0 non-absorbable suture (Fig. 32,33).

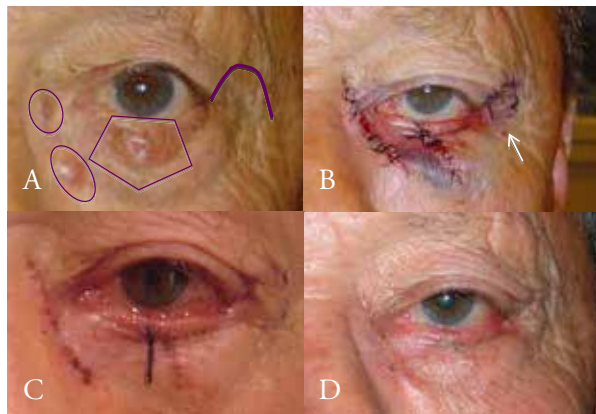


Fig. 31 – a) Multiple basal cell carcinomas of the inferior eyelid. The expected defect post excision of the biggest tumour is about 50 % of the length of the eyelid margin. Tenzel's skin flap designed with the concavity facing down. b) Sutures after excision of the tumors. Flap anchored to the periosteum with a suture attached to a small fragment of a silicon tube (arrow). c) 7 days post-surgery, after removal of the skin sutures. The suture of the gray line remains for 2 weeks. d) 2 weeks post-surgery.

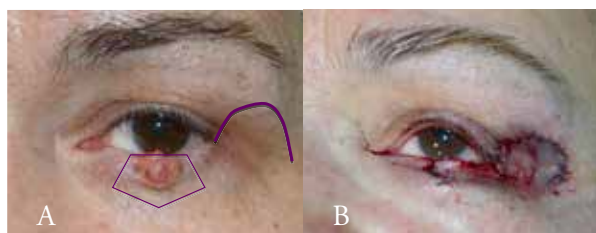


Fig. 32 – a) Voluminous basal cell carcinoma in the inferior eyelid. b) The defect is repaired with a Tenzel's skin flap.

B.3) Over 50 % of the total length of the eyelid – the options to reconstruct such a defect are as follows:

- a) Posterior lamella – Flap
 - Tarsconjunctival Hughes flap
- Anterior lamella – Graft
 - Full-thickness skin graft (Fig.27)
- **Tarsconjunctival Hughes flap** – A strip of upper tarsal plate on a pedicle of conjunctiva is used to reconstruct the posterior lamella of the lower eyelid. It is indicated in central defects with intact canthi. Pass a traction suture through the gray line of the

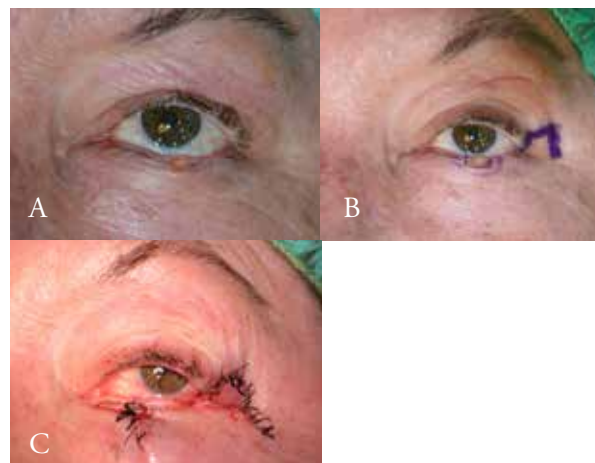

Fig. 33- a) A nodular basal cell carcinoma in the left inferior eyelid. b) drawing of the area to excise and the Tenzel's flap to reconstruct the defect. c) at the end of the surgery with a full thickness eyelid suture and the suture of the flap after displacing the skin to reconstruct the defect.

upper lid and evert it with a Desmarres retractor. Mark a parallel line 4 mm from the border with the length of the defect. From the ends of that line draw vertical lines to the superior border of the tarsus. Cut through those marks, dissect the tarsus from the orbicular and continue to dissect the Muller's muscle from the conjunctiva about 10 mm superiorly. Extend the tarsal cuts for 3-4 mm into the conjunctiva to allow adequate inferior displacement of the flap. Start to suture the ends of the superior border of the tarsus to the margins of the defect in the lower lid. Suture the inferior border of the flap to the retractor-conjunctiva complex in the lower eyelid with 6/0 absorbable sutures. Cover the flap with an FTSG, suture it with 6/0 silk or monofilament, leaving some long ends to tie a bolster to press the skin graft against the flap. Remove the skin sutures one week later and 2 or 3 weeks later divide the pedicle.

- b) Posterior lamella - Graft
 - Tarsconjunctival graft
 - Hard palate graft
 - Oral mucosa

Anterior lamella - Flap

- Transposition flap from the superior eyelid (Tripier's flap)(Fig. 35,36)
- Nasojugal transposition flap (Tessier's flap) (fig.37)
- Mustardé rotation flap
- Advancement flap from inferior eyelid (skin laxity)

- **Tarsconjunctival graft** (fig. 34) Put a traction suture with a 4/0 silk in the margin of the superior eyelid and with the aid of a Desmarres retractor

evert the eyelid. Mark the limits of the graft on the surface of the tarsus with a dermatographic pencil without forgetting that it is necessary to keep the 4 mm of the tarsus adjacent to the eyelid margin (to avoid eversion of the eyelid). The length of the graft can be up to 16 mm in length. Dissect it from the insertions of the elevator aponeurosis and from the insertions of the Muller muscle. Cut the graft at the superior border of the tarsus and apply it to the defect, suturing it to the rest of the tarsus and retractor-conjunctiva complex in the inferior fornix with interrupted 6/0 resorbable sutures. The graft should have reasonable tension or else there is a risk of an ectropion appearing. Leave the defect in the superior eyelid tarsus without suturing. It will repair by second intention healing. Cover the graft with a skin flap. If there is skin laxity, an advancement flap usually suffices. At the eyelid margin, suture the skin to the flap with 6/0 silk leaving 1 mm of the graft above the border of the skin to prevent future corneal erosion from the skin hair (Fig. 35 and 36).

- **Transposition flap from the superior eyelid** (Tripier's flap) – this flap is used to reconstruct narrow defects in the inferior lid that extend to the lateral canthus and when there is lax skin available in the upper lid. The flap should be a little longer than the defect.

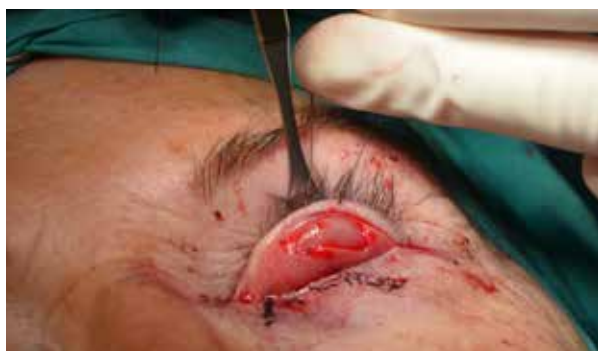

Fig 34 – 4/0 silk traction suture in the eyelid margin. Eyelid everted with a Desmarres retractor. Defect in the tarsus after harvesting the tarsoconjunctival graft.

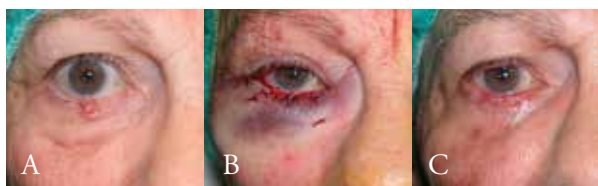

Fig. 35 – a) Basal cell carcinoma of the inferior eyelid. b) Reconstruction of the posterior lamella with a tarsoconjunctival graft from the superior eyelid and the anterior lamella with an advancement flap of the inferior eyelid. Note the graft border above the skin border to prevent corneal erosion by the skin hairs. c) 1 month after surgery.

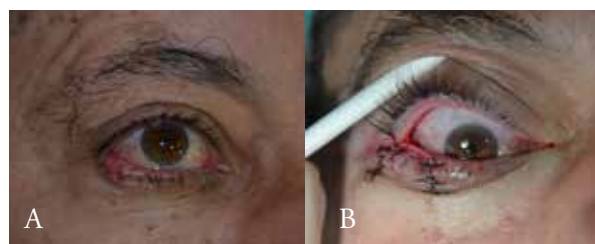

Fig 36 – a) Basal cell carcinoma of the inferior eyelid. b) Reconstruction with a tarsoconjunctival graft from the upper lid and with an advancement skin flap of the inferior eyelid.

Mark the superior lid crease (inferior border of the flap) and, above this, mark a second line and extend them medially, tapering as for a blepharoplasty (note that the residual skin must be between 15 and 20 mm vertically) (Fig. 37b) and laterally to create the pedicle of the flap.

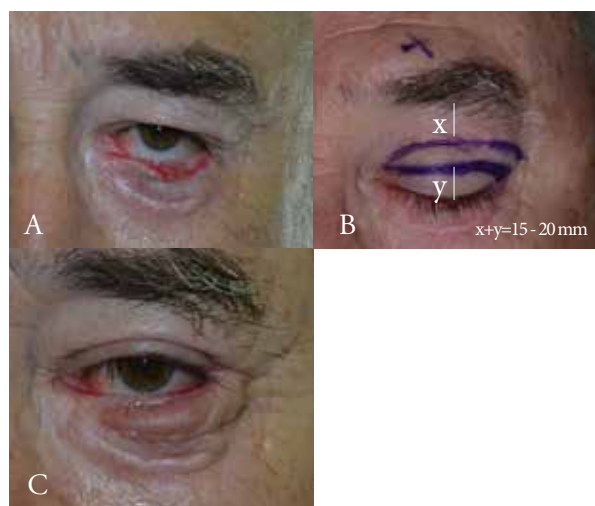


Fig. 37– a) Ectropion and deficit of the temporal half of the eyelid post excision of a basal cell carcinoma of inferior eyelid followed by partial reconstruction with a skin graft (lower part of the eyelid). b) Drawing of the transposition flap from the superior eyelid. The posterior lamella was reconstructed after harvesting a tarsoconjunctival graft from the superior eyelid. c) 6 weeks after surgery with some thickening of the flap.

Dissect the skin and muscle and transpose it to the lower lid. Suture the skin of the flap and the donor site with interrupted 6/0 silk or monofilament (Fig. 37 b and c and Fig 38). Remove the sutures one week later.

- **Nasojugal transposition flap (Tessier's flap)** - this flap is used to repair medial defects of the lower lid. Draw two lines of the desired length vertical and parallel to each other, beginning in the area just below the medial canthal tendon. Dissect within the fat layer and then transpose it into the defect. Close the secondary defect with 6/0 interrupted sutures. Reconstruct the posterior lamella with a graft and suture it with 6/0 absorbable sutures to the remaining tarsus and

15. Inferior Eyelid Reconstruction

conjunctiva-lower eyelid retractor complex. Trim the flap to fit in the initial defect and suture the skin with 6/0 silk or monofilament-interrupted sutures. The margin of the flap must be closed with a continuous 6/0 suture to the graft used to reconstruct the posterior lamella (Fig. 39).

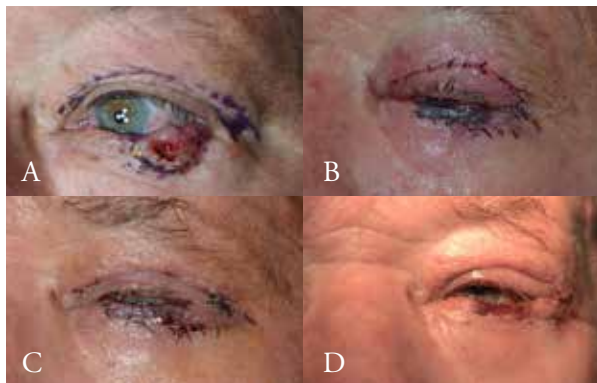


Fig. 38 - Tripier's flap – a) Basal cell carcinoma of the inferior eyelid with the area to excise and the flap to reconstruct the anterior lamella of the defect, drawn in the superior eyelid. The posterior lamella was reconstructed with a tarsoconjunctival graft harvested in the superior lid. b) 3 days after surgery the flap has a dark color at the extremity that may correspond to hemorrhage or necrosis. c) One week after surgery, before removing the skin stitches. d) De-epithelization of the extremity of the flap and second intention healing. e) Discrete ectropion and irregularity of the marginal contour of the eyelid, two months later.

- **Mustardé rotation flap** - This flap is indicated in the reconstruction of large and long vertical defects of the inferior lid. Mark the medial end of the defect as a vertical line. This line should be twice the horizontal length of the defect. From the inferior end of this line draw a second line that should define the lateral border of the tissue to be excised. An inverted triangle is defined by these two lines and corresponds to the total area of the defect to reconstruct. Mark a line from the lateral canthus that curves towards the lateral end of the eyebrow, with convexity facing down. Continue in a gentle curve across the temple skin, down in front of the ear, ending at the level of the ear lobe. Undermine the entire flap in the subcutaneous layer. Reconstruct the posterior lamella of the eyelid with a graft of tarsus and conjunctiva, oral mucosa, hard palate or nasal septal cartilage that is sutured with 6/0 absorbable suture to the remains of the conjunctiva. The graft should be oversized in height to properly reconstruct the lid margin. Place multiple deep sutures between the flap and deep tissues with 4/0 absorbable sutures to stabilize the flap. Place it over the graft and anchor the flap to the medial wall and the lateral orbital rim with 4/0 non-absorbable sutures. Suture the skin with an interrupted 5/0 or 6/0 monofilament suture and close the mucosa to the skin at the lid margin with a continuous 6/0

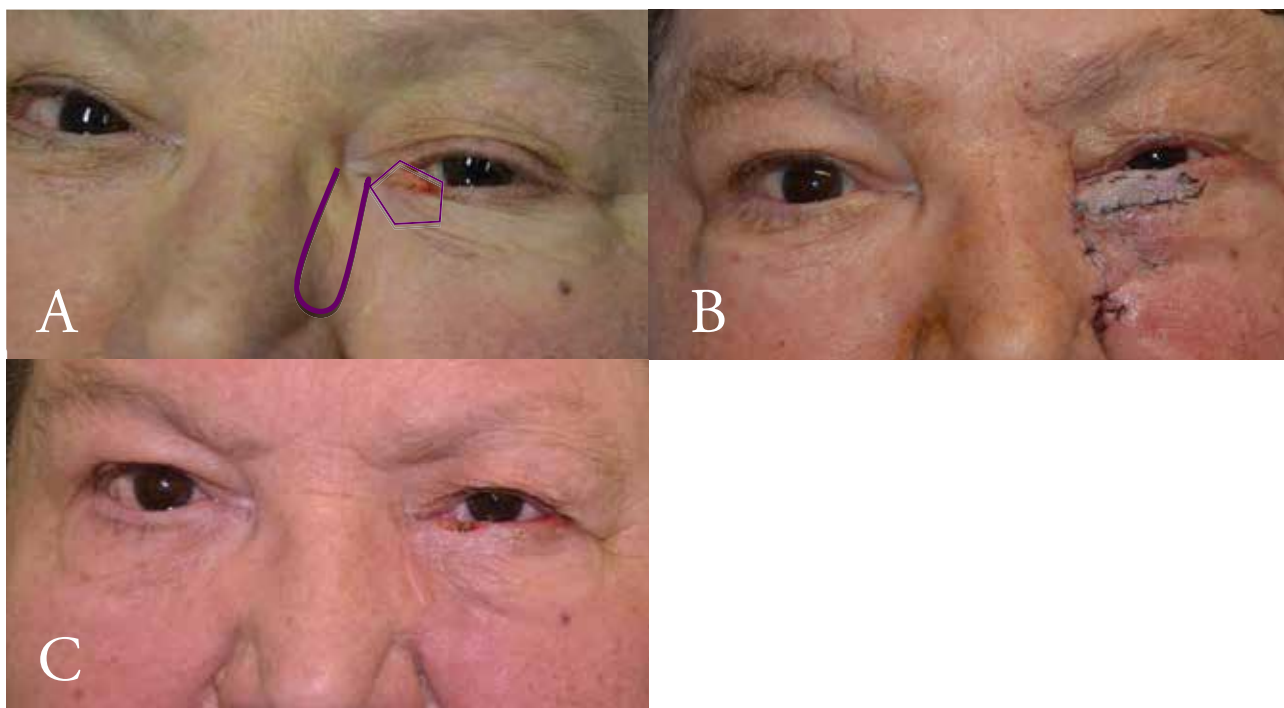


Fig. 39 - a) Basal cell carcinoma in the left inferior eyelid with the nasojugal flap (Tessier's flap) designed to reconstruct the anterior lamella of the defect. The posterior lamella is reconstructed after harvesting a tarsoconjunctival graft from the superior eyelid b) Three days later the flap has a pale colour. c) 3 weeks later with a small area of exposition of the tarsus at the eyelid margin.

silk suture. A drain should be left beneath the lower part of the flap and a pressure dressing must be left for 48 h. Remove the drain after 48 h and the sutures one week later (Fig.40.)

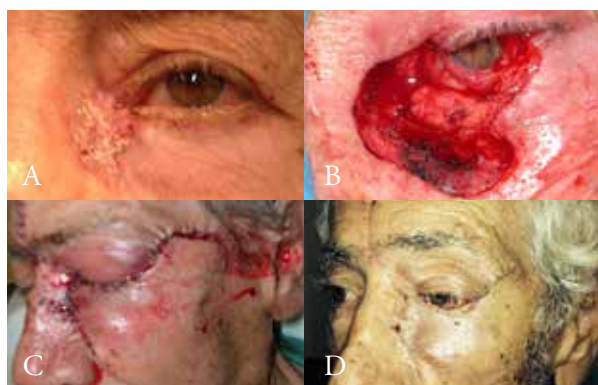

Fig. 40 – a) Basal cell carcinoma of the inner canthus. b) Defect after the excision of the lesion. c) Reconstruction of the inner canthus with a glabellar flap and the inferior eyelid with an oral mucosa graft and a Mustardé rotation flap. d) 1 month after surgery.

Bibliography

1. Bowman PH, Fosko SW, Hartstein ME: Periocular Reconstruction, *Seminars in cutaneous medicine and surgery*, Vol 22 No. 4 (December), 2003: pp 263-272
2. Jewett BS, Shockley WW: Reconstructive option for periocular defects, *Otolaryngologic Clinics of North America*, vol 34 No. 3 June 2001: pp 601-625
3. Lindgren G, Lindblom B, Larko O: Mohs micrographic surgery for basal cell carcinomas on the eyelids and medial canthal area. II Reconstruction and follow-up, *Acta ophthalmol Scand* 2000: 78 430-436
4. Inkster C, Ashworth J, Murdoch JR, Montgomery P, Telfer NR, Leatherbarrow B: Oculoplastic reconstruction following Mohs surgery, *Eye* 1998; 12, 214-218
5. Foster JA, Scheiner AJ, Wide AE, Wallace IB, Greenbaum SS: Intra operative tissue expansion in eyelid reconstruction, *Ophthalmology* vol 105 No. 1, January 1998 170-175
6. Wiggs E: Periocular flaps, *J Dermat Surg Oncol* 1991; 18: 1069-1073
7. Jelks GW, Jelks EB: Prevention of ectropion in reconstruction of facial defects, *otolaryngologic clinics of North America*, vol 34 No. 4 August 2001: 783-788
8. Hintschich C: Periocular plastic surgery, *Dtsch Arztlbl Int* 2010; 107(9): 141-146
9. Moesen I, Paridaens D, A technique for reconstruction of lower eyelid marginal defects, *Br J Ophthalmology* 2007;91:1695-1697
10. Hayano SM, Whipple KM, Korn BS, Kikkawa DO: principles of periocular reconstruction following excision of cutaneous malignancy, *Journal of skin cancer*, vol 2012, 6 pages
11. Parodi PC, Calligaris G, Flavia M, Zeppieri: Lower eyelid reconstruction utilizing auricular conchal chondral-perichondral tissue in patients with neoplastic lesions, *Biomed research international* vol 2013, 6 pages
12. Subramanian N: Reconstruction of eyelid defects, *Indian J Plastic Surgery*, 2011 Jan-APR; 44(1):5-13
13. Czyz CN, Cahill KV, Foster JA, Michels KS, Clark CM, Rich NE: Reconstructive options for the medial canthus and eyelids following tumor excision, *Saudi J Ophthalmology*. Jan 2011; 25(1):67-74
14. J A. G. Tyers, R. O. Collin, *Colour Atlas of Ophthalmic and Plastic Surgery*, Butterworth Heinemann, 2nd Edition, 2001
15. T. E. Rohrer, J.I. Cook, T.H. Nguyen, J. R. Mellette Jr, *Flaps and grafts in Dermatologic Surgery*, Saunders Elsevier, 2007
16. N.T. Toledano, G.M. Grau, C. P. Sánchez, A. S. López, R. M. Jiménez, G. B. Mateos, *Cirugía palpebral y periocular*, Soc Española de Oftalmología, 2009

16. Cosmetic Blepharoplasty

Marco Marques, José Costa, Nádía Lopes, Guilherme Castela, Ana Rosa Pimentel

Introduction

Dermatochalasis refers to redundant and lax upper or lower eyelid skin, with loss of the underlying muscles' tone. It is usually an involutional change that occurs with the loss of the elastic and connective tissues of the eyelid that accompany the aging process. Less frequently, it is secondary to other conditions such as trauma, thyroid eye disease and blepharochalasis. Dermatochalasis is a common finding in patients over the age of 50, but it may also be seen in young adults. It is usually a cosmetic problem, but effects such as upper visual field loss, upper eyelid entropion and lower eyelid ectropion should not be overlooked. Patients frequently complain of saggy eyelids, with bags on the lids and wrinkles. The purpose of a blepharoplasty is not to remove all of the redundant skin: it is a reshaping procedure, which aims to provide a symmetric, aesthetically pleasing eye contour.

UPPER BLEPHAROPLASTY

Incision Planning

Upper eyelid blepharoplasty is performed via a cutaneous approach, and preoperative planning is as important as an appropriate surgical technique.

- The incisions should be marked while the patient is seated, so that the gravitational forces are taken into account (fig 1). The design of the cutaneous incision should be individualized: the patient's sex, race, facial features and globe prominence should all be taken into consideration.
- First, the upper eyelid crease must be marked. This is the most important step, as it will delineate the final lid position. In men, the crease it should be positioned 7-8 mm above the midpoint of the lid margin and extend laterally, parallel to it. In women, the crease is positioned slightly higher, 9-10 mm above the margin. Prominent globes are more easily concealed if the incision is placed nearer the margin. The incision is extended medially, above the upper punctum. The line is then tilted curvilinearly towards the medial end of the brow to form a 30° angle with the lid. Laterally, the inci-

sion is extended up to the orbital wall, above the lateral canthus. Then, a straight line, angled 45°, is directed towards the lateral end of the brow.

- The upper limit of the incision is measured from the eyebrow and the surgeon should leave 15-20 mm of skin of the anterior lamella. When the vertical extent of the blepharoplasty has been defined, a curvilinear line parallel to the eyebrow joins the previously marked nasal and lateral ends. (fig 2-3)
- The surgeon performs the pinch technique. The forceps grasp the inferior and superior incision. This technique must be performed while the patient keeps their eyes closed to make sure that there is no secondary lagophthalmos. (fig 4)

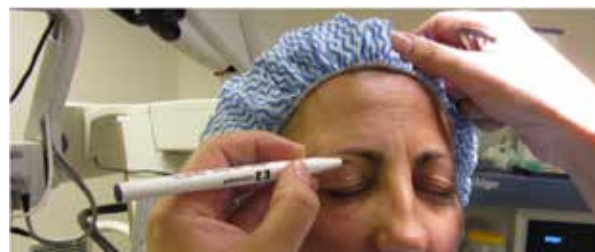

Fig. 1: The incision demarcation is done while the patient is seated.

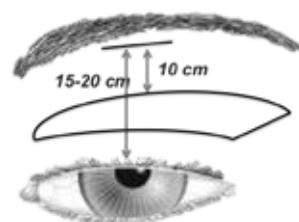


Fig. 2 : Skin incision marks.

Skin Excision

- Local anesthesia (i.e. 1% lidocaine with 1:200.000 epinephrine dilution),
- The skin can be incised with a no. 15 blade, beginning in the eyelid crease (fig 5). The surgeon must keep in mind that the levator muscle runs

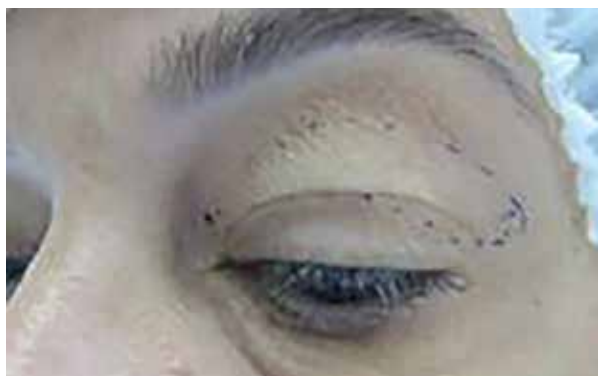

Fig. 3: Demarcation of the skin incision.

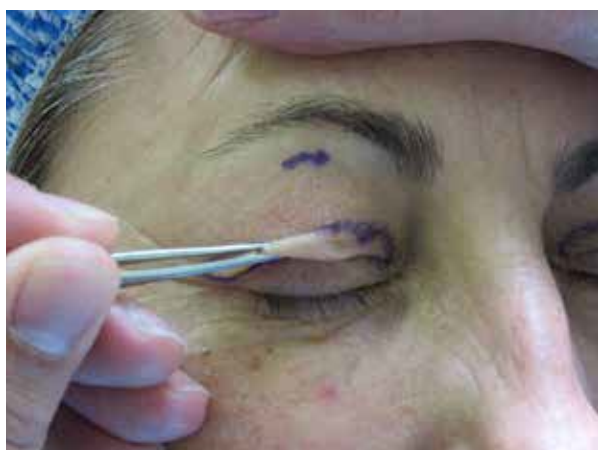

Fig. 4: The pinch technique.

superficially in this area and overly deep incisions may damage it. Ideally, the skin incisions should be performed in a continuous movement, as repositioning the blade often leads to irregular and excessively deep incisions.

- The skin flap can be freed from its connections to the *orbicularis* using the blade or with Westcott scissors (fig. 6). Insulated fine needle electrocautery, radiosurgery, and carbon dioxide lasers may help seal small blood vessels during dissection and limit the amount of deep orbital traction.

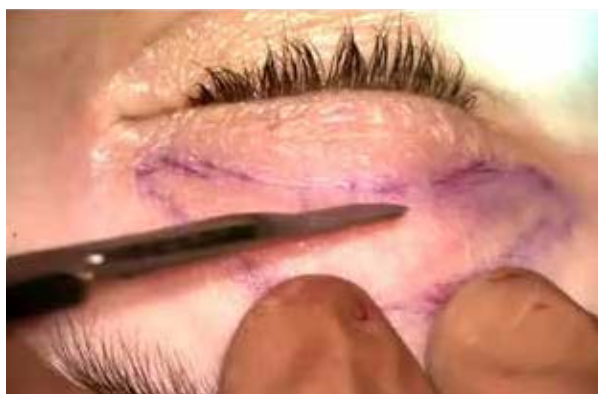

Fig. 5: Skin incision with a n° 15 blade.

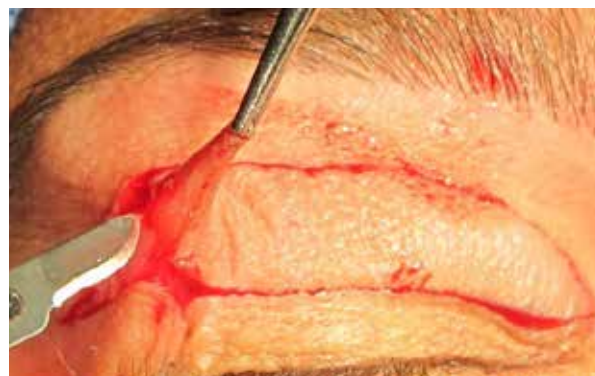

Fig 6: The skin flap is freed from its connections to the orbicularis.

Additional procedures

At this point, a partial resection of the *orbicularis* muscle can be done. Opinions diverge regarding the need to perform this orbicular myectomy. Some surgeons advocate that muscle excision is essential to prevent redundant tissue and create an aesthetically pleasing supratarsal fold. Others believe that it might hollow the orbit and decrease the lacrimal pump function. Nevertheless, orbicular myectomy should be performed whenever access to the orbital septum is warranted, as in coexisting orbital fat herniation (to approach the medial palpebral fat pad) (fig. 7) and senile ptosis (to access the levator aponeurosis).

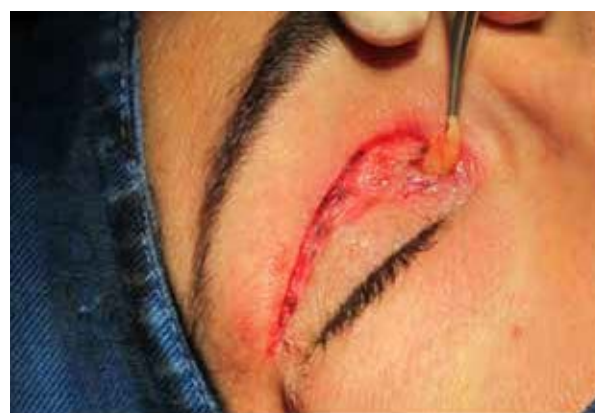

Fig. 7: Lipectomy of the internal superior fat pad.

Skin closure

Skin closure is usually performed with absorbable or non-absorbable 6-0 continuous sutures (fig. 8). An interrupted suture can be placed on the lateral edge of the wound to prevent dehiscence, as this is the area where wound stress is greater. Additionally, the upper eyelid crease can be reformed by grabbing a small portion of the aponeurosis when joining the skin edges.

INFERIOR BLEPHAROPLASTY

The lower lid is affected by numerous aesthetic deformations caused by ageing, including increased laxity of the skin, orbital septum, *orbicularis* muscle and canthus,

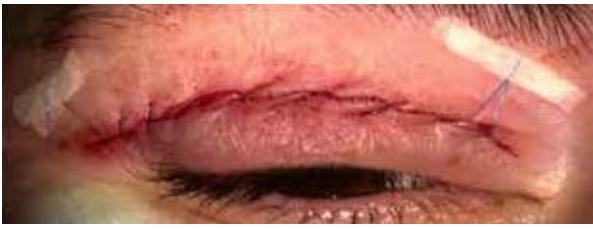

Fig. 8: Skin closure with a continuous suture.

herniation of orbital fatty tissue (caused by the relaxation of the orbicularis muscle, orbital septum and skin), malar festoons, periocular wrinkles and crow's feet.

The traditional procedure involved the removal of the herniated fat through a skin incision. Strengthening procedures for the orbital septum can complement both methods. Currently, there are two main approaches to lower lid surgery: the external or skin approach, and the internal or transconjunctival approach. The *ab externo* surgery is generally easier to perform than the transconjunctival technique, which, although harder, but allows surgical access without visible scar or lid malpositioning, and has lower rates of eyelid retraction and post-surgery ectropion. Nevertheless, some surgeons prefer a skin approach when there is dermatochalasis or evidence of orbicularis hypertrophy requiring muscle excision.

Cutaneous approach

- When no fat prolapse is evident, the skin pinch technique is used to estimate the amount of tissue to be removed. A subciliary incision is made and the redundant cutaneous tissue is conservatively removed (fig 9). Skin borders are then sutured to preserve the *orbicularis* muscle, except in cases of orbicularis muscle hypertrophy (fig 10).
- When skin laxity is associated with herniation of orbital fat tissue, more aggressive techniques are used. In what is known as the skin-muscle flap method, the eyelid skin is marked 2 mm below the *cilia* line, from the inferior lacrimal punctum to the lateral *canthus*. A scalpel is used to perform the skin incision, which can be extended temporally and downward in the case of *orbicularis* tightening or excess skin removal. Once the *sub-orbicularis* plane is reached, the orbital septum can be identified by carefully pushing the globe anteriorly. Orbital fat will prolapse, although still contained by the orbital *septum*. After opening the septum, orbital fat pads can be identified (fig 11). The capsule of each is opened and orbital fat can then be released from the pads, a procedure that requires caution to avoid hemorrhage within the orbit. Temporal and central fat pads are continuous, split only by a vertical fascia, while the medial pad capsule must be opened

separately and carefully so as not to damage the inferior oblique muscle. Closure of the skin is performed with 6/0 non-absorbable suture.

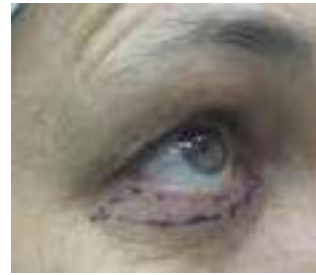


Fig. 9: Demarcation of the skin incision in inferior blepharoplasty.

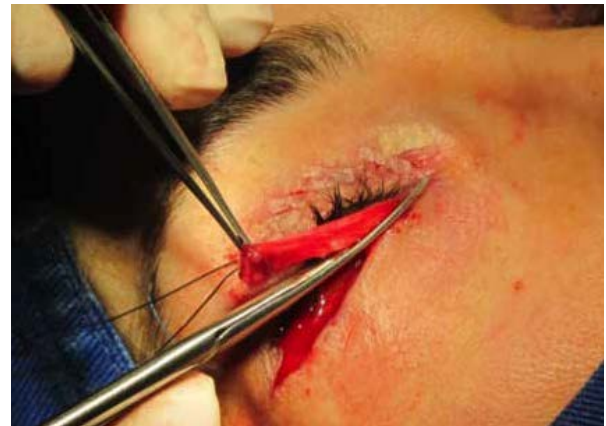

Fig. 10: Orbicularis myectomy.

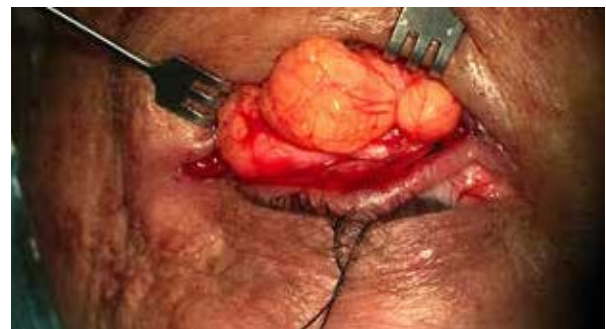

Fig. 11: Orbital fat pads released.

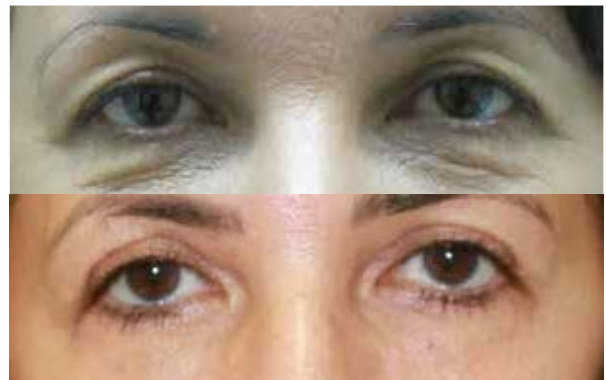

Fig. 12: Pre- and postoperative aspect of a patient who has undergone a lower blepharoplasty, cutaneous approach, and lipectomy.

16. Cosmetic Blepharoplasty

Transconjunctival approach

- A Desmarres retractor is used to evert the inferior lid and expose the fat pads (fig 13).
- An incision is made 4-6 mm from the eyelid margin by dissection with sharp scissors, cautery, or laser (fig 14).
- Fat pad prolapse can be incited by applying pressure on the eyeball, allowing the identification of the 3 inferior fat compartments of the orbit: lateral, central and medial (fig 15).
- Conservative fat removal is achieved after cauterization to prevent massive hemorrhage (fig 16). Care is taken not to damage the inferior oblique muscle, which runs between the medial and central fat pads.
- Excision is finished when pressure on the globe pushes the fat tissue forward but within the orbital rim.
- The conjunctival incision is usually left unsutured, with the borders well apposed to prevent overlap, and the healing process takes about one week (fig 17).

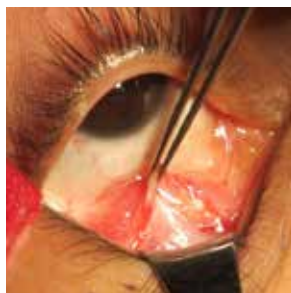

Fig. 13: A Desmarres retractor is used to evert the inferior eyelid.

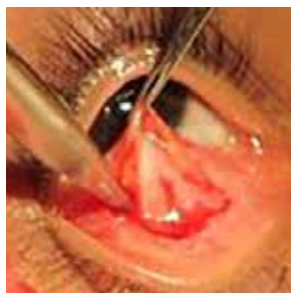

Fig. 14: An incision is made 4-6mm from the eyelid margin.

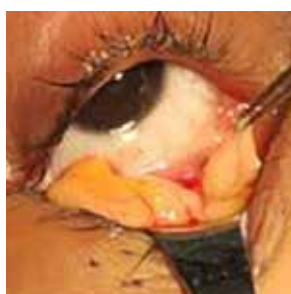

Fig. 15: Exposure of the 3 inferior fat pads.

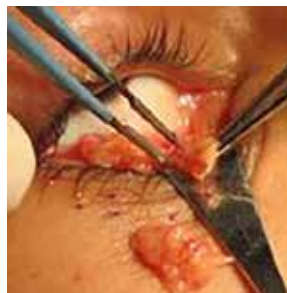

Fig. 16: Cauterization of the fat pads.

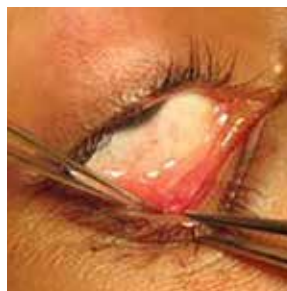

Fig. 17: The conjunctival incision is left unsutured, with the borders apposed.

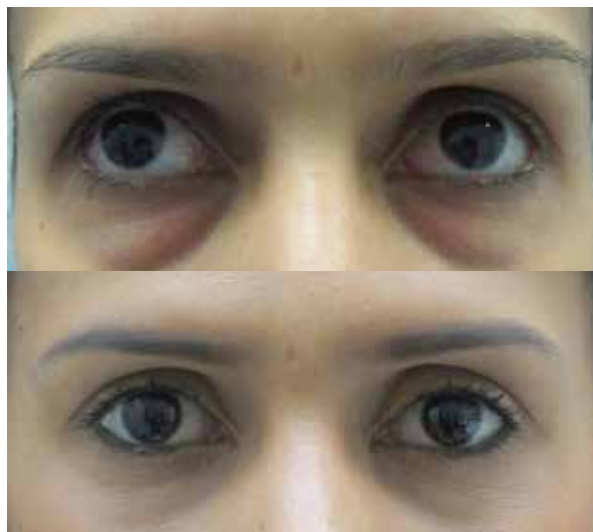
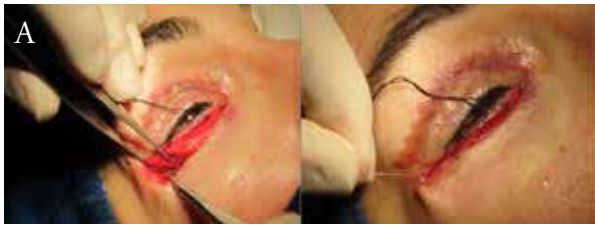
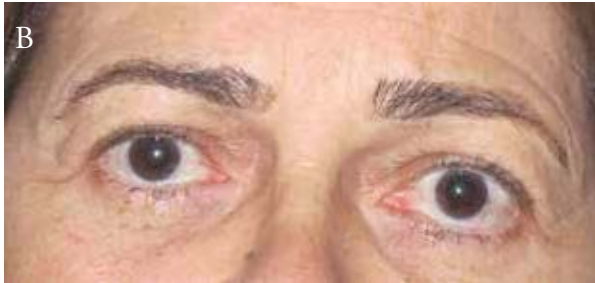Fig. 18: Pre- and postoperative aspect of a patient who has undergone lower blepharoplasty, transconjunctival approach, and lipectomy.

Additional procedures

- Canthopexy can be used in “rounded” lateral angles, by attaching them to the orbital periosteum, and tarsal strip procedures can be performed when excessive lid laxity is noticed (fig 19).
- Orbicularis suspension flap anchored to the periosteum can elevate the lower eyelid position to a more natural and anatomically appropriate position, and it also reinforces the underlying attenuated orbital septum.



Pre:



Post:

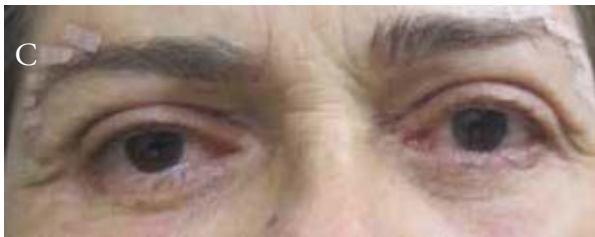

Fig. 19: A- A lateral canthopexy during an inferior blepharoplasty. B-C Pre and postoperative aspect of a patient with a rounded lateral angle, submitted to a lateral canthopexy.

Fat repositioning

The excision of the fat pads may cause a hollow appearance in patient with nasojugal groove. The repositioning of the inferior eyelid fat may be achieved by the cutaneous and transconjunctival approach, which is a useful procedure to fill the tear trough (fig. 20). Through this technique, a supraperiosteal pocket is created with a blunt dissection (fig 21), and the medial and the central lower eyelid herniated orbital fat are repositioned into the nasojugal fold (fig 22).

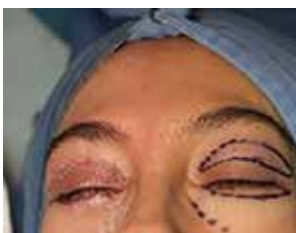

Fig. 20: Fat repositioning is a useful technique to fill the nasojugal groove.

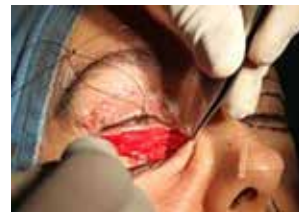

Fig. 21: A supra-periosteal pocket is created

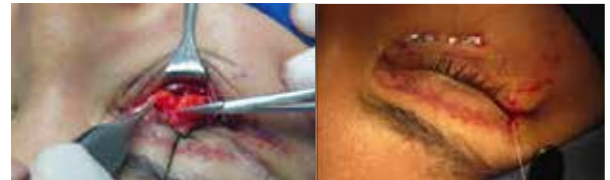

Fig. 22: The medial and central fat pads are repositioned in the nasojugal fold

Postoperative Care

- Head elevation and maintenance of supine position during sleep
- Ocular lubrication
- Activity restriction
- Corticosteroid eyedrop in cases of chemosis
- Local ice packs
- Sutures can usually be removed after 5-7 days.

COMPLICATIONS

Blepharoplasty is usually a safe procedure, although mild complications such as, edema, blurred vision and dry eyes are common. More serious complications such as orbital hematoma, lagophthalmos, ptosis and diplopia are rare but the oculoplastic surgeon should be able to manage them.

• Orbital hematoma

The incidence of orbital hematoma is 0.055% and it usually develops within the first 24 hours. Manipulation of the orbital fat and incision of the orbital septum predispose to this complication. The risk of postoperative orbital hemorrhage can be reduced through meticulous hemostasis, with cauterization of the resected fat pouches as well as the cauterization of bleeding points in the orbicular muscle and adjacent tissues. Canthotomy or cantholysis may be necessary in severe cases.

• Ectropion

Excessive skin resection, scarring of the orbital septum and failure of canthus anchoring may result in a lower eyelid malpositioning. In mild cases of cicatricial ectropion, a digital massage, associated or not with a steroid injection, may stretch the scar. In moderate to severe forms, the ectropion can be corrected by retractor resection, midface lift or myocutaneous flap combined with canthopexy (fig. 23).

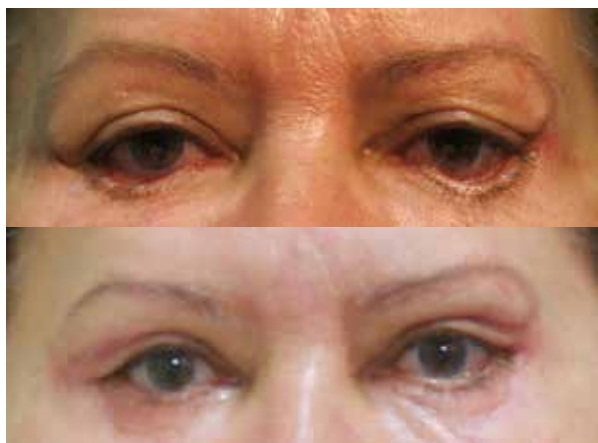

Fig. 23: A patient with a post blepharoplasty cicatricial ectropion. A: pre operative aspect. B: 3 months after a myocutaneous flap and a canthopexy.

- **Upper eyelid retraction**

This complication results from excess skin and fat removal. The surgeon must leave 15-20 mm of anterior lamella to avoid lagophthalmos. A full thickness skin graft may be necessary in severe cases. Retroauricular skin is often available and is a good substitute for eyelid skin.

- **Eyelid ptosis**

The main causes of ptosis after a blepharoplasty surgery are: eyelid edema, adherences between the orbital septum and the elevator eyelid during the blepharoplasty suture, and the damage to the levator aponeurosis with cautery. In most cases, the ptosis resolves spontaneously within 3 months.

- **Diplopia**

The lesion of the inferior oblique may result in transitional or permanent diplopia.

- **Unaesthetic result**

- Senile Orbit: the excessive removal of fat pouches can increase upper and lower eyelid grooves.
- Eyelid crease asymmetry: this complication is due to imprecise preoperative measurements. A repair operation can be performed after 3 months. The lower crease can be raised by making a higher incision to match and attaching the new crease to the levator aponeurosis. It is difficult to lower a crease which is too high.
- Epicanthus may occur when incisions are extended too far medially. Aggressive massage will eliminate the majority of cases. Persistent cases are treated by a V-to-Y plasty procedure.

References

1. Laser blepharoplasty with transconjunctival orbicularis muscle/septum tightening and periocular skin resurfacing: a safe and advantageous technique.
2. Seckel BR, Kovanda CJ, Cetrulo CL Jr, Passmore AK, Meneses PG, White T. *Plast Reconstr Surg.* 2000 Oct; 106(5):1127-41

3. Orbital septorhaphy for the correction of baggy upper and lower eyelids. Mühlbauer W, Holm C. *Aesthetic Plast Surg.* 2000 Nov-Dec; 24(6):418-23
4. Lower eyelid blepharoplasty: analysis of indications and the treatment of 100 patients. Rizk SS, Matarasso A. *Plast Reconstr Surg.* 2003 Mar; 111(3):1299-306; discussion 1307-8.
5. Expanded applications for transconjunctival lower lid blepharoplasty. Zarem HA, Resnick JJ. *Plast Reconstr Surg.* 1991 Aug; 88(2):215-20
6. Transcutaneous lower blepharoplasty. Adamson PA, Strecker HD. *Facial Plast Surg.* 1996 Apr; 12(2):171-83
7. Pinch technique for repair of cosmetic eyelid deformities. Parkes M, Fein W, Brennan HG. *Arch Ophthalmol.* 1973 Apr; 89(4):324-8
8. Sight lost after lower lid laser blepharoplasty. Trelles MA. *Ann Plast Surg.* 2000 Dec; 45(6):678-9
9. Hoorntje LE, Lei B, Stollenwerck GA, et al. Resecting orbicularis oculi muscle in upper eyelid blepharoplasty--a review of the literature. *J Plast Reconstr Aesthet Surg.* 2010 May; 63(5):787-92.

17. Periorbital Rejuvenation Fillers and Botulinum toxin

João Gil, Joana Providência, Guilherme Castela, Célia Stathler

Introduction

As life expectancy has increased over the years and the quality of life has improved, there is no doubt about the desire for a more youthful and attractive appearance. Understanding and slowing the aging process have become recurrent demands for an ever-growing number of patients. There is a widespread perception that looking young is equivalent to being successful, and today's culture values a youthful appearance probably more than ever before. The perception of a young face is the focal point of looking good and an aesthetic, well defined, periorbital unit is crucial to displaying a young face. Achieving such a goal can have a tremendous impact on a patient's physical, mental and social well-being.

Aging

Aging is a complex and continuous process that takes place under the influence of intrinsic factors and external agents, thus implying that every person ages differently and every attempted treatment should begin with a careful assessment of the particular anatomical details of the patient. The periorbital area is often one of the earliest parts to suffer structural aging changes¹ and, given the cultural significance attached to a person's eyes and the surrounding area, it is a region where even subtle changes in appearance can have a strong impact on the self-perceived notion of youngness and health. Thinning, deflation, descent and loss of subcutaneous tissue are the hallmarks of periorbital aging. The focus of earlier treatment approaches was almost exclusively excisional and consisted of removing skin and fat perceived as redundant. The notion that this "extra" skin is due to volume loss, and therefore treatment should be aimed at restoring the lost volume, is by no means new but interest in it has been renewed with the introduction of more sophisticated volumization options.

INJECTABLE HYALURONIC ACID FILLERS

Despite the early and ever increasing recognition of the importance of volume loss on the process of facial

aging, the role of volumization in aesthetic surgery was initially limited by the number of volume replacements available.² The first to be used was autologous fat, harvested and then grafted onto the face. Despite the abundance of donor material available, the process was slow, problematic and involved serious risks. Also, the longevity of its effect was remarkably inconsistent and fat survival difficult to predict. The reputation of fat as a filling agent declined steadily after the 1980s, but interestingly it has now gained new traction with the awareness of the potential benefit of stem cell grafting. Then came collagen injectables in the mid '80s, originally developed from bovine donors. They were all immunogenic to some extent and the risk of bovine encephalopathy from prion disease overshadowed their use but until the emergence of hyaluronic acid they were the most popular commercial fillers available. The discovery of synthetically created, non-animal-sourced fillers truly marked a breakthrough in the development of nonsurgical periorbital rejuvenation. Hyaluronic acid is a glycosaminoglycan disaccharide that represents the main polysaccharide in human extracellular matrix and is present in the skin, synovial joint fluid, and vitreous humor. Commercially available HA is usually obtained from bacterial sources and consists of repeating polysaccharide chains bonded with a varying amount of cross-linking agents. They provide a useful and practical treatment option by assuring a good safety profile, tolerability and efficacy. The exact composition of the gel can be adjusted to optimize its hardness, survival time, augmentation effect and degradation pattern to fit different clinical purposes. The existence of hyaluronidase, an "antidote" that can quickly degrade HA, means its use is reversible when needed, a key safety feature in an elective cosmetic procedure. The very action of injecting HA has been shown to stimulate the endogenous production of collagen, probably induced by the mechanical effect of stretching the dermis, thereby adding another therapeutic advantage to its use, particularly when used in atrophic skin.³ Despite small local differences, HA fillers have been the most popular

option since their introduction in the market. They represent an unbeatable leap in quality and efficacy over early collagen competitors and marked a game changing moment in facial aesthetic procedures. It was a watershed moment that reshaped the concept of facial aesthetic intervention, opening a new era where volumization is no longer a secondary resource for correcting two-dimensional flaws but the accepted first-line of treatment for optimal results. The main difference between commercially available HA fillers is their viscosity. As noted above, it is the cross-linking that gives the filler its stiffness and longevity. As a rule of thumb, the higher the cross-linking ratio the longer it lasts before being broken down and losing efficacy. The larger the fragments used and the higher its concentration, the more lift we can obtain from its use. The FDA approved hyaluronic acid fillers include Juvederm Ultra/volbella/vollift/volume (Allergan Inc., Irvine, CA), Restylane/Perlane (Medicis, Scottsdale, AZ), Belotero (Merz, San Mateo, CA), and Prevelle Silk (Genzyme/ Mentor Corp., Santa Barbara, CA). FDA approval for these products is similar and their usage in the periocular area is off-label. Based on the experience of the authors and the characteristics of the periocular region, it is likely that Restylane® and Juvederm Volbella/ Ultra ® are better suited to the periocular area

Application technique

A comprehensive history and physical examination are needed so as to carefully assess the areas of volume loss before injection. Pertinent items in the medical history are infections, autoimmune diseases, history of keloid formation, and previous cosmetic treatments. If the patient has used fillers before it is useful to know how long ago, in which site they were placed and what the patient's perception of the results was. Informed consent should be obtained before any treatment. Taking pre-injection photographs is extremely important, although their number, angle and close-up can vary among treatments and physicians.

A cold or a numbing cream can be applied 30 minutes before the procedure to reduce pain. Infiltrative anesthesia is likely to be more effective but the size of the needles and cannulas is unlikely to induce much pain. Nevertheless, instilling lidocaine and adrenaline has the advantage of achieving some level of local vasoconstriction. In some areas, like the eyelid skin, infiltrative local anesthesia can cause considerable distortion of the tissues, which limits its systematic use. There are several injection techniques and they all can be combined to achieve optimal results depending on the area to be treated. The **serial puncture** technique uses multiple passes, pointing the bevel of the needle superiorly to dispense small

droplets of product across a fold. The disadvantage is that the patient will have to endure multiple needle sticks. In the **linear threading** technique, the product is laid like a cord, in a retrograde fashion as the needle is removed after being advanced forward. The **fanning** technique is one the most commonly used, and the method is similar to linear threading but the product is dispensed in multiple angles, in a fan-like arrangement, without the needle actually being completely removed from the skin. The **cross-hatching** technique involves injecting several parallel lines of filler layered in one direction, and then another group of lines are injected perpendicularly at a different depth. The goal is to create a scaffold-like structure beneath the fold. Serial puncture and linear threading are the most commonly used techniques in the periorbital region. Some recommendations on injection technique according to particular anatomic areas are given below. Although we are presenting these as individual, segmented, anatomic units most authors recommend using a comprehensive rather than a segmental approach to filler rejuvenation.⁴

Lower Eyelid

Nasojugal (tear trough) and palpebral malar sulcus

In the lower eyelid HA is usually injected at a slightly deeper level using a needle or cannula to travel through the suborbicularis plane and into the deep supraperiosteal plane.

With the patient looking up, the HA can be introduced using multiple passes to distribute content in a linear manner. A serial puncture technique can also be used with the advantage that it more easily identifies the supraperiosteal space. Using cannulas instead of needles and not withdrawing the cannula completely can help diminish bruising. The advantage of using a needle is more precision in the application technique. The average amount of HA applied can range from 0.3 to 0.5 or 0.8 ml. (on each side). Restylane® and Juvederm Volbella® are products suitable for these regions. (Fig. 1 to 4)

Sub-brow and temple

Filler can also be used in the subbrow area and along the lateral orbital rim, particularly in patients with some degree of exposure of the lateral orbital rim. The filler is injected in the supra-periosteal area, and somewhere from 0.1 ml to 0.4 ml of HA is used to treat this area on each side. Temple hollowing due to soft tissue deflation is a common feature of the aging process and can affect the look of the whole periorbital region. Restoring volume is used to treat patients with hollowing of the temple. The needle is inserted through the skin and into the superficial

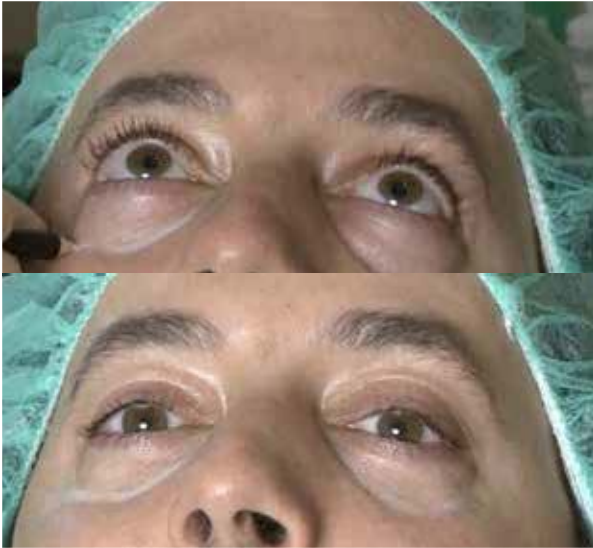

Fig. 1: Marking the nasojugal and palpebral malar sulcus.

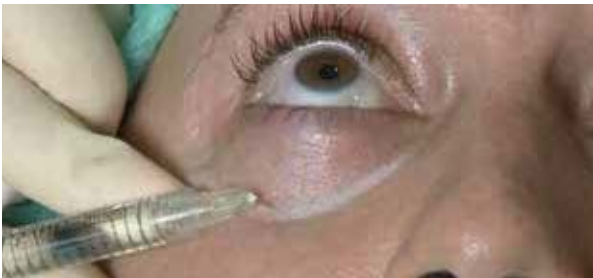

Fig. 2: Serial puncture technique, HA application of Volbella® in the suprapariosteal plane.

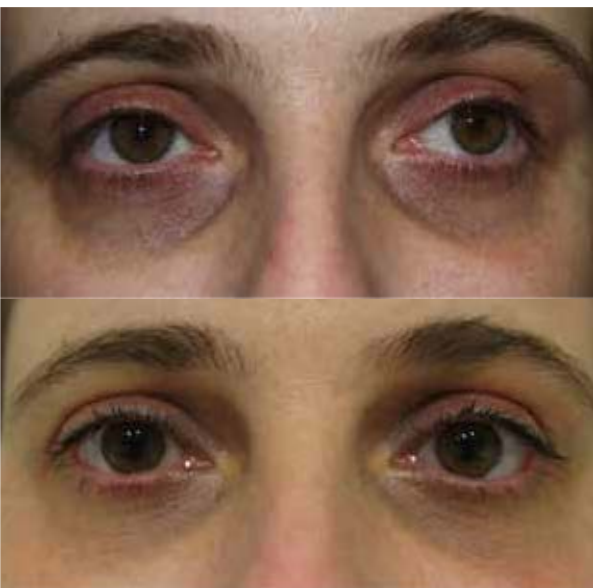

Fig. 3: Nasojugal and palpebral malar sulcus pre-treatment and post-treatment photos.

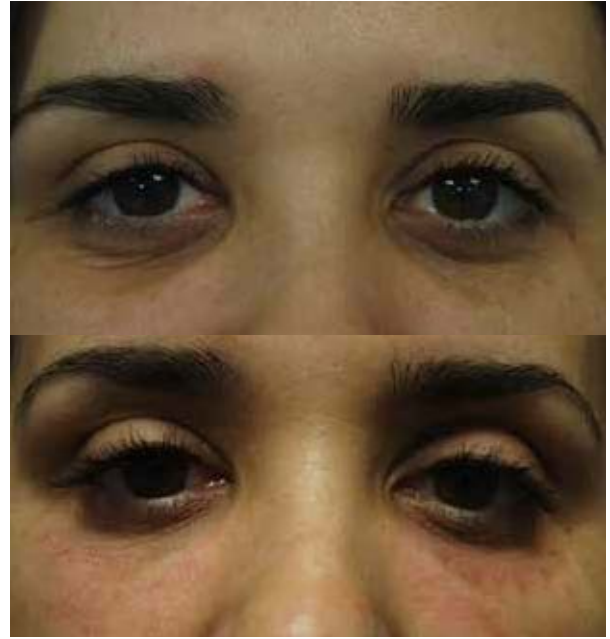

Fig. 4: Tear trough pre-treatment and post-treatment photos.

temporal fascia. HA is introduced slowly as the needle advances. The filler should be spread evenly both superiorly and inferiorly to avoid a corrugation-like appearance. Because the skin of this area is quite thin, some authors recommend the use of diluted HA using sterile saline to make up a 1:1 mixture.⁵ Even so, some bruising can be expected. Juvederm Ultra 3® and Voluma® are appropriate products for these areas. (Fig. 5)

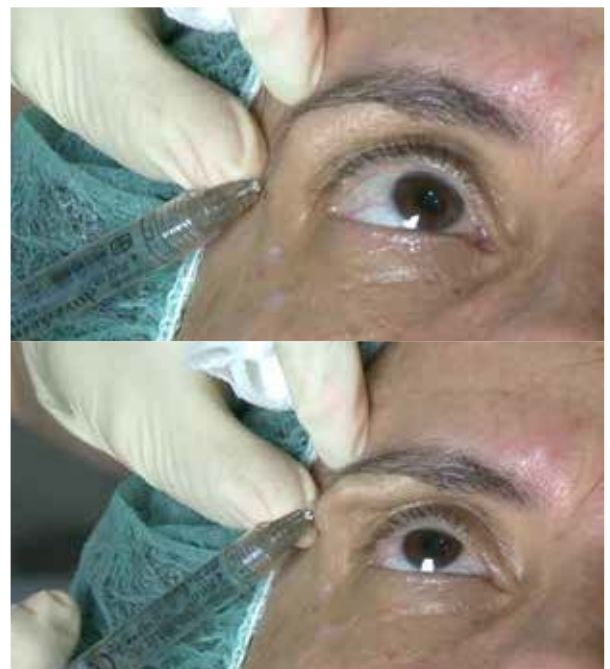

Fig. 5: Sub-brow subdermal injection of HA (Ultra 3®).

Adverse Effects and Complications

Side effects are usually mild and self-limiting. The most common are bruising, redness, contour irregularities, pain at the injection site, swelling, and product discoloration.⁶⁻⁹ Almost all of them can be minimized by injecting more slowly, using less product and using more passes.

A certain amount of bruising and redness is always to be expected and should disappear after 1 to 2 weeks. Choosing the puncture site carefully and injecting slowly is a good way to avoid rupturing small vessels and causing localized bruising. Applying ice packs and firm local compression should reduce swelling and bruising. Localized painful and erythematous nodules may be due to infectious dissemination and should be treated with appropriate antibiotic coverage. The importance of ensuring a proper asepsis and antisepsis before the procedure cannot be overstated. If there is a site of infection nearby it is advisable to postpone the injection.

Some patients may complain of overcorrection or localized lumps that give an unnatural appearance. This can be prevented by injecting less volume and choosing the injection site more carefully. When a lump or overcorrection (fig 6) is already present, hyaluronidase can be used to quickly dissolve a localized nodule.¹⁰ A bluish discoloration of the skin, known as the Tyndall effect, can occur (fig 7). It is caused by the reflection and scattering of light inside the clear cavity created by the fluid pocket. Blue light is scattered more strongly by the suspended particles inside the HA, thus creating this effect.¹¹ It occurs more often when the HA is applied more superficially, below the skin on the orbicular muscle. Again, minimizing the amount of HA injected on each pass and spreading several passes across different levels can reduce the risk of the Tyndall effect occurring without decreasing the total amount injected. Applying a vigorous localized massage can be effective in dispersing the accumulated material. Vascular compromise is a rare but serious occurrence. Vascular flow can be impaired by direct vessel trauma, inadvertent endoluminal injection, or contiguous pressure exerted by the filler. An arterial occlusion should be apparent almost immediately due to the sudden appearance of localized blanching and pain. The injection should be stopped immediately and an attempt made to carefully aspirate the material. This should be followed by a vigorous warm massage and application of nitroglycerin paste. Venous occlusion can be heralded by delayed dull pain and skin breakdown. Again, warm massage and nitroglycerin paste should be used. Assuming that an HA based filler was used, injection of hyaluronidase can be attempted in both cases to disrupt the offending product.

Probably the most feared side-effect of periorbital filler injection is blindness due to vascular occlusion. Although extremely rare, this has been increasing due to the constantly growing popularity of the procedure. There are several published series reporting on this event.¹²⁻¹⁴ In none of the series were the events limited to HA injection or periorbital treatments. The proposed mechanism involves intravascular injection of material rather than external pressure. If the artery is inadvertently penetrated and pressure applied, the filler can travel against the flow near to the origin of the retinal artery. As pressure ceases, the arterial flow will then carry the embolus into the retinal circulation. Since the implicated vessels are of small caliber, it does not take a large amount of material to fully occlude a portion of the retinal circulation.¹⁵ In a recent review by Carruthers et al.¹⁵ the authors recommend following some precautions to prevent these complications. Among them are the use of blunt cannulas and smaller syringes, and injecting epinephrine to induce vasoconstriction. The proper technique recommended includes injecting slowly and in small amounts, gently withdrawing the needle or cannula before injecting, and never injecting near the site of a recent trauma. In the unfortunate event of this dreaded complication occurring, early recognition of the complication and timely injection of retrobulbar hyaluronidase may help prevent more severe effects.

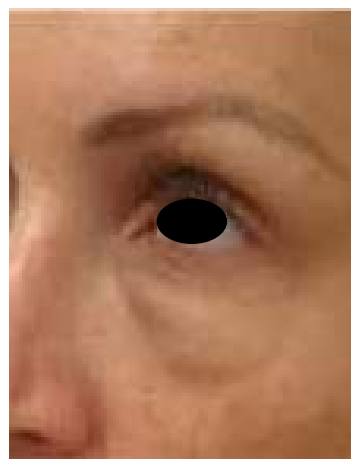

Fig. 6: Overcorrection after tear trough HA filler.

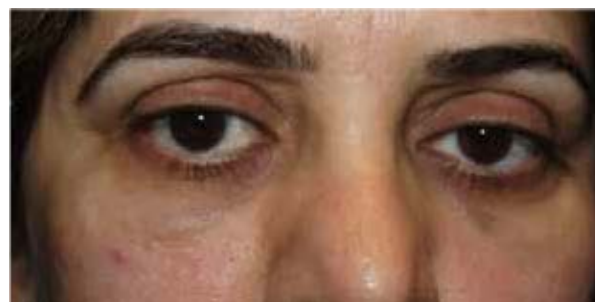

Fig. 7: Tyndall effect.

BOTULINUM TOXIN

Botulinum toxin is biologically produced by *Clostridium botulinum*, a gram positive anaerobe bacterium responsible for botulism. Botulinum toxin acts by pre-synaptically blocking the exocytosis of acetylcholine from motor nerve terminals and causing a reduction in muscular contraction. Even though the neurotransmitter release is blocked there is no nerve degeneration associated with the process.¹⁶ Botulinum toxins have been grouped into seven types, A, B, C1 and C2, D, E and F, based on their immunological properties, although most clinical products are based on the botulinum neurotoxin type A. This serotype is present in OnabotulinumtoxinA (Botox® and Vistabel®), IncobotulinumtoxinA (Xeomin®) and Abobotulinum toxin A (Dysport®). IncobotulinumtoxinA differs from the other formulations in that it is free from complexing proteins and can be stored at room temperature. All these formulations have similar potency except abobotulinum toxin A, which has a conversion ratio of 3 U per 1 U of the other commercially available brands.¹⁷ This toxin has been used since the late 1970s, when Allan Scott used botulinum toxin type A to treat children with strabismus. Scott believed that the toxin would cause weakness in the injected ocular muscles and so enable the antagonist muscles to contract more effectively. In 1989 botulinum toxin type A was approved by the FDA for strabismus and blepharospasm treatment. Nowadays it is used in other hyperfunctional muscular disorders, autonomic nervous system diseases, pain syndromes and in glandular and secretor modulation. In Ophthalmology it has a therapeutic indication in strabismus, blepharospasm, hemifacial spasm, spasmodic entropion, palpebral retraction, crocodile tears syndrome, and a cosmetic function in hyperfunctional facial lines. It is one of the most popular aesthetic procedures in the world. The use of botulinum toxin in aesthetic medicine appears to have modulatory effects on the patient's mood and can have some role in the treatment of depression, probably via proprioceptive feedback mechanisms.¹⁸⁻¹⁹ The natural process of aging is characterized by the loss of volume around the eyes, lid and brow ptosis, dermatochalasis and the appearance of facial lines, resulting in a tired and sad facial expression. The use of botulinum toxin can improve some of these signs with a great impact on the appearance and well-being of patients.

As with other medical procedures, before any treatment is performed a full medical history and examination is mandatory. A dynamic and at rest evaluation are essential, with the focus on facial

asymmetry and other ocular alterations, such as exophthalmos or lid retraction. Facial lines can be evaluated by asking the patient to smile, to raise and lower the eyebrows. Lower lid snapback test is important in the evaluation of lid laxity. Each procedure must be planned individually and the patient should be informed about the expected final results of the intervention.

Reconstitution

The toxin comes as a crystalline substance from the manufacturer, which then has to be reconstituted. OnabotulinumtoxinA is recommended to be reconstituted with sterile non-preserved saline (0.9% sodium chloride). The reconstitution can be stored in the freezer (2 to 8 degrees) and used within 3 days. Some authors say that the reconstituted toxin can be used over the following three weeks with no risk of contamination. The facial muscles require less concentrated solutions as these are associated with less painful injections, so the recommended dilution volume for OnabotulinumtoxinA in facial muscles is usually 1 to 3 ml of saline.²⁰ All units specified in this chapter are American units. To convert to European units the values should be multiplied by 3. (Table 1)

Table 1: Common reconstitutions for aesthetic procedures

Toxin	Volume
Botox® Vistabel® and Xeomin®	1 to 3 ml (2 ml; 0.1ml/5U) (2.5 ml; 0.1ml/4U)
Dysport® 300 U	1.5 to 2.5ml (2.3 ml; 0.1ml/13U)

Contraindications

Botulinum toxin is contraindicated in patients who are hypersensitive to any botulinum toxin preparation or to any of the components in the formulation. Also, it is not recommended if there is a local inflammatory or infectious process, a history of neuromuscular disease, use of aminoglycosides or pregnancy and lactation. Note that other pre-existing ocular conditions can get worse with the treatment. Therefore, botulinum toxin should be used carefully if there is severe elastosis, dry eye, facial palsy, body dysmorphic disorder, lid ptosis or hypofunctioning orbicular muscle. Any anticoagulant or antiaggregant medication should be stopped one week before the procedure to avoid hemorrhagic complications.

Glabellar lines and Eyebrow

Botulinum toxin type A for treatment of glabellar rhytides was approved by the FDA in 2002, fifteen years after it was first noticed that patients treated with botulinum toxin for blepharospasm also had improvement of glabellar lines.

Glabella includes the corrugator supercilli muscles and

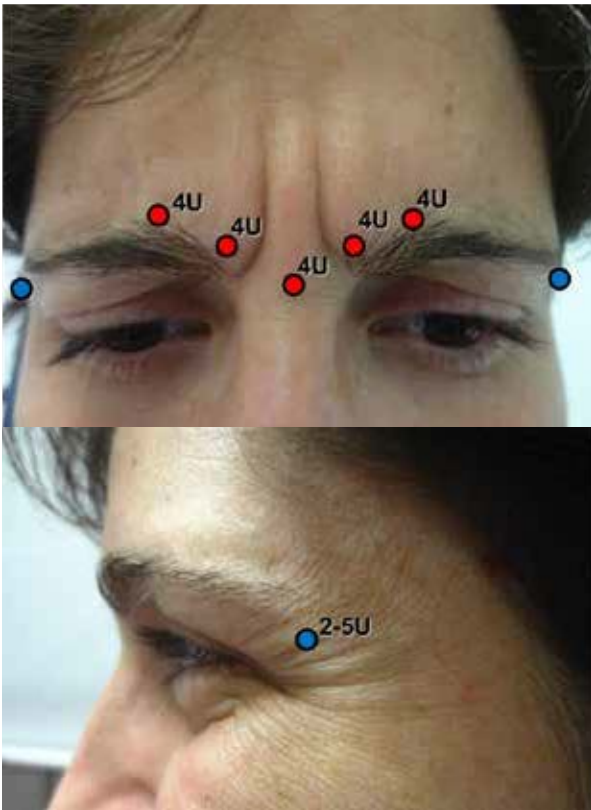


Fig. 8: Glabellar lines and eyebrow, possible injection sites and doses.

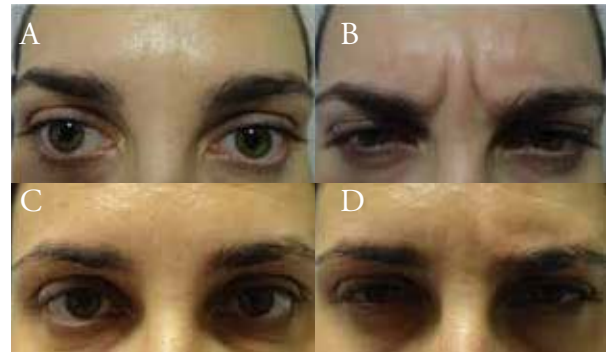

Fig. 9: Glabellar lines: A-B Pre-treatment, C-D Post-treatment.

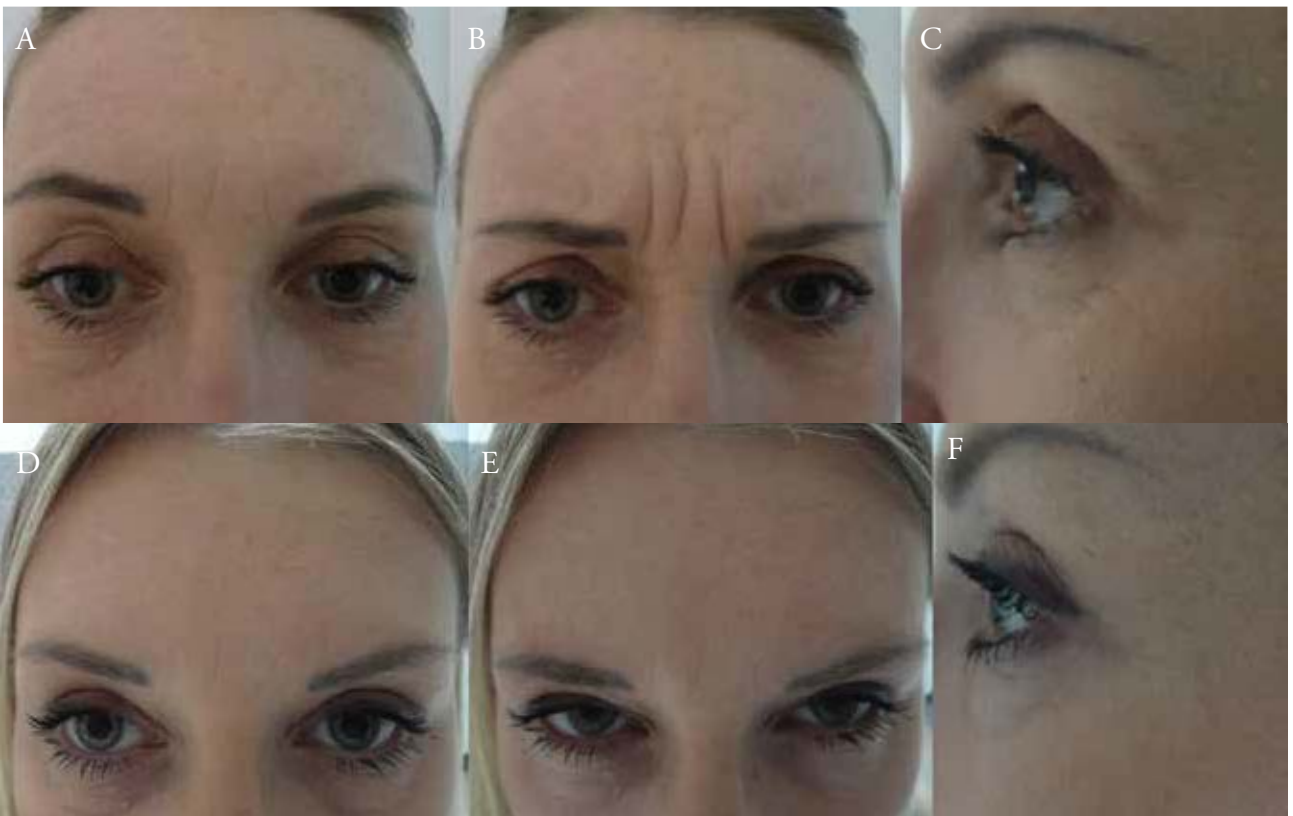

Fig. 10: Glabellar lines and eyebrow: A-C Pre-treatment, D-F Post-treatment.

the procerus muscle, both responsible for pulling the eyebrow medially and downward, and so gradually causing the glabellar lines. The frontalis muscle is responsible for raising the brow and the orbicularis oculi is the main brow depressor. The movement and shape of the brow are important factors in perceived facial expression and aesthetics and the overall facial shape must be evaluated when planning the procedure. Botulinum toxin can be used both to treat glabellar lines and to raise the brow. The treatment of glabellar lines typically uses five to seven injection sites. 4-5 units are injected into the procerus, 4-5 units in each medial corrugator, 4-5 units in each lateral corrugator. The effect is noticed after 5-7 days with its maximum effect reached in 15 days, and lasts three to four months. Normally the total used dose is 20-30 units in women and 30-40 units in men.²¹⁻²² In the eyebrow elevation procedure, 2 to 5 units are injected inferior to the lateral brow, promoting an elevation of 1 to 3 mm. (Fig. 8 to 10)

Frontalis lines

The forehead is particularly responsive to botulinum toxin so smaller doses are generally used to maintain facial expression and avoid eyebrow ptosis. The injected sites are chosen individually, depending on the shape of the forehead. Injection below the first frontalis line is avoided as it is associated with brow ptosis and horizontalization of the brow. Botulinum toxin can also be used in the treatment of forehead scars to reduce asymmetry. The total dose used is between 10 to 15 U in women and 20 to 25 U in men.²³ (Fig. 11, 12)

Crow's feet

Crow's feet lines are one of the first signs of aging, often appearing by the 3rd decade of life. The skin in this area is particularly thin, elastic and has little underlying fat, making it susceptible to rhytides. There are some known associated factors that contribute to the development of the lines, including smoking and sun exposure.

The botulinum toxin injection is done superficially in this area, 2 to 2,5 units in 3 to 6 sites lateral to the bony orbital rim. Normally, the injection is done 1 cm from the orbital rim to reduce dissemination of the toxin to the orbit and minimize the risk of accidentally injuring any orbital structure, including the eyeball. The characteristics of the skin in this area also make it particularly susceptible to ecchymosis. Lip ptosis can occur if the zygomatic muscles are accidentally injected. The total dose used is 6 to 8 U each side.²⁴ (Fig. 13, 14)

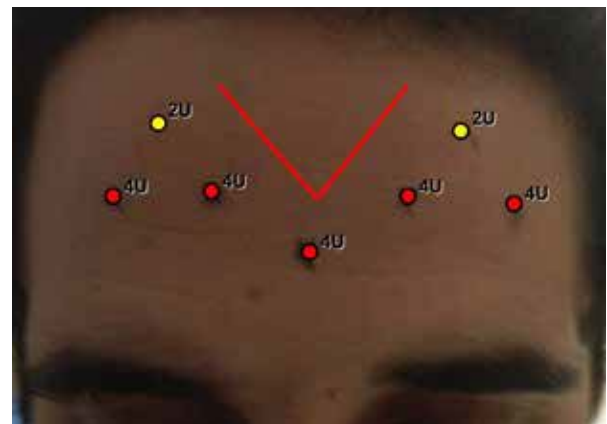


Fig. 11: Frontalis lines injection sites and doses.

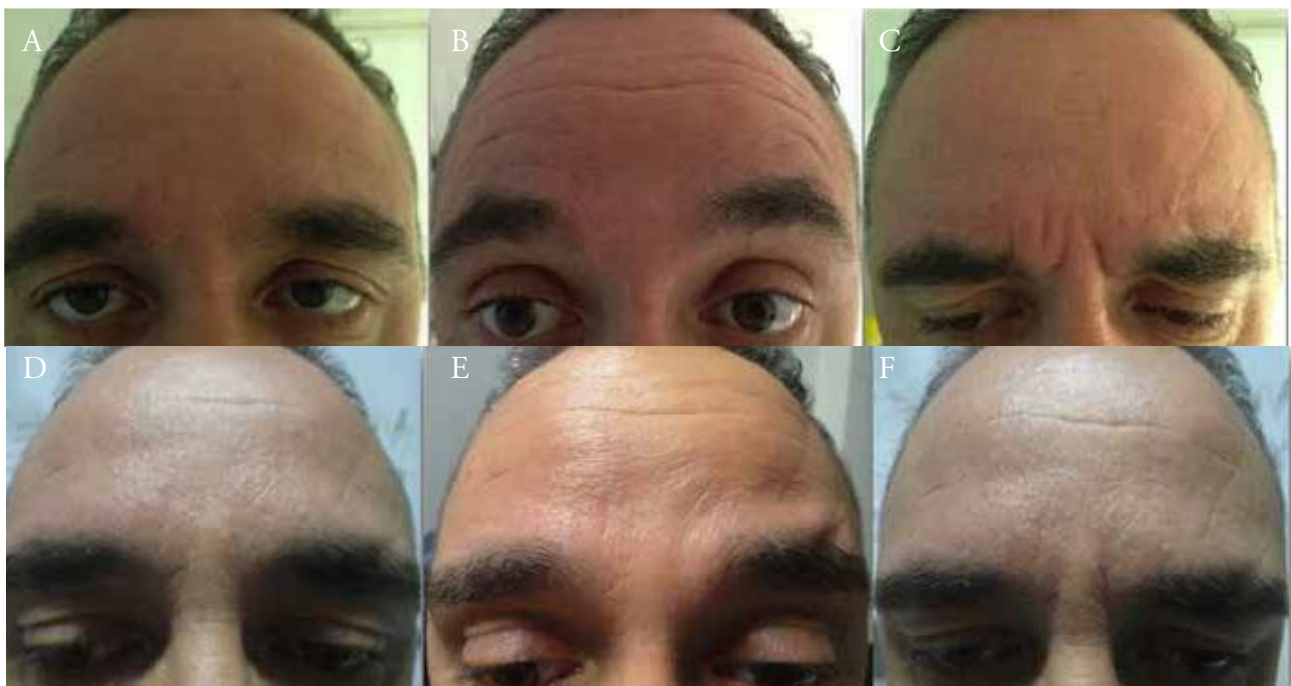

Fig. 12: Frontalis lines A-C Pre-treatment, D-F Post-treatment.

17. Periorbital Rejuvenation Fillers and Botulinum toxin

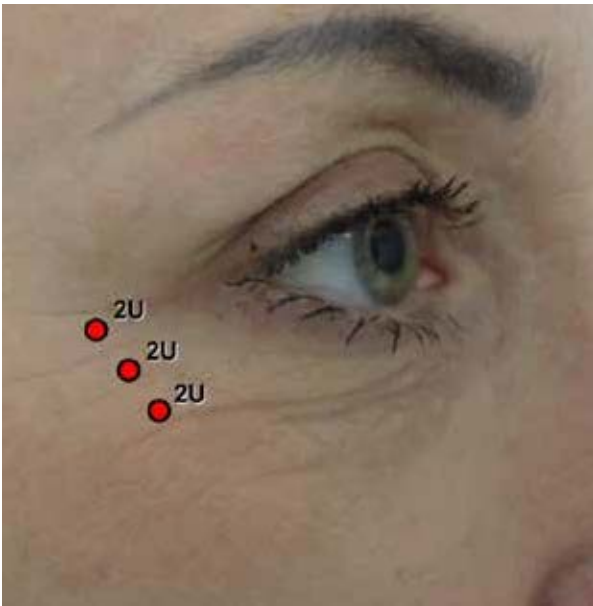


Fig. 13: Crow's feet injection sites and doses.

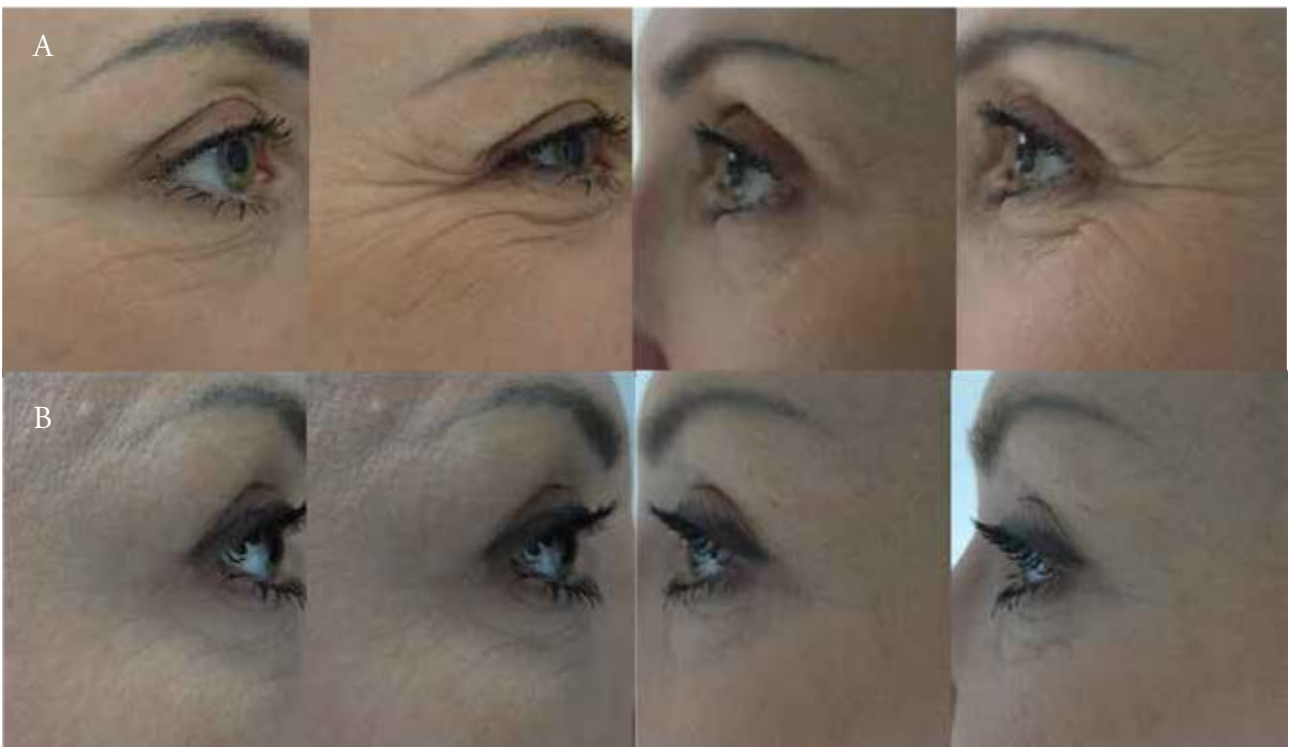

Fig. 14: Crow's feet: A - Pre-treatment, B - Post-treatment.


Conclusion

Botulinum toxin is an effective and safe procedure for the aesthetic treatment of the periocular area, and its clinical use is quickly expanding. Other non-invasive aesthetic procedures such as fillers and fat graft can be used to optimize the final results of botulinum toxin therapy. A comprehensive knowledge of the facial anatomy and aesthetics of the upper face can result in keeping a youthful look and improving the signs of aging. The conscious change of self-image can boost self-esteem and have a holistic impact on the quality of life.

References

- Liew S, Nguyen DQA. Nonsurgical volumetric upper periorbital rejuvenation: A plastic surgeon's perspective. *Aesthetic Plast Surg.* 2011;35(3):319-325. doi:10.1007/s00266-010-9609-4.
- Johl SS, Burgett R a. Dermal filler agents: a practical review. *Curr Opin Ophthalmol.* 2006;17(5):471-479. doi:10.1097/01.icu.0000243021.20499.4b.
- Wang F, Garza L a, Kang S, et al. In vivo stimulation of de novo collagen production caused by cross-linked hyaluronic acid dermal filler injections in photodamaged human skin. *Arch Dermatol.* 2007;143(2):155-163. doi:10.1001/archderm.143.2.155.
- Kane M a. C. Nonsurgical periorbital and brow rejuvenation. *Plast Reconstr Surg.* 2015;135(1):63-71. doi:10.1097/PRS.0000000000000831.
- Hoenig J, Hoenig D. Minimally invasive periorbital rejuvenation. *Facial Plast Surg.* 2013;29(4):295-309. doi:10.1055/s-0033-1349363.
- Finn JC, Cox S. Fillers in the Periorbital Complex. *Facial Plast Surg Clin North Am.* 2007;15(1):123-132. doi:10.1016/j.fsc.2006.10.006.
- Goldberg RA, Fiaschetti D. Filling the periorbital hollows with hyaluronic acid gel: initial experience with 244 injections. *Ophthal Plast Reconstr Surg.* 2006;22(5):335-341; discussion 341-343. doi:10.1097/01.iop.0000235820.00633.61.
- Friedman PM, Mafong EA, Kauvar ANB, Geronemus RG. Safety data of injectable nonanimal stabilized hyaluronic acid gel for soft tissue augmentation. *Dermatologic Surg.* 2002;28(6):491-494. doi:10.1046/j.1524-4725.2002.01251.x.
- Matarasso SL, Carruthers JD, Jewell ML. Consensus recommendations for soft-tissue augmentation with nonanimal stabilized hyaluronic acid (Restylane). *Plast Reconstr Surg.* 2006;117(3 Suppl):3S - 34S; discussion 35S - 43S. doi:10.1097/01.prs.0000204759.76865.39.
- Sharad J. Dermal Fillers for the Treatment of Tear Trough Deformity: A Review of Anatomy, Treatment Techniques, and their Outcomes. *J Cutan Aesthet Surg.* 2012;5(4):229-238. doi:10.4103/0974-2077.104910.
- Lafaille P, Benedetto A. Fillers: contraindications, side effects and precautions. *J Cutan Aesthet Surg.* 2010;3(1):16-19. doi:10.4103/0974-2077.63222.
- Ozturk CN, Li Y, Tung R, Parker L, Piliang MP, Zins JE. Complications following injection of soft-tissue fillers. *Aesthet Surg J.* 2013;33(July):862-877. doi:10.1177/1090820X13493638.
- Park SW, Woo SJ, Park KH, Huh JW, Jung C, Kwon OK. Iatrogenic retinal artery occlusion caused by cosmetic facial filler injections. *Am J Ophthalmol.* 2012;154(4):653-662. doi:10.1016/j.ajo.2012.04.019.
- Lazzeri D, Agostini T, Figus M, Nardi M, Pantaloni M, Lazzeri S. Blindness following cosmetic injections of the face. *Plast Reconstr Surg.* 2012;129(4):995-1012. doi:10.1097/PRS.0b013e3182442363.
- Carruthers JDA, Fagien S, Rohrich RJ, Weinkle S, Carruthers A. Blindness Caused by Cosmetic Filler Injection. *Plast Reconstr Surg.* 2014;134(6):1197-1201. doi:10.1097/PRS.0000000000000754.
- Burgen AS, Dickens F, Zatman LJ. The action of botulinum toxin on the neuro-muscular junction. *J Physiol.* 1948;109:10-24.
- Karsai S, Raulin C. Current evidence on the unit equivalence of different botulinum neurotoxin A formulations and recommendations for clinical practice in dermatology. *Dermatol Surg.* 2009;35(1):1-8. doi:10.1111/j.1524-4725.2008.34375.x.
- Wollmer MA, de Boer C, Kalak N, et al. Facing depression with botulinum toxin: a randomized controlled trial. *J Psychiatr Res.* 2012;46(5):574-581. doi:10.1016/j.jpsychires.2012.01.027.
- Alam M, Barrett KC, Hodapp RM, Arndt KA. Botulinum toxin and the facial feedback hypothesis: can looking better make you feel happier? *J Am Acad Dermatol.* 2008;58(6):1061-1072. doi:10.1016/j.jaad.2007.10.649.
- Almeida AT de, Secco LC. Reconstitution/dilution. In: Carruthers A, Carruthers J, eds. *Botulinum Toxin*. 3rd ed. Elsevier; 2013.
- Ascher B, Talarico S, Cassuto D, et al. International consensus recommendations on the aesthetic usage of botulinum toxin type A (Speywood Unit)--Part I: Upper facial wrinkles. *J Eur Acad Dermatol Venereol.* 2010;24(11):1278-1284. doi:10.1111/j.1468-3083.2010.03631.x.
- Wesley NO, Jones DH. Glabella. In: Carruthers A, Carruthers J, eds. *Botulinum Toxin*. 3rd ed. Elsevier; 2013.
- Liu A, Ozog DM, Cohen JL. Frontalis and horizontal forehead lines. In: Carruthers A, Carruthers J, eds. *Botulinum Toxin*. 3rd ed. Elsevier; 2013.
- Warycha M, Dover JS, Alam M. Treatment of crow's feet. In: Carruthers A, Carruthers J, eds. *Botulinum Toxin*. 3rd ed. Elsevier; 2013.

LACRIMAL DRAINAGE SYSTEM

- 
- 18 Congenital Nasolacrimal Duct Obstruction
 - 19 External Dacryocystorhinostomy
 - 20 Endonasal Dacryocystorhinostomy
 - 21 Transcanalicular Laser Dacryocystorhinostomy

18. Congenital nasolacrimal duct obstruction (CNLDO)

Guilherme Castela

Introduction

Congenital nasolacrimal duct obstruction (CNLDO) is the most frequent cause of epiphora in children and affects ~6% to 20% of all newborns^{1,2}. CNLDO is more common in children with Down syndrome and craniofacial syndromes. At birth, 50% of the nasolacrimal ducts are not permeable and spontaneous perforation occurs within the first 3 to 4 weeks of life. A few children have persistent epiphora and spontaneous resolution in the first year of life occurs in more than 90% of cases.

In normal embryonic development, the nasal lacrimal membrane (Hasner valve) breaks during pregnancy between 6 months of gestation and birth. In children with CNLDO, maturation of the lacrimal system and nose is delayed, mainly due to the absence of Hasner valve permeability at the entrance of the inferior meatus²⁻⁴. Less often, CNLDO is caused by a narrowing in the distal nasolacrimal duct or nasal inferior turbinate hypertrophy. This situation must be resolved by the time the child reaches 2 to 3 years of age, as the obstructions become more complex with the passage of time and therefore more difficult to resolve.

Clinical Manifestations

Symptoms begin within the first few weeks of life, the most common being the presence of mattering in the first few weeks and increased lacrimal meniscus and epiphora after the second month (Fig. 1,2).

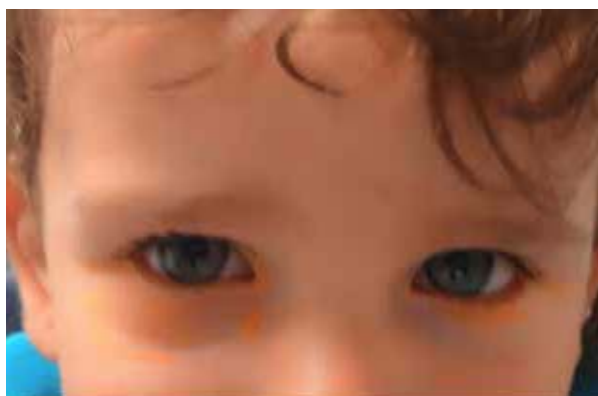

Fig. 1: Bilateral CNLDO.

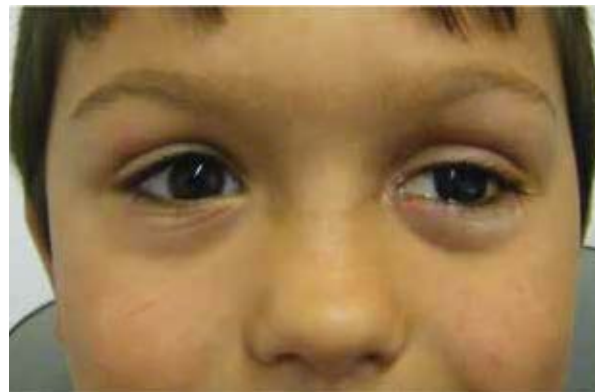

Fig. 2: Unilateral CNLDO.

Symptoms are more often bilateral than unilateral and worsen during respiratory infections^{4,5}. CNLDO may be accompanied by inflammatory signs of the periocular skin, conjunctivitis, and dacryocystitis. Cellulitis is rare. Purulent conjunctivitis is not common, so antibiotic therapy is generally not warranted. The onset of photophobia can indicate that congenital glaucoma is the cause of the watering eye and this must be therefore be considered in the differential diagnosis.

Congenital Dacryocystocele

This results from the combination of nasolacrimal duct obstruction and a competent Rosenmuller valve⁶ and manifests as a swelling in the lacrimal sac, causing a tense bluish mass that can be present at birth or appears within the first 1 to 4 weeks of age. May cause Dacryocystitis or cellulitis with fever (Fig. 3).

Approximately 25 % of patients are affected bilaterally⁷. In 75 % of cases the dacryocystocele extends intranasally to form a nasal cyst in the inferior meatus, which may cause airway obstruction. The differential diagnosis can be confirmed by nasal endoscopic examination and CT or Magnetic resonance imaging⁸. Treatment is with immediate probing in the first few weeks of life. In some less severe cases, 7 to 10 days of observation with conservative measures (lacrimal sac massage) may be successful and can be done before proceeding to surgery⁶.

18. Congenital nasolacrimal duct obstruction (CNLDO)

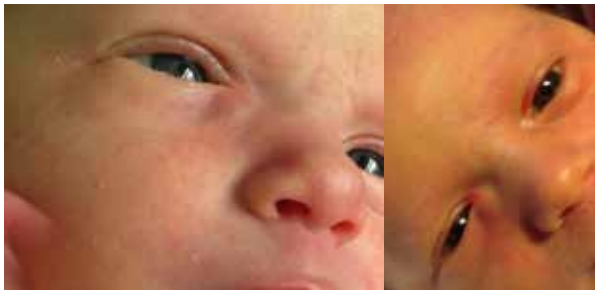

Fig. 3.1: Right dacryocystocele in a newborn one week old.

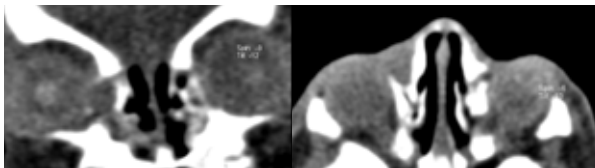


Fig. 3.2: CT of the same child with a right dacryocystocele.



Fig. 3.3: Same child after probing.

Clinical evaluation

A complete eye exam is important to rule out causes of excess tear production, which can be caused by any eye irritant such as trichiasis, foreign body, corneal abrasion, or eyelid malposition.

The application of the Jones permeability test in children is limited and difficult due to a lack of cooperation, but a fluorescein dye retention test can be performed to confirm the diagnosis. The fluorescein dye retention test is performed by applying 1 drop of fluorescein with anesthetic to the conjunctival sac. The residual amount of fluorescein is scored according to residual coloring after 3 to 5 minutes (grading scale from 0 [no dye] to 4 [all dye present]). The test is positive if there is residual fluorescein in the conjunctival sac after 3 to 5 minutes⁶ (Fig.4).

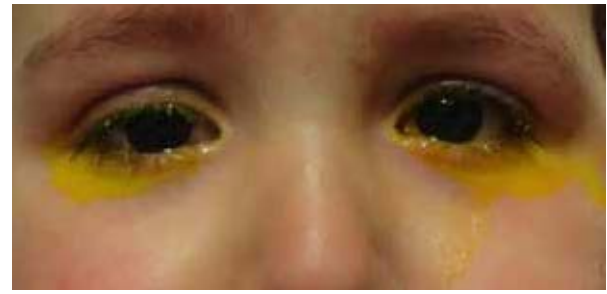

Fig. 4: Positive fluorescein dye test (grading 4).

Nasal examination

Nasal examination is essential to complement the clinical examination, not only in the preoperative assessment but also peri and postoperatively. It can be performed by nasal endoscopy (Fig. 5), but also by direct visualization with a nasal speculum and a light source (fig. 7). It enables the identification of septal deviations, hypertrophy of the cornets (Fig. 6), rhinitis, sinusitis, and polyps, all situations that are detrimental to clinical treatment and factors for a worse prognosis of the surgical result.

Nasal endoscopic-assisted probing to minimize nasal mucosal trauma decreases the chance of creating a false passage and provides the best management option for different congenital variants of nasolacrimal duct obstruction⁹.



Fig. 5: Endoscope and normal nasal anatomy.

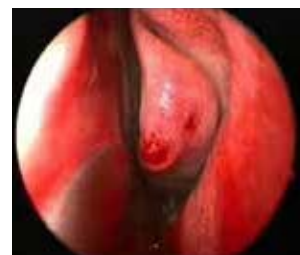

Fig. 6: Hypertrophic cornet.

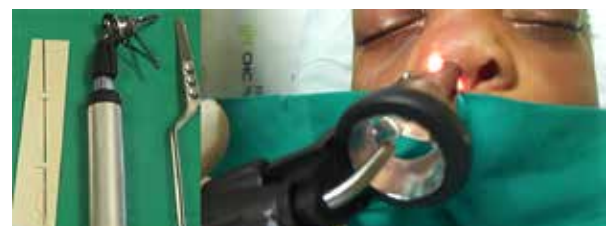

Fig. 7: Nasoscope.

Dacryocystography

Most patients are managed without requiring diagnostic imaging, but when treatment fails or patients have

atypical presentations dacryocystography can guide further management. It is the most commonly used ancillary radiological examination and is simple and safe. Dacryocystography provides an anatomical and semi-functional study to assist in diagnosis, planning, prognosis, and outcome. The procedure can be used to determine the site of the obstruction and the sac size, and to identify intra-sac pathology, especially a lacrimal fistula¹⁰. It can be useful when probing is not effective, and makes it possible to determine the next therapeutic step. Dacryocystography is not a routine examination in children as it requires general anesthesia, but on some occasions it can be therapeutic. The radio-opaque fluid used as a contrast is thick and often breaks the Hasner valve.

This procedure is performed by injecting contrast directly into the lacrimal system via the lacrimal punctum. In the normal pattern, the lacrimal sac and nasolacrimal duct are observed as a continuous small diameter tube. The contrast disappears almost completely within 5 minutes when there is no obstruction.

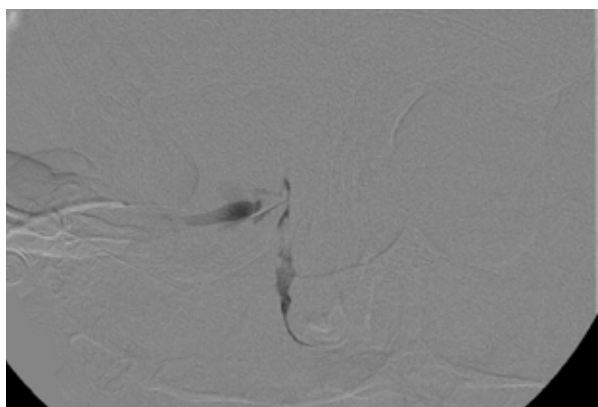


Fig. 8: Dacryocystography, demonstrating an incomplete obstruction.

Management

Conservative treatment

Congenital nasolacrimal duct obstruction spontaneously resolves in more than 90 % of cases during the first year of life with conservative treatment^{1,11}. There is no convincing evidence to show that probing before 12 months offers any advantage in terms of how quickly symptoms are reduced, and it would very likely be performed on considerable numbers of children that would spontaneously remit¹².

Conservative treatment consists of lacrimal sac massage, which was first described by Crigler in 1923¹³. The objective is to increase the hydrostatic pressure and bring about rupture of the membranous obstruction in the nasolacrimal duct (Hasner valve). Parents must be instructed as to how the massage should be performed with the index finger underneath

the inner canthal tendon. Massage of the lacrimal sac is essential to helping spontaneous resolution of nasolacrimal duct obstruction in the first year of life and should be continued until surgery¹⁴. Lacrimal sac massage should be accompanied by nose washing with saline solution.

There is no evidence that antibiotics significantly promote the spontaneous resolution of CNLDO¹⁵, so antibiotic eye drops should be avoided unless there is conjunctival infection. Treatment with antibiotics may also contribute to the increase of antibiotic resistance in children.

Probing

Probing is the next intervention after conservative treatment and after 1 year of age. In the authors view, the only indications for probing before 12 months of age are congenital dacryocystocele and acute dacryocystitis. The optimal timing for probing remains controversial and some authors perform probing as early as 6 months of age¹⁶. Early probing can produce false passages⁶ and iatrogenic canaliculal obstruction can occur.

Spontaneous resolution can occur after 12 months of age, but after that age the success rate of probing efficacy is higher than spontaneous resolution¹⁷. After the age of 2 to 3 years, probing can aggravate the fibrosis and stenosis of the nasolacrimal duct and the effectiveness decreases after 3 years of age¹⁸. As children grow older, more complex and severe obstructions become increasingly common, which in turn reduces the success rate of probing in older children. Therefore, the optimal age range when probing is most effective is between 12 and 24-36 months of age.

Probing must be performed under general anesthesia (laryngeal mask) and can be assisted by endoscopy. The use of nasal endoscopy minimizes the risks of nasal mucosal trauma and of creating a false passage^{9,19}.

Probing Technique (Fig. 9):

- Nasal mucosa must be decongested using 0.25% phenylephrine.
- The upper or lower punctum are dilated with a punctal dilator.
- The lacrimal system is irrigated using a 2 ml syringe and a lacrimal cannula (26G) to confirm the obstruction.
- Probing is conducted on one of the puncta (preferably the upper one) using 00, 000, or 0000 (0 or 1 in older children) Bowman probes. The probe is introduced perpendicularly to the edge of the eyelid to enter the punctum. It is then rotated horizontally and inserted along

the upper/lower and common canaliculus, (palpebral traction in the opposite direction to movement facilitates passage of the probe). When the bone of the lacrimal fossa (hard stop) is felt, the probe is rotated down 90° through the nasolacrimal duct until resistance is felt. Pressure is applied to overcome the resistance.

- The presence of the probe in the inferior meatus is confirmed with the aid of metal-to-metal contact or by nasal endoscopy.
- The patency of the lacrimal system is verified by irrigation with saline solution and sodium fluorescein through the punctum and confirming its presence in the nasopharynx.

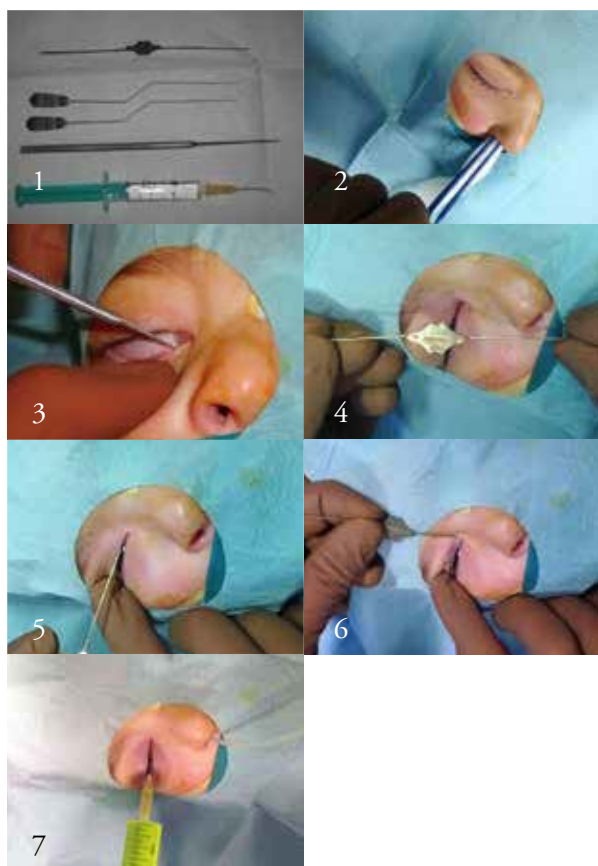


Fig. 9. Probing technique: (1) Material for probing (punctal dilator; Bowman probes; 2 ml syringe and 26G lacrimal cannula); (2) Nasal mucosa is decongested with 0.25%; (3) Dilatation of the lacrimal punctum, (4) 0/00 Bowman probe; (5) The probe is introduced along the upper and common canaliculus until a hard stop is felt; (6) The probe is rotated 90° and introduced through the nasolacrimal duct until resistance is felt at the Hasner valve; pressure is applied to rupture the membranous obstruction; (7) Irrigation with saline solution and sodium fluorescein confirming patency.

When probing fails

After probing failure, additional procedures or a second probing can be performed. Certain factors other than patient age are associated with poorer success rates for probing, including severe symptoms, bilateral

symptoms, canalicular stenosis, atonic sac, and non-membranous nasolacrimal duct obstruction²⁰. A second probing can be repeated after 1 month. There is a low rate of success for a second procedure (25%- 60 %), as ineffective first probing can result in scarring, secondary strictures, and a false passage^{21,22}. The presence of more complex and severe obstructions may be the cause of probing failure, so the second probing procedure is highly likely to be ineffective, too.

Silicone tube intubation

Intubation of the lacrimal system is usually recommended for cases where conservative treatment and probing have failed, with a reported success rate between 80 % and 97 %²³. Intubation can be also used in cases of canalicular stenosis after probing and as a primary procedure in older children and in patients with Down syndrome^{14, 24}. Silicone prevents the formation of granulation-related obstruction around the newly patent tract after the probing procedure²⁰. This procedure was first described by Quickert and Dryden in 1970²⁵.

There are different bicanalicular intubation sets, including the *Bika*, *Crawford*, *Ritleng* ones (Fig. 10,11,12), and self-retaining intubation sets such as *Nunchaku* (Fig. 13), which have a metallic guide inside the lumen and do not need to be retrieved from the nose. An alternative to bicanalicular intubation is monocalicular intubation, with systems like *Monoka*, which are easier to remove but have a greater risk of prematurely falling out and are normally not used in children.

The timing for tube removal remains controversial, but the majority of authors advocate leaving the tubes in for 6 weeks to 6 months^{26, 27}. The recommended time is usually 3 months.

Complications of this procedure include premature removal of the probes, which can lead to re-obstruction, disruption of the lacrimal puncta with the silicone, corneal abrasion from the silicone, and retrieval of the stents from the nose can cause injury to the inferior turbinate and the nasal mucosa. In addition, a second administration of anesthesia is required to remove the tubes²⁸.

Bika intubation technique (Fig.14)

- General anesthesia with a laryngeal mask.
- Nasal mucosa must be decongested using 0.25 % phenylephrine.
- Lacrimal punctal dilatation with a punctum dilator.
- Introduce the metal stent on the canaliculus until the bone is felt, rotate 90°, and slide along the path of the nasolacrimal duct.
- Under endoscopic visualization, catch the metallic guide with a clamp, and pull it outwards

until the silicone tube appears.

- Repeat the procedure in the other canaliculus.
- Attach the silicone tips with 2 to 3 knots, which are retained in the nostril.

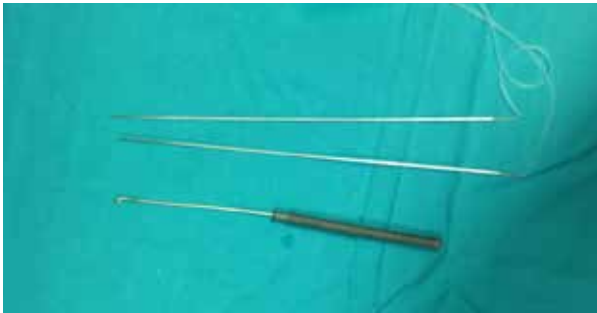

Fig. 10: Bika tubes.




Fig. 11: Crawford tubes and retrieval hook.

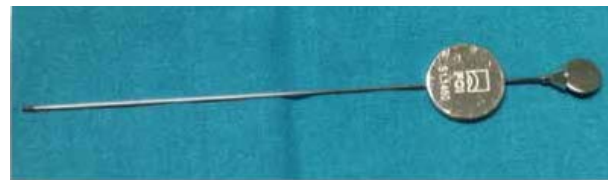

Fig. 12: Ritleng introducer.

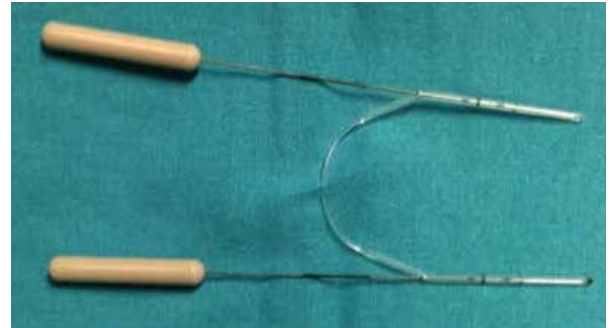


Fig. 13: Nunchaku tubes.

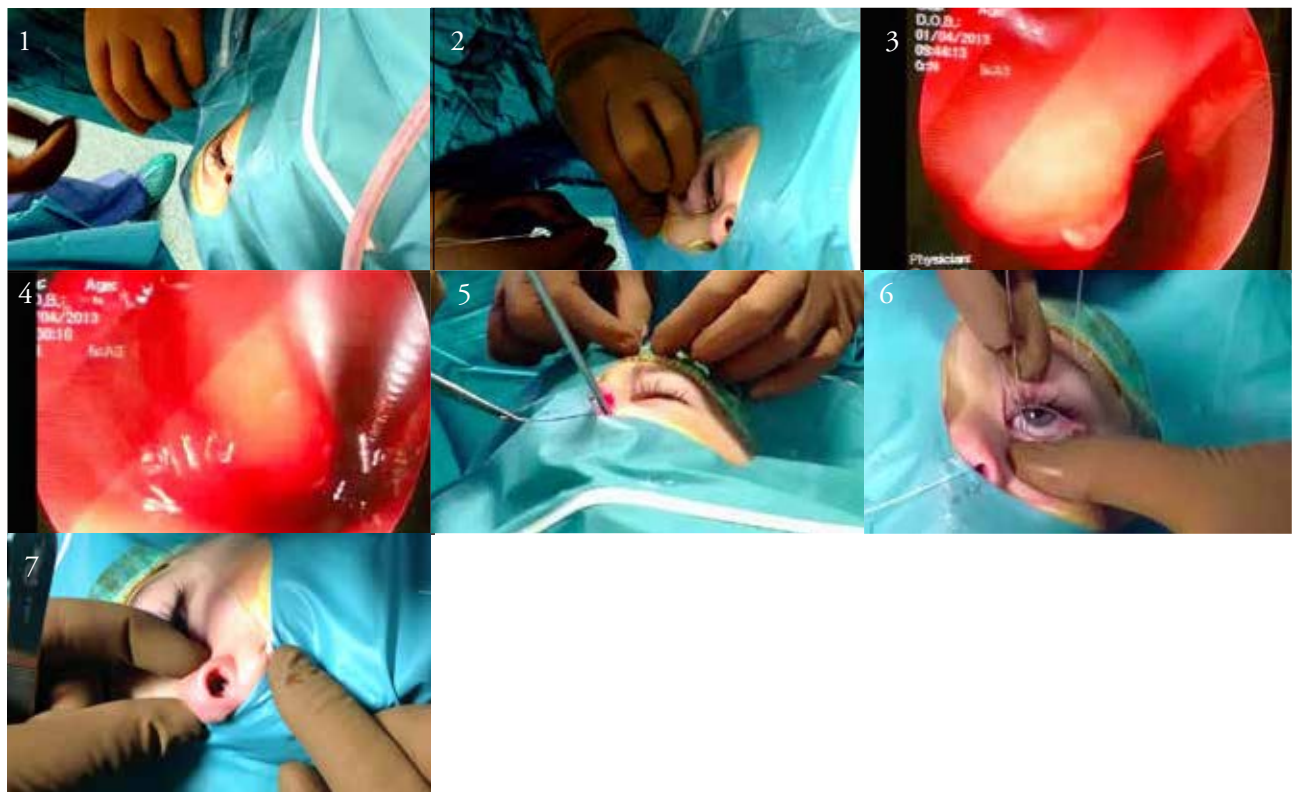


Fig. 14. Bika intubation technique: (1) Introduction of the metal stent on the canaliculus until a hard stop is felt; (2) Rotate 90°, and slide along the nasolacrimal duct, through the nose until the floor of the nose is reached; (3) Endoscopic visualization of the metallic guide; (4) Catching the metallic guide with a clamp; (5) Pulling the metallic guide from the nose; (6) The same procedure is repeated in the other canaliculus; (7) Visualization of the silicone knot in the nostril.

Nunchaku intubation technique (Fig. 15)

- General anesthesia with a laryngeal mask.
- Nasal mucosa must be decongested using 0.25 % phenylephrine.
- Lacrimal punctal dilatation with a punctum dilator.
- Introduce silicone tubes with the metallic guide inside through the canaliculus until reaching the bone wall, rotate 90°, and slide along the nasolacrimal passage until the nasal floor is felt.
- With a clamp, slide the silicone tubing that coats the metallic guide along the lacrimal duct. At the same time, the metallic guide is removed.
- Repeat the procedure in the other canaliculus to create a small silicone loop between the two lacrimal puncta.

Infracture of the inferior turbinate

Infracture of the inferior turbinate is a technique that can be performed in addition to any of the other treatment procedures. The fracture is effective when the inferior turbinate is very close to the outer wall, which makes the inferior meatus too narrow and thus causes occlusion of the ostium of the nasolacrimal duct. Furthermore, the procedure also enables a better

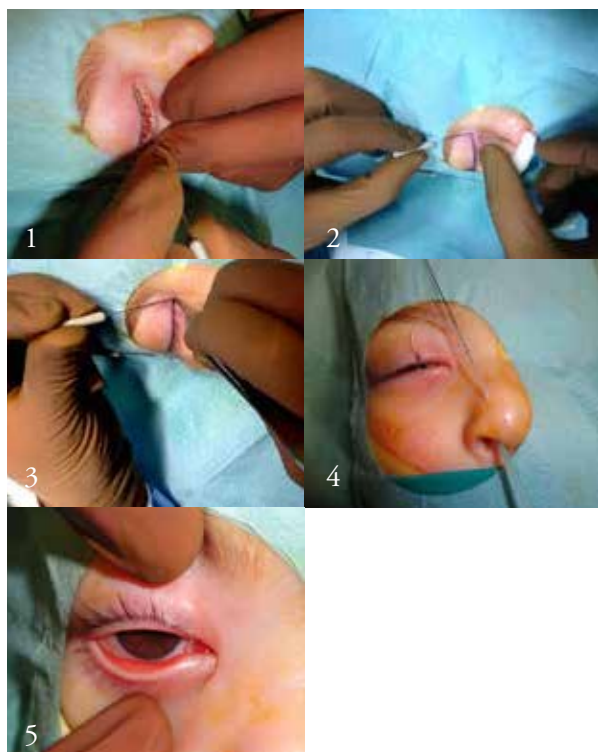

Fig. 15. *Nunchaku* intubation technique: (1) The silicone tube with the metallic guide is introduced through the canaliculus as far as the lacrimal bone wall; (2) Then they are rotated 90° and introduced through the nasolacrimal duct, reaching the nose; (3) A clamp is used to slide the silicone tube along the lacrimal canaliculus, as the metallic guide is removed; (4) The same procedure is repeated in the other canaliculus; (5) View of the silicone loop between the two lacrimal puncta.

view of the inferior meatus during endoscopy, and it should be performed in situations where probing is effective but no fluorescein is visualized in the nose. The original procedure was described by Jones and Wobig²⁹ and is performed by pushing the inferior turbinate medially with a Free's elevator until a sensation of movement is felt. The effectiveness of this procedure can reach 88 % to 100 % in combination with probing and silicone intubation^{26, 30}.

Dacryoplasty

Dacryoplasty, first described by Becker and Berry in 1996³¹, is a procedure in which a balloon catheter is used to dilate the nasolacrimal duct. With this technique the obstructed duct is dilated as opposed to punctured during probing. It is a simple and rapid procedure and avoids several drawbacks of intubation, including the risk of injuring the inferior turbinate and nasal mucosa. It does not require a second administration of anesthesia to remove the tubes. The only disadvantage is its high cost. Success rates for this procedure range from 74 % to 94 %³². This technique is normally used as a second approach




Fig. 16: *OphtaCath*.

in children with CNLDO when probing fails as an alternative to intubation. It is more effective in older children and may be preferred to intubation in children over 3 years of age³³. In adults, this procedure is useful in cases of functional epiphora. The only complication described is nasolacrimal duct injury caused by excessive pressure of the balloon. Two catheter balloons are commercially available, the *Lacricath* and the *OphtaCath* (Fig. 16).

Balloon catheter dilatation Technique (*OphtaCath*) (Fig. 17)

- General anesthesia with a laryngeal mask.
- Nasal mucosa must be decongested using 0.25 % phenylephrine.
- Preparation of the inflation system with 10 cc saline solution.
- Lacrimal punctal dilatation with a punctum dilator.
- The catheter balloon is inserted into the upper lacrimal punctum and passed through the

canaliculus, lacrimal sac, and nasolacrimal duct to the inferior meatus. Positioning should be checked with an endoscope or metal-on-metal contact

- The catheter should be pulled back so that the proximal mark is just visible at the punctum (15 mm from the balloon) to dilate the distal nasolacrimal duct.
- Inflate the balloon to 8 atm (bars) for 2 minutes and then deflate.
- Pull the catheter back so that the second mark is visible at the punctum (10 mm from the balloon) to dilate the proximal nasolacrimal duct. Repeat the inflation to 8 atm (bars) for 2 minutes and then deflate.
- Unlock the inflation device and remove all of the saline solution.
- Remove the catheter balloon once it is completely empty.
- Confirm success with fluorescein.

Dacryocystorhinostomy (DCR)

Dacryocystorhinostomy is the last resort in situations where probing, intubation, and balloon catheter dilatation are not effective and in children with more complex obstructions. The procedure creates a permanent fistula between the lacrimal sac and the

nasal cavity, thereby providing an alternative pathway for lacrimal outflow.

The ideal age at which to perform a DCR in children is controversial. Most physicians prefer to wait until the child is 2 to 4 years old, although there is no formal contraindication for DCR at an earlier age and there seems to be no association with changes in bone maturation^{6, 34, 35}.

External DCR is more commonly performed in children and the success rate is similar to that in adults (83 %-96 %)^{36, 37, 38}. The only downside of this approach is the external skin incision with the possibility of scarring. Typically, the scar is imperceptible in children and adults after 3 to 6 months, so this is not a contraindication to the external technique.

Recently, endonasal DCR has been used increasingly in children, with a success rate of 82 % to 92 %^{35-37, 39, 40}. Cutaneous scars can be avoided, but a pediatric endoscopic procedure is technically difficult because of the small size of the nasal cavity and the close proximity to the brain⁴⁰.

The effectiveness of DCR in children may be poorer because of the rapidly changing and poorly defined anatomy, with a greater risk of synechiae forming between the osteotomy site and septum, and a greater

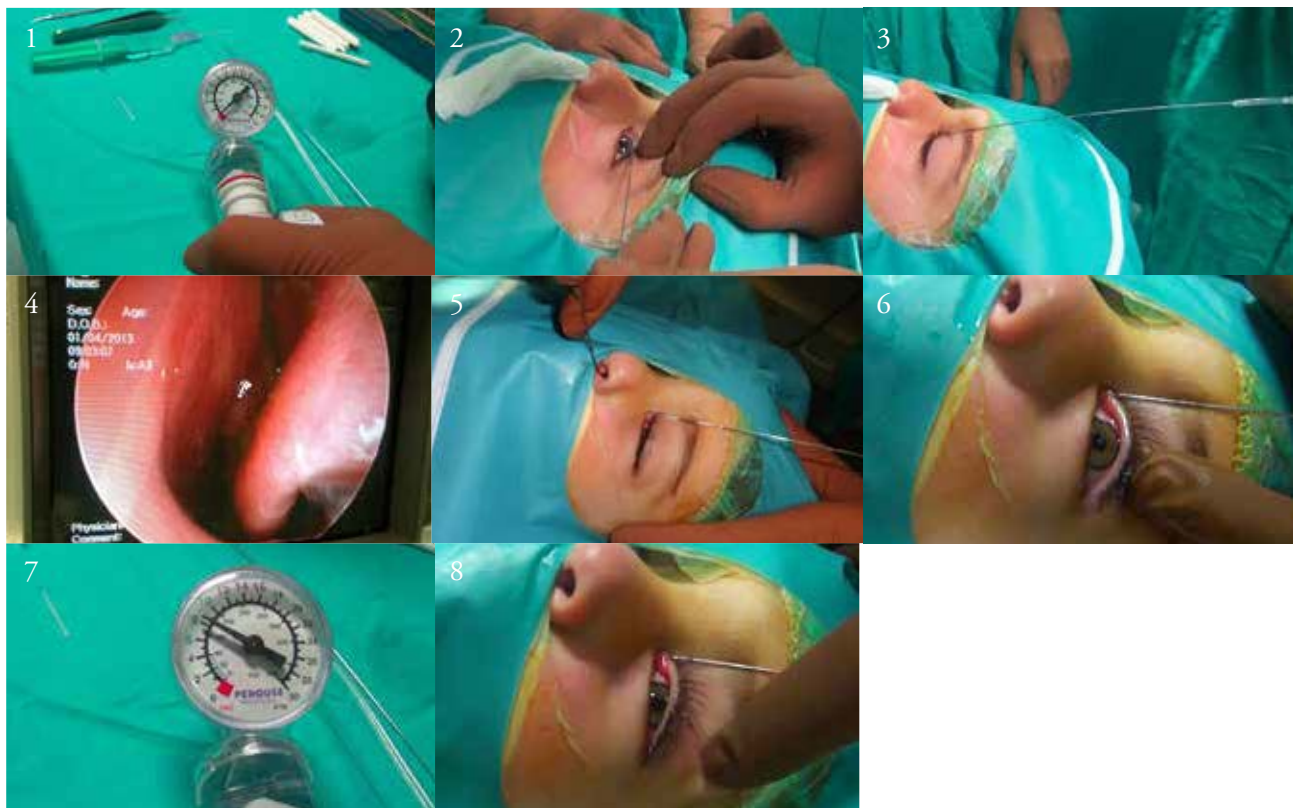

Fig. 17. *OphtaCath* dilatation technique: (1) the inflation system is prepared and tested with 10 cc saline solution; (2) The catheter is inserted into the upper lacrimal punctum and passed through the canaliculus until the lacrimal sac; (3) It is then passed through the nasolacrimal duct until the inferior meatus is reached; (4) Endoscopic view of the catheter position; (5) Metal-on-metal contact to confirm the catheter presence in the nasal cavity; (6) The catheter is positioned so that the proximal mark is just visible at the punctum; (7) The balloon is inflated to 8 atm; (8) Then the catheter is pulled back so that the distal mark is at the punctum, to dilate the proximal nasolacrimal duct.

18. Congenital nasolacrimal duct obstruction (CNLDO)

risk of scar tissue formation. For these reasons, children should be intubated for at least 6 weeks^{36, 41}. Overall, the success of both procedures in children is similar, so choosing which technique to use depends on the preference and experience of the surgeon.

Conclusion

Based on the literature, I propose the following management protocol for the treatment of CNLDO (Fig. 18). Conservative treatment is the best option in the first 12 months of life, as the vast majority of cases resolve spontaneously. When the obstruction persists, a staggered treatment using various techniques should be initiated, starting with probing and ending with DCR.

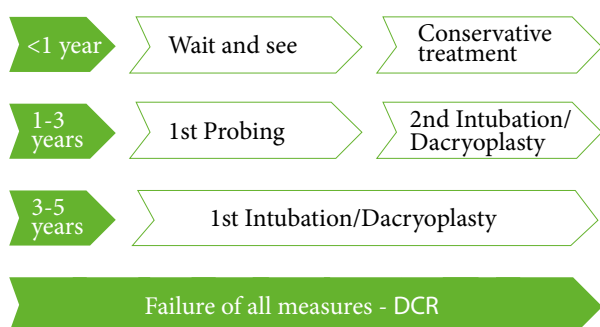


Fig. 18. Management protocol for CNLDO.

Bibliography

- Paul TO. Medical management of congenital nasolacrimal duct obstruction. *J Pediatr Ophthalmol Strabismus*. 1985;22:68-70.
- Yuksel D, Ozer PA. Long-term results of probing guided with soft cannula in children with congenital nasolacrimal duct obstruction. *Jpn J Ophthalmol*. 2014;58:94-9.
- Yuen SJA, Oley C, Sullivan TJ. Lacrimal outflow dysgenesis. *Ophthalmology*. 2004;111:1782-90.
- Kapadia MK, Freitag SK, Woog JJ. Evaluation and management of congenital nasolacrimal duct obstruction. *Otolaryngol Clin North Am*. 2006;39:959-77.
- Arora S, Koushan K, Harvey JT. Success rates of primary probing for congenital nasolacrimal obstruction in children. *J AAPOS*. 2012;16:173-6.
- Olver J. Pediatric lacrimal surgery In: Olver J, ed. *Colour atlas of lacrimal surgery*. Oxford: Butterworth Heinemann; 2002. p. 70-89.
- Cavazza S, Laffi GL, Lodi L, Tassinari G, Dall'Olio D. Congenital dacryocystocele: diagnosis and treatment. *Acta Otorhinolaryngol Ital* 2008;28:298-301.
- Roy D, Guevara J, Santini J, Castillo L. Endoscopic marsupialization of congenital duct cyst with dacryocoele. *Clin Otolaryngol Allied Sci*. 2002;27:167-70.
- Al-Faky YH. Nasal endoscopy in the management of congenital nasolacrimal duct obstruction. *Saudi J Ophthalmol*. 2014;28:6-11.
- Kapadia MK, Freitag SK, Woog JJ. Evaluation and management of congenital nasolacrimal duct obstruction. *Otolaryngol Clin North Am*. 2006;39:959-77.
- Nucci P, Capoferri C, Alfaro R, Brancato R. Conservative management of congenital nasolacrimal duct obstruction. *J Pediatr Ophthalmol Strabismus*. 2007;44:80-3.
- MacEwen CJ, Young JDH. Epiphora during the first year of life. *Eye*. 1991;5:596-600.
- Crigler L. The treatment of congenital dacryocystitis. *JAMA*. 1923;81:21-4.
- Al-Faky YH, Al-Sobaie N, Mousa A, Al-Odan H, Al-Huthail R, Osman E, Al-Mosallam AR. Evaluation of treatment modalities and prognostic factors in children with congenital nasolacrimal duct obstruction. *J AAPOS*. 2012;16:53-7.
- Kim YS, Moon SC, Yoo KW. Congenital nasolacrimal duct obstruction: irrigation or probing? *Korean J Ophthalmol*. 2000;14:90-6.
- Pediatric Eye Disease Investigator Group, Repka MX, Chandler DL, Beck RW, Crouch ER 3rd, Donahue S, Holmes JM, Lee K, Melia M, Quinn GE, Sala NA, Schloff S, Silbert DI, Wallace DK. Primary treatment of nasolacrimal duct obstruction with probing in children younger than 4 years. *Ophthalmology*. 2008;115:577-84.
- Young JD, MacEwen CJ, Ogston SA. Congenital nasolacrimal duct obstruction in the second year of life: a multicentre trial of management. *Eye*. 1996;10:485-91.
- Arora S, Koushan K, Harvey JT. Success rates of primary probing for congenital nasolacrimal obstruction in children. *J AAPOS*. 2012;16:173-6.
- Kato K, Matsunaga K, Takashima Y, Kondo M. Probing of congenital nasolacrimal duct obstruction with dacryoendoscope. *Clin Ophthalmol*. 2014;8:977-80.
- Takahashi Y, Kakizaki H, Chan WO, Selva D. Management of congenital nasolacrimal duct obstruction. *Acta Ophthalmol*. 2010;88:506-13.
- Honavar SG, Prakash VE, Rao GN. Outcome of probing for congenital nasolacrimal duct obstruction in older children. *Am J Ophthalmol*. 2000;130:42-8.
- Pollard ZF. Tear duct obstruction in children. *Clin Pediatr*. 1979;18:487-90.
- Lim CS, Martin F, Beckenham T, Cumming RG. Nasolacrimal duct obstruction in children: outcome of intubation. *J AAPOS*. 2004;8:466-72.
- Casady DR, Meyer DR, Simon JW, Stasior GO, Zolal-Ratner JL. Stepwise treatment paradigm for congenital nasolacrimal duct obstruction. *Ophthalm Plast Reconstr Surg*. 2006;22:243-7.
- Quickert MH, Dryden RM. Probes for entubation in lacrimal drainage. *Trans Am Acad Ophthalmol Otolaryngol*. 1970;74: 431-3.
- Migliori ME, Putterman AM. Silicone intubation for the treatment of congenital lacrimal duct obstruction: successful results removing the tubes after six weeks. *Ophthalmology*. 1988;95:792-5.
- Al-Hussain H, Nasr AM. Silastic intubation in congenital nasolacrimal duct obstruction: a study of 129 eyes. *Ophthalm Plast Reconstr Surg*. 1993;9:32-7.
- Pediatric Eye Disease Investigator Group, Repka MX, Melia BM, Beck RW, Chandler DL, Fishman DR, Goldblum TA, Holmes JM, Perla BD, Quinn GE, Silbert DI, Wallace DK. Primary treatment of nasolacrimal duct obstruction with nasolacrimal duct intubation in children younger than 4 years of age. *J AAPOS*. 2008;12:451-5.
- Jones LT, Wolbig JL. Newer concepts of tear duct and eyelid anatomy and treatment. *Trans Sect Ophthalmol Am Acad Ophthalmol Otolaryngol*. 1977;83:603-16.
- Havins WE, Wilkins RB. A useful alternative to silicone intubation in congenital nasolacrimal duct obstructions. *Ophthalmic Surg*. 1983;14:666-70.
- Becker BB, Berry FD, Koller H. Balloon catheter dilatation

- for treatment of congenital nasolacrimal duct obstruction. *Am J Ophthalmol.* 1996;121:304-9.
32. Tao S, Meyer DR, Simon JW, Zobal-Ratner J. Success of balloon catheter dilation as a primary or secondary procedure for congenital nasolacrimal duct obstruction. *Ophthalmology.* 2002;109:2108–11.
 33. Ceylan K, Yuksel D, Duman S, Samim E. Comparison of two endoscopically assisted procedures in primary surgical treatment of congenital nasolacrimal duct obstruction in children older than 3 years: balloon dilatation and bicanalicular silicone tube intubation. *Int J Pediatr Otorhinolaryngol.* 2007;71:11–7.
 34. Vanderveen DK, Jones DT, Tan H, Petersen RA. Endoscopic dacryocystorhinostomy in children. *J AAPOS.* 2001;5:143-7.
 35. Komínek P, Cervenka S. Paediatric endonasal dacryocystorhinostomy: a report of 34 cases. *Laryngoscope.* 2005;115:1800-3.
 36. Nowinski TS, Fahnagan JC, Mauriello J. Pediatric dacryocystorhinostomy. *Arch Ophthalmol.* 1985;103:1226-8.
 37. Welham RA, Hughes M. Lacrimal surgery in children. *Am J Ophthalmol.* 1985;99:27-34.
 38. Barnes EA, Abou-Rayyah Y, Rose GE. Pediatric dacryocystorhinostomy for nasolacrimal duct obstruction. *Ophthalmology.* 2001;108:1562–4.
 39. Jones DT, Fajardo NF, Petersen RA, Vanderveen DK. Pediatric endoscopic dacryocystorhinostomy failures: who and why? *Laryngoscope.* 2007;117:323–7.
 40. Leibovitch I, Selva D, Tsirbas A, Greenrod E, Pater J, Wormald PJ. Paediatric endoscopic endonasal dacryocystorhinostomy in congenital nasolacrimal duct obstruction. *Graefes Arch Clin Exp Ophthalmol.* 2006;244:1250-4.
 41. Choung HK, Khwarg SI. Selective non-intubation of a silicone tube in external dacryocystorhinostomy. *Acta Ophthalmol Scand.* 2007;85:329-32.

19. External Dacryocystorhinostomy

Nádia Lopes, Guilherme Castela

Introduction

With the external dacryocystorhinostomy (DCR), an alternative pathway is created between the lacrimal sac and the nose. This technique has been practiced for over two millennia, however, modern lacrimal surgery began in 1904, when Toti described a surgery involving an external incision, a bony ostium, a medial sac excision and canalicular probing. Dupuy-Dutemps and Bourget introduced the technique of anastomosing lacrimal and nasal mucosal flaps, which remains the basis of the modern external DCR.

Indications for external DCR:

- primary acquired nasolacrimal duct obstruction;
- secondary acquired nasolacrimal duct obstruction (dacryolithiasis, nasal or sinus pathology, midfacial traumatism or surgery);
- persistent congenital nasolacrimal duct obstruction, unresponsive to previous therapies;
- functional epiphora secondary to nasolacrimal stenosis;
- chronic dacryocystitis.

Contraindications for external DCR:

- active dacryocystitis,
- tumor of lacrimal sac.

Anesthesia Considerations

The surgery is performed under local anesthesia with sedation or general anesthesia.

The local anesthesia involves blocking the infratrochlear, infraorbital and ethmoidal anterior nerves, local infiltration and intranasal packing (lignocaine 4%/ xylometazoline 0.5%). This approach is advantageous in the elderly and in patients with significant comorbidities because general anesthetic poses a greater risk.

With general anesthesia, endotracheal intubation and throat pack protects against blood aspiration, but the laryngeal mask can be used when the surgeon is experienced as there is less risk of bleeding. The use of remifentanyl, an ultra-short acting synthetic opioid, gives better control of blood pressure, and reduces operative bleeding.

Surgical Technique

Skin incision

The skin incision is curvilinear, 10-12 mm long, 3-4 mm from the medial canthus along the anterior lacrimal crest (Fig. 1a). Other skin incisions have been described that improve the aesthetic outcome. In a study published by Ekinici et al., the “W” incision was found to leave a smaller scar than the classical vertical incision (Fig. 1b). Also, the subciliary incision, which starts just under the medial canthal tendon and is placed in the tear trough, results in a smaller scar after an external DCR (Fig. 1c).

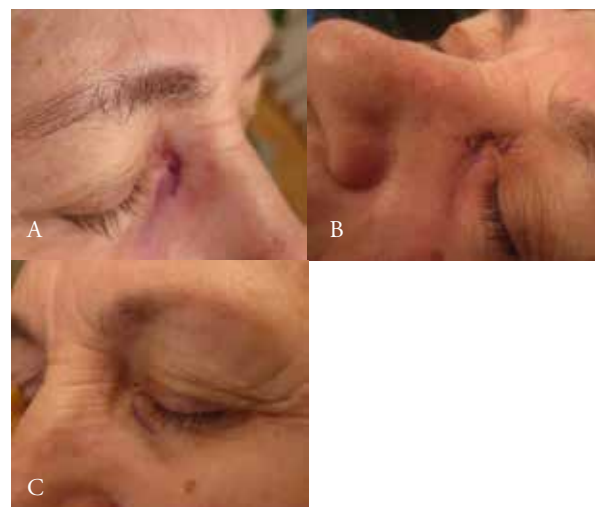

Fig. 1. a) skin incision along the lacrimal crest, b) the “W” incision, c) the subciliary incision.

Tissue Dissection

The orbicularis muscle is dissected as far as the periosteum (Fig. 2). The angular vessels should be avoided in this phase. The assistant retracts the orbicularis muscle using a squint hook. A periosteal elevator is used to reflect the periosteum (anteriorly along the nose and posteriorly to elevate the lacrimal sac in the lacrimal fossa (Fig. 3)) and the anterior limb of the medial canthal tendon.

Osteotomy

The osteotomy should be large, 12-18 mm in diameter (Fig. 4). No bone should be left within

19. External Dacryocystorhinostomy

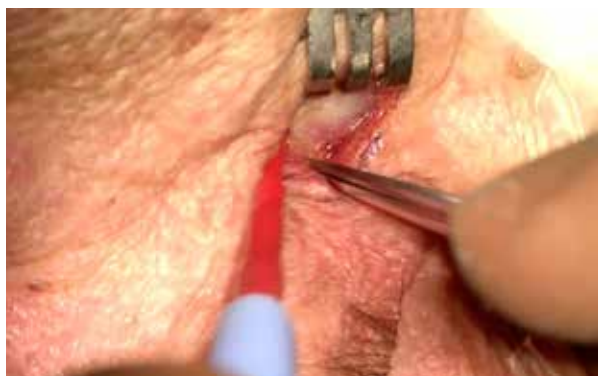

Fig. 2 Tissues dissection until the periosteum.

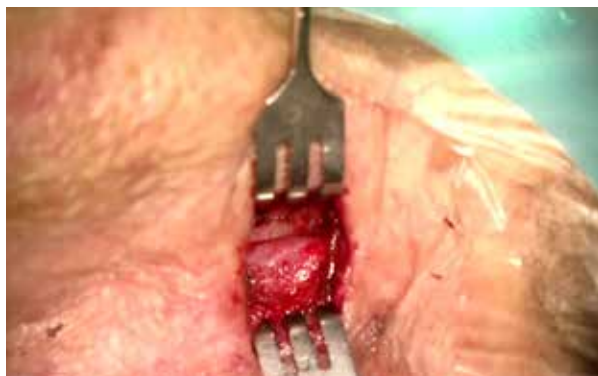

Fig. 3 Exposition of the lacrimal sac.

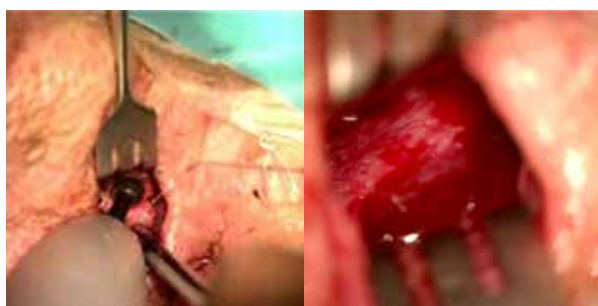


Fig. 4 A large osteotomy is done.

5 mm of the common canaliculus. Bone can be removed with a Kerrison rongeur or a drill, starting at the junction between the papyracea lamina of the ethmoid and the lacrimal bone and extended:

- anteriorly, up to 10 mm in front of the anterior lacrimal crest;
- posteriorly, an anterior ethmoidectomy should be performed;
- inferiorly, the bone removal should be directed to the level of the inferior orbital rim;
- superiorly, 2 mm above the medial canthus.

Flap Formation

The flap sac is first created:

- The lacrimal puncta are dilated (Fig. 5a).
- A bowman probe (usually 00 or 1) is passed through the inferior lacrimal punctum and is

used as a guide during the incision. The injection of a viscoelastic agent, through the upper lacrimal punctum, into the lacrimal sac increases the tension in the sac wall and facilitates its incision.

- An “H”-shaped incision is made in the medial face of the wall with a #11 blade or a #65 Beaver blade. The horizontal incision should be as posterior as possible to create a large anterior flap and a small posterior flap (fig. 5b).
- The dissection is performed until the Bowman probe tip is seen. In cases of chronic dacryocystitis, a multilayered lacrimal sac might be found.
- The internal opening of the common canaliculus should be examined. When a soft tissue obstruction is identified, the membrane is excised around the canaliculus. Likewise, stones should be removed in cases of dacryolithiasis (Fig. 5c).
- The posterior flap is removed.

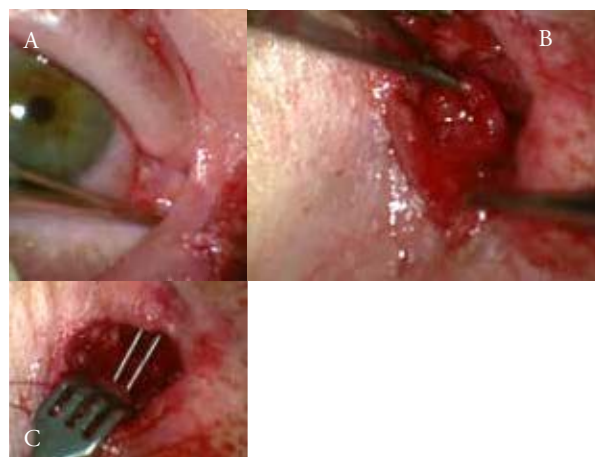

Fig. 5 a) The lacrimal puncta are dilated, b) the lacrimal flap is performed, c) The internal opening of the common canaliculus should be examined.

The nasal mucosal flap is then performed:

As with the lacrimal flap, an H incision is made, with the anterior flap larger than the posterior one, which is excised (Fig. 6).

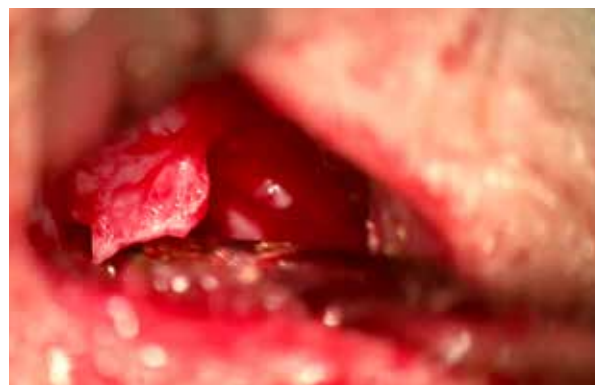


Fig. 6 A nasal mucosa flap is performed.

The use of antimetabolites

There are no established indications or treatment regimens for antimetabolites (mitomycin C and 5-fluorouracil). Several studies have been carried out, with no consensus on their effectiveness. The authors use mitomycin C (0.5 mg/ml, for 10 minutes), only in reintervention procedures.

Bicanalicular intubation

The use of silicone tubes for external DCR is controversial. Some surgeons only use it in cases of canalicular stenosis, failure of previous procedure and insufficient flap formation, because the tubes can cause complications such as corneal and punctal erosions and pyogenic granuloma formation. The authors use silicone tubes since they act as a mechanical barrier and prevent fibrosis formation in the newly created lacrimal system.

An alternative to the bicanalicular intubation, is the monocalicular intubation with the mini-monoka tube (S1-1500u, FCI Ophthalmic). A study by Detrokis et al, showed that the monocalicular intubation in external DCR is safe and effective. The technique may have advantages over bicanalicular intubation such as, easier insertion and removal, easier probing and irrigation through the unintubated canaliculus and lower risk of migration and punctal and corneal damage.

Flap anastomosis

In conventional external DCR, anastomosis of both the anterior and posterior flaps is performed. The authors prefer excising the posterior flaps and suspending the anterior flaps (Fig. 7a and b).

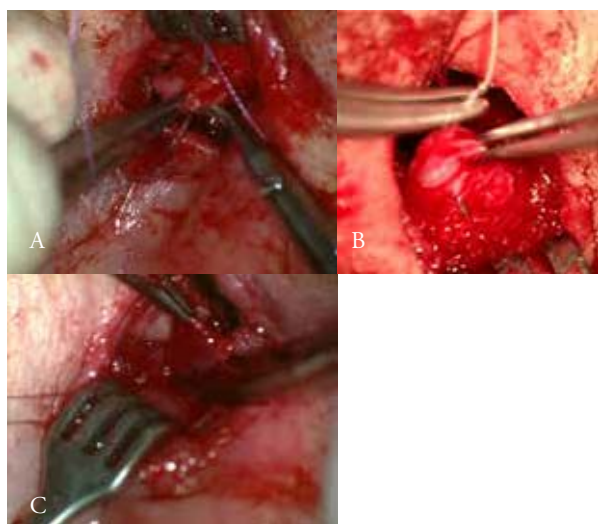


Fig. 7 Flap anastomosis, the nasal mucosa flap (a) and the lacrimal flap (b) are sutured to the orbicularis muscle (c) excision of the posterior flap.

Excision of the posterior flap simplifies the surgery and does not adversely affect the outcome of the

surgery (Fig. 7c). A randomized study by Serin et al. compared sutured and excised posterior flaps and found a success rate of 93.75 % and 96.67 %, respectively.

The anterior suspended flap was first described by Baldeschi et al. With this technique the anterior flap is sutured to the orbicularis muscle (with a 6-0 polyglactin suture), thus preventing it from adhering to the deeper tissues.

Wound closure

The orbicularis muscle is closed with a 6-0 polyglactin suture and the skin with a 6-0 polypropylene suture (Fig. 8).

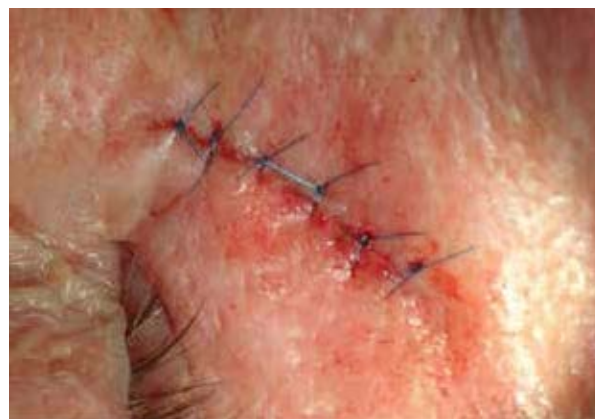

Fig. 8 The skin is closed with a 6-0 polypropylene suture.

Post-operative care:

- nasal package in cases of active hemorrhage;
- the patient must be seated, in the first post-operative hours to reduce nasal venous congestion and they should avoid nose-blowing for the first week;
- systemic antibiotic (e.g. cefuroxime);
- eye-drops (antibiotic + steroid);
- nasal steroid;
- application of a steroid ointment to the wound;
- silicone tube removal after 4 weeks.

Complications

Intraoperative

1. Hemorrhage

- This complication can be mitigated by adopting measures such as:
 - head up position;
 - hypotensive anesthesia;
 - incision infiltration with lidocaine/adrenaline;
 - nasal pack soaked with decongestant solution (epinephrine 1/1000);
 - careful handling and cauterization of soft tissues.

2. Cerebrospinal fluid (CSF) leakage

- This is a rare occurrence after ophthalmic

19. External Dacryocystorhinostomy

surgery. In a study published by Dolman et al, the incidence of this complication after a dcr procedure was 0.04 %. A fracture of the cribriform plate caused by rotational forces during the rhinostomy may result in this complication.

- The symptoms of CSF leak are rhinorrhea, which can be associated with headache or meningitis.
- Most cases resolve spontaneously with bed rest and elevation of the head.
- Antibiotic prophylaxis with drugs that pass through the blood-brain barrier (e.g. ceftriaxone) is recommended.

3. Canalicular damage

This complication is avoided by using a non-traumatic stent and probe manipulation.

Postoperative

1. Drainage Failure

The most common causes of failure are: fibrosis of the rhinostomy; canalicular obstruction; inappropriately sized and/or localized ostium; synechiae between the ostium and the middle turbinate or the nasal septum; incomplete opening of the lacrimal sac ("sump syndrome"); granuloma formation at the ostium, and severe septal deviation.

2. Hypertrophic Scar

- A study published by Sharma et al. showed a high degree of satisfaction with the external scar. However, an improper incision placement (an anterior incision on the side of the nose or a posterior incision along the concavity of the medial canthus), excessive diathermy on the wound or a history of keloid formation can predispose to an unaesthetic scar.
- If a hypertrophic scar develops, measures such as intensive massage, continued application of steroid ointment, intrascar steroid injection with triamcinolone (0.25 to 0.50 ml) or application of silicone gel (Kelo-cote®) can be used. If scarring persists or epicanthus develops, a scar excision or a Z-plasty may be necessary.

3. Wound infection

Soft tissue infection occurs in approximately 8 % of patients after external DCR. A 5-fold reduction in this rate can be achieved with routine administration of antibiotics after surgery.

4. Orbital Emphysema

- Laryngospasm following anesthesia, blowing the nose and the Valsalva maneuver can cause air to enter the subcutaneous tissues, through the ostium.

- Evolution is usually benign with spontaneous resolution after 2-3 weeks. Treatment includes observation. However it can cause ischemic optic neuropathy or a central retinal artery occlusion. When these complications are suspected, underwater drainage of air using a 24-gauge needle or lateral canthotomy and cantholysis should be performed.

Conclusion:

Over time, other techniques, including endonasal and radiofrequency DCR, have emerged. Nonetheless, the external DCR procedure remains the gold standard for relief of epiphora due to chronic dacryocystitis and nasolacrimal duct obstruction, with a success rate of 80-96 %. However, external DCR is not an easy surgical procedure and a good knowledge of the technique is essential to prevent complications.

Bibliography:

1. Cohen A, Mercandetti M, Brazzo B. The Lacrimal System. Springer Ed. 2015
2. W Riad, I Chaudry. Anaesthesia for DCR. Trends in Anaesthesia and critical care. 2010. Vol21, issue 4, pages 180-183
3. Ekinci M1, Çağatay HH, Oba ME, Yazar Z, Kaplan A, Gökçe G, Keleş S. The long-term follow-up results of external dacryocystorhinostomy skin incision scar with "W incision" Orbit. 2013 Dec;32(6):349-55.
4. Dave TV, Javed Ali M, Sravani P, Naik MN. Subciliary incision for external dacryocystorhinostomy. Ophthal Plast Reconstr Surg. 2012 Sept-Oct;28(5):341-5
5. KOSTAS G, BOBORIDIS, MD, CATEY BUNCE, DSC, AND GEOFFREY E. ROSE. Outcome of External Dacryocystorhinostomy Combined With Membranectomy of a Distal Canalicular Obstruction. Am J Ophthalmol 2005;139:1051-1055
6. Gül A, Duran M, Can A, Öztürk I, NARitürk. The Effect of Silicone Tube Intubation in External Dacryocystorhinostomy. Acta Medica Anatolia Volume 3 Issue 1 2015.
7. Serin D, Alagöz G, Karsloğlu S, Celebi S, Kükner S. External dacryocystorhinostomy: Double-flap anastomosis or excision of the posterior flaps? Ophthal Plast Reconstr Surg. 2007 Jan-Feb;23(1):28-31.
8. Baldeschi L, Nardi M, Christoph R Hintschich, Koornneef L. Anterior suspended flaps: a modified approach for external dacryocystorhinostomy. Br J Ophthalmol 1998;82:790-79
9. Badilla J, Dolman P. Cerebrospinal Fluid Leaks Complicating Orbital or Oculoplastic Surgery. JAMA Ophthalmology. December 1, 2007, Vol 125, No. 12 FREE
10. Sharma V, Martin PA, Bengner R. Evaluation of the cosmetic significance of external dacryocystorhinostomy scars. American Journal of Ophthalmology. Volume 140, Issue 3, September 2005, Pages 359.e1-359.e7
11. Tang YW. Intra- and postoperative steroid injections for keloids and hypertrophic scars. Br J Plast Surg. 1992 Jul;45(5):371-3.
12. Walland MJ¹, Rose GE. Soft tissue infections after open lacrimal surgery Ophthalmology. 1994 Mar;101(3):608-11
13. Shah N. Spontaneous subcutaneous orbital emphysema following forceful nose blowing: Treatment options. Indian J Ophthalmol. 2007 Sept-Oct; 55(5): 395

20. Endonasal Dacryocystorhinostomy

Rui Tavares, Vera Soares, Sara Marques

In this chapter we will go through the management of patients with acute or chronic dacryocystitis, epiphora or discharge from nasolacrimal duct obstruction, acquired or congenital, using an endonasal endoscopic approach.

Endoscopic DCR technique and postoperative management will be covered in depth.

Historical overview

Caldwell initially described endonasal DCR in the 19th century,¹ a few years before Tori described the external DCR procedure.² Over 120 years ago Caldwell used an electric drill to resect the medial wall of the nasolacrimal duct from the inferior turbinate up to the lacrimal sac. However, poor visualization of the operation site and the progressively improving results achieved with the external approach led to a decline in popularity of the endonasal procedures.

As rigid endoscopes and endoscopic sinus surgery became popular in the late 1980's there was renewed interest in endonasal DCR, often performed together by ENT and Oculoplastic surgeons. Especially in the early years, as would be expected of a new and developing technique, the success rates tended to be lower than those for external approach DCR. However, with time and the development of better endoscopes and surgical instruments, together with improved surgical techniques, the success rates came to match those of the external procedures.

In the mid-1990s, laser endoscopic DCR was promoted but the results were disappointing, mainly because the technique created a small opening into the posterior inferior lacrimal sac through the thin lacrimal bone. It is currently well recognized in the literature that a small ostium does not achieve the same success rates as a large opening of the lacrimal sac.³

There are several advantages to the endonasal endoscopic approach. Apart from the obvious lack of facial scar, this procedure allows better lacrimal pump function, direct viewing of the operation site, the possibility of dealing with endonasal pathology at the same time, lower operative time, postoperative inactivity and morbidity. Thanks to Wormald PJ's^{4,5}

work on powered endoscopic surgery, we now know it is possible to achieve osteotomy sizes similar to those achieved with the external technique.

Indications for the endoscopic technique are growing and evolving and include lacrimal sac abscess and acute dacryocystitis,⁵ post chemotherapy and radiotherapy nasolacrimal duct obstruction, and common canalicular obstruction.

In our experience, depending on patients' clinical status, this is a day-care procedure, even considering that for most patients we prefer general anesthesia with controlled hypotension.

Assessment of patients for surgery

The assessment of patients for EN-DCR is addressed elsewhere in this book and focuses on the nature and location of the obstruction. By probing and syringing the patient, the key point is to rule out canalicular disease, feeling a "hard stop" (Fig. 1).

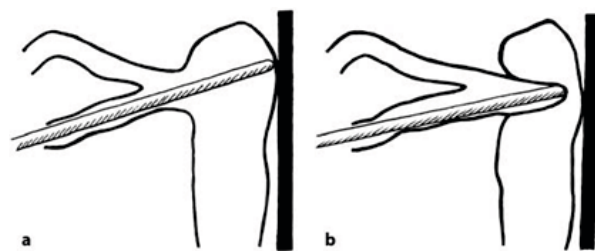


Fig. 1: a - Hard stop; b - Soft stop (Adapted from Kom. nek P, Červenka S, Müllner K (2003). The lacrimal diseases. Diagnosis and treatment. Maxdorf, Prague.

In some cases a dacryocystography or a CT scan or both should be requested to better understand the clinical case and plan the surgical procedure. This is so in post-traumatic obstruction, post-surgical or atypical cases.

With this particular technique it is crucial to evaluate patients endonasally, to be prepared for possible troublesome anatomies and to treat any nasal pathology that might be present. Ali MJ et al. reported a 47% rate of associated endonasal procedures during a DCR, in particular septoplasty, solo or associated with turbinoplasty.⁶ Others report lower rates.⁷ Some authors report the safety and effectiveness of limited septoplasty by trained ophthalmologists.⁸ These

procedures provide additional access to the lacrimal region and can facilitate successful outcomes. In any case the endonasal examination should be the rule in every lacrimal patient.

EN-DCR technique

Despite the number of DCR techniques described, they all share the same purpose, which is to create a communication between the lacrimal sac and the nasal cavity, bypassing the obstructed nasolacrimal duct and allowing free tear drainage to the nose.

A good understanding of the nasal anatomy is crucial before starting this technique. Recognition of familiar landmarks inside the nose is very helpful (Fig. 2), especially when dealing with revision cases.

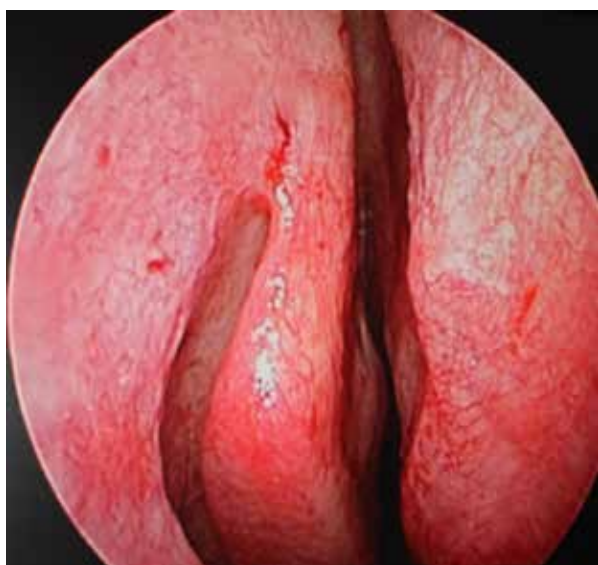


Fig. 2: Normal anatomy of a right nasal fossa.

The standard positioning of the patient is in dorsal decubitus with inverted Trendelenburg, the head slightly turned right and with the chin down. The surgeon stands on the right side of the patient, regardless of the side being operated on. The procedure is performed under general anesthesia with propofol and remifentanyl or deep sedation.

After setting the table with standard FESS instruments, up- and down-biting 90 and 135 degrees Kerrison punches and a 0 or 30 degrees, 175-180 mm long, 4 mm diameter nasal endoscope, the next step is to prepare the nasal cavity for the surgery. Phenylephrine soaked cottonoids are placed near the middle meatus and a mixture of lidocaine 1% with epinephrine 1:100,000 is used to infiltrate the nasal mucosa of the middle turbinate head and axilla and the maxillary line.

A posteriorly based U-shaped flap is created using a long Colorado™ needle (Stryker Leibinger, Freiburg, Germany). It's helpful to keep an aspiration around the

nasal vestibule in order to keep the surgical field clear. This incision begins 5 mm above the axilla of the middle turbinate and extends anteriorly for 8 to 10 mm, then downwards for 10 mm and then posteriorly again. A Freer elevator - blunt side - (the sharp side can be used to incise the mucosa if you don't have a Colorado™ needle) is then used to expose the maxillary line and posterior to that, up to the lacrimal bone. Many mucosal flap shapes have been described: posteriorly, inferiorly and, superiorly based flaps; in an L, in a U. We sometimes change our flap shape, but the posteriorly based classic flap is the rule. Trimarchi⁹ stated in 2009 that the anastomosis between the lacrimal and nasal flaps is the most important aspect of the surgical procedure as it plays a key role in preventing surgical failure. Other authors, however, report similar success rates without mucosal flaps.¹⁰

A 135 degrees up-biting 1 or 2 mm Kerrison punch is used to begin the osteotomy and expose the lacrimal sac (Fig. 3).

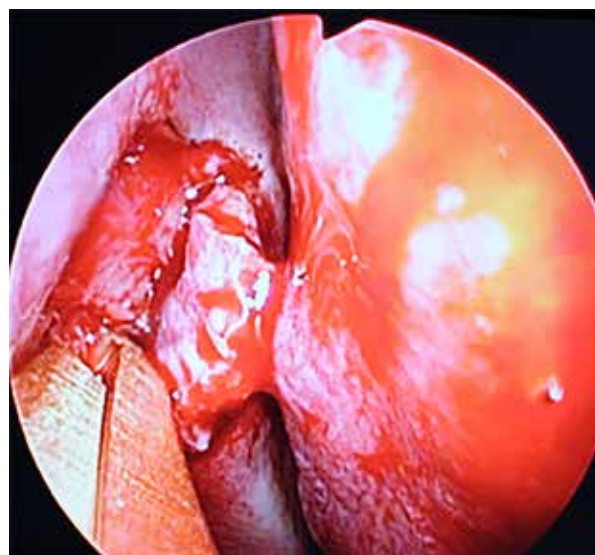


Fig. 3: A Kerrison punch is used to make the osteotomy.

Some authors prefer to use the drill to perform the osteotomy or at least to enlarge it up where the bone becomes thick and is not amenable to punch removal. Wormald PJ¹¹ popularized the expression “powered mechanical endoscopic DCR” and reported success rates that rival those of the external DCR.¹² When the thick or hard frontal bone stops us from getting an optimal lacrimal sac exposure, we usually use a shaver drill (Diego elite™) to finish our osteotomy.

When the lacrimal sac is well exposed in the nasal cavity (Fig. 4), it's time to incise it. At this point we have found it very helpful to use the lacrimal probe to check the position of the common canaliculus, and to create some tension to ease the lacrimal sac incision.

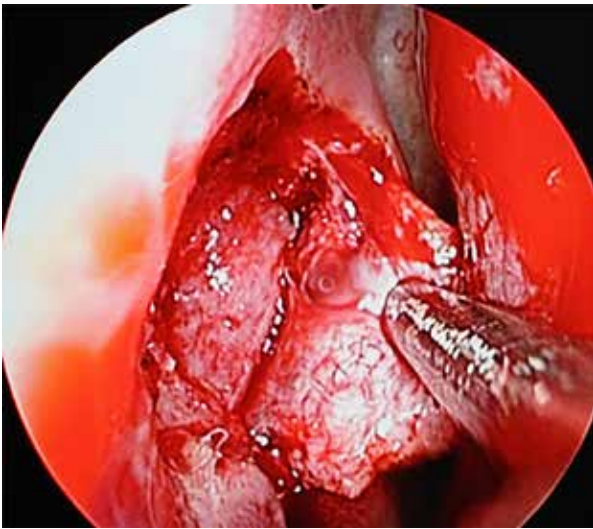

Fig. 4 – lacrimal sac is well exposed.

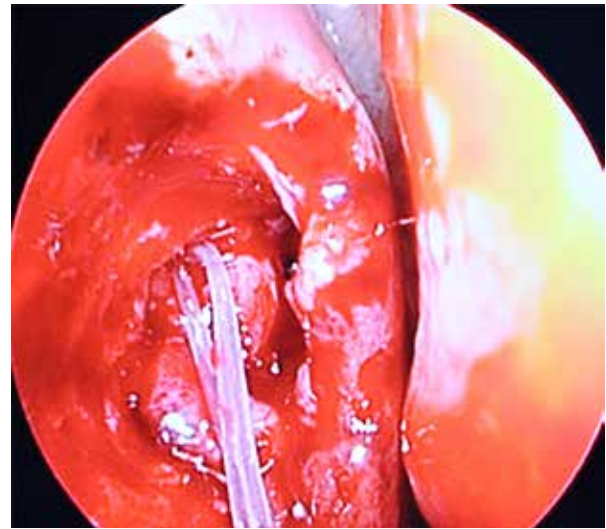


Fig. 5: Bicanalicular silicone stent in place inside the nasal cavity.

A Bowman probe is then used to reach and tent the medial sac wall and a sickle knife or a 2.75 mm keratome is used to open it. It is possible to create anterior and posterior flaps, but we usually incise the sac anteriorly, to create a posteriorly based flap. The advantages of the H shaped flap is said to be a better marsupialization of the sac and the possibility of covering any exposed bone anterior to the osteotomy, thus minimizing granulation tissue formation. We usually take the osteotomy to our mucosal flap limit, so we don't find this necessary.

After the first vertical incision, a big posterior based flap is created with two single cuts superiorly and inferiorly in the medial wall of the sac, using nasal scissors. The interior of the sac is now exposed, and the common canaliculus emergence should be easily seen; if necessary, membranes and bridles can be removed. The medial wall of the sac is totally marsupialized in the nose, and trimmed, like the mucosal flap, to achieve contact between the lacrimal and nasal mucosa.

We use silicone stenting as a rule, for a maximum of 6 weeks (4 to 6 weeks). We find the stents useful for the follow up, as we find it is easier to remove the crusts and to carry out endoscopic assessment, although some authors find there is no advantage.¹³ After the DCR procedure is completed, a silicone bicanalicular stent is passed through the new ostium under endoscopic control. Both ends of the silicone stent are secured with several square knots. (Fig. 5)

At the end of the surgery a hemostasis revision is performed along with a revision of the flaps position. No packing or dressing is needed, although, we use a piece of NasoporTM between the nasal concha and the septum if significant bleeding as occurred and/or is expected to occur postoperatively.

Post-operative care

Postoperative care is considered key to achieving a good surgical result.

As a rule, the patients undergo a short course of systemic steroids for 5 days prior to the day of the surgery (if no other nasal pathology is diagnosed and no other nasal procedure is planned; otherwise, this pre-op medication is adapted to the particular situation). In the OR, we use a prophylactic antibiotic (usually cefazolin 2 g, 1 hour before the procedure) and a single dose of IV steroids, such as methylprednisolone.

After the procedure, the patient stays on antibiotic and steroid eyedrops for 10 days; on the first day after surgery, we introduce nasal irrigation with saline and nasal steroid spray.

The patient should not blow his nose for ten days to prevent periorbital ecchymosis and emphysema, but the nasal irrigation is mandatory.

The first post-op visit is about 10-12 days after surgery. Nasal endoscopic control is performed at every visit, after topical nasal anesthesia and decongestion. At this first visit, nasal crusts are removed as well as any granulation tissue, leaving the neo-ostium completely free and allowing the stents to move easily inside the nose along with eyelid movements.

Silicon stents are removed 4-6 weeks after surgery, under endoscopic control. Any residual granulation tissue is removed. The patients are kept on nasal steroid therapy for 2 months, at least.

Follow-up control with patient symptoms' assessment, neo-ostium endoscopic control, fluorescein dye test and irrigation is performed at 3, 6 and 12 months post-op. Surgical success is defined by neo-ostium size greater than 2 mm, a positive fluorescein dye test in less than 10 seconds and the fact that the patient stays

asymptomatic (Munk scale 0).

Revision cases

Poor visualization, suboptimal instruments, inadequate osteotomy size and location, limited understanding of intranasal anatomy, poor marsupialization of the lacrimal sac and inability to correct concomitant intranasal pathology, all contribute to surgical failure. In almost all cases the failure of the primary surgery is due to scar and fibrosis formation, which leads to reclosure of the new nasolacrimal stoma and osteotomy site with granulation tissue.

It is important to address the causative factors mentioned above when dealing with revision cases.

Certain goals are crucial:

- clear and thorough understanding of intranasal anatomy, as the landmarks may not be so clear;
- efficient osteotomy to allow complete exposure of the lacrimal sac remnants;
- careful excision of all fibrotic tissue;
- complete incision and marsupialization of the lacrimal sac.

Therefore EN-DCR is the best technique to deal with failure cases and it is considered safe and effective, particularly after unsuccessful external DCR.¹⁴

The importance of using antifibrotics such as mitomycin C in revision cases is widely accepted nowadays. Mitomycin C (MMC) is an antibiotic isolated from *Streptomyces caespitosus* by Wakaki et al. in 1958.¹⁵ It inhibits the synthesis of DNA, cellular RNA, and protein by inhibiting the synthesis of collagen by fibroblasts, thus preventing scar tissue formation, and has been used over the last few years in a number of ophthalmic procedures including trabeculectomy, pterygium surgery, refractive surgery to prevent haze, external DCR, endoscopic DCR and endocanalicular laser-assisted DCR.

No severe complications from MMC use have been described, except for poor skin cicatrization if direct contact is made; no side effects have been reported for the mucosal utilization.

Several papers point out that it should be used in primary external DCR procedures thus leading to improved success rates,¹⁶ as well as in EN-DCR dealing with revision cases.¹⁷ Electron microscopy has recently demonstrated¹⁸ how 0.02% MMC application for 3 minutes changes nasal mucosa, with significant and distinct ultra-structural changes involving the epithelial, glandular, vascular, and fibrocollagenous tissues. This study found profound changes within fibroblasts with intracellular edema, pleomorphic and vesicular mitochondria, dilated smooth and rough endoplasmic reticulum, and chromatin condensation.

We use 0.02% MMC for 5 minutes at the end of the procedure in every revision case, and recently in every external DCR.

Thanks to this careful approach, or/and to MMC use, our revision success rates are similar to the primary ones, making EN-DCR revision a good choice in failures with distal obstruction.

Pediatric patients

As stated elsewhere, children with either congenital or acquired nasolacrimal duct obstruction (NLDO) are dealt with in a stepwise approach with massage, probing, silicone intubation and/or balloon dacryoplasty and DCR.

Fortunately, over 90% of congenital NLDOs resolve spontaneously with little or no treatment in the first year of life. However, some cases are resistant to different treatment strategies.

Consequently, pediatric DCR is not the first line treatment for children with NLDO. Its indications are cases unresponsive to other previous treatments, those associated with a mucocoele, potentially complex cases like craniofacial abnormalities or Down's syndrome especially in older children, or when children experience recurrent dacryocystitis.

There are many studies on external DCR and pediatric patients. In most series, success rates range between 90% and 96%.^{19,20} More recent studies of EN-DCR in children show higher success rates and fewer complications^{21,22}.

In 2008, Dolmetsch et al.²³ published the largest reported group of pediatric patients in a series undergoing endoscopic DCR and the first one to use MMC in pediatric cases, based on the fact that in children, MMC had been used topically in otolaryngology in choanal atresia repair,²⁴ management of laryngeal and tracheal stenosis,²⁵ and to prevent the recurrence of caustic esophageal strictures.²⁶ No complications were observed in any of these studies. Dolmetsch's study showed that EN-DCR with MMC is a safe and successful procedure in children. It has the advantages that it leaves no scar, preserves the medial canthal structures, and it can be performed successfully as a simultaneous bilateral procedure. Importantly, there are no significant complications associated with the use of MMC in children.

There are some differences in surgical technique between children and adults for anatomical reasons. Infiltration with lidocaine and adrenalin must be carefully considered in younger children because of the risk of overdosage. A 2.7 mm rigid endoscope is used, but we use all the standard FESS adult instruments, and sometimes some ear surgery instruments. Care must be taken while performing the osteotomy because of the proximity of the cranial base.

Complications

There are few complications associated with this procedure.

Minor complications such as ecchymosis of the cheek and/or lids and emphysema occur more often, although they are still rare.

Epistaxis is usually mild and infrequent,²⁷ not requiring a return to operating theatre; in the authors' opinion there is no need to pack the nose at the end of the procedure.

It is advisable to stop or replace any antiplatelet or anticoagulant drugs before the surgery, when possible - although this should be a case-to-case decision shared with the patient's physician and the anaesthesiologist. However there are reports saying otherwise.²⁸ Nevertheless, nasal bleeding can occur in the first week postoperative and patients are taught how to manage it if it happens.

Ostium granulomas, stent prolapse, nasal synechiae and membrane formation over internal common opening are other possible complications. In the few cases of failure that do occur, circumstrial injections of antimetabolite such as mitomycin C have been reported.²⁹ Dacryoplasty balloons are also available in the market, specially designed for endonasal use to enlarge the ostium.

CSF leakage has been described³⁰ as well as orbital damage with possible vision loss or diplopia.

Air reflux is relatively common after the surgery but rarely bothersome to the patients.³¹

Key points

It is now consensual that success rates of EN-DCR now match those of the EX-DCR procedure.

There are growing and evolving indications for the endoscopic technique and these include lacrimal sac abscess and acute dacryocystitis, post chemotherapy and radiotherapy nasolacrimal duct obstruction, and common canalicular obstruction.

It is an attractive option in pediatric patients and it is our first choice in revision surgery for failed DCR. The growing success rates are clearly associated with improvements in surgical instruments and techniques such as good endoscopic visualization, postoperative care and the use of mitomycin C, especially in revision surgery.

There is no proven evidence of the benefit of silicone stenting during endonasal DCR.

EN-DCR, with or without adjunctive MMC and with or without silicone intubation, achieves high success rates that makes it an attractive alternative to external DCR.

Bibliography

1. Caldwell G. Two new operations for obstruction of the nasal duct, with preservation of the canaliculi, and with an incidental description of a new lacrymal probe. *Am J Ophthalmol* 1893; 10:189-193
2. Toti A. Nuovo método conservatore di cura radicale dele suppurazione croniche del sacco lacrimale (dacriocistorhinostomia). *Clin Moderna* 1904;10:385
3. Linberg J, Anderson R, Busted R, Barreras R. Study of intranasal ostium external dacryocystorhinostomy. *Arch Ophthalmol* 1982;100:1758-1762
4. Wormald PJ. Powered endonasal dacryocystorhinostomy. *Laryngoscope* 2002;112:69-71.
5. Madge S, Chan W, Malhotra R, Ghabrial R, Floreani S, Wormald PJ, Tsirbas A, Selva D. Endoscopic Dacryocystorhinostomy in Acute Dacryocystitis: A Multicenter Case Series *Orbit*, 30(1), 1–6, 2011
6. Ali MJ, Psaltis AJ, Wormald PJ The frequency of concomitant adjunctive nasal procedures in powered endoscopic dacryocystorhinostomy. *Orbit*. 2015 Apr 22;1-4.
7. Figueira E, Al Abbadi Z, Malhotra R, Wilcsek G, Selva D. Frequency of simultaneous nasal procedures in endoscopic dacryocystorhinostomy. *Ophthal Plast Reconstr Surg*. 2014 Jan-Feb;30(1):40-3
8. Cheng AC, Wong AC, Sze AM, Yuen HK. Limited nasal septoplasty by ophthalmologists during endonasal dacryocystorhinostomy: is it safe? *Ophthal Plast Reconstr Surg*. 2009 Jul-Aug;25(4):293-5.
9. Trimarchi M, Resti AG, Bellini C, Forti M et al. Anastomosis of nasal mucosal and lacrimal sac flaps in endoscopic dacryocystorhinostomy. *Eur Arch Otorhinolaryngol* (2009) 266:1747-1752.
10. Hodgson N, Bratton E, Whipple K, Priel A, Oh SR, Fante RG, Kikkawa DO, Korn BS. Outcomes of endonasal dacryocystorhinostomy without mucosal flap preservation. *Ophthal Plast Reconstr Surg*. 2014 Jan-Feb;30(1):24-7.
11. Tsirbas A, Wormald PJ. Endonasal dacryocystorhinostomy with mucosal flaps. *Am J Ophthalmol* 2003;135:76-83
12. Tsirbas A, Davis G, Wormald PJ. Mechanical endonasal dacryocystorhinostomy versus external dacryocystorhinostomy. *Ophthal Plast Reconstr Surg* 2004;20:50-6
13. Gu Z, Cao Z. Silicone intubation and endoscopic dacryocystorhinostomy: a meta-analysis. *Journal of Otolaryngology-Head & Neck Surgery*, Vol 39, No 6 (December), 2010; pp 710–713
14. Choussy O, Retout A, Marie JP, Cozlean A, et al. Endoscopic revision of external dacryocystorhinostomy failure. *Rhinology* 2010, 48:104-107
15. Wakaki S, Marumo H, Tomioka K. Isolation of new fractions of antitumor mitomycins. *Antibiot Chemother* 1958;8:228-240
16. Xue K, Mellington FE, Norris JH. Meta-analysis of the adjunctive use of mitomycin C in primary and revision, external and endonasal dacryocystorhinostomy. *Orbit*. 2014 Aug;33(4):239-44
17. Ozkiris M, Ozkiris A, Goktas S. Effect of mitomycin C on revision endoscopic dacryocystorhinostomy. *J Craniofac Surg*. 2012 Nov;23(6):608-10
18. Ali MJ, Baig F, Lakshman M, Naik MN. Electron microscopic features of nasal mucosa treated with topical and circumstrial injection of mitomycin C: implications in dacryocystorhinostomy. *Ophthal Plast Reconstr Surg*. 2015 Mar-Apr;31(2):103-7.
19. Barnes EA, Abou-Rayyah Y, Rose GE. Pediatric dacryocystorhinostomy for nasolacrimal duct obstruction. *Ophthalmology* 2001;108:1562–4.
20. Hakin KN, Sullivan TJ, Sharma A, et al. Paediatric dacryo-

- cystorhinostomy. *Aust N Z J Ophthalmol* 1994;22:231–5.
21. Kominek P, Cervenka S. Pediatric endonasal dacryocystorhinostomy: a report of 34 cases. *Laryngoscope* 2005;115:1800–3.
22. Eloy P, Leruth E et al. Pediatric endonasal endoscopic dacryocystorhinostomy. *International Journal of Pediatric Otorhinolaryngology*, Volume 73, Issue 6, 867–871
23. Dolmetsch A, Gallon M, Holds J. Nonlaser endoscopic endonasal dacryocystorhinostomy with adjunctive mitomycin C in children. *Ophthal Plast Reconstr Surg* 2008 Vol 24, No5, 390–393
24. McLeod JK, Brooks DB, Mair EA. Revision choanal atresia repair. *Int J Pediatr Otorhinolaryngol* 2003;67:517–24.
25. Senders CW. Use of mitomycin C in the pediatric airway. *Curr Opin Otolaryngol Head Neck Surg* 2004;12:473–5.
26. Olutoye OO, Shulman RJ, Cotton RT. Mitomycin C in the management of pediatric caustic esophageal strictures: a case report. *J Pediatr Surg* 2006;41:e1–3.
27. Andrew N, Selva D. Postoperative haemorrhage in powered endoscopic dacryocystorhinostomy. *Clin Experiment Ophthalmol*. 2014 Apr;42(3):262–5.
28. Smith W, Merkonidis, C, Yung M. Endoscopic dacryocystorhinostomy in patients taking aspirin perioperatively. *Am J Otolaryngol* 27 (2006) 323–326
29. Kamal S, Ali MJ, Naik MN. Circumostial injection of mitomycin C (COS-MMC) in external and endoscopic dacryocystorhinostomy: efficacy, safety profile, and outcomes. *Ophthal Plast Reconstr Surg*. 2014 Mar-Apr;30(2):187–90.
30. Cerebrospinal fluid leakage after endonasal dacryocystorhinostomy. Fayet B, Racy E, Assouline M. *J Fr Ophthalmol*. 2007 Feb;30(2):129–34.
31. Biro N, Murchison AP, Pribitkin EA, Rosen MR, Bilyk JR. Air reflux and other sequelae following endoscopic dacryocystorhinostomy. *Ophthal Plast Reconstr Surg*. 2013 Sep-Oct;29(5):386–8.

21. Transcanalicular laser dacryocystorhinostomy

Maria Araújo

Introduction

Tearing and epiphora describe the same symptom of teardrops overflowing on the face or moist eye, but they have very different etiologies.

The first concerns changes in the process of secretion, in particular reflex excessive tear production because of changes in the external ocular surface, dry eye, foreign body, etc.

A history of acute dacryocystitis, trauma of the face or nose points to functional or organic changes in drainage. The complaint of moist eye or tearing does not mean that there is an obstruction in the excretory system.

As Rose²⁰ wrote, “epiphora results from an imbalance between secretion, evaporation and drainage”.

Correct diagnosis is based on history and clinical examination, with procedures like the Schirmer test, or probing and possibly additional diagnostic exams such as CT scan or dacryocystography.¹⁹

Anatomic bases:

- Secretory system and drainage

Tears are secreted by the main lacrimal gland and accessory glands, goblet cells and glands of the eyelid margin.^{1,3}

The main lacrimal gland has two lobes, the orbital one located in the supero-external quadrant of the orbit, and palpebral lobe in the supero-external quadrant of the upper eyelid. The accessory glands located along the superior conjunctival fornix are known as Krause's glands, and those on the tarsal margin of the upper lid are Wolfring glands¹. Secreted tears, aided by blinking, lubricate and protect the external ocular surface. During this process the tear produced partially evaporates and the rest is drained by the lacrimal excretory system.¹

Drainage of tears begins in the lacrimal puncta, which are two 0.3 mm diameter holes in the medial area of the eyelids. Tear drainage from the canaliculus to the lacrimal sac is essentially the responsibility of Horner's muscle; however, the exact mechanism is unknown.³

The lower lacrimal punctum is in a more lateral location due to faster embryonic development of the maxilla in relation to the frontal bone.¹ The lacrimal

canaliculi run vertically from the puncta for 2 mm, (ampullae) and then describe a medial angle of 90° to pass approximately 8 mm horizontally. They are 0.5 to 1 mm in diameter and are covered by stratified squamous epithelium and surrounded by orbicular muscle. In more than 90% of cases the canaliculi converge to form the common canaliculus.¹ Its path is parallel to the eyelid margin, but it describes angles when passing the medial canthal tendon, at the junction of the common canaliculus and at the entrance of the lacrimal sac. These angles have a valve effect and prevent lacrimal reflux from the lacrimal sac.¹ The explanation of the presence and function of the valves of Rosenmüller, Krause and even of Hasner is, however, not consensual¹

The lacrimal sac lies within the lacrimal fossa and measures 12 to 15 mm vertically by 4 to 8 mm in anteroposterior diameter. The main body of the lacrimal sac is below the medial canthal tendon,¹ which is why pathological processes affecting the lacrimal sac are almost always below the tendon. Above it are 3 to 5 mm of the fundus of the lacrimal sac. Therefore, a wide osteotomy may require previous medial tendon disinsertion.

The lacrimal sac extends down through the nasolacrimal duct. Anatomically they are different parts of the same structure.¹ The nasolacrimal duct crosses the bone and ends in the inferior meatus. The nasolacrimal fossa and the nasolacrimal duct are narrower in women than in men, which helps explain why a greater number of women are affected by nasolacrimal obstructions. Hasner's valve lies between the nasolacrimal duct and nasal cavity, and impermeability of this valve results in epiphora in children.

- Osteology

The medial side of the orbital rim is formed inferiorly by the frontal process of the maxilla and superiorly by the maxillary process of frontal bone. The lacrimal fossa is located infero-medially in the orbital rim and is limited anteriorly by the anterior lacrimal crest, formed by the maxilla, and posteriorly by the posterior lacrimal crest of the lacrimal bone. The two

21. Transcanalicular laser dacryocystorhinostomy

bones articulate at the lacrimo-maxillary suture. The lacrimal fossa is about 16 mm in height by 4 to 9 mm wide and 2 mm deep.¹

The anterior lacrimal crest is the most important reference point in external DCR because it sets the anterior limit of the lacrimal fossa and connects superiorly to the anterior tendon of the medial canthus. Between the lower and the medial part of the orbital rim, a small elevation is palpated, the lacrimal tubercle, which defines the lower boundary of the lacrimal sac¹ - another important reference in external DCR.

The lacrimal fossa drains into the nasolacrimal duct which is about 12 mm in length, and whose limits are defined laterally by the maxillary bone and medially by the lacrimal bone and inferior turbinate.¹ The nasolacrimal duct drains into the nasal cavity, more specifically into the inferior meatus, through the inferior ostium of the nasolacrimal duct.

- Nasal Anatomy:

Knowledge of nasal anatomy is especially important in endoscopic DCR and in transcanalicular DCR guided by nasal endoscopy.

The nasal septum is formed by the vomer bone and the vertical plate of the ethmoid bone, and it separates the two nasal cavities.

The inferior turbinate limits the inferior meatus and it drains the inferior ostium of the nasolacrimal duct.

The middle meatus lies between the middle turbinate and the lateral wall of the nose. The insertion site of the turbinate in the lateral wall of the nose is called the axilla. The lacrimal sac ends approximately 8.8 mm above the axilla of the middle turbinate.² The two important markers of this meatus are the uncinate process and the bulla ethmoidalis. The uncinate process is a crest with a half-moon shape that fits into the ethmoidal process of the middle turbinate. This crest starts above the axilla of the middle turbinate and in the projection of the cranial end of the lacrimal sac.² The bulla ethmoidalis lies posterior to the uncinate process and contains most of the anterior ethmoid cells. The middle meatus is bounded behind by the middle turbinate, which inserts on the lamina papyracea and divides the ethmoid cells into anterior and posterior groups.²

The lacrimo-maxillary suture, previously mentioned, appears in the middle meatus as a linear elevation called maxillary line. While the anterior lacrimal crest is the essential marker for the external DCR, in endonasal and transcanalicular DCR the reference point is the maxillary line.² It is located more or less in the middle of the sac, and the distance between this line and the anterior lacrimal crest is about 4 mm.²

Behind the maxillary line is the lacrimal bone, a thin bone of about 106 microns,¹ which enable a laser to

be used to perform osteotomy. Superiorly, the bone articulates with the frontal bone and behind with the lamina papyracea of the ethmoid bone. Most of the lacrimal sac is located behind the suture line. The osteotomy should be done behind the nasolacrimal suture line and ahead of the uncinate process.²

Anatomical variations alter the relationships of the structures described and sometimes require modification of the surgical technique. The most common is the pneumatization of the middle turbinate, or concha bullosa, which narrows the middle nasal meatus and changes the relationship of the nasolacrimal suture line with the middle turbinate, and can involve removal of the anterior wall of the concha before osteotomy.² Other variations include the paradoxical curve of the medial turbinate and pneumatization of the uncinate process. In TLDCR the optical fiber can appear behind the uncinate process between the concha bullosa and the lamina papyracea demanding the removal of the uncinate process.²

Patient assessment

The terms epiphora and tearing refer to different conditions, though they can coexist in the same patient. The differential diagnosis is made by clinical history and by performing anatomic or functional permeability tests on the drainage system, such as probing, irrigation of the canaliculi, dacryoendoscopy, dacryocystography, nasal examination, dye tests,^{5,19} etc., and secretory function tests like the Schirmer test and break-up-time.

Patients with a history of acute or chronic dacryocystitis, mucocoele, lacrimal or nose surgery, bone fractures involving the lacrimal drainage system, are not good candidates for TLDCR⁶ or are even contraindicated for this surgical technique. The presence of dacryolithiasis, lacrimal fistula, lacrimal sac or nose tumors, extensive polyp disease, allergic or atrophic rhinitis, sarcoidosis and Wegener's granulomatosis, are contraindications for the use of this technique.⁶

Treatment of nasolacrimal duct obstructions or of the lacrimal sac distal to the common canaliculus

Obstruction of the drainage path between the lacrimal punctum and the inferior ostium of the nasolacrimal duct results in epiphora that can be quite pronounced, depending on its location and extent, and secretory and evaporation functions.

The acquired impermeability of the nasolacrimal duct or the lacrimal sac distal to the common canaliculus is handled by creating a new drainage pathway between the lacrimal sac and the nasal cavity.⁵ The surgical technique is called dacryocystorhinostomy and can be performed via a skin incision,⁵³ through

the conjunctiva,^{33,41} endonasal route^{34,36,50} and transcanalicular route,^{51,54,55,56} or combined forms.²⁶ Conjunctivorhinostomy, intubation, punctoplasty, are among other techniques used for the treatment of epiphora whose cause is not the sole responsibility of the nasolacrimal duct and whose discussion is beyond the scope of this chapter.

TLDCR

TLDCR is the latest surgical technique employed for DCR. This technique requires the use of a laser that can be used in an optical fiber and an endoscope. The diode laser has a wavelength between 810 and 980 nm and can be driven by an optical fiber. In TCDCR, the diameter of the fiber optic used varies between 400 and 600 microns. It is best introduced via the superior lacrimal punctum up to the lacrimal sac. Then, after the correct placement of the fiber tip and under endonasal endoscopic control, the osteotomy is performed using a pulsed or continuous laser.²⁸ Surgery ends with the fitting of silicone tubes.

Material

The material essential to accomplish a diode laser-assisted TCDCR technique consists of a punctum dilator, number 0, 00 or 1 Bowman probes, a lacrimal cannula for irrigation, the laser console, optical fiber with diameter of 400-600 micra, single or multiple use, and silicone tubes,⁴⁰ for canalicular intubation. A turbinate retractor is needed for nasal endoscopy and intraoperative correction of some anatomical variations, along with a 2 mm suction cannula, a 14 cm bayonet forceps, an ethmoid Blakesley forceps, 12 cm 45°, 0° endoscope, fiber optic cold light cable and a column with the light source and endoscope video system linked to a television monitor similar to Storz ® (Fig. 1).

Laser types

The laser is a collimated (parallel), monochromatic and coherent light (with the same wavelength). The laser effect on the tissues is termed photo-thermal and depends on the energy used.^{16,25} From 40-70 °C it causes denaturation of proteins, from 70-80 °C clotting, from 85-100 °C vacuolation, from 100-400 °C vaporizing and above 400 °C it causes charring.¹⁶

For TCDCR it must be possible to use in an optical fiber (Fig. 2, left), have an effective ablation, provide good hemostasis, have a narrow range of penetration while not destroying or damaging adjacent tissues,⁴ and be precise.^{17,27} Different types of laser^{48, 42, 58} have been used in TLDCR, some, however, have been replaced by other more effective, cheaper models that cause less damage to surrounding tissues.

The potassium titanyl phosphate (KTP) laser, the diode laser, erbium laser: YAG (Er:YAG)⁴² and the



Fig.1



Fig. 2- The optic fiber (left), and the diode laser console (right).

holmium: YAG (Ho:YAG) are some of the systems that can be used to perform TCDCR. Both Er:YAG and Ho:YAG lasers give a good cut. The collateral damage is 12 micra for the first and 500 micra for the second.²⁴ However, the Ho:YAG laser spreads the tissues, dirties the lenses, which requires frequent cleaning, and damages adjacent tissues more than the Er:YAG or KTP ones²². The KTP laser leads to bad vaporization of the bone,^{17,23} but it gives a good cut and good coagulation.⁶

The laser diode has become more popular in recent years because of the portability of the console (Fig. 2, right), the possibility of multi-use, good cut, good hemostasis for being well absorbed by melanin and hemoglobin and good coagulation, which decreases the risk of bleeding in hypo-coagulated or anti-platelet aggregation drugs patients. There is less collateral damage with the diode laser than with other types^{6,15,22} because the diode only operates at the tip of the fiber. However, adjacent tissue changes^{21,37,38} of 0.3-0.6 mm around the optical fiber optic are reported¹⁷ and, rarely, burns of the canaliculi or necrosis of the medial canthus.²⁹

Technique

- Anesthesia

The TLDCR can be performed under general^{15,16} or locoregional anesthesia with premedication by blocking the nasociliary, supra- and infratrochlear and the infraorbital nerves with 2% lidocaine with epinephrine 1:200000 or doing just a little pinch between the caruncle and the medial canthus, 12.5 mm deep, 8-10 cm³ of a mixture of 0.5% bupivacaine and 2% lidocaine with 5 IU/ml of hyaluronidase.³⁹ The eyeball is anesthetized with topical tetracaine.

After a first examination of the nasal cavity with a flexible or 0° endoscope, nasal packing is performed with gauze soaked in 2% lidocaine with adrenaline 1:200000 and oxymetazoline hydrochloride 0.5 mg/ml or phenylephrine hydrochloride 5 mg/ml, ten minutes before starting the surgery.

The disinfection is performed with 5% povidone-iodine after applying topical anesthetic and general anesthesia induction, or prior to performing locoregional anesthesia.

- Nasal cavity observation

Ten minutes later the nasal packing is removed and the endoscope is reintroduced as far as the middle meatus. It is crucial at this stage to recognize the structures, their anatomical variations and pathological changes. Because of this, in the middle meatus (Fig. 3) one should evaluate the space, the axilla, the maxillary line, the uncinate process, the relationships between the different structures and the possible presence of inflammatory pathology, tumors or infection.

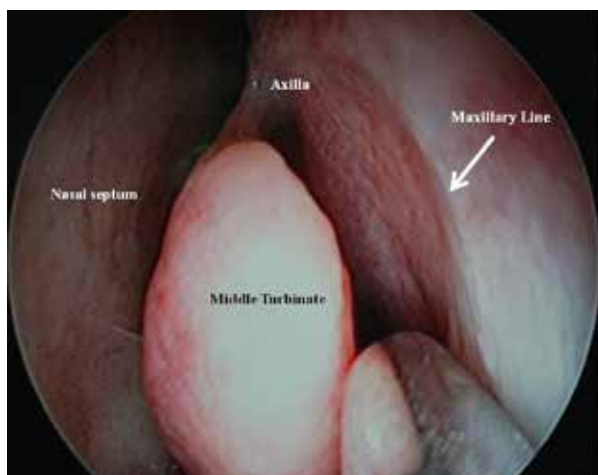


Fig. 3 Middle meatus.

- Probing and introduction of the optic fiber

After dilation of the lacrimal punctum (Fig. 4, left) probing is performed in the upper and lower canaliculi with a Bowman lacrimal probe, 0, 00 or 1, to assess the presence of bands over the canaliculi. The wider probes are preferred because they facilitate

the entry of the optical fiber. With the endoscope inserted into the middle meatus, the lachrymal probe is removed and an optical fiber with a diameter between 400 and 600 microns is introduced in the superior lacrimal punctum up to the lacrimal sac (Fig. 4, center and right). Despite slight damage to adjacent tissues, the introduction of the fiber and the osteotomy performed through the upper canaliculus reduces the risk of damage to the inferior canaliculus, which is much more important for the drainage system. Insertion in the lacrimal punctum is facilitated if the laser aiming light is off; however, once introduced, the aiming light should be turned on to better locate the optical fiber.

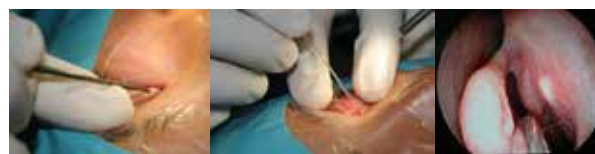

Fig. 4. Left: punctum dilation. Centre: introduction of the fiber in the lacrimal punctum. Right: Transillumination of the aiming light through the bone.

When in the correct position, between the maxillary line and the uncinate process, the optical fiber is visible by transillumination through the lacrimal bone. Otherwise, there could be anatomical variations, canaliculi bands might have prevented the advance of the optical fiber or the fiber might have followed a wrong path.

- Osteotomy (rhinostomy)

The osteotomy should be performed between the maxillary line and the uncinate process. The laser console must be programmed for pulse mode. The parameters vary from author to author; those used by the author of this article are 90 ms pulse with breaks of 50 ms; the power must be from 8 to 10 watts.^{9,15} The pause period allows the tissue temperature to recover. Supporters of the continuous mode claim it is more accurate and does not cause further damage.²⁸ Osteotomy is performed with a contact laser, and must always use endoscopic visualization. After the initial opening, called a puncture, the fiber tip is displayed as the coagulation and necrosis of nasal mucosa that surrounds (Fig. 5). The osteotomy should be extended to the sides, also by contact, up to a diameter of least 5 mm, using the diameter of the suction cannula for comparison (Fig. 6).

Some surgeons combine the transcanalicular and the endonasal approaches. The operation is initiated through a transcanalicular approach and the enlargement of the osteotomy to 10 mm in diameter is accomplished endonasally. This reduces the risk of canalicular burn injury,¹⁷ but it does increase the risk of laser-induced orbital lesions.

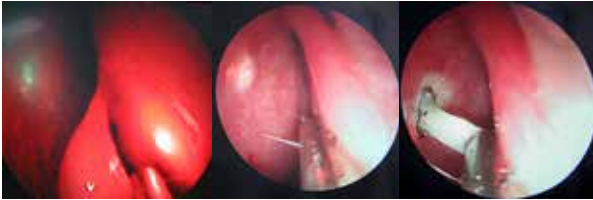


Fig. 5. Right: Laser transillumination. Center: puncture. Left: mucus aspiration of the lacrimal sac.

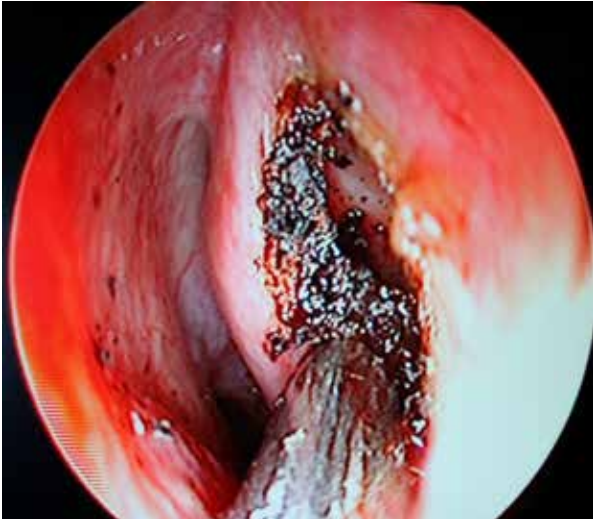

Fig. 6. Diameter comparison between suction cannula and osteotomy.

- Irrigation and adjuvant treatments:

After reaching the desired diameter the fiber is removed. At this stage the canaliculi can be irrigated with saline and adjuvant treatments such as MMC can be implemented.

MMC is an alkylating antibiotic used in DCR as healing modulator. It is applied using a soaked compress. MMC decreases the synthesis of collagen and cell proliferation and at a dose of 0.5 mg/ml does not cause systemic problems.⁴³ There is no consensus as to its use, the concentration, the time of application and how often it should be applied.^{6,15, 43} The minimum concentration found in the literature is 0.02 %.⁶ Yeşim Altay et al.³⁰ applied 0.4 mg/ml of MMC after osteotomy for 2 and 5 minutes in two groups of patients. The group receiving MMC for 5 minutes had significantly better results. On the other hand, Raman Wadhwa et al.⁴³ in a study of endonasal DCR, found no additional benefit in those patients receiving MMC. According to Remzi Dogan et al.⁴⁶ in TLDCR the bicanalicular intubation associated with the application of MMC is more successful than either of the two separate procedures.

The application is ended by removing the compress without performing irrigation.^{6,30}

Bicanalicular intubation

The metallic guides of the silicone tubes are inserted and harvested sequentially in the middle meatus

under endoscopic visualization, (Fig. 7), and removed from the nasal cavity. The position and length of the tubes are adjusted and the metallic guides are removed. Both ends of the tubes are knotted and left free in the nasal cavity.

Bicanalicular intubation does not seem to improve success in endonasal³⁴ or external DCR in first intention surgery and without canalicular stenosis.^{11,12,45} In fact, it can lead to the formation of bacterial biofilm,¹⁴ granulomas, laceration of lacrimal puncta, etc., but it continues to be done.¹⁰ Regarding TLDCR, maybe for the smallest diameter of the osteotomy, without flaps¹⁷ and the slight trauma induced by the optical fiber, intubation is almost always performed. The tubes used depend on the surgeon's preference.

A study carried out in 2015 in patients undergoing endoscopic endonasal DCR reports similar results for silicone and polypropylene tubes, and less for T-tube.⁴⁰ Orbital adverse events were more common with polypropylene and spontaneous losses were higher with the T-tube.⁴⁰

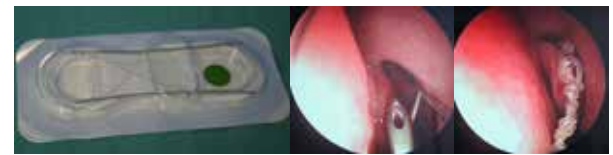


Fig. 7. Right: silicon tubes (FCI °). Center: bicanalicular tube metal guide harvesting. Left: free silicone tubes and tips tied in the nasal cavity.

Complications:

TLDCR is a minimally invasive surgical technique. It has lower morbidity than external DCR, there is less risk of intra- and postoperative bleeding, less inflammation, the laser is directed away from the orbit so there is less risk of injury, there is no skin incision, it spares the lacrimal pump, and is considerably faster than the external DCR.⁶ However, canalicular stenosis,⁶ necrosis of the medial canthus²⁹ and temporary alteration of olfactory function³⁷ have been reported, along with other complications,³⁸ some of which are common to other techniques of DCR.

Postoperative treatment

Postoperatively, the patient applies an antibiotic such as tobramycin and an anti-inflammatory such as dexamethasone in the operated eye, in the form of eye drops, 5 times a day for 10 days. Nose drops of oxymetazoline hydrochloride 0.5 mg/dl are applied twice a day for 3 days. The use of prophylactic systemic antibiotics is controversial in external DCR and does not seem to be justified as a matter of routine.^{7,8,13} The same principle should be applied in TLDCR.

Some authors advocate the use of MMC 2 mg/ml soaked in a compress and applied on a weekly basis

21. Transcanalicular laser dacryocystorhinostomy

in the first three postoperative consultations after endonasal osteotomy cleaning,⁶ or just cleaning the osteotomy a week after surgery.³¹ Silicone tubes are removed 8 to 12 weeks after surgery.

Results

The idea of an osteotomy connecting the lacrimal sac to the nose in the treatment of epiphora dates back about 2000 years and was described by Celsus.¹⁸ The modern form of the DCR using an external approach was described by Toti in 1904.¹⁸ Today, the external DCR is still the standard treatment for obstructions of the nasolacrimal duct or lacrimal sac distal to the common canaliculus. Its results are still the best, with a success rate of more than 90%; however, the demand for faster, less aggressive procedures, with less damage to vascular structures, to the medial canthus tendon, with less risk of bleeding and with better aesthetic results,^{15,32} associated with the technical development including endoscopy and laser today makes it possible to perform the TLDCR.

Of all the DCR techniques, TLDCR is the fastest one, taking between 8 and 25 minutes,^{15,16,17,49} unlike external DCR whose duration varies from 78 to 118.6 minutes. The risk of morbidity is lower than for external DCR. Surgical success of TLDCR varies from one author to another (Table 1), depending essentially on the success criteria, the operated population,⁹ intubation, postoperative surveillance and the experience of the surgeon. The success criteria most often used are the absence of epiphora and permeability in irrigation, i.e. one functional and one anatomical criterion. The success rate varies from 34 % to 95.2 %.^{15,35,47,52}

Simon Dulku⁹ reports that individuals younger than 40 years old have a worse prognosis, probably because of fibroblastic and osteoclastic activity and the smaller diameter of the osteotomy achieved by this technique. The success rate was 52 % in a group aged less than 30 and 88 % in those over 60.⁹ Only a few studies have been carried out in this area.²³

Conclusion

TLDCR, is a minimally invasive surgical procedure, faster, with lower morbidity than the external approach, without injury to the lacrimal pump or cutaneous scar. However, there is still no consensus on the use of MMC, the level of energy to use or post-operative treatment. The selection of patients is another important issue. Not all patients with indication for dacryocystorhinostomy should be operated on with the transcanalicular approach. The only technique that can be used in patients with acute dacryocystitis is endonasal,¹⁷ which prevents the spread of infection to the orbit. Patients with a history

of chronic dacryocystitis, mucocoele, or dacryolithiasis should be operated on by external DCR, as should those in whom TLDCR has failed.^{44,57}

This technique is also contraindicated in patients with dacryolithiasis, lacrimal fistulae, tumors of the lacrimal sac and nose, extensive polyp disease, allergic or atrophic rhinitis, sarcoidosis and Wegener's granulomatosis.

Abbreviations:

DCR- dacryocystorhinostomy

TLDCR- transcanalicular laser dacryocystorhinostomy

MMC –mitomycin C

Fig.- Figure

Author	Journal and year	LASER	Total success, functional or anatomic	Type of study	Surgery: first intention or review	Follow up in months	Notes
Yeşim Altay	Journal of Clinical and Analytical Medicine. 2015. 6(1):25-8	diode	TLDCR +MMC 0.4/2min: 59,1% and TLDCR +MMC 0.4/5 min: 80%	prospective	1st intention	12	
Melike Balıkoğlu-Yılmaz	Ophthal Plast Reconstr Surg 2015;31:13-18	diode	EX-DCR 81.8%, EN-DCR 75.9%, TLDCR 76.7%	prospective	1st intention	12.8	
Emre Ayıntap	Journal of Ophthalmology Volume 2014, Article ID 913047, 5	diode	67.2%, varies between 52% and 88% depending on age	retrospective	1st intention	16.1	
Ibrahim Bulent Buttanri	Ophthal Plast Reconstr Surg 2014;30:209-211	diode	43.8% by TLDCR and 94.4% by EX-DCR	retrospective, review of failure of TLDCR		7.8	
Arzu Tas, Kıran C, o"mez	Lasers in Surgery and Medicine 46:275-280 (2014)	diode	74.9% in TLDCR and 89.1 % in EX-DCR-symptomatic success	retrospective, comparative TLDCR/EX-DCR		15.6 and 16	MMC
Kutukde Derya	Ophthal Plast Reconstr Surg 2013;29:15-17	diode	functional success 86 % EX-DCR and 68% TLDCR	prospective	1st intention	3	
Remzi Dogan	Eur Arch Otorhinolaryngol (2013) 270:2255–2261	diode	TLDCR+MMC+tube: 84.3%, TLDCR+ MMC: 76.9%, TLDCR+tube: 80%	prospective	1st intention	18.1	MMC groups
F. Nuhoglu, B	Acta Otorhinolaryngol Ital 2012;32:258-262	diode	success 95.2%	prospective	1st intention	42	
Sanjiv K. Gupta	Oman Journal of Ophthalmology, Vol. 5, No: 3, 2012	diode	success 90.5%	comparative not Interventional	1st and 2nd intention	12	
B. Parente Hernández	Arch Soc Esp oftalmol. 2012;87(5):139-144	diode	Functional/ anatomic 67.85%/ 71.42% in EX-DCR; 61.20%/67.74% in EN-DCR; 75%/75% in TLDCR	retrospective		8.55	MMC in TLDCR
Salah Zuhair Al-Asadi	Bas J Surg, September, 17, 2011	diode	TLDCR with tube 93.75 without tube 62.5%	prospective	1st intention	6	
Brigita Drnovšek-Olup	Indian Journal of Ophthalmology. 2010. Vol : 58, No: 3 Pag: 213-217	diode	success 83.3%	prospective, observational, consecutive		12	
Brigita Drnovšek-Olup	Zdrav Vestn Supl, december 2010, Letnik 79	diode	success 82%	successive	1st intention	16	
Jose M Riera	Acta Otorrinolaringol Esp. 2007;58(1):10-5	diode	TLDCR without tube or MMC: 88%. TLDCR with MMC and tube: 93.3%	prospective, observational, non random	1st intention	16	
Alanon Fernandez	Acta Otorrinolaringol Esp 2004; 55: 171-176	diode	94.11% TLDCR combined with endonasal		1st intention	8.33	
Alanon Fernandez	Arch Soc Esp Oftalmol 2004; 79: 325-330	diode	success 90.7%	prospective	1st intention	4 - 38	
Georg Von Arx	Med. Laser Appl. 18: 297-306 (2003)	Er:YAG	success 95.2 % (combined with dacryocentesis)	retrospective	1st and 2nd intention	29.3	
Marco Caversaccio	Rhinology, 39, 28-32, 2001	Er:YAG	TLDCR in 12 patients, high and low obstructions, 8 successes		1st intention	11 -27	
Bhupendra C. K. Patel	Ophthalmology Volume 104, Number 7, July 1997	Nd:Yag	success 46%	prospective	2nd intention	18	

Table 1. Some of published works on TLDCR.

References

1. Cat N., Burkat and Leslie A. Wei Anatomy of the Lacrimal System. Chap.1 The Lacrimal System: Diagnosis, Management and Surgery. Second edition. Adam J. Cohen, Michael Mercandetti, Brian Brazzo, editors. 2015 Springer.
2. H. Massegur-Solench and Jacinto, García-Lorenzo, and Juan Ramon Gras-Cabrero. Chap 2. Nasal Anatomy and Evaluation. The Lacrimal System: Diagnosis, Management and Surgery. Second edition. Adam J. Cohen, Michael Mercandetti, Brian Brazzo, editors. 2015 Springer.
3. H.-W. Meyer-Rüsenberg and K.-H. Emmerich. Transcanalicular Dacryocystorhinostomy. Chap.13. The Lacrimal System: Diagnosis, Management and Surgery. Second edition. Adam J. Cohen, Michael Mercandetti, Brian Brazzo, editors. 2015 Springer.
4. S. Mirza and N. Jones. Laser-Assisted Dacryocystorhinostomy. Chap 7. Rainer K. Weber, Rainer E. Keerl, Steven D. Schaefer, Roberto C. Della Rocca (Eds). Atlas of Lacrimal Surgery. 2007 Springer.
5. JRO Collin. Lacrimal Surgery. Chap 8. A Manual of Systematic Eyelid Surgery. 3rd Edition, 2006 Elsevier
6. Raoul Paolo D. Henson Primary Endocanalicular Laser Dacryocystorhinostomy. Chap 24. M. Javed Ali (ed.), Principles and Practice of Lacrimal Surgery, 2015 Springer.
7. Simon Dulku, Aderonke Akinmade, and Omar M Durrani, Postoperative Infection Rate After Dacryocystorhinostomy Without the Use of Systemic Antibiotic Prophylaxis. Orbit, 31(1), 44-47, 2012
8. Sergio Pinar-Sueiro, Roberto-Víctor Fernández-Hermida, Ane Gibelalde, and Lorea Martínez-Indart. Study on the Effectiveness of Antibiotic Prophylaxis in External Dacryocystorhinostomy: A Review of 697 Cases. Ophthal Plast Reconstr Surg. Vol.26, No 6, 2010
9. Emre Ayintap, Ibrahim Bulent Buttanri, Fariz Sad Jgov, Didem Serin, Mustafa Ozsutcu, Julide Canan Umurhan Akkan, and Kemal Tuncer. Clinical Study. Analysis of Age as a Possible Prognostic Factor for Transcanalicular Multidiode Laser Dacryocystorhinostomy. Journal of Ophthalmology Volume 2014, Article ID 913047, 5 pages
10. Rahman MZ, Hossain MJ, Hassam Z, Hayat ABMS, Karim M. Comparative study of success of dacryocystorhinostomy with and without tube intubation. JAFMC, vol 8 n° 2 December 2012
11. Edwin C. Figueira, Andrea Zarcovic, Simon N. Madge, Marcus M. Marcet, Dinesh Selva. Debates in Dracryology: The intubation Dilemma. Chap 37. M. Javed Ali (ed.), Principles and Practice of Lacrimal Surgery, 2015 Springer.
12. Nooshin Bazzazi, Mohammad Shayaninasab, Farhad Farahani, Siamak Akbarzad. A study of the relation between silicone tube removal time and results of external dacryocystorhinostomy with intubation. Life Science Journal 2013;10(1)
13. Mohammad Javed Ali, Anuradha Ayyar, Swapna R Motukupally, Savitri Sharma and Milind N Naik. Bacteremia during dacryocystorhinostomy: results of intra-operative blood cultures. Journal of Ophthalmic Inflammation and Infection 2014, 4:27
14. Balikoglu-Yilmaz M, Yilmaz T, Cetinel S, Taskin U, Esen AB, Taskapili M, Kose T. Comparison of scanning electron microscopy findings regarding biofilm colonization with microbiological results in nasolacrimal stents for external, endoscopic and transcanalicular dacryocystorhinostomy. Int J Ophthalmol 2014;7(3):534-540
15. Arzu Taskiran Çomez, Onur Karadag, Sedat Arıkan, Baran Gencer, and Selçuk Kara. Comparison of Transcanalicular Diode Laser Dacryocystorhinostomy and External Dacryocystorhinostomy in Patients with Primary Acquired Nasolacrimal Duct Obstruction. Lasers in Surgery and Medicine 46:275-280 (2014)
16. Eduardo Alonso Garcia, Pedro Paulo Vivacqua Cunha Cintra. Transcanalicular dacryocystorhinostomy with diode laser: complications. Arq Bras Oftalmol. 2009;72(4):493-6
17. M. A. Alanon Fernandez et al. Endonasal and endocanalicular dacryocystorhinostomy by diode LASER, preliminary results. Acta Otorrinolaringol Esp 2004; 55: 171-176
18. Vladimir S. Yakopson, Joseph C. Flanagan, Daniel Ahn, Betsy P. Luo. Dacryocystorhinostomy: History, evolution and future directions. Saudi Journal of Ophthalmology (2011)25,37-49
19. Sima Das. Evaluation of Epiphora. Chap 6. M. Javed Ali (ed.), Principles and Practice of Lacrimal Surgery, 2015 Springer.
20. Geoffrey E Rose. The Apparent Paradox of "Success" in Lacrimal Drainage Surgery. Oculoplastic and Orbit. Essentials in Ophthalmology. Chap 4, pp 51 to 59, 2006 Springer.
21. M. A. Alanon Fernandez et al. Dacryocystorhinostomia Transcanalicular com Láser Díodo. Archivos de la Sociedad Española de Oftalmología. 2004. scielo.isciii.es/scielo.php
22. Mohammad Ajalloueyan, Mohammad Fartookzadeh, Hamid Parhizgar. Use of Laser for Dacryocystorhinostomy. Arch Otolaryngol Head Neck Surg. 2007;133:340-343
23. Sevin Soker Cakmak, Muzeyyen Yildirim. Use of endocanalicular dacryocystorhinostomy with multidiode laser in children. International Journal of Pediatric Otorhinolaryngology 74 (2010) 1320-1322
24. Bhupendra C. K. Patel, FRCOphth, Barratt Phillips, William M. McLeish, Patrick Flaharty, Richard L. Anderson. Transcanalicular Neodymium: YAG Laser for Revision of Dacryocystorhinostomy. Ophthalmology Volume 104, Number 7, July 1997
25. Sanjiv K. Gupta, Ajai Kumar 1, Swati Agarwal, Paritosh Pandey. Transcanalicular laser dacryocystorhinostomy using low energy 810 nm diode laser. Oman Journal of Ophthalmology, Vol. 5, No 3, 2012
26. Georg Von Arx, Andreas Schmelzer, and Klaus Lammli. Transcanalicular Endoscopic Laser-assisted Dacryocystorhinostomy (TELA-DCR). Med. Laser Appl. 18: 297-306 (2003)
27. Brigita Drnovsek-Olup, Matej Beltram. Transcanalicular diode laser-assisted dacryocystorhinostomy. Indian Journal of Ophthalmology. 2010. Vol : 58, No 3 Pag: 213-217
28. José Maeso Riera and Maria Teresa Sellarès Fabrès. Transcanalicular Diode Laser Dacryocystorhinostomy: Technical Variations and Results. Acta Otorrinolaringol Esp. 2007;58(1):10-5
29. Scott M. McClintic, Michael K. Yoon, Maziar Bidar, Jonathan J. Dutton, M. Reza Vagefi, and Robert C. Kersten. Tissue Necrosis Following Diode Laser-assisted Transcanalicular Dacryocystorhinostomy. Ophthal Plast Reconstr Surg, Vol. 31, No 1, 2015
30. Yeşim Altay et al. The Success Rate of Endocanalicular Laser Dacryocystorhinostomy with Two Different Mitomycin-C Application. J. Clin Anal Med 2015;6(1): 25-8
31. Halil Ibrahim Yener, Adem Gul, Cagatay Caglar, and Muammer Ozcimen. The Effectiveness of Postoperative Early Ostium Cleaning in Transcanalicular Diode Laser-Assisted Dacryocystorhinostomy. Ophthal Plast Reconstr Surg, Vol. 30, N° 6, 2014
32. B. Parente Hernández, A. Sentieri Omarrementería, J. Junceda Moreno. Corrective techniques of lacrimal obstruction in the vertical system. Arch Soc Esp de Oftalmol. 2012; 87(5): 139-144
33. Jean Paul Adenis Pierre-Yves Robert. Retrocaruncular

- approach to the medial orbit for dacryocystorhinostomy. Graefes Arch Clin Exp Ophthalmol (2003) 241:725-729
34. Kelvin K. L. Chong, Frank H. P. Lai, Mary Ho, Abbie Luk, Ben W. Wong, Alvin Young, Randomized Trial on Silicone Intubation in Endoscopic Mechanical Dacryocystorhinostomy (SEND) for Primary Nasolacrimal Duct Obstruction. Ophthalmology 2013;120:2139-2145
 35. Melike Balikoglu-Yilmaz, Tolga Yilmaz, Umit Taskin, Muhittin Taskapili, Mehmet Akcay, M. Faruk Oktay and Saban Eren. Prospective Comparison of 3 Dacryocystorhinostomy Surgeries: External Versus Endoscopic Versus Transcanalicular Multidiode Laser. Ophthal Plast Reconstr Surg, Vol. 31, N° 1, 2015
 36. Dior WX Lee, Charmaine H. C. Chai and Seng Chee Loon. Primary external dacryocystorhinostomy versus primary endonasal dacryocystorhinostomy: a review. Clinical and Experimental Ophthalmology 2010; 38: 418-4266
 37. Yildirim Yildirim, Murat Salihoglu, Taner Kar, Aytug Altundag, Hakan Tekeli, Abdullah Kaya, Melih Cayonu, and Melih Unal. Postoperative Changes in Olfactory Function After Transcanalicular Diode Laser Dacryocystorhinostomy. Ophthal Plast Reconstr Surg, Vol. XX, No XX, 2014
 38. Ruchi Goel, Sonam Garg, Smriti Nagpal, Sushil Kumar, Saurabh Kamal, Naso-cutaneous fistula following transcanalicular laser dacryocystorhinostomy. Saudi Journal of Ophthalmology (2014) 28, 69-71
 39. Waleed Riad and Imtiaz A. Chaudhry. Anaesthesia for dacryocystorhinostomy. Current Anaesthesia & Critical Care 21 (2010) 180-183
 40. Okuyucu S. et al. Endoscopic dacryocystorhinostomy with silicone, polypropylene, and T-tube stent; randomized controlled trial of efficacy and safety. Am J Rhino Allergy. 2015 Jan; 29(1) : 63-8
 41. Pelin Kaynak-Hekimhan, and Ömer Faruk Yilmaz. Transconjunctival Dacryocystorhinostomy: Scarless Surgery Without Endoscope and Laser Assistance. Ophthal Plast Reconstr Surg, Vol. 27, No 3, 2011
 42. Marco Caversaccio, Martin Frenz, Peter Schär, Rudolf Häusler. Endonasal and transcanalicular Er:YAG laser dacryocystorhinostomy. Rhinology, 39, 28-32, 2001
 43. Raman Wadhera et al. A comparative study of endoscopic endonasal dacryocystorhinostomy with and without intraoperative mitomycin-C application. Clinical Rhinology: An International Journal, Jan-April 2013; 6(1):5-9
 44. Ibrahim Bulent Buttanri, Emre Ayintap, Didem Serin, Muslime Akbaba, and Safak Karslioglu. Comparison of Revision Surgeries With Transcanalicular Diode Laser and External Approaches in Cases With Failed Transcanalicular Diode Laser Dacryocystorhinostomy. Ophthal Plast Reconstr Surg 2014;30:209-211)
 45. Yi-fan Feng, Jian-qiu Cai, Jia-yu Zhang, Xiao-hui Han. A meta-analysis of primary dacryocystorhinostomy with and without silicone intubation. Can J Ophthalmol 2011; 46:521-527.
 46. Remzi Dogan, Aysenur Meric, Mustafa Ozsu"tcu", Alper Yenigun. Diode laser-assisted endoscopic dacryocystorhinostomy: a comparison of three different combinations of adjunctive procedures. Eur Arch Otorhinolaryngol (2013) 270:2255-2261
 47. Salah Zuhair Al-Asadi, Ahmed Muhammed Al-Abbasy . Efficacy of diode laser DCR in acquired nasolacrimal duct obstruction. Bas J Surg, September, 17, 2011
 48. Fay et al. Endocanalicular Nd:YAG Laser Dacryocystorhinostomy. Int Ophthalmol Clin. 1999 Winter; 39(1):177-84
 49. Jenny E. Hong, Mark P. Hatton, Martin L. Leib, Aaron M. Fay. Endocanalicular Laser Dacryocystorhinostomy. Analysis of 118 Consecutive Surgeries. Ophthalmology 2005;112:1629-1633. 2005
 50. Bruce M. Massaro; Russell S. Gonnering; Gerald J. Harris. Endonasal Laser Dacryocystorhinostomy: A New Approach to Nasolacrimal Duct Obstruction. Arch Ophthalmol. 1990 ;108:1172-1176
 51. Kutukde Derya, Soner Demirel, Selim Doganay, Gozde Orman, Tongabay Cumurcu, and Abuzer Gunduz. Endoscopic Transcanalicular Diode Laser Dacryocystorhinostomy: Is It an Alternative Method to Conventional External Dacryocystorhinostomy? Ophthal Plast Reconstr Surg, Vol. 29, N° 1, 2013
 52. G. Savino, R. Battendieri, S. Traina, G. Corbo, G. D'Amico, M. Gari, E. Scarano, G. Paludetti. External vs. endonasal dacryocystorhinostomy: has the current view changed? Acta Otorhinolaryngol Ital 2014;34:29-35
 53. Gilad Rabina, Shani Golan, Meira Neudorfer, and Igal Leibovitch. External Dacryocystorhinostomy: Characteristics and Surgical Outcomes in Patients with and without Previous Dacryocystitis. Journal of Ophthalmology Volume 2013, Article ID 287524, 4 pages
 54. Seongmu Lee and Michael T. Yen. Laser-assisted dacryocystorhinostomy: a viable treatment option? Curr Opin Ophthalmol 22:413-418
 55. F. Nuhoglu, B. Gurbuz, K. Eltutar. Long-term outcomes after transcanalicular laser dacryocystorhinostomy. Acta Otorhinolaryngol Ital 2012;32:258-262
 56. Brigita Drnovšek-Olup, Matej Beltram. Long-term success rate of transcanalicular laser dacryocystorhinostomy. Zdrav Vestn Supl, december 2010 Letnik 79
 57. Rajesh S. Joshi. Convencional dacryocystorhinostomy in a failed trans-canalicular laser assisted dacryocystorhinostomy. Indian Journal of Ophthalmology. Vol 59, no 5, 2011
 58. Aaron M. Fay, Peter Michalos, Peter A. D. Rubin. Endocanalicular Nd: YAG Laser Dacryocystorhinostomy. Int Ophthalmol Clin. 1999 Winter; 39 (1): 177-84
 59. Christenbury J. D. Translacrimal Laser Dacryocystorhinostomy. (Letter). Arch Ophthalmol-Vol 110, February 1992.

Thanks:

The author thanks the members of his surgical team, Dr. António Friande, ophthalmologist, and Dr. Jorge Oliveira ENT, for the cooperation. Also the Alcon lab for providing essential bibliography for this chapter.

Commercial interests:

The author informs not to have commercial interest in any of the brands mentioned or displayed in the photographs.

ORBIT



- 22 Enucleation and Evisceration
- 23 Anophthalmic socket
- 24 Congenital Anophthalmia
- 25 Orbital Inflammatory Disease
- 26 Bacterial Orbital Cellulitis
- 27 Thyroid Orbitopathy
- 28 Adult Orbital Tumours
- 29 Pediatric Orbital Tumours
- 30 Ocular Prosthesis

22. Enucleation and Evisceration

Mara Ferreira, João Cabral

Enucleation and evisceration procedures have been performed in medical practice for hundreds of years. The decision to remove an eye must be made individually for each patient. All of the surgical techniques, implant materials, and wrapping materials have their advantages and disadvantages. Whether enucleation or evisceration is performed, the goals of the procedures are the safe removal of the diseased eye, placement of an appropriately sized orbital implant, and enabling the patient to wear a comfortable and cosmetically acceptable ocular prosthesis, because eye contact is such an essential part of human interaction. The best possible result is achieved in cooperation with an ocularist.

The characteristics of the ideal socket and eyelid on the anophthalmic side are a centrally placed and well-covered implant of suitable size and with deep fornices, prosthetic motility, an inferior lid and cul-de-sac that can support the weight and pressure of a prosthesis, a superior lid and supratarsal fold that simulates the fellow eyelid, an anophthalmic socket that is on the same plane as that of the normal side and normal position of the eyelashes.

An implant should not be inserted if orbital infection or trauma with foreign matter contamination are present. In such cases a secondary implant should be placed at a later date.

History

Dating back thousands of years, there is evidence that the Egyptians and Sumerians were making artificial eyes and performing enucleations. It was not until the 1500s that enucleations were reported in the medical literature. Noyes first reported evisceration of the ocular contents in 1874. In 1885, Mules was the first physician to report the use of an orbital implant, a glass sphere, after an evisceration.

Advances in surgical techniques, anesthesia, implant materials, and prosthetics over the past decade have greatly improved surgical outcomes and patient satisfaction. In addition, the ability to deal with the long-term complications of the anophthalmic socket such as enophthalmos, ptosis, contraction, exposure,

extrusion, and lower lid laxity has improved significantly. Today, most patients can confidently return to their daily activities with good cosmetic results following the removal of an eye.

Definition

Enucleation is the surgical removal of the entire eye and the anterior portion of the optic nerve. Evisceration is the surgical removal of the contents of the eye, leaving the sclera shell and extraocular muscle attachments intact.

Indications

Removal of an eye should be fully discussed and understood by the patient and the family. The patient requires caring explanations and psychological support, both before and after the surgery. They must be informed that an ocular prosthesis will be fitted secondarily, approximately 6 weeks after the surgery. Otherwise untreatable intraocular tumors require enucleation. There is still controversy over the choice of enucleation versus evisceration for other indications such as blind painful eye, blind unaesthetic eye, trauma, phthisis bulbi, microphthalmia, endophthalmitis. There has been a trend to opt for evisceration because it is less invasive and may result in a better appearance and function of the socket.

Following severe injury of the globe, there is evidence that the risk of sympathetic ophthalmia, which is very low, can be prevented by removing the traumatized eye within a 10 day period². Sympathetic uveitis is now rare and the risk of it occurring can be minimized by meticulous repair and the use of postoperative steroids. Every effort should be made to preserve the globe, because even with no vision, a viable globe (sometimes with a scleral shell for optimal cosmesis) provides a better psychological and anatomic result than an enucleated or eviscerated globe.

Surgical technique

Preoperatively, the surgeon should mark the forehead on the side of the eye to be removed. In cases where the external appearance of both eyes is normal, the

22. Enucleation and Evisceration

surgeon must, without fail, reexamine the fundus to confirm the pathology. Removal of the wrong eye is one of the greatest disasters that can occur to the ophthalmic surgeon and patient.

Enucleation and evisceration surgery are usually done under general anesthesia, with or without associated bupivacaine 0.5%, lidocaine 2% with adrenaline 1:100,000 in the retrobulbar space using an irrigating canula after the capsule of Tenon has been dissected. Perioperative antibiotics should be considered when implants, especially porous implants, are used.

Since the manipulation of the muscles or applying pressure to the optic nerve or apex can initiate the oculocardiac reflex, care should be taken to ensure that there is no bradycardia or asystole.

The implant can be inserted at the same time as the enucleation or evisceration procedure, or at a later date. The orbital implant can be alloplastic (e.g., polymethyl methacrylate sphere) or autologous tissue (e.g., dermis-fat grafts).

The periocular area is prepared with an aqueous antiseptic and the face draped (Fig. 1).

Enucleation

The lids are separated by a speculum and a 360° conjunctival peritomy is performed, taking care to preserve all conjunctival tissue with Westcott scissors (Fig.2). Tenon's capsule is bluntly dissected from the sclera in all four quadrants with curved Stevens scissors. The rectus muscles are engaged with a muscle hook (Fig. 3), isolated and passed through with a 5-0 absorbable suture (Vicryl®) on a spatula needle, with a locking bite at each edge of the muscle, prior to release from the globe (Fig. 4). Do not strip the intermuscular septum or check ligaments for more than 3 to 4 mm. As the medial rectus is regularly used to grasp the globe while severing the optic nerve, it is best to leave a 2 to 3 mm stump of the tendon, which can be gripped with forceps or suture. The other rectus muscles are severed at their insertions. The oblique muscles are isolated and cut close to the globe but are not secured with sutures, otherwise the inferior oblique muscle can be secured with Vicryl®, detached, and saved for later attachment to the inferior border of the lateral rectus muscle. This use of the inferior oblique muscle as an eventual "hammock" for the orbital implant is more important than to meaningfully enhance anophthalmic socket motility. Once the 6 muscles have been removed from the globe, another attempt is made to sweep the globe free of Tenon's capsule.

Traction is applied to the globe via the residual stump of the medial rectus, which should straighten the optic nerve and allow it to be identified. A curved clamp can be used to identify the optic nerve

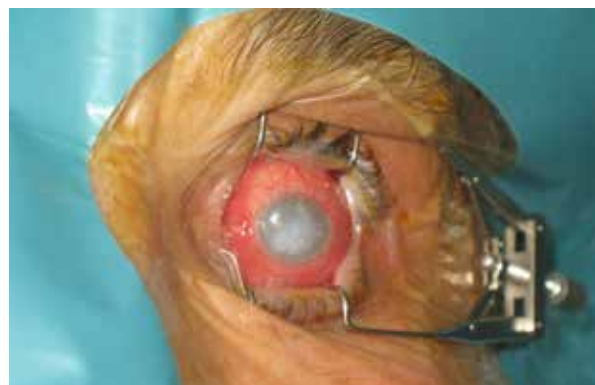

Fig. 1: Neovascular glaucoma in an eye with uveal melanoma.

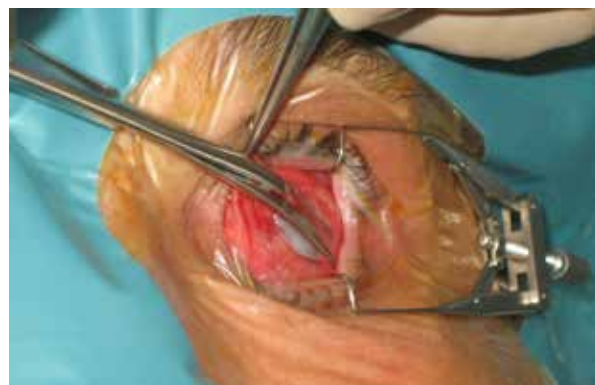

Fig. 2: Conjunctival peritomy.

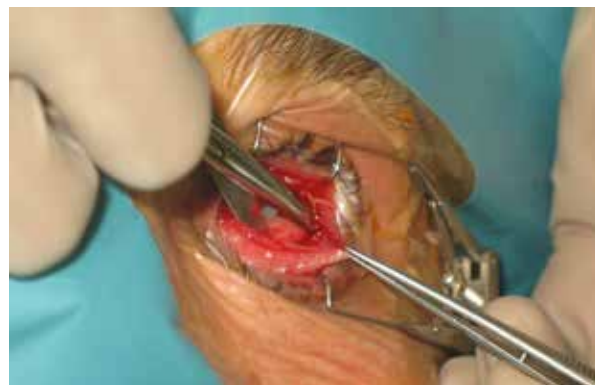

Fig. 3: Dissection of Tenon's capsule.

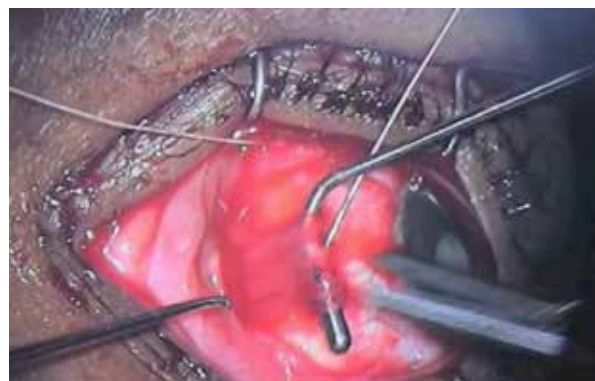

Fig. 4: Isolation of the rectus muscles.

and its associated vessels, except in retinoblastoma. Thin, curved scissors are used to strum and identify the position of the optic nerve, and the blades are

then separated around it and pushed deeper into the orbit before the nerve is cut off. If the eye contains a retinoblastoma or a perioptic melanoma, cut the nerve at least 10-15 mm behind the globe (Fig. 5). The clamp and scissors can be passed along the medial or lateral wall. When using the lateral approach, care must be taken to avoid penetrating the thin medial orbital wall with the tips. The surgeon should inspect the entire globe for intactness and/or unusual findings before submitting the specimen for histopathological examination.

At this point, as the artery has been cut bleeding can be significant. Apply cold sterile saline gauze, or small gauze swabs soaked in adrenaline 1:1,000 or hydrogen peroxide with saline solution 1:1 for 3 to 4 minutes with pressure, or cauterize it.

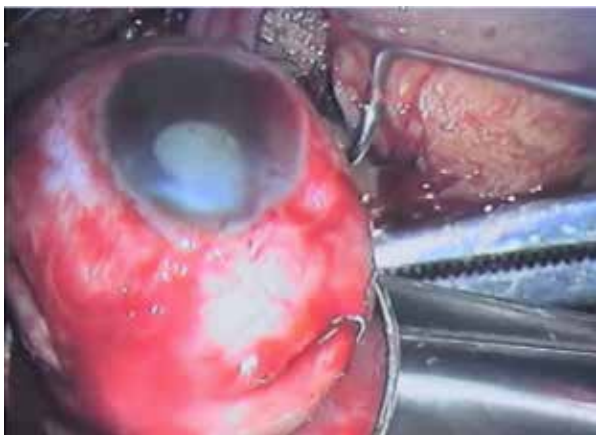


Fig. 5: Cutting the optic nerve.

Sizing balls ranging from 22 to 16 mm are used to gauge the size of an orbital implant that can be safely buried in the orbital tissue, remembering that wrapping the implant with sclera or fascia adds approximately 1-1.5 mm to its overall diameter. Removing a typical 24 mm globe reduces the orbital volume by 7.5 mL; the prosthesis will replace 2 mL, leaving a shortfall of around 5 mL. A 22 mm sphere replaces 5.6 mL, and a 20 mm sphere replaces 4.2 mL.

After the implant has been buried in the socket, the sutures on the rectus muscles are used to secure their distal ends to the implant, or pass over the implant (Fig. 6). The muscles are attached in the following manner. The medial rectus muscle is tied to the lateral rectus muscle in front of the implant. The superior rectus muscle is gently advanced and loosely attached to the inferior rectus muscles. Ptosis may occur if the superior rectus is advanced too far inferiorly. Previously harvested retrobulbar fat and connective tissue can be placed over the exposed surface of the implant to provide a cushion between the suture knots and Tenon's closure to help prevent postoperative implant extrusion. Tenon's capsule and the conjunctiva are sutured separately with Vicryl® 5-0 and 7-0 interrupted sutures, (Fig. 7) respectively.

Antibiotic ointment, an ocular conformer and a firm pressure bandage are applied for 48 hours.

After 6 weeks, the prosthesis can be made by an ocularist.

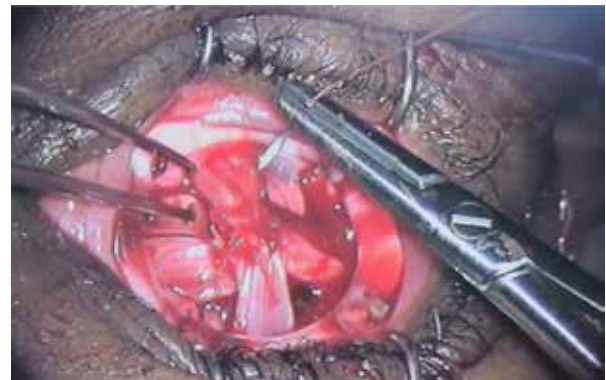


Fig. 6: Rectus muscles over the implant.

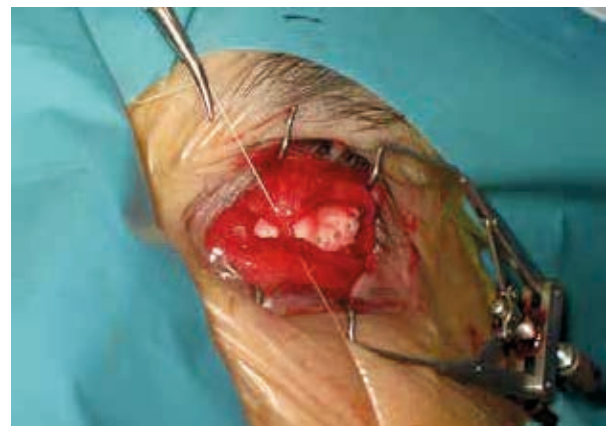

Fig. 7: Tenon's capsule suture.

Evisceration

The lids are separated by a speculum. A 360° conjunctival limbal peritomy is performed (Fig. 2). The capsule of Tenon and conjunctiva are separated posteriorly and dissected off the sclera in 2 layers up to the insertions of the rectus muscles, and posteriorly between the rectus muscles where the radial sclerotomy is to be done (Fig. 3).

A full-thickness incision is made around the corneal limbus with a sharp blade or Colorado tip and the entire corneal button removed (Fig. 8). An evisceration spoon is used to remove all the ocular contents (Fig. 9). It is inserted in the suprachoroidal space. It is important to remove all pigment from the inner scleral layer. Gauze can be used to abrade the scleral shell, and hydrogen peroxide soaked pledgets can be inserted and then washed with saline to control capillary bleeding. If evisceration is performed for intraocular infection, the sclera should be irrigated with antibiotic solution (gentamicin or as guided by the antibiogram) or povidone-iodine surgical paint mixed 1:1 with normal saline. Two or four radial sclerotomies with perineurotomy, or circumferential sclerotomies are done to allow an implant bigger

22. Enucleation and Evisceration

than the 16 mm to be accommodated in the scleral shell. (Fig.10 to 12) The anterior scleral defect is sutured (imbricating sutures create a scleral overlap and provide a two layer closure) using 5-0 Ethibon® (Fig. 13) . The Tenon capsule and the conjunctiva are closed in separate layers with 5-0 and a 7-0 Vicryl® (Fig. 7). Antibiotic ointment and a temporary

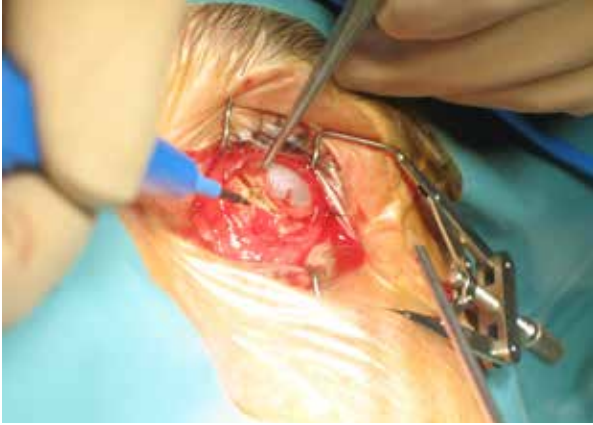

Fig. 8: Keratectomy.

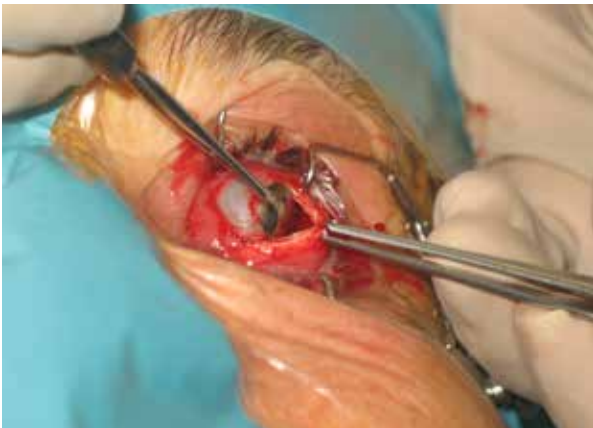

Fig. 9: Evisceration spoon removing the ocular contents.

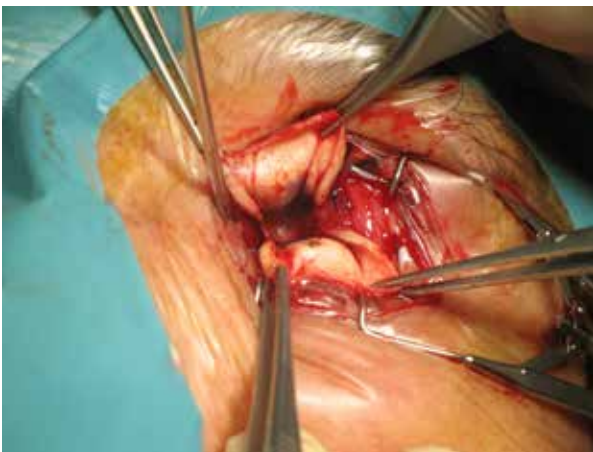


Fig. 10: Two radial sclerotomies.

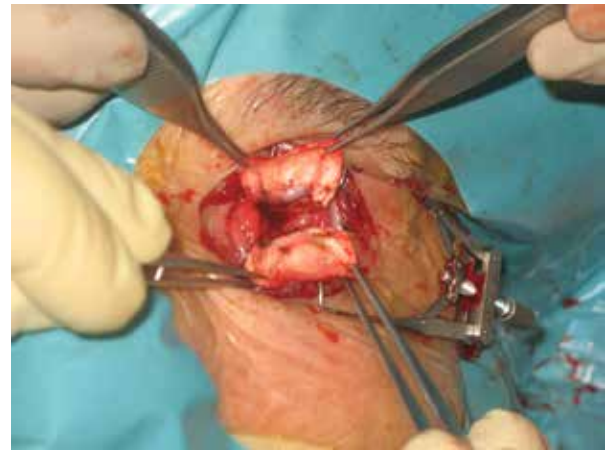

Fig. 11: Two radial sclerotomies with perineurotomy.

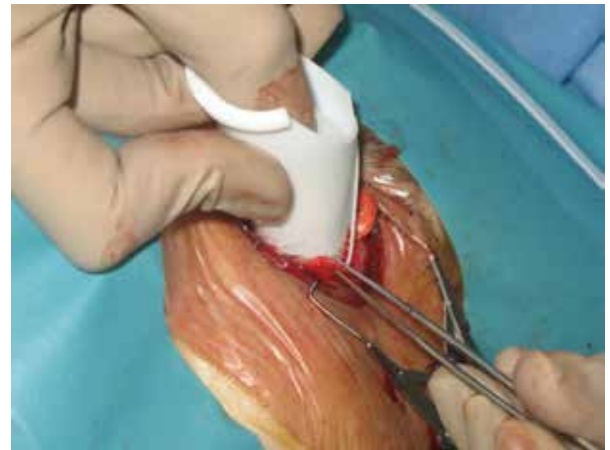

Fig. 12: Posterior implant placement.

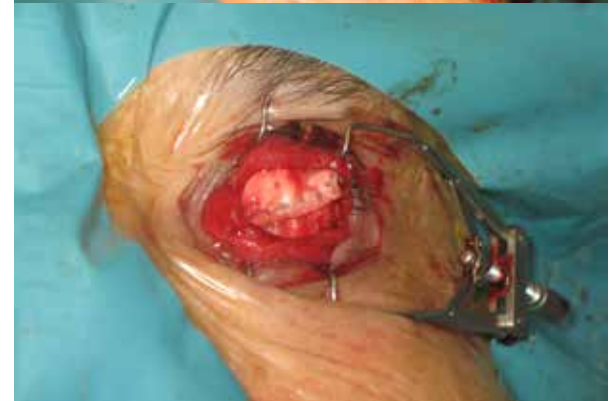
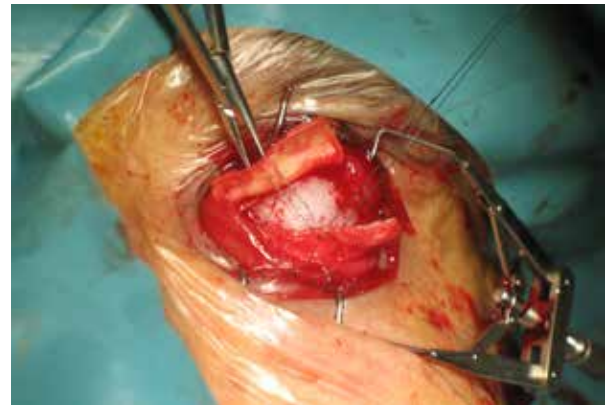
Fig. 13: Closing the sclerotomies.

conformer are inserted, and 6 to 8 weeks later the ocularist can create a definitive artificial eye.

Complications

Postoperative orbital hemorrhage can occur from the central retinal artery, the cut extraocular muscles, or vessels within the orbital fat. Usually reabsorbs after several weeks.

Orbital infection is always a concern when an implant is inserted.

Displacement or extrusion of the implant may be related to the surgical technique, to improper selection of the orbital implant size, infection or hematoma. If the extrusion is small it can be patched with fascia, if it is big, the implant should be removed and a new implant or dermo-fat graft inserted.

Post enucleation socket syndrome is discussed in another chapter.

Bibliography

1. Collin JRO. A Manual of Systematic Eyelid Surgery. 3rd Edition. Elsevier. 2006.
2. Salcedo G, Prada MC. Pérdida ocular. Auroch Health Care. 2008
3. Toledano N, Prada MC. Manejo de la cavidade anoftálmica. Memory Chip S.L. 2002
4. Tyers AG, Collin JRO. Colour Atlas of Ophthalmic Plastic Surgery. 3rd Edition. Elsevier. 2008.
5. Rootman J. Orbital surgery. A conceptual approach. 2nd Edition. Wolters Kluwer/Lippincott Williams & Wilkins. 2014.
6. Yanoff M, Duker JS. Ophthalmology. 4th Edition. Saunders Elsevier. 2014.
7. Singh AD, Damato BE, Peér J, Murphree AL, Perry JD. Essentials of Ophthalmic Oncology. SLACK Incorporated. 2009.
8. Spaeth GL, Meyer HVD, Goldberg I, Kampik A. Ophthalmic Surgery Principles and Practice. 4th Edition. Elsevier Saunders. 2012.
9. Levine MR. Manual of Oculoplastic Surgery. 4th Edition. SLACK Incorporated. 2010.
10. Tse DT. Colour Atlas of Oculoplastic Surgery. 2nd Edition. Wolters Kluwer/Lippincott Williams & Wilkins. 2011.
11. Dutton JJ. Atlas of Oculoplastic and Orbital Surgery. Wolters Kluwer/Lippincott Williams & Wilkins. 2013.
12. Nerad JA. Techniques in Ophthalmic Plastic Surgery. A Personal Tutorial. Saunders Elsevier. 2010.

23. Anophthalmic socket

Consuelo Prada, Maria Varela

Anophthalmic cavity syndrome was first described by Vistnes in 1976, but the term post enucleation/evisceration socket syndrome (PESS) used now was coined by Tyers and Collin in 1982.

PESS includes enophthalmos, superior sulcus syndrome, lower eyelid laxity and upper eyelid ptosis (Fig.1). These changes are present in all anophthalmic cavities in different degrees.

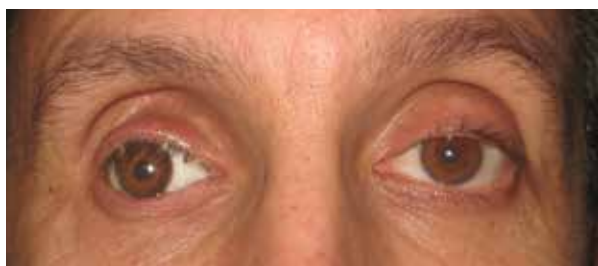

Fig. 1: Post-evisceration socket syndrome, enophthalmos and deep sulcus.

A few mechanisms have been described to explain these changes: orbital fat tissue atrophy, muscular cone migration, fractures with bone loss or orbital fat herniation. Inadequate orbital volume replacement with small implants would also explain enophthalmos and superior sulcus deformity.

Orbital contents undergo progressive remodeling because of gravitational forces and laxity of the orbital soft tissue. There is displacement of the structures with a shift from a superior to posterior and posterior to an inferior position. These changes together with the implant and external prosthesis weight contribute to lower eyelid laxity. Lower eyelid ptosis may be caused by the enucleation or evisceration surgery itself, or result from its treatment, surgical iatrogeny or damage to the superior rectus/levator complex; disinsertions and elongations have been described in various studies.

In addition to the above alterations (Fig. 2) PESS can also include conjunctival sac shortening (Fig. 3). This contraction hampers adaptation to and retention of the external prosthesis (Fig. 4).

The management of orbital contraction depends on its severity and vascularization, since poorly

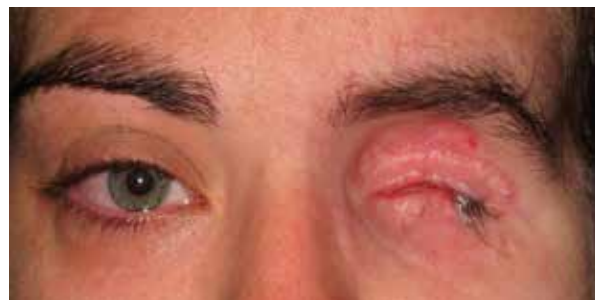

Fig. 2: Socket syndrome.

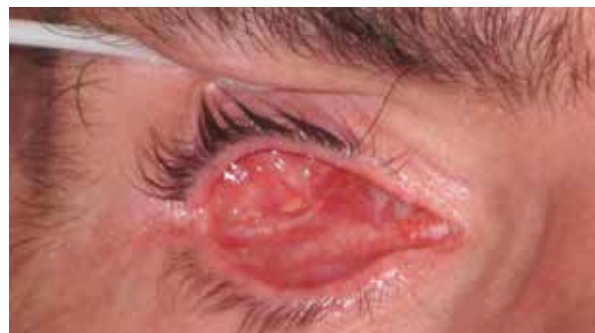

Fig. 3: Retracted conjunctival fornices.

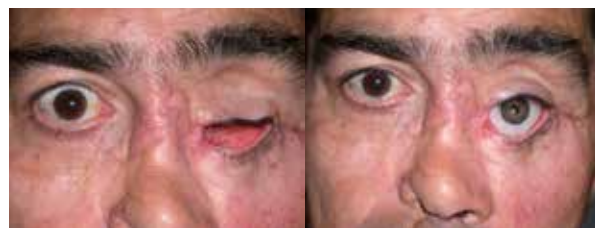

Fig. 4: Evisceration after traumatic lesion. Conjunctival retraction affects maladaptation to the prosthesis.

vascularized orbits will have a worse prognosis with certain types of grafts, especially irradiated orbits.

To prevent PESS, the surgical technique should be the least traumatic and aggressive possible.

The choice of the implant size is of paramount importance, since enophthalmos is directly related to inadequate volume replacement.

Ocular volume replacement depends on the axial length and varies from 6.9 to 9 ml. The selected implant usually replaces 4 ml and the external prosthesis around 1.5 to 4 ml.

23. Anophthalmic socket

The choice of implant size is also based upon the fellow eye axial length obtained with biometry. In general, implant size will be between 21 and 23 mm, with smaller implants being avoided.

External prosthesis should be regarded as an adjunct to achieve an adequate volume, as a prosthesis that is too heavy will induce ptosis, lower lid laxity and adversely affect motility.

A properly sized implant will minimize the risk of enophthalmos and a deep sulcus and prevent ptosis, since it helps to keep the levator muscle in an appropriate position.

In this chapter we demonstrate the available tools to improve volume and prosthesis adaptation, and thus achieve a better final cosmetic result with psychological benefits for our patients.

Most of the described surgical techniques are conducted under general anesthesia. Cavity manipulation and muscle traction can be very traumatic for the patient. Lipostructure can be performed under sedation with local anesthesia in the donor site, and retrobulbar anesthesia in the orbit, to allow a comfortable and safe procedure for surgeon and patient.

Secondary Implant (Fig. 5)

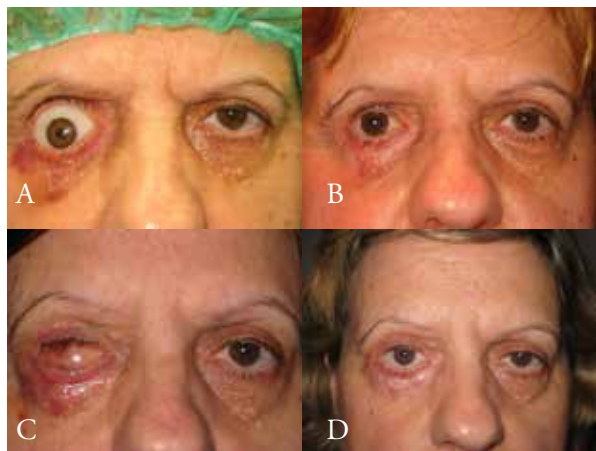


Fig. 5: Before and after treatment. First surgery with secondary Medpor® implantation. To correct persistent enophthalmos, lipostructure is performed in a second intervention.

We advise a secondary implant when cosmetic issues are a major problem. In these patients multiple interventions have a deleterious effect including cavity contraction and surgical failure, which worsen the condition. Careful patient selection is crucial.

Of the types of implants available, we tend to prefer the porous polyethylene implant because, in our experience, this offers the best results: it allows fibrovascular ingrowth with good integration and motility, thus lessening extrusion risk.

An orbital imaging scan with coronal and axial sections, without contrast, confirms the absence of

an implant and identifies the rectus muscle.

If the implant is not large enough to correct enophthalmos or if the conjunctival fornices need to be enlarged, we can associate a dermis-fat or an oral mucosa graft procedure (see below).

In previously eviscerated patients, after opening the conjunctiva and Tenon's capsule we isolate the four rectus muscles to improve prosthesis motility (Fig. 6).

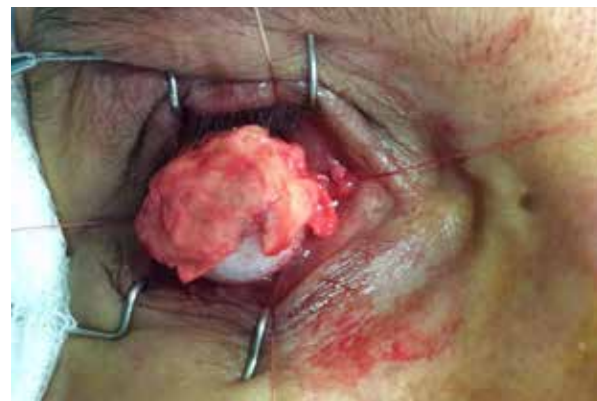

Fig. 6: Medpor® implant covered with autologous sclera. Rectus muscles are isolated to be sutured to each other or to the dermis-fat graft tissue.

If a scleral stub is found, we open it, introduce the implant and cover it. We should explore to see if the optic nerve has been sectioned, if not it should be done to avoid implant extrusion risk.

The rectus muscles should be sutured to the sclera or in pairs with the antagonist. When the muscles cannot be identified, we should approximate the tissues where they should be, in theory. In many cases this yields good prosthesis motility as a final result, because it manages to include some fibers of the atrophic muscle among the sutured tissues. Finally we close with a layered suture.

In enucleated patients, we can also use donor sclera to cover the anterior portion of the implant. The rectus muscle is also isolated and sutured afterwards to the scleral tissue, to improve prosthesis motility. The procedure then continues as described before.

Dermis-Fat Graft (Fig. 7)

The first surgeries to implant fat grafts in anophthalmic cavities were performed by Barraquer at the beginning of 20th century. The graft only included fat tissue and there was a significant early reabsorption rate. In the 80s, Petrilli and Smith started to include dermis tissue in their fat grafts, extending the graft's survival and improving its structural stability.

The indications for dermis-fat grafts are:

1. implant extrusion;
2. volume expanders in PESS, with or without conjunctival insufficiency;
3. primary graft in orbits that have been empty,

eviscerated or enucleated for a long time, where secondary implant has an increased risk of extrusion because of poor vascularization;

4. deep sulcus correction in anophthalmic cavities; in these cases we would rather use lipostructure, which is less invasive in more manipulated cavities (see below).

Dermis-fat grafts are a good choice when the required conditions are met.

The cavity should have good vascularization, since ischemic tissue will lead to graft necrosis. In very contracted orbits or irradiated cavities, the mucous membrane graft is preferred (see below) because, even though it does not achieve the same optimal cosmetic results, the success rate will be higher.

Dermis-fat graft is usually extracted from the supero-external quadrant of the gluteal region (Fig. 7). This site contains abundant fat tissue, is safe and more comfortable for the patient post-operatively.

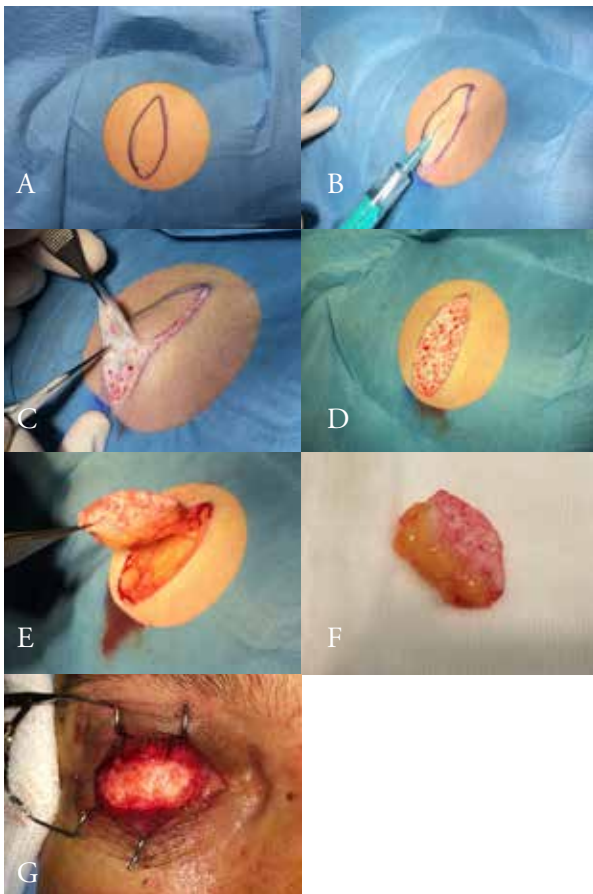


Fig. 7: Obtaining of the dermis-fat graft. An oval is drawn. Anesthetic is injected beneath the epidermis to facilitate epidermis and hair follicle removal. Anesthetic is injected deeper to lessen the bleeding. Draw the graft borders with the scalpel and remove the epidermis, sparing the dermis. Deepen the limits of the graft to the desired thickness. The graft is sutured to the conjunctiva with slight conjunctival overlap to facilitate coverage.

The donor site skin should be marked with an oval about 20-25 mm long. Local anesthesia, bupivacaine and epinephrine 1:200,000, is given by injection

beneath the epidermis to facilitate the dissection and extraction of the tissue. Injecting the anesthetic deeper allows its total removal with a no. 11 scalpel. It is advisable to remove the epidermis and its hair follicles while keeping the dermis intact. After this we deepen the graft borders with the scalpel and with scissors we remove a piece of tissue about 20-25 mm thick, depending on the size of the receptor orbit. Coagulate any significant bleeding and suture by layers with Vicryl® 4/0 for deeper dermis and silk 5/0 for the skin.

The graft is placed in the orbit and the four rectus muscles are sutured to it, if possible, or the neighboring tissues if the muscles are not identifiable, with Vicryl® 6/0. The suturing of the muscles will enable prosthesis motility and graft vascularization. After that, the Tenon's capsule and conjunctiva are sutured to the dermis with absorbable sutures as Vicryl® 6/0, to allow posterior conjunctival coverage. In cases of implant extrusion, the conjunctiva and Tenon's capsule should be dissected and separated from the implant. If the implant is not considered to be infected it can be kept, but debriding and removing its anterior surface with a no. 22 scalpel lowers the risk of infection. If the implant is considered to be infected it should be completely removed and replaced by another implant or dermis-fat graft if the orbital conditions allow (Fig. 8).

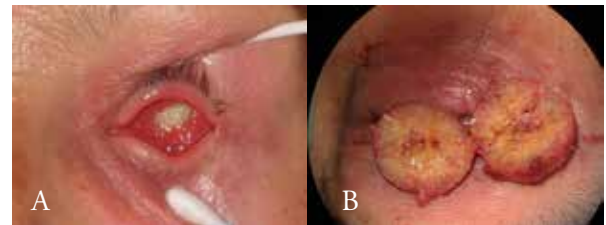


Fig. 8: Exposure of a Medpor® implant. In the first picture the implant is infected and must be completely removed, with posterior reconstruction of the cavity.

Conjunctival growth and coverage of the graft takes about 1 to 3 months, with late coverage cases still having good outcomes. We usually send the patient for prosthesis adaptation 4 weeks afterwards, if the coverage is progressing well, even if it is only partial (Fig. 9).

Oral Mucosa Graft (Fig. 10)

Conjunctival sac retraction is a common complication in eviscerated or enucleated patients, being found in about 25% of cases (Fig. 3).

In cases with inferior fornix contraction we see an anterior rotation and displacement of the prosthesis, usually caused by the anterior migration of orbital fat and retractor disinsertion. In this case, it may suffice to reposition the inferior fornix with 3-4 transfixing

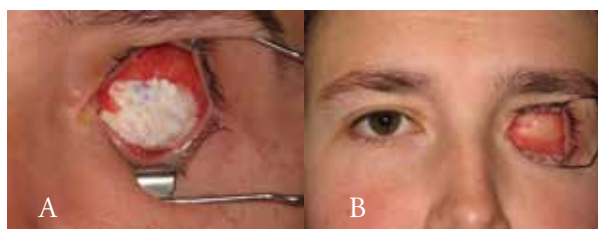


Fig. 9: Dermis-fat graft with conjunctival coverage, 1.5 months after surgery. Total coverage 3 months after surgery.

sutures fixing the conjunctival sac with the orbital rim for a period of 3 weeks.

Indications for oral mucous membrane graft are:

1. moderate retraction of conjunctival fornices;
2. conjunctival deficit after enucleation or evisceration.

We do not use oral mucous membrane in implant extrusion cases, because of the poor vascularization of the underlying tissues and consequent low success rate. To obtain the graft, we use the upper lip inner mucosa. Although the lower lip is more practical for the surgeon the upper lip will be more comfortable for the patient post-operatively.

We expose the upper lip with the aid of a continuous 5-0 silk suture of 3 stitches and pull upwards, with minimal damage (Fig. 10). Mark the graft with a no.11 scalpel 50% wider than the orbit defect. Always leave 3-5 mm from the border of the lip and from its frenulum and be generous with its width, since mucous folds are considered a good result, as the graft tends to retract afterwards.

To ease the dissection of the mucous membrane, a local anesthetic is infiltrated (bupivacaine with epinephrine 1:200.000) and a no. 11 scalpel is used to smoothly deepen the graft limits and the graft is removed with Westcott scissor.

Once the graft has been harvested, the mucosa should be cleaned and smoothed. There is no need to remove all the papilla since they are also responsible for cavity's nutrition.

At the donor site, incision edges are approximated with Vicryl® 4-0, without complete closure, to ease its healing and avoid labial entropion. When present, entropion usually resolves spontaneously.

The oral incision is treated with regular gargles of chlorhexidine 2% and hyaluronate.

The oral mucosa graft is sutured to the conjunctiva with Vicryl® 7-0, without tension.

As in any surgery to improve conjunctival fornices, with dermis-fat or oral mucosa graft, a conformer is placed and fixation sutures are placed from the conjunctival fornix to the orbital rim, through the skin, and protected with silicone bolsters. This suture remains in place for 6-7 weeks (Fig. 11).

The graft integrates after about 1 month.

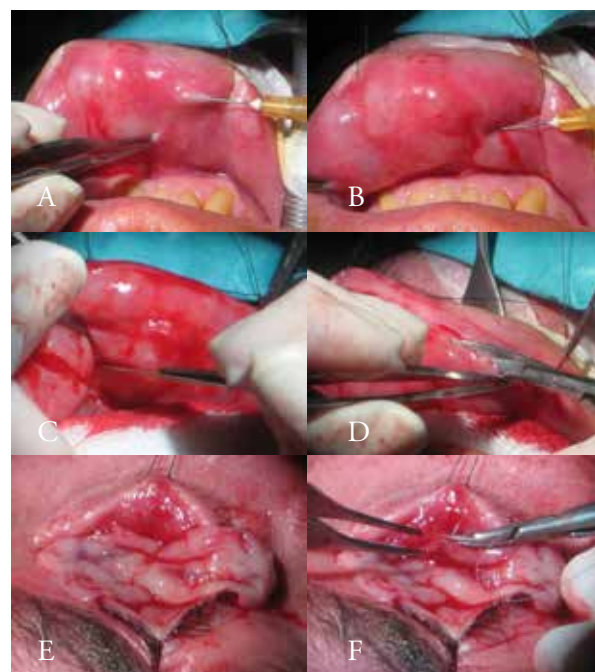

Fig. 10: Oral mucosa graft: Anesthetic injection will help tissue dissection. The desired tissue is delimited with a cold scalpel and dissected with a Westcott scissor. Graft suture with Vicryl®. The graft should be slightly larger than the defect, since it will retract.

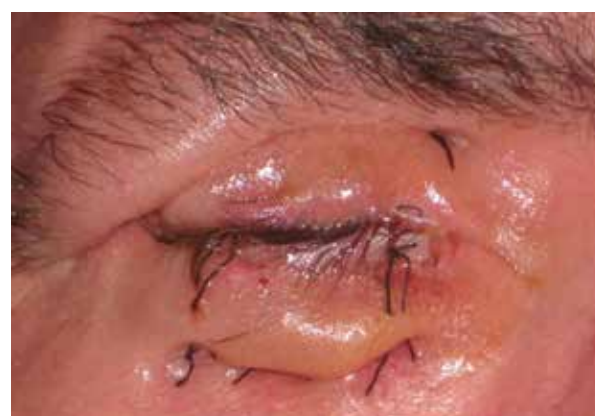

Fig. 11: Fixation sutures of the conjunctival fornices and tarsorrhaphy to improve cavity prognosis.

This surgery has good results, as it helps prosthesis adaptation with 90% of functional success, depending on cavity status.

Lipostructure (Fig. 13)

Autologous dermal grafts have been used in aesthetic and reconstructive medicine since the end of the nineteenth century. The procedure was first described in 1883 by Neurer for facial reconstruction. In ophthalmology, Lambert in 1990 used this technique in an exenterated cavity. Coleman's work means that today we have a safe technique to obtain purified adipocytes.

Adipose tissue is very delicate and easily damaged by mechanical or chemical action; the transplant's success will depend on the careful handling of the tissue.

For this technique we will need specific equipment,

including liposuction and lipoinjection cannulas as well as a centrifuge (Fig. 12).

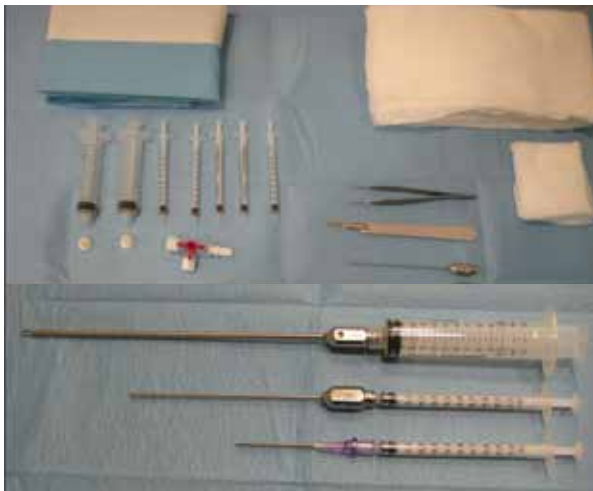

Fig. 12: Lipostructure material: 1 ml and 10 ml syringes, 3-way valves, Adson forceps, scalpel no. 15, 4 mm liposuction cannula, 2 – 3 mm lipoinjection cannula.

For the donor site, periumbilical incisions of 3 mm are performed and injected with local anesthetic and Ringer's solution; this injection will ease fat tissue extraction. Other solutions such as glucose or saline are not recommended because their osmolarity may damage fat tissue.

After anesthesia, proceed with liposuction with the suction cannula. This cannula is connected to a 10 cc syringe with negative pressure while continuous uniform movements are performed beneath abdominal fat tissue.

After collection, the syringes without the plunger are closed and placed in the centrifuge. Coleman recommends centrifuging at 3000 rpm for 3 minutes. In our technique, described by Dr Tazartes and Dr Male, we centrifuge at 1000 rpm for 1-2 seconds, remove the free floating fat, repeat the procedure and centrifuge a third time at 2000 rpm to reduce adipose tissue damage.

After centrifuging, the contents of the syringes are divided into 3 phases: the upper layer has a liquid oily consistency, the middle one is solid fat and the bottom one is serum.

The contents are decanted to remove the upper and lower phases, by inclining the syringe, after removing the cover. The remaining fat is slowly placed in 1 cc syringes with stopcocks.

Lipostructure is a safe and durable autologous filling technique. Its indications in ophthalmology are:

1. Correction of deep superior eyelid sulcus.
2. Enophthalmus correction in an anophthalmic cavity, by injecting fat into the orbital apex.
3. Correction of dark circles, by injecting the fat

anterior to the orbicularis muscle, to decrease tissue transparency through the skin.

4. In lower eyelid retraction. Fat gives stability to the eyelid; in the presence of fat atrophy with lid retraction this is the treatment of choice.

For the injection, it is recommended to create multiple tunnels and slowly inject the fat to ensure graft survival.

In the first 24 hours, fat tissue graft undergoes an ischemic process with inflammatory reaction. Around the fourth day after surgery, vascularization appears in a centripetal direction, and so the center of the graft may undergo ischemia for a longer period with consequent necrosis. To improve graft survival it is recommended to inject small amounts of fat separately.

The resorption rate after six months ranges from 30 to 70%, according to the literature. In our experience, we inject 10% more than the desired effect, since we have not seen great resorptions.

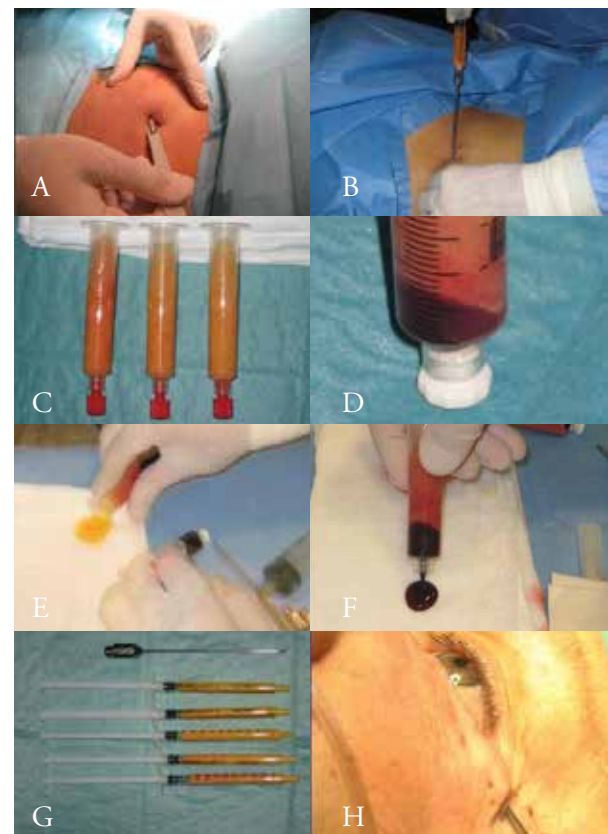


Fig. 13: Perform two periumbilical incisions 1 cm extension. Liposuction with the cannula. The obtained material is centrifuged to separate the different phases (oil, adipose and hematic). The hematic and oily phases are discarded and the adipose tissue is placed in the appropriate syringes with cannulas for injection. During adipose tissue injection, multiple tunnels should be created to improve adipocyte survival.

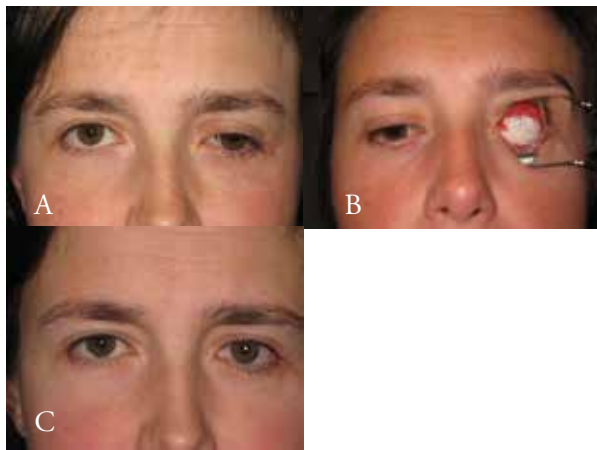

Fig. 14: Before and after treatment after placement of dermis fat graft to correct enophthalmos.

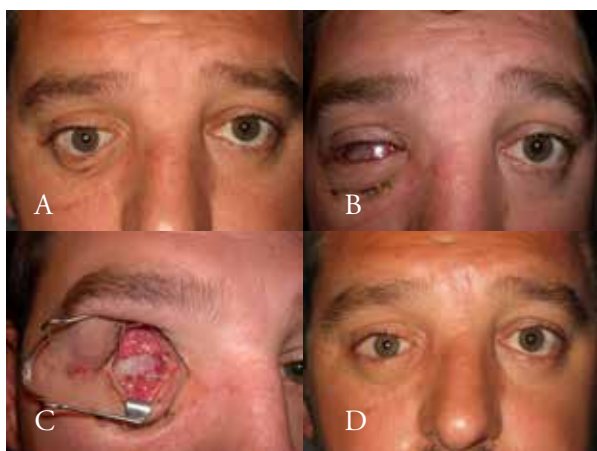

Fig. 15: Before and after surgery with oral mucosa graft and tarsal strip to correct inferior fornix insufficiency and lid laxity.

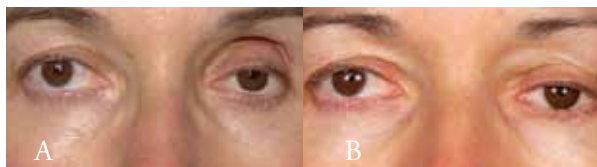


Fig. 16: Before and after lipostructure treatment to correct a deep superior sulcus.

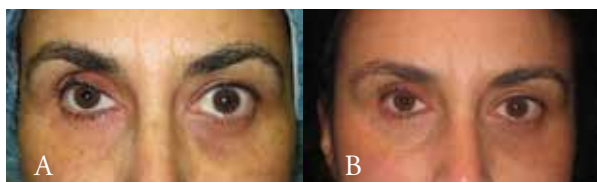


Fig. 17: Before and after lipostructure treatment to correct enophthalmos.

REFERENCES

1. Vistnes LM. Mechanism of upper lid ptosis in the anophthalmic orbit. *Plast Reconstr Surg.* 1976;58:539-45.
2. Tyers AG, Collin JRO. Orbital implants and post enucleation socket syndrome. *Trans Ophthalmol Soc Uk* 1982; 102:90-2.
3. Christopher S, Hughes M, Krizhner M. Anophthalmic syndrome: a review of management. *Ophthal Plast Reconstr Surg.* 2014;30:361-5.

4. Baylis H, Shorr N. Correction of problems of the anophthalmic socket. In: Mc Cord CD Jr, ed. *Oculoplastic Surgery.* New York: Raven Press, 1981:313-26.
5. Shah CT, Hughes MO, Kirzhener M. Anophthalmic syndrome: a review of management. *Ophthal Plast Reconstr Surg.* 2014; 30:361-5.
6. Sadiq SA, Mengher LS, Lowry J, Downes R. Intefrated orbital impolants. A comparison of hydroxyapatite and porous polyethylene implants. *Orbit* 2008;25:37-40.
7. Barraquer L. Enucleación con injerto de tejido adiposo en cápsula de Tenon. *Arch Oft His-Am* 1901, 1:82-84.
8. Smith B, Petrelli R: Dermis-fat graft as a movable implant within the muscle cone. *Am J Ophthalmol* 1978, 85:62-69.
9. Guberina C, Hornblase A, Meltzer MA, Soarez V, Smith B. Autogenous dermis-fat orbital implantation. *Arch Ophthalmol.* 1983, 101:1586-1590.
10. Bhattacharjee K, Bhattacharjee H, Kuri G, Das JK, Dey D. Comparative analysis of use of porous orbital impolant with mucus membrane graft an dermis fat graft as a primary procedure in reconstruction of severely contracted socket. *Indian J Ophtalmol.* 2014 62:145-53.
11. Nentwich MM, Schebitz-Walter K, Hirneiss C, Hinstschich C. Dermis fat grafts as primary and secondary orbital implants. *Orbit.* 2014 33: 33-8.
12. Kim CY, Woo YJ, Lee SY, Yoon JS. Postoperative outcomes of anophthalmic socket reconstruction using an autologous buccal mucosa graft. *J Craniofac Surg.* 2014, 25: 1171-4.
13. Kim HE, Jang SY, Yoon JS. Combined orbital floor wedge implant and fornix reconstruction for postenucleation subkeb socket syndrome. *Plast Reconstr Surg.* 2014, 133:1469-75.
14. Mai C, Bertelmann E. Oral mucosal grafts: old technique in new light. *Ophthalmic Res.* 2013, 50:91-8.
15. Pu LL, Coleman SR, Cui X, Ferguson RE Jr, Vasconez HC. Autologous fat grafts harvested and refined by the Coleman technique: a comparative study. *Plast Reconstr Surg.* 2008, 122:932-7.
16. Defossez T, Garson S, Benabid L, Berthout A, Malthieu D, Milazzo S. Comblement d'une cavité orbitaire éviscérée par greffe d'adipocytes selon la technique de Coleman, après expulsion d'implant. *J Fr. Ophtalmol.* 2007, 30: 610-615.
17. Huss FR, Kratz G. Adipose tissue processed for lipoinjection shows increased celular survival in vitro when tissue engineering principles are applied. *Sacand J Plast Reconstr Surg Hand Surg.* 2002, 36: 166-71.
18. Pulsfort AK, Wolter TP, Pallua N. The effect of centrifugal forces on viability of adipocytes in centrifuged lipoaspirates. *Ann Plast Surg* 2011; 66:292-295.
19. Pu LL, Coleman SR, Cui X, Ferguson RE Jr, Vasconez HC. Cryopreservation of autologous gat grafts harvested with the Coleman technique. *Ann Plast Surg.* 2010, 64: 333-7.

24. Congenital Anophthalmia

Guilherme Castela, Cátia Azenha

Definitions

Anophthalmia: complete absence of an eye as a result of a developmental defect. This diagnosis requires the absence of neuroectodermal structures confirmed by histological examination.

Clinical anophthalmia: when a small cystic remnant of globe is seen.

Microphthalmia: congenital underdevelopment or acquired reduction in the size of the globe. It is defined as an axial length less than 21 mm in an adult or less than 19 mm in 1-year-old child¹.

Anophthalmia and microphthalmia represent a phenotypic continuum. The complete absence of the eye is rare, usually eye remnants are found and the term clinical anophthalmia should be used instead². Because of this, most cases of clinical anophthalmos probably are extreme microphthalmos^{3,4}.

Microphthalmia can be simple, relating to a structurally normal but smaller eye, or complex when associated with other ocular disorders, such as coloboma, orbital cyst, sclerocornea, Peters anomaly, fetal vasculature persistency or retinal dysplasia. It can occur isolated or in a syndromic context. Severe microphthalmia is defined as an axial length at birth under 10 mm or under 12 mm at 1 year of age¹.

Anophthalmia is frequently associated with other malformations, including those of the optic nerve, chiasm and optic tracts, as well as palpebral phimosis and conjunctival sac atresia.

Epidemiology

Congenital anophthalmia has a prevalence ranging from 0.6 to 4.2 per 100,000 births and microphthalmia around 2 to 17 per 100,000 births [5-8]. When combined these conditions affect up to 0.7 - 1.0 per 10 000 births, without sex predilection^{6,9,10}.

Epidemiological data suggests maternal age over 40, multiple births, low birth weight, low gestational age, lower socioeconomic status and lower maternal education as risk factors^{6,10}. A recent prospective study in the United Kingdom also revealed a higher prevalence in Pakistani and Scottish children, probably caused by genetic and environmental factors. This requires further investigation⁸.

Etiology

Even though a genetic disease or intrauterine factor is identified in a small number of patients, the vast majority of cases of anophthalmos and microphthalmos are sporadic and idiopathic.

The precise pathogenesis of anophthalmia/microphthalmia remains unknown.

Congenital anophthalmia/microphthalmia is a developmental anomaly that results from an insult to the embryo after the optic vesicle outgrowth¹. Insults early on - 1 to 4 weeks of gestation - result in primary or secondary anophthalmos while insults during the second stage of development - 4 to 8 weeks - result in degeneration and regression of the elements already formed (degenerative anophthalmos)^{11, 12}. Anophthalmia reflects the incomplete invagination of the embryonic optic vesicle, at the fourth week of gestation; and microphthalmia is the consequence of its incomplete closure, at the seventh week of gestation¹³.

The high rate of intracranial anomalies seen in patients with bilateral anophthalmia suggests a more generalized maldevelopment of the forebrain structures and failure of formation or degeneration of the optic vesicles during early gestation¹¹.

Epidemiological studies have suggested both heritable and environmental factors as etiological factors for anophthalmia-microphthalmia¹⁴ (table.1). The association between congenital anophthalmos or microphthalmos and a variety of syndromes makes it important for such patients to undergo genetic evaluation and counselling.

Evaluation

A systematic ophthalmological and pediatric evaluation is essential.

The diagnosis is based upon clinical and imaging criteria. To establish the cause a comprehensive medical history, physical examination, family history and ancillary exams (including imaging, karyotyping and molecular or genetic testing) are required.

Ophthalmological assessment

The diagnosis is made by inspection and palpation

24. Congenital Anophthalmia

Table.1: Causes of anophthalmia

<p>Congenital</p> <p>In-uterus infections: rubella, CMV, toxoplasmosis</p> <p>Drug exposure: thalidomide, alcohol, LSD</p> <p>Vitamin A deficiency</p> <p>Radiation</p> <p>Trauma</p> <p>Autosomal dominant, recessive, X-linked, gene SOX2, PAX6, OTX2, CHX10 and RAX gene mutation, chromosomal duplications, deletions and translocations</p>
<p>Associations¹</p> <p>Isolated</p> <p>Microphthalmos with orbital cyst</p> <p>Foetal vasculature persistency</p> <p>Retinopathy of prematurity</p> <p>Congenital rubella syndrome</p> <p>Congenital toxoplasmosis</p> <p>Congenital syphilis</p> <p>Posttraumatic</p> <p>Postinflammation (herpes, CMV)</p> <p>Postradiation</p> <p>Hallerman-Streiff syndrome</p> <p>MIDAS syndrome (microphthalmia, dermal aplasia, sclerocornea)</p> <p>Lowe syndrome (oculocerebral-renal disease)</p> <p>Norrie syndrome</p> <p>Warburg syndrome</p> <p>Meckel syndrome</p> <p>Trisomy 13 and 18</p> <p>Others</p>

and by measuring corneal diameter and axial length, when a globe is present. In cases of microphthalmos the globe may be extremely small with microcornea or sclerocornea, without recognizable intraocular landmarks.

If the eye has function, visual acuity must be determined. Visual evoked potentials may be useful.

Both eyes must be examined, since in unilateral cases the fellow eye may show subtler abnormalities such as coloboma, optic nerve hypoplasia, retinal dystrophy, or even cataract.

The orbitopalpebral exam must assess: orbital volume, eyelid size and function (phimosis, ptosis, lashes malpositioning), conjunctival socket, ocular motility if present, eyebrow position, and other associated malformations. Facial symmetry should also be assessed; however, early in life orbitofacial asymmetry may not yet be apparent.

Examination under general anesthesia is sometimes necessary for uncooperative children. Possible orbital and eyelid findings associated with anophthalmos/microphthalmos are listed in tables 2 and 3. (Fig. 1 to 5)

Table.2: Orbital findings in Anophthalmos/Microphthalmos

<p>Orbital Findings</p> <p>Small orbital rim and entrance</p> <p>Reduced size of bony orbital cavity (micro-orbit)</p> <p>Extraocular muscles absent</p> <p>Lacrimal gland may be absent</p> <p>Small and underdeveloped optic foramen</p>

Table.3: Orbital findings in Anophthalmos/Microphthalmos

<p>Eyelid findings</p> <p>Foreshortening of the lids horizontally and vertically</p> <p>Palpebral phimosis</p> <p>Absent or decreased levator function with decreased lid folds</p> <p>Contracted orbicularis oculi muscle</p> <p>Contracted and shallow conjunctival fornix (especially inferiorly)</p>

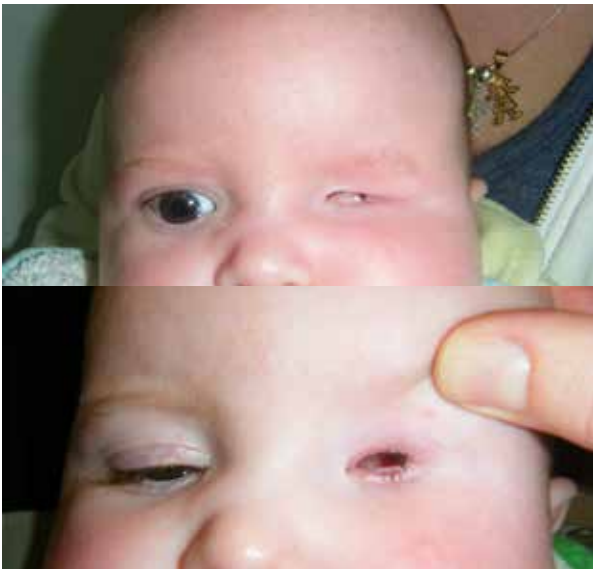

Fig.1: Left anophthalmos, with palpebral fimosis and contracted conjunctival socket.

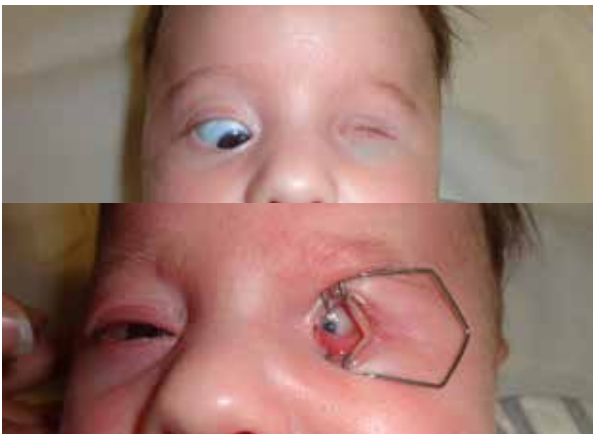

Fig.2: Severe left congenital microphthalmos.

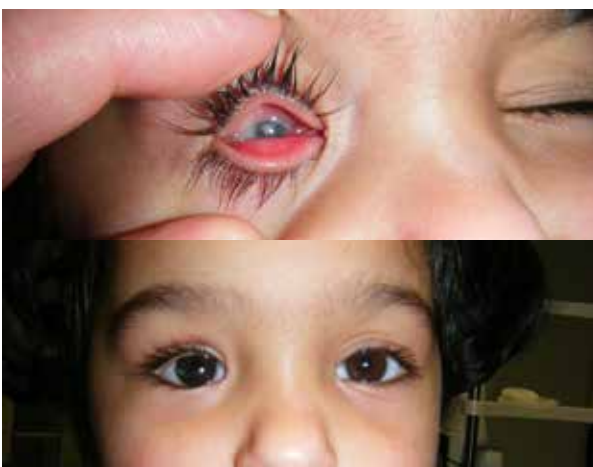

Fig.3: Severe right microphthalmos. Rehabilitation with an ocular prosthesis, preserving the microphthalmic eye.

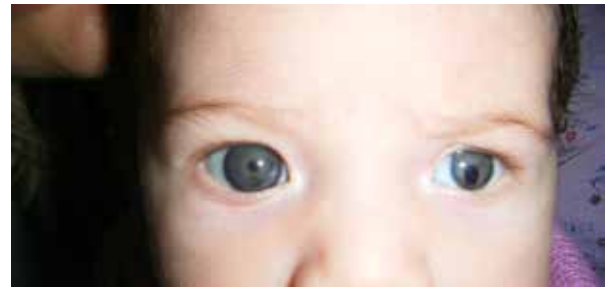

Fig.4: Left microphthalmos associated with iris and retinal colobomas.

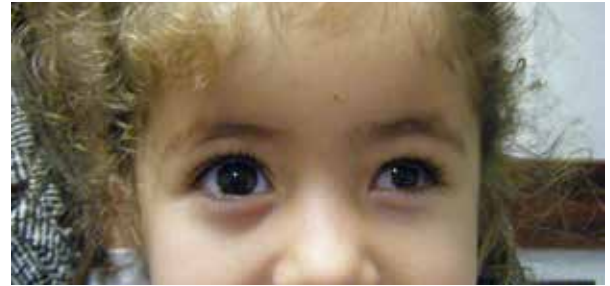

Fig.5: Left microphthalmos with vision. No other ocular anomalies present.

Imaging

Eye and orbital imaging is very helpful in determining the status of the eye, bony structures and associated intracranial or other abnormalities.

Orbital ultrasound evaluates whether an eye or an ocular remnant or cyst is present, its dimensions and internal structure. Even though it cannot give information on the bony structures, it is easy and quick to perform, does not need anesthesia and probably the best primary imaging modality.

Since many conditions that affect the eye also affect brain development, central nervous system imaging is essential, with special attention given to midline structures¹¹.

Magnetic resonance imaging (MRI) does not have side effects and is extremely informative about both the soft tissues and the bone and central nervous system. Requiring sedation and not being readily obtained are its downsides. Moreover, while the bony anatomy around the eye is not directly imaged it can be inferred. This is a useful technique that can be used not only for diagnosis but also for treatment follow-up.

Computerized tomography (CT) is the best modality for bone imaging and preoperative planning as it allows three-dimensional reconstructions; however, besides the need for sedation it also includes radiation exposure.

Most children requiring surgical intervention will need a presurgical CT scan, so that the real orbital volume can be determined. Follow-up imaging can be performed by MRI to minimize radiation exposure.

24. Congenital Anophthalmia

Management

When considering treatment of a microphthalmic eye or an anophthalmic socket, one must take in account the cause, the status of the affected and fellow eye, the amount of volume deficit, bone asymmetry, the child's age and their psychosocial support.

Maldevelopment or loss of an eye in childhood has particular consequences that do not arise for adults. Harmonious facial and orbital development depends on orbital volume growth¹⁵.

At birth, the globe axial length in a full-term infant measures about 17.3 mm, 70% of its adult size, and in a 2-year-old child it is about 80 % to 90 % of an adult eye [1]. In contrast, by three months of age the face is only 40% of adult size. However, it undergoes rapid growth such that at 2 years of age it is 70% and at 5.5 years it is 90% of adult size. Orbital growth reaches its adult dimensions at about the age of eight and the face keeps growing until puberty¹⁶⁻¹⁸.

In untreated anophthalmos/microphthalmos, periocular soft tissue including the eyelids and eye socket, bony orbit and midface can become hypoplastic¹⁵. If unilateral it produces hemifacial hypoplasia, if bilateral it causes central hypoplasia¹⁹. Because of this, early identification and intervention is crucial. To allow normal symmetrical facial and bone structure development, orbital volume rehabilitation should be a priority and must be accomplished as early as possible, preferably in the first months of life²⁰.

The treatment is directed at simultaneous stimulation of both soft tissue and bony orbital growth and, secondarily, at improving cosmesis.

There are several methods for treating clinical anophthalmos, all with the same objectives: enlarge the conjunctival socket, widen palpebral fissure length, promote the growth of the lid, and expand the bony orbit. The final goal is to enable the child to use an external prosthesis and achieve good tissue volume and a symmetric periorbita.

Most authors prefer to avoid surgery whenever possible, particularly in the eyelids and conjunctival fornices, to prevent the formation of contractive scar tissue. For this reason the rehabilitation of a congenital anophthalmic cavity generally starts with conservative treatment.

Conservative treatment

Conformers

This technique was first described in Russian literature in 1930²¹. Expansion of the conjunctival fornices and palpebral and orbital bone growth are promoted by fitting progressively larger conformers as the socket stretches.

Most conformers are custom made; a silicone mold

is created to fit the cavity of each specific patient, and the final model is made of acrylic. Monthly, or every two months a new conformer is made to accompany the growth of the cavity.

Instead of just one piece, a combination of two conformers is often used: one posterior in the orbit and another anteriorly to expand palpebral fissure

Once the cavity and palpebral fissure have reached the ideal size a definitive implant can be surgically placed, thereby reducing the number of surgeries and the need for implant replacement.

This strategy may be the treatment of choice for moderate to severe congenital anophthalmos.

It is a time consuming process and requires the parents' compliance and cooperation. Close collaboration between the ocularist and the ophthalmologist is also necessary to achieve an optimal outcome (Fig. 6 to 11).

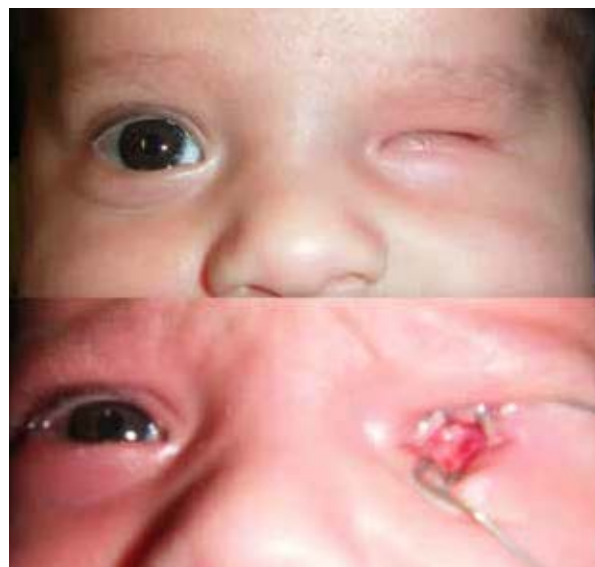

Fig.6: A 3-month-old child presenting a congenital left anophthalmia.

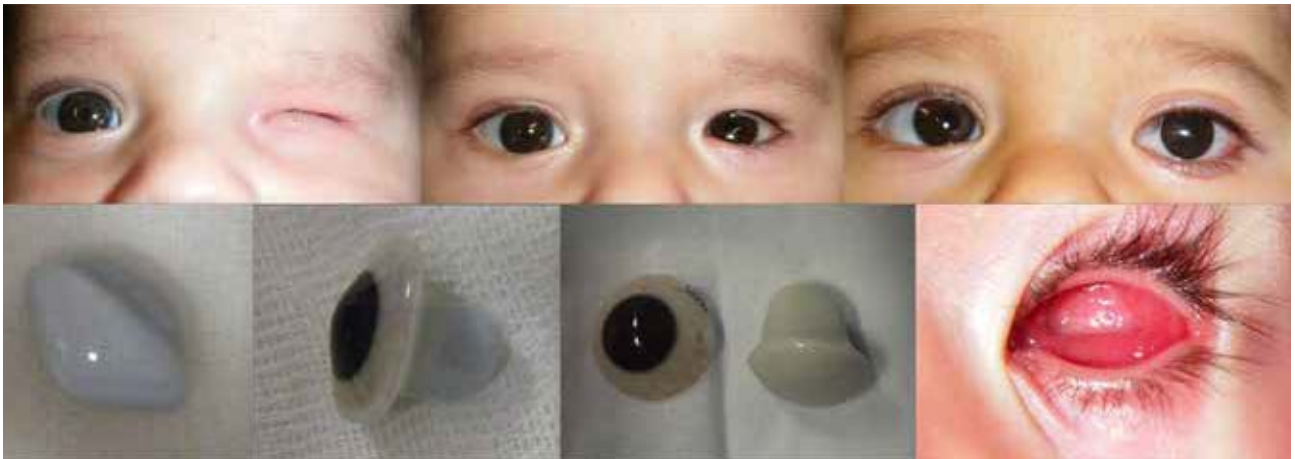

Fig.7: Same child from the previous image with 2 years. Anophthalmia rehabilitation was performed using conformers of increasing size, in one or two pieces.

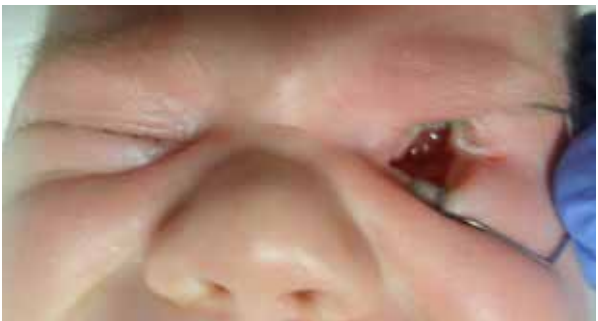

Fig.9: Left congenital anophthalmos in a 1-month-old child.

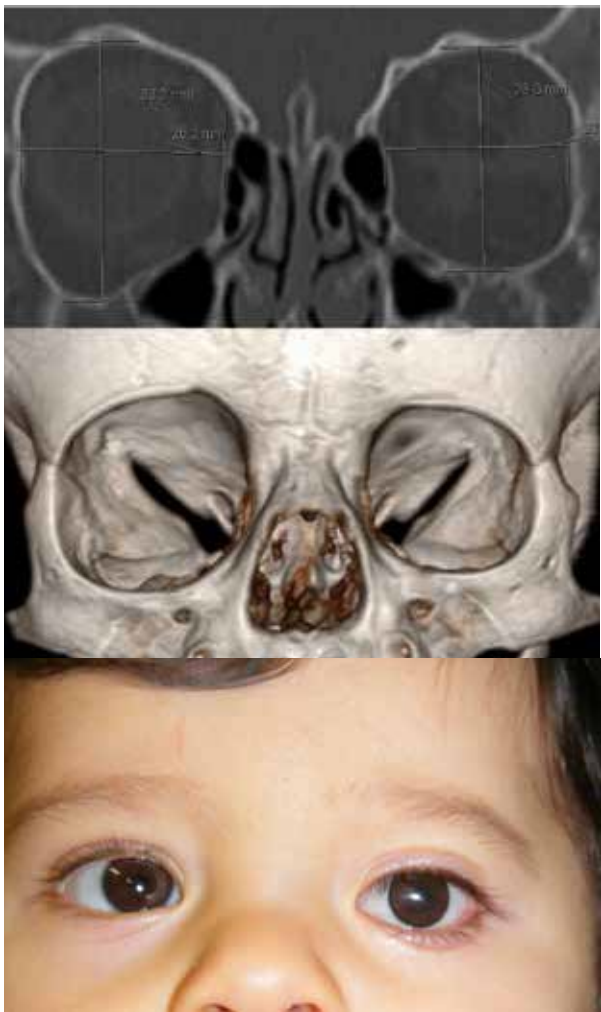


Fig.8: Same child from the previous images with 2 years. Minimal residual bone asymmetry with no aesthetic facial asymmetry.

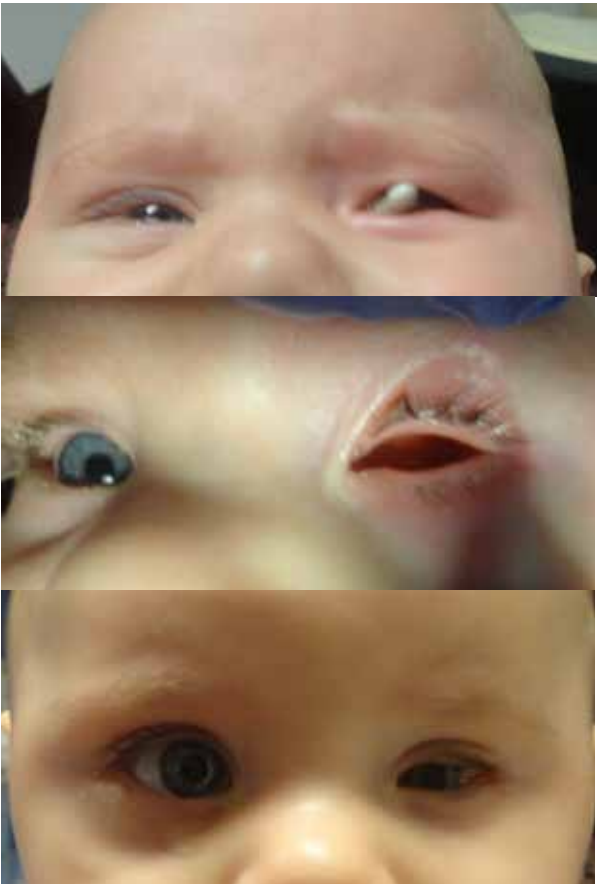

Fig.10: Same child from the previous image after two months of conservative management with conformers.

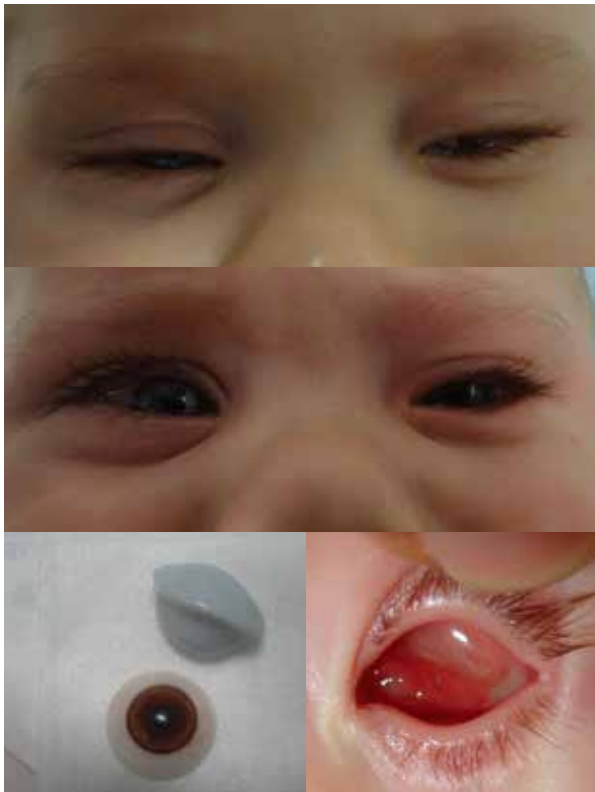

Fig.11: Same 1 year old child demonstrating minimal asymmetry, with a good conjunctival socket.

Surgical treatment

Implants

The ideal implant for a child is still a matter of controversy. Generally, it must be easy to manipulate and biocompatible, and ideally have the potential to expand accompanying the child's growth.

Static orbital implants

These implants are usually spherical and can be solid, for example, soft silicone and acrylic (PMMA), or porous, such as hydroxyapatite, porous polyethylene (Medpor®) or aluminum oxide. In the last two decades porous implants have superseded the solid ones and most surgeons tend to use them nowadays, although their real advantage over the solid implants is open to question.

Concerning the size of the implant, the target should be a minimum of 18 mm²². However, in congenital anophthalmia with important socket contracture it is impossible to introduce a definitive larger size implant and one of 16 mm may be acceptable. In these cases the implant needs to be replaced as the cavity grows. Because of this, the strategy of primarily enlarging the cavity with conformer therapy allows the introduction of a larger implant in the first surgery, reducing the number of surgical reinterventions (Fig. 12).

The complications associated with alloplastic orbital implants include infection, implant migration, exposure or extrusion, which are very challenging to manage.

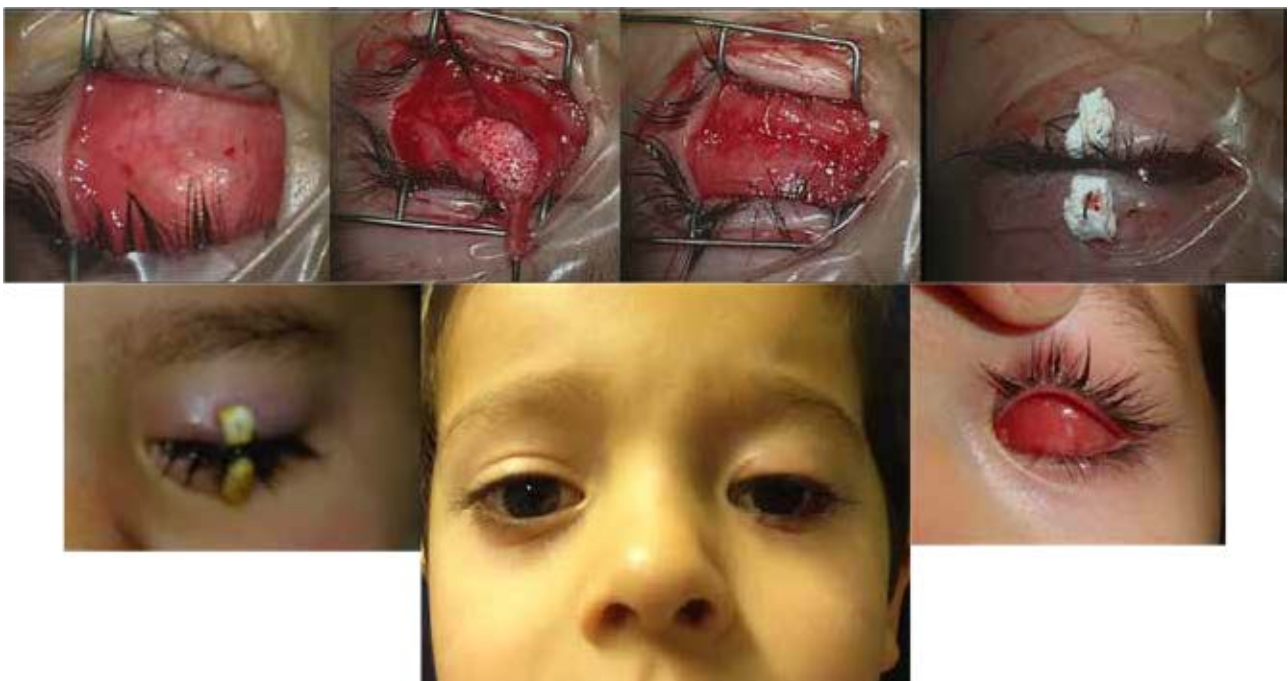


Fig. 12: Left anophthalmia rehabilitated with conformer therapy and an alloplastic implant of 20 mm.

Dermis-fat grafts

The dermis-fat graft in the orbit was first reported in 1978 by Smith and Petrelli, who used it to manage an extruding ocular implant in an adult²³. Since then, it has become an acceptable procedure for primary and secondary anophthalmic implants in the adult and pediatric population²².

It has perfect biocompatibility and an excellent safety profile thanks to the use of autologous tissue, usually from the buttock or abdomen.

The graft atrophy noted to be a problem in adults does not seem to be a problem in the pediatric population under 5 years and is a dynamic implant, with a good preservation of orbit volume over time²²⁻²⁴. As it has the ability to grow, it is the ideal primary implant in children with severe anophthalmia, when it is not possible to place a larger static implant^{17, 22}.

Besides increasing orbital volume, the dermal component provides structural support for graft vascularization and also offers the possibility of increasing conjunctival fornices in very contracted cavities. This is achieved by only partially covering the implanted dermis with

conjunctiva, leaving an exposed central area. This area will secondarily be covered by the ingrowth of conjunctiva, thus augmenting the conjunctival socket. A combined approach with a dermis-fat graft and a static orbital implant can be used to correct both orbital volume deficit and contracted conjunctival cavity. (Fig. 13)

Disadvantages of using a dermis fat graft include the need for a second surgical site and the consequent scar, and graft atrophy in older children and adults that can reach 25 to 30% in 6 months. Less common complications include overgrowth in young children, central ulceration and conjunctival granuloma formation, all easily managed²² (Fig. 14).

Expandable orbital implants

There are two types of expandable implants: inflatable silicone implants, and implants that auto hydrate and expand over time¹⁷. The former normally consist of a spherical liquid chamber that is anchored to the bone, and an injection port with a subcutaneous filling tube to allow titration of the implant volume.

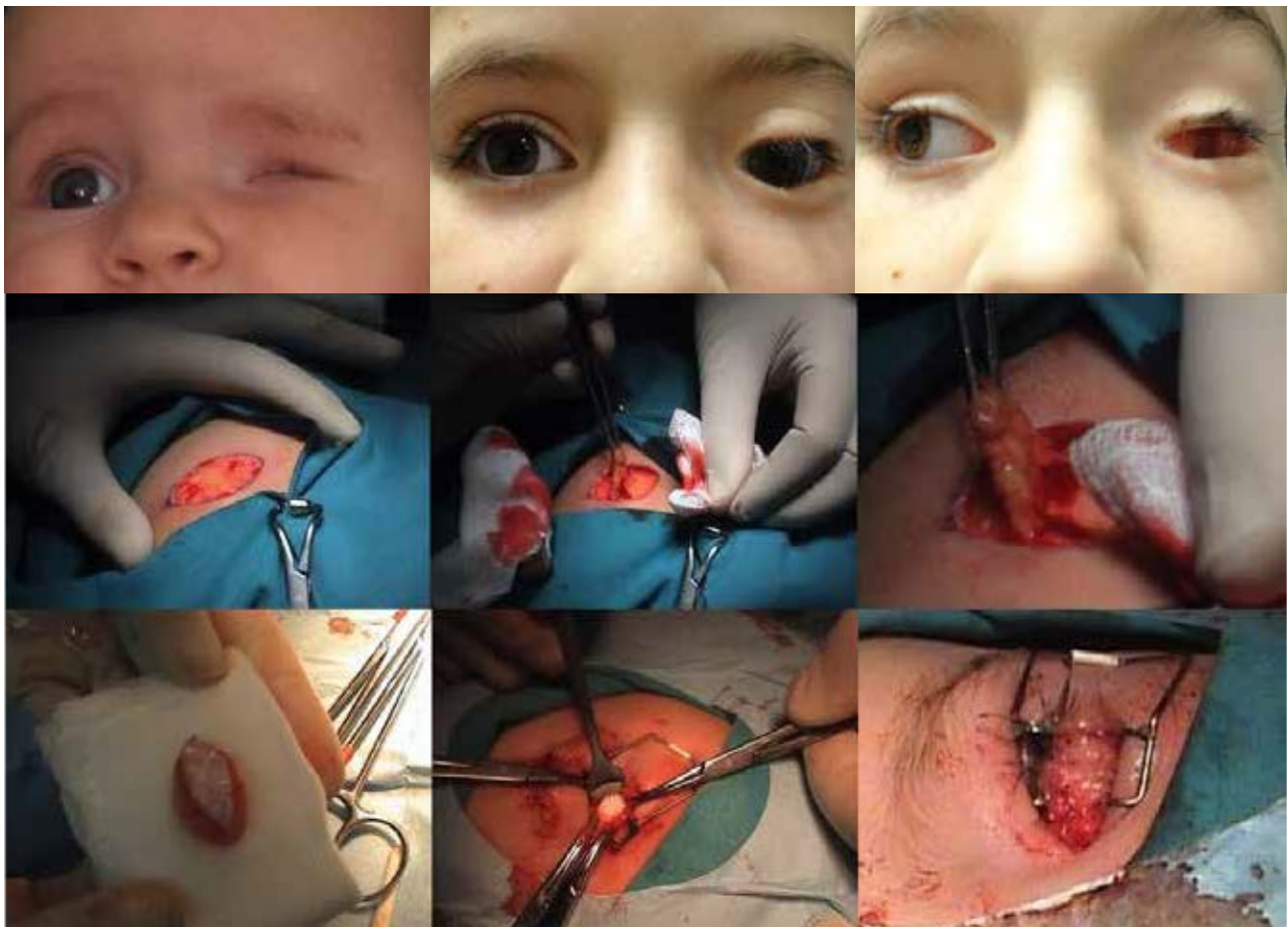


Fig.13: Severe anophthalmos of the left eye with blepharofimosis and shallow conjunctival socket. After conservative treatment with conformers, a porous polyethylene implant and dermis-fat graft were used to treat the volume deficit and shallow conjunctival fornices. A good orbital volume and facial symmetry was achieved although a complete soft tissue rehabilitation was not possible. The child maintains some degree of palpebral phimosis and superior eyelid ptosis with lashes malposition.

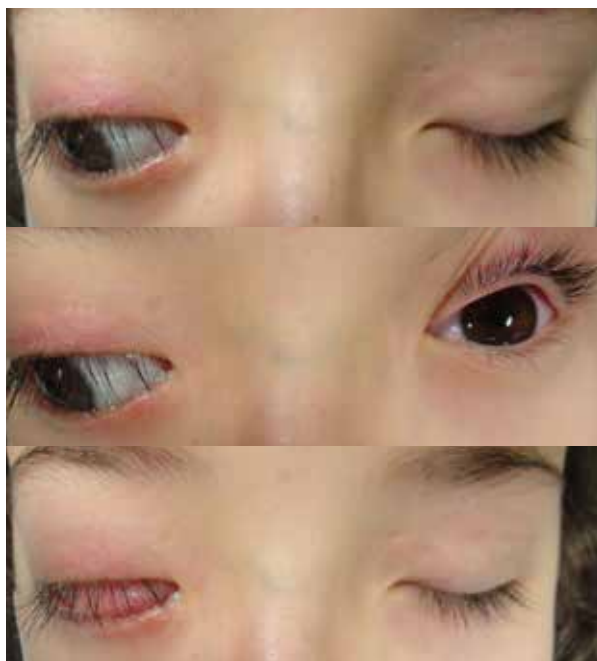

Fig.14: Right congenital anophthalmos treated with a dermis-fat graft. An overgrowth of the fat resulted in a proptosis making impossible for the child to use the external prosthesis. A partial excision of the fat was performed.

The challenge is to maintain orbital fixation and control the direction of expansion.

The latter are spherical or hemispherical solid hydrophilic tissue expanders made of hydrogel. When dehydrated they are small and solid, easily inserted through a small incision in a less time consuming procedure; with hydration they expand slowly and cause less atrophy of the surrounding tissues. They have lower exposure and extrusion rates. They can increase 10 to 12 times their initial size²⁵⁻²⁷. Their main drawback is that when fully hydrated they lose expansion force if the volume is insufficient and often have to be replaced with another type of implant. For this reason it is not recommended as our first choice. These alternatives have a role when conformers fail to achieve the desired bone growth and cavity volume. They are usually recommended in the first year of life in very severe forms of congenital anophthalmia (Fig.15, 16).

Management of microphthalmos with vision

If there is a microphthalmic eye with vision, treatment options are narrowed. It is simultaneously necessary to restore the volume and preserve vision.

In most situations with vision the microphthalmos is not severe and does not result in greater asymmetry or bone hypoplasia.

In these situations the use of a prosthesis with a clear pupil (also called scleral shell) can be an aesthetically interesting solution (fig. 17,18).

One must never forget that the microphthalmic seeing

eye is bound to be refracted, and if significant refractive error is present correction should be prescribed and the underlying amblyopia always treated.

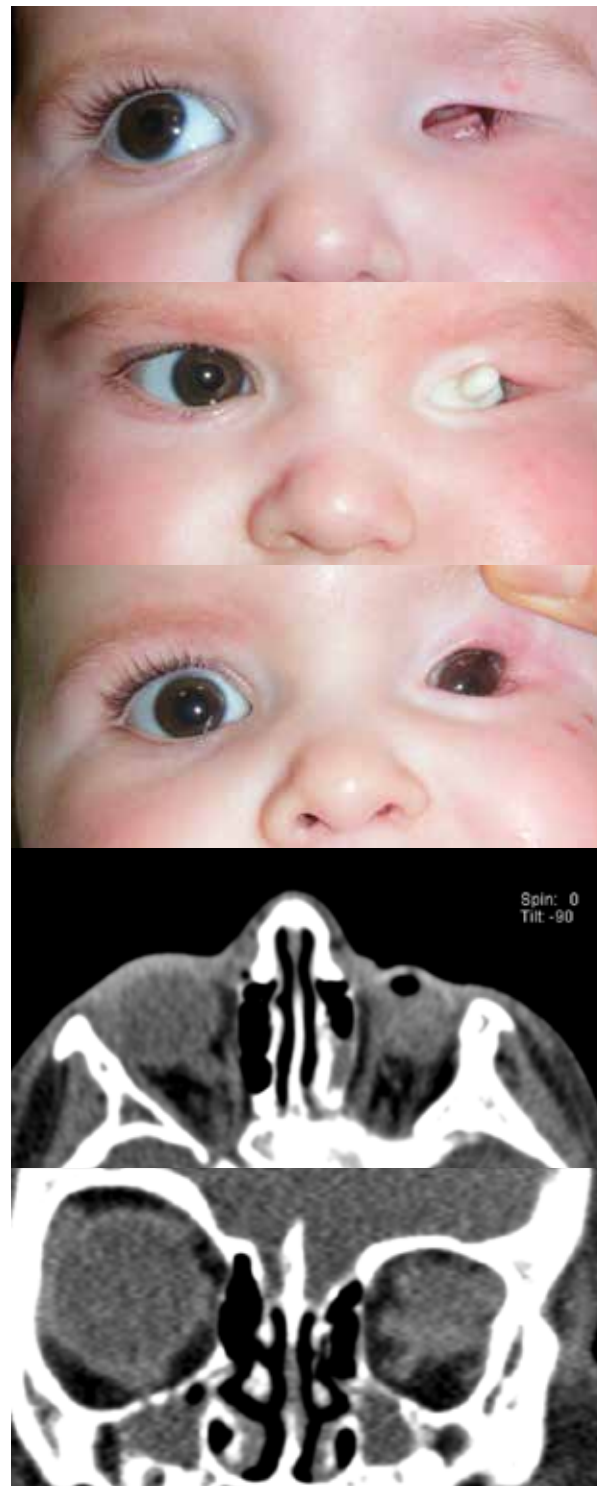


Fig.15: Congenital severe left anophthalmos first treated with conformers. At 8 months of age a spherical self-inflating hydrogel was introduced in the orbit. CT demonstrates a hypointense implant in the left orbit with insufficient volume in relation to the contralateral eye, and an asymmetry in the bony orbits.

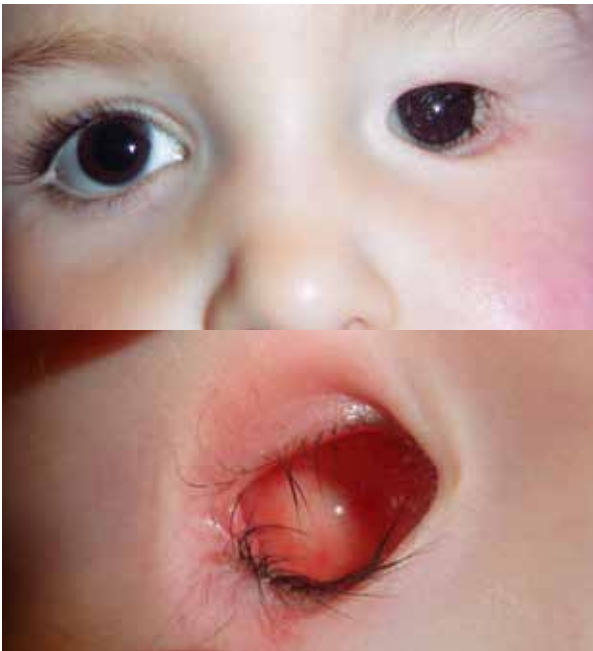

Fig.16: Same child from previous image with 24 months after further conservative treatment with external conformers of increasing size, continuing orbit volume and socket rehabilitation.

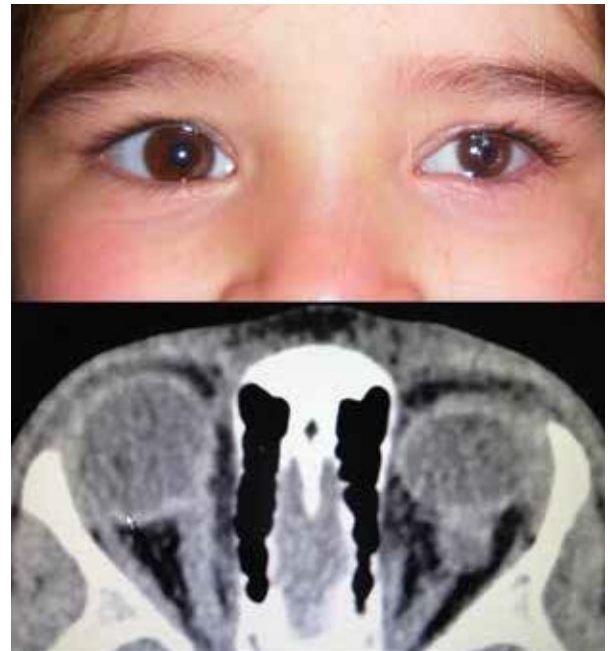

Fig.17: A 5-year-old girl, presenting a congenital left microphthalmia with vision and minimal orbital asymmetry.

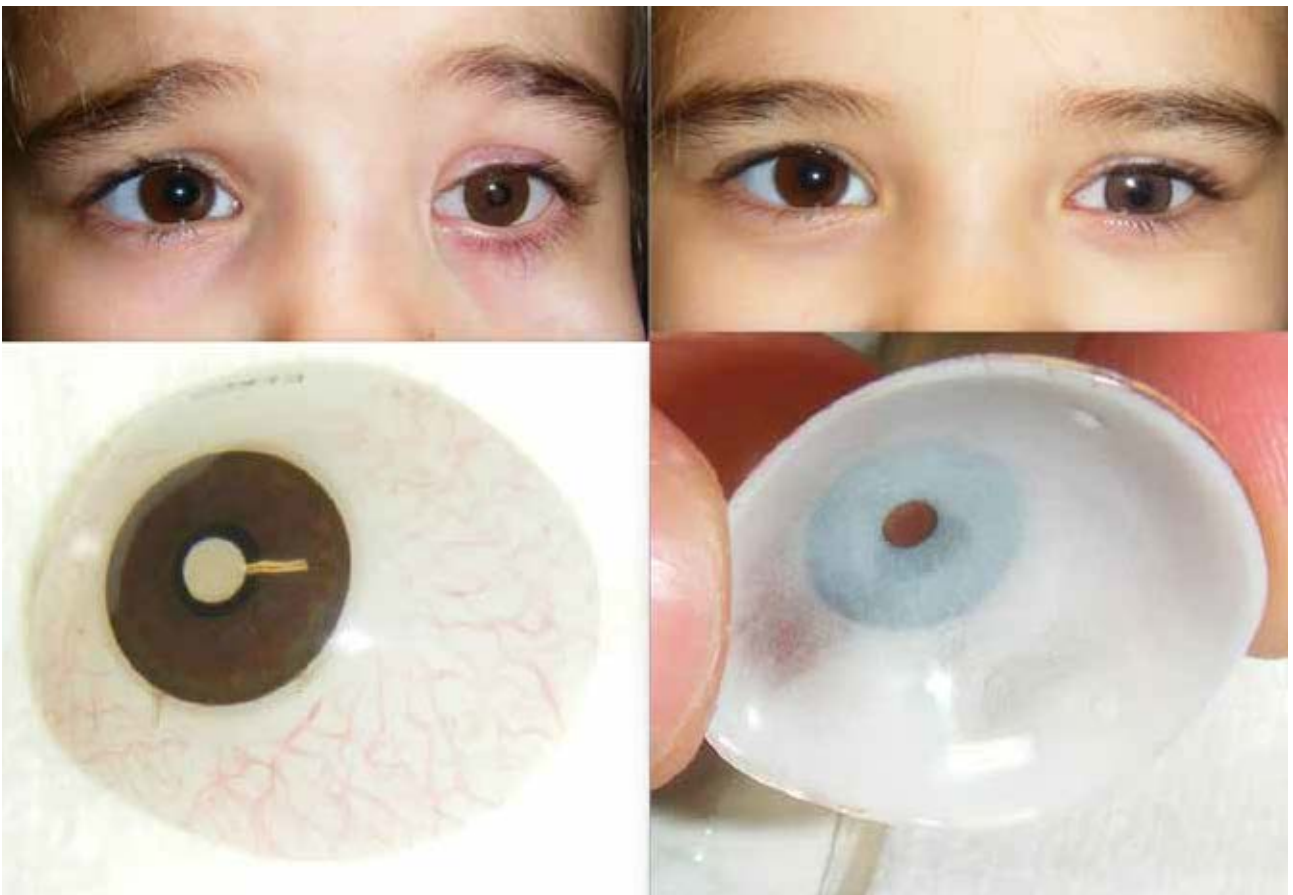

Fig.18: Same girl from previous image, using a scleral shell with a clear pupil. The retinal reflex is visualized through the prosthesis.

Further rehabilitation

The priority for the anophthalmic-microphthalmic socket is to re-establish the orbital volume. After that, secondary surgical procedures can be carried out on the lids, like correction of inferior eyelid malposition, superior eyelid ptosis repair and canthoplasty. Procedures to augment and reconstruct the conjunctival sac may also be needed, using oral mucous grafts. Other procedures, such as lipostructure, can be used later to increase the volume of soft tissues. If conformers and expanders are unsuccessful, the bony orbit can be expanded. This is usually only needed in more severe cases with a late referral.

Spectacles with plus lenses and prisms can also be prescribed to minimize unilateral facial and socket asymmetry.

Finally, the adaptation of an external ocular prosthesis is an essential step in rehabilitating congenital anophthalmos and is discussed in another chapter.

Anophthalmia has many implications in aesthetics and, to a great extent, in all psychosocial aspects of a child's life. Treatment success is crucially dependent on addressing the child's and parents' psychological issues. The cooperation and active enrolment of the parents and caregivers are essential to achieving good conformer adaptation, and also to the recovery from multiple surgeries. Patients must be monitored closely to evaluate the response to treatment, to check if the goals are being reached and to assess and encourage compliance. Because complete aesthetic symmetry is very difficult to achieve, it is also essential to discuss expectations and explain realistic results^{26, 28}.

Conclusion

Congenital anophthalmia-microphthalmia is a particularly challenging condition for the ophthalmologist, as it carries a different set of challenges from those posed by secondary anophthalmos in adults. This is mainly due to the close relationship between volume and normal orbital growth in children. Early intervention with conformer expansion is the gold standard in the management of this pathology. Surgical approaches are often necessary and orbital implants are commonly required to stimulate orbital growth. Although no perfect orbital implant exists, various good options are available, including static solid implants and dermis-fat grafts. Expanding implants such as hydrogel spheres can also be an option in severe cases. Additional soft tissue procedures to the eyelids and/or socket are often necessary. A proposed treatment protocol for congenital anophthalmos is summarized in table 4¹⁷.

The management of this condition demands a comprehensive and multidisciplinary approach

from the ophthalmologist, ocularist, geneticist and pediatrician, as well as a motivated family and child. With early intervention, adequate therapeutic choices and an open discussion with a well-informed family, a satisfactory cosmetic outcome with facial symmetry can be achieved. This will allow a healthy anatomical and psychosocial child development.

Table.4: Proposed treatment protocol for Congenital Anophthalmos

1. Conservative treatment with conformers, starting in the first months of life
2. Static orbital implant of size greater than or equal to 18 mm, around 2-3 years old.
3. Dermis-fat graft in children under 5 years of age when a larger solid implant is impossible to use
4. Orbital tissue expander when the above measures fail
5. Additional surgical procedures for eyelid and conjunctival rehabilitation

References

1. Mf, M., Part 1 The Eye Pathology, in Imaging of the head and neck, M.M.V.G.B. M, Editor. 2005. p. 146-147.
2. Celebi, A.R. and H. Sasani, Differentiation of true anophthalmia from clinical anophthalmia using neuroradiological imaging. *World J Radiol*, 2014. 6(7):515-8.
3. Duke-Elder, S., in *System of ophthalmology*. 1964, Mosby: St Louis. p. 416-423.
4. Young, A. and M. O'Keefe, Bilateral clinical anophthalmos. *Acta Ophthalmol Scand*, 1997. 75(3):308-10.
5. Shaw, G.M., et al., Epidemiologic characteristics of anophthalmia and bilateral microphthalmia among 2.5 million births in California, 1989-1997. *Am J Med Genet A*, 2005. 137(1):36-40.
6. Kallen, B. and K. Tornqvist, The epidemiology of anophthalmia and microphthalmia in Sweden. *Eur J Epidemiol*, 2005. 20(4):345-50.
7. Morrison, D., et al., National study of microphthalmia, anophthalmia, and coloboma (MAC) in Scotland: investigation of genetic aetiology. *J Med Genet*, 2002. 39(1):16-22.
8. Shah, S.P., et al., Anophthalmos, microphthalmos, and typical coloboma in the United Kingdom: a prospective study of incidence and risk. *Invest Ophthalmol Vis Sci*, 2011. 52(1):558-64.
9. Dolk, H., et al., Geographical variation in anophthalmia and microphthalmia in England, 1988-94. *BMJ*, 1998. 317(7163):905-9; discussion 910.
10. Harris, J., B. Kallen, and E. Robert, The epidemiology of anotia and microtia. *J Med Genet*, 1996. 33(10):809-13.
11. Albarnaz, V.S., et al., Imaging findings in patients with clinical anophthalmos. *AJNR Am J Neuroradiol*, 1997. 18(3):555-61.
12. Fitzpatrick, D.R. and V. van Heyningen, Developmental

- eye disorders. *Curr Opin Genet Dev*, 2005. 15(3):348-53.
13. Fuhrmann, S., Eye morphogenesis and patterning of the optic vesicle. *Curr Top Dev Biol*, 2010. 93:61-84.
14. Verma, A.S. and D.R. Fitzpatrick, Anophthalmia and microphthalmia. *Orphanet J Rare Dis*, 2007. 2:47.
15. Kennedy, R.E., THE EFFECT OF EARLY ENUCLEATION ON THE ORBIT IN ANIMALS AND HUMANS. *Trans Am Ophthalmol Soc*, 1964. 62: p. 459-510.
16. Farkas, L.G., et al., Growth patterns in the orbital region: a morphometric study. *Cleft Palate Craniofac J*, 1992. 29(4):315-8.
17. Chen, D. and K. Heher, Management of the anophthalmic socket in pediatric patients. *Curr Opin Ophthalmol*, 2004. 15(5):449-53.
18. Scott, J.H., The growth of the human face. *Proc R Soc Med*, 1954. 47(2):91-100.
19. Kennedy, R.E., Growth retardation and volume determinations of the anophthalmic orbit. *Trans Am Ophthalmol Soc*, 1972. 70:278-97.
20. Ragge, N.K., I.D. Subak-Sharpe, and J.R. Collin, A practical guide to the management of anophthalmia and microphthalmia. *Eye (Lond)*, 2007. 21(10):1290-300.
21. Verigo, E.N., V.A. Tuchin, and I.A. Priakhina, [Historical aspects of eye prosthetics]. *Vestn Oftalmol*, 2012. 128(5):44-7.
22. Mitchell, K.T., et al., The autogenous dermis-fat orbital implant in children. *J AAPOS*, 2001. 5(6):367-9.
23. Smith, B. and R. Petrelli, Dermis-fat graft as a movable implant within the muscle cone. *Am J Ophthalmol*, 1978. 85(1):62-6.
24. Martin, P.A., P.A. Rogers, and F. Billson, Dermis-fat graft: evolution of a living prosthesis. *Aust N Z J Ophthalmol*, 1986. 14(2):161-5.
25. Mazzoli, R.A., et al., Use of self-expanding, hydrophilic osmotic expanders (hydrogel) in the reconstruction of congenital clinical anophthalmos. *Curr Opin Ophthalmol*, 2004. 15(5):426-31.
26. Schittkowski, M.P. and R.F. Guthoff, Injectable self inflating hydrogel pellet expanders for the treatment of orbital volume deficiency in congenital microphthalmos: preliminary results with a new therapeutic approach. *Br J Ophthalmol*, 2006. 90(9):1173-7.
27. Tse, D.T., et al., Evaluation of an integrated orbital tissue expander in congenital anophthalmos: report of preliminary clinical experience. *Am J Ophthalmol*, 2011. 151(3):470-82 e1.
28. Michael P. Schittkowski, J.A.K., Karsten K.H. Gundlach, Rudolf F. Guthoff, Oculoplastics and Orbit, in *Essentials in Ophthalmology*. 2006, Springer. p. 205-221.

25. Orbital inflammatory disease

João Barbosa-Breda, Vitor Leal

Introduction

Orbital inflammatory disease (OID) is a heterogeneous group of disorders affecting all age groups, and represents 6% of orbital diseases¹. The most common causes are, in order of prevalence, thyroid orbitopathy (Figures 1-3), lymphoproliferative disorder (Figures 4-6) and idiopathic orbital inflammation (IOI)², which is the focus of this chapter.

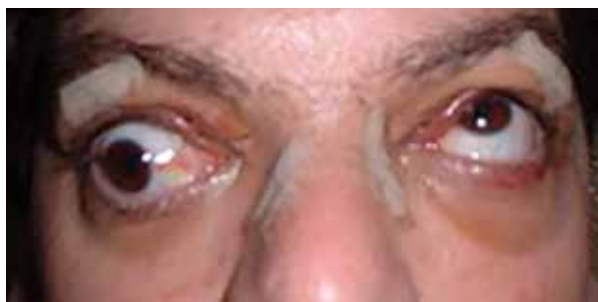

Fig. 1. Thyroid orbitopathy (macroscopic findings; pre operatory).

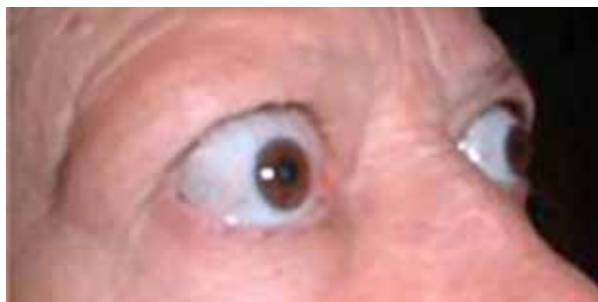

Fig. 2. Thyroid orbitopathy (macroscopic findings; post operatory).

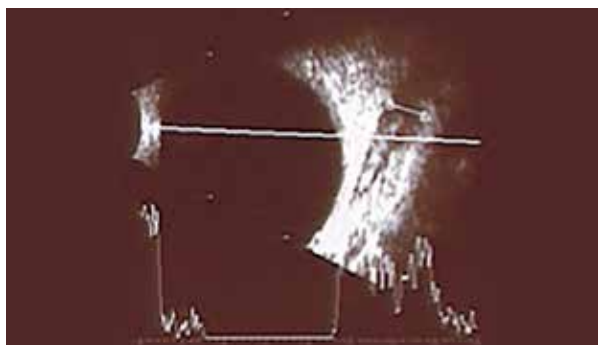


Fig. 3. Ocular ultrasonography (higher than normal width of inferior rectus muscle).

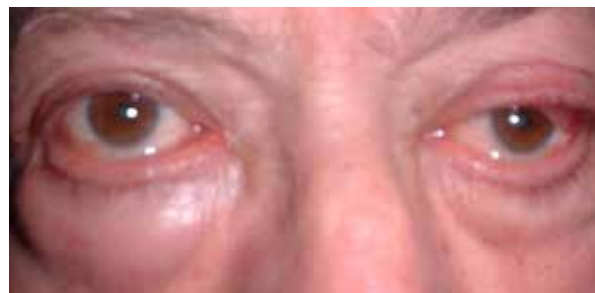

Fig. 4. B-cell lymphoma (macroscopic findings).

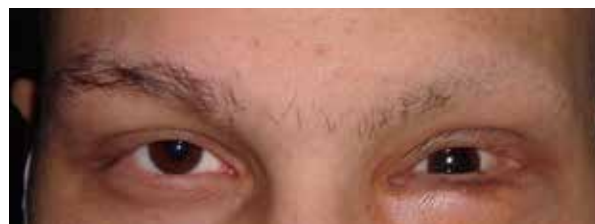

Fig. 5. B-cell lymphoma (macroscopic findings).

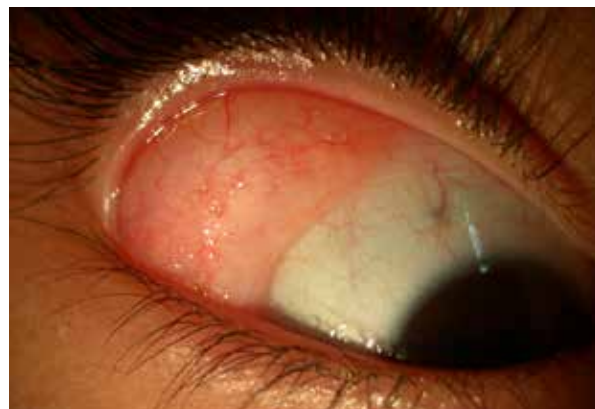

Fig. 6. B-cell lymphoma (biomicroscopic findings).

IOI (Figures 7-9), also known as nonspecific orbital inflammation, idiopathic orbital inflammatory pseudotumor (so called because of the propensity to mimic malignancies), idiopathic orbital inflammatory syndrome, orbital granuloma (ICD 9 376.11), granuloma of orbit (ICD 10 H05.11), is a diagnosis of exclusion, used in 5 to 8 % of cases, when even biopsy is not able to generate a diagnosis². First described by Busse and Hochheim in 1903³ and Birch-Hirschfeld in 1905⁴, it represents 10% of all

25. Orbital inflammatory disease

orbital mass lesions⁵ and is the most common cause of painful orbital mass in adults⁶.

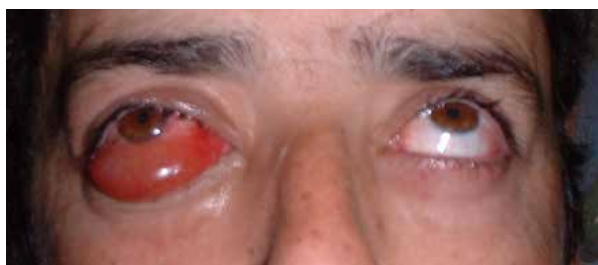

Fig. 7. Idiopathic orbital inflammation (pre-operative).

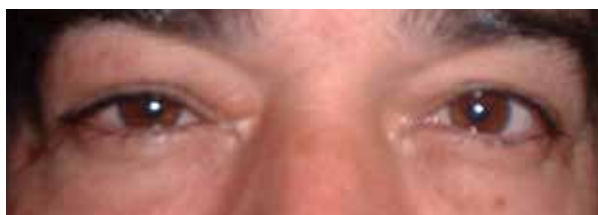

Fig. 8. Idiopathic orbital inflammation (post-operative).

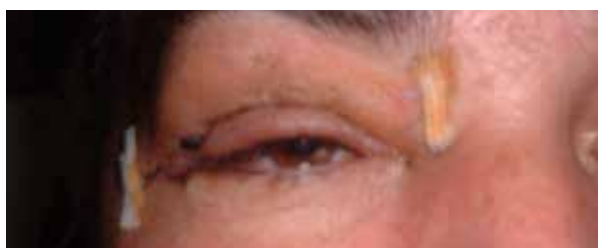

Fig. 9. Idiopathic orbital inflammation (post-operative).

IOI is a benign inflammatory process where inflammation is the physiological response to an underlying disease (local or systemic) and not the disease *per se*. Pathology typically shows a mixture of small lymphocytes, plasma cells and histiocytes. Some variants exist, such as sclerosing orbital inflammation (when there is extensive fibrosis) and calcifying orbital inflammation⁷. There is no gender predilection and it can affect people of all ages, although the mean age is in the fifth decade of life⁸.

Etiology

The various causes of orbital inflammatory disease are listed in Table 1.

Clinical presentation

OID has an acute, subacute or chronic presentation, and the signs and symptoms vary according to the location, degree of inflammation, fibrosis and mass effect. Presentation can be with proptosis, chemosis, visual disability and/or diplopia. The typical presentation of IOI comprises unilateral periorbital pain, cranial nerve palsies and a drastic response to corticosteroids⁷.

OID may be a localized process in a single orbital structure, but also (and more usually) a combination of different structures can have infiltration (diffuse, orbital or extraorbital)⁷.

Children usually have a different presentation in IOI; it is more often bilateral and disc edema, uveitis and eosinophilia are more common findings⁹.

Diagnosis

Apart from patient history and physical examination, which are essential, laboratory exams, histology and imaging techniques play a significant role, too.

Laboratory exams must be requested according to clinical suspicion. They may include a complete blood count, erythrocyte sedimentation rate, C-reactive protein, anti-nuclear antibody screen, anti-neutrophil cytoplasmic antibodies (ANCA), rheumatoid factor, serum protein electrophoresis, serum-angiotensin converting enzyme (ACE), and thyroid function tests. Thoracic radiography and computed tomography (CT) should be done if sarcoidosis is suspected¹.

Regarding imaging, both CT and magnetic resonance imaging (MRI) are valuable, the first because of the good contrast of orbital fat, muscle, bone, calcification and air⁶, and the second because of its ability to better show soft-tissue changes (especially in orbital fissures and cavernous sinus due to bone artifacts¹⁰). MRI should be done with use of frequency-selective fat saturation, since subtle areas of inflammation can be masked by the high signal intensity of orbital fat. On CT, inflammation usually presents with a high intensity signal and enhancement with iodate-based contrast. On MRI, inflammatory infiltrates typically show low signal intensity on T1-weighted images, variable intensity on T2-weighted images, and gadolinium enhancement. The sclerosing variant of

Table 1 – Possible causes for a clinically inflamed orbit (adapted from Gordon *et al.*¹)

Idiopathic inflammation	Systemic	Neoplastic	Congenital	Infectious	Trauma
	Autoimmune thyroid disease	Lymphoma	Dermoid cyst		
	Sarcoidosis	Lymphoproliferative disorders			
	Granulomatosis with polyangiitis	Rhabdomyosarcoma			
	Chron's disease	Choroidal malignant melanoma with extrascleral spread			
	Systemic lupus erythematosus	Metastasis			
	Churg-Strauss syndrome				

OID usually presents with decreased signal intensity on T2-weighted images¹.

One should never forget the value of ocular ultrasonography (Figure 3), which can be used to identify the extraocular muscle insertions and extrascleral expansion of intraocular tumors, to evaluate the size and internal reflectivity of lacrimal gland tumors, and also to identify typical signs, such as the T-sign in posterior scleritis, due to scleral thickening and fluid in the sub-Tenon space¹.

Histologic analysis requires a tissue sample, which can only be obtained invasively. Biopsy is not required in most cases of OID (often required in IOI, since it is a diagnosis of exclusion)¹. It can be avoided if: the clinical history and presentation are a typical history and imaging features of myositis, scleritis or acute dacryoadenitis; improvement occurs with treatment within days; there is no mass after 3 months, and when there is a rapid onset of a painful orbital apex syndrome (high morbidity associated with biopsy)¹¹.

IgG4 related orbital inflammation

IgG4 related disease was first described in patients with autoimmune pancreatitis who had higher than normal serum concentrations of IgG4¹². Afterwards, several authors showed how this was a systemic entity that affects several sites, including the orbit^{12, 13}. The sclerosing orbital inflammation subtype is usually present, since this disease is characterized by normal tissue being replaced by dense fibrous tissue.

It predominantly affects middle-aged and elderly men and usually has a systemic involvement. Other characteristics are bilateral presentation and more prolonged disease.

Diagnostic criteria have recently been proposed^{14, 15}:

- Diffuse or focal enlargement of mass lesions in one or more organs
- Elevated levels of serum IgG4 (> 135 mg/dL)
- Histopathological findings:
 - Noticeable infiltration of lymphocytes and plasmacytes with fibrosis, but no neutrophilic infiltration
 - Abundant infiltration of IgG4-positive plasmacytes (> 10 high power field) and/or a ratio of IgG4/IgG-positive cells > 40%
 - Storiform/swirling fibrosis
 - Obliterative phlebitis

Lacrimal gland is an exception, since obliterative phlebitis is infrequent¹⁶.

Interestingly, some reports are raising awareness about the possibility of orbital lymphoma arising from a background of IgG4-positive inflammation^{17, 18}.

Differential diagnosis

Localized OID can be differentiated according to a different clinical presentation (Table 2)^{1, 7}.

Table 2 – Clinical features and differential diagnosis according to the anatomical pattern/area affected (adapted from Ding *et al.*⁷)

Anatomical pattern/area	Clinical features	Differential diagnosis
Lacrimal gland	Localized pain and tenderness, eyelid swelling	Lymphoma, sarcoidosis, granulomatosis with polyangiitis, neoplasm
Sclera	Orbital pain, swollen eyelid	Infection, orbital trauma with retained foreign body
Extraocular muscles	Orbital pain, proptosis, chemosis, diplopia with restriction of ocular mobility	Thyroid orbitopathy, vasculitis
Optic nerve sheath	Visual disability (visual acuity, colour vision), orbital pain	Optic neuritis, optic nerve sheath meningioma
Orbital apex and intracranial involvement	Orbital apex syndrome or painful ophthalmoplegia, minimal proptosis	Tolosa-Hunt syndrome, lymphoma, glioma, metastasis

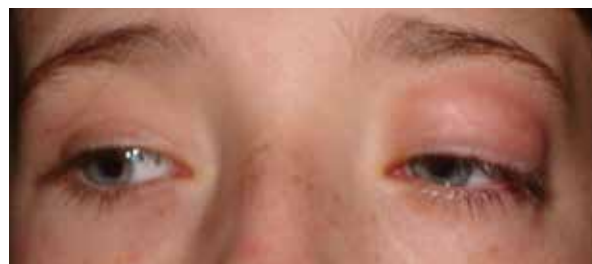

Fig. 10. Dacryoadenitis (macroscopic findings).

1. Lacrimal gland

Dacryoadenitis usually presents acutely with pain, enlargement of the gland in the supero-temporal anterior orbit with associated tenderness on palpation and an S-shaped ptosis of the upper eyelid. A chronic presentation of inflammation of the lacrimal gland is also possible, usually with a painless mass.

Possible etiologies include idiopathy, infection, Sjogren's syndrome, sarcoidosis, lymphoma and a non-lymphoid tumor. Regarding the last possibility, if pleomorphic adenoma is suspected, incisional biopsy is contraindicated. Excisional biopsy (*en bloc*) or fine-needle aspiration biopsy are the most suitable options^{1, 19-21}.

The lacrimal gland is the orbital structure most often affected by IOI⁶. The clinical presentation is no different from other causes, and imaging is important to ascertain if IOI is the probable cause. Typically, CT shows a diffuse enlargement of the gland with preservation of its shape. Margins can be blurred by adjacent inflammatory reaction. Tissue density is the same as or slightly greater than that of muscle, enhancing with iodine-based contrast. MRI usually shows isointensity to slight hypointensity relative to

25. Orbital inflammatory disease

the brain on T1-weighted and T2-weighted images, with homogeneous enhancement with contrast. The main differential diagnosis is lymphoma, which typically affects older patients and is painless. However, biopsy is very often required⁷.

2. Extraocular muscles

Myositis, or inflammation primarily involving the extraocular muscles, usually derives from thyroid eye disease (TED) or is idiopathic^{1,22}. The first possibility should be readily excluded (classically, TED spares the tendon insertion and is in most cases bilateral, apart from all the other typical clinical aspects). This kind of localized orbital inflammation is more common in females. In the acute phase, patients complain of diplopia (usually due to restrictive strabismus) and pain (exacerbated by ocular movements), and present with proptosis and external inflammatory signs. Ultrasonography is very often the key to diagnosing IOI as it shows tendon insertion involvement and irregular muscle borders⁷.

In the acute phase, systemic steroids can dramatically reduce signs and symptoms. Slow tapering is advised to prevent recurrence, but no evidence has shown this to be true. Patients refractory or intolerant to steroids should undergo further studies and will probably need additional therapeutics.

3. Optic nerve sheath (perineuritis)

The main complaints are pain, decreased color vision and loss of vision^{1,23-26}. Most often young females are affected and recurrence is possible. Main differential diagnosis include typical optic neuritis, sarcoidosis and primary tumors of the optic nerve sheath¹.

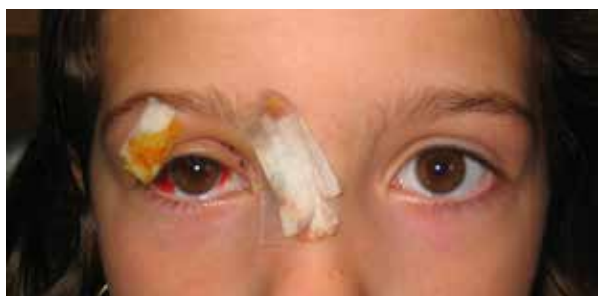

Fig. 11. Perineuritis (macroscopic findings; post-operative).

Imaging shows a mass lesion surrounding the optic nerve sheath, blurring of the optic sheath margin and infiltration of adjacent fat. Contrast-enhanced exams show enhancement of tissues surrounding an unenhanced optic nerve (“tramline” sign).

Main differential diagnosis include retrobulbar optic neuritis and optic nerve sheath meningioma. For the first one, clinical presentation is all too often undifferentiating, but MRI shows enhancement of the optic nerve itself, with or without white matter lesions. Meningioma is suspected when certain imaging signs are present, such as a localized eccentric mass, well-defined

tubular thickening of the optic nerve sheath, fusiform enlargement of the optic nerve-sheath complex and a tramline calcification showing on CT²⁷.

4. Sclera

Scleral tissue inflammation can be localized in the anterior or posterior sclera, with no signs in the opposite end of the globe. It may be accompanied by uveitis, exudative retinal detachment or papillitis, which can be helpful in differentiating the diagnosis. Main causes of scleral inflammation are infectious disease and systemic collagen-vascular disease¹.

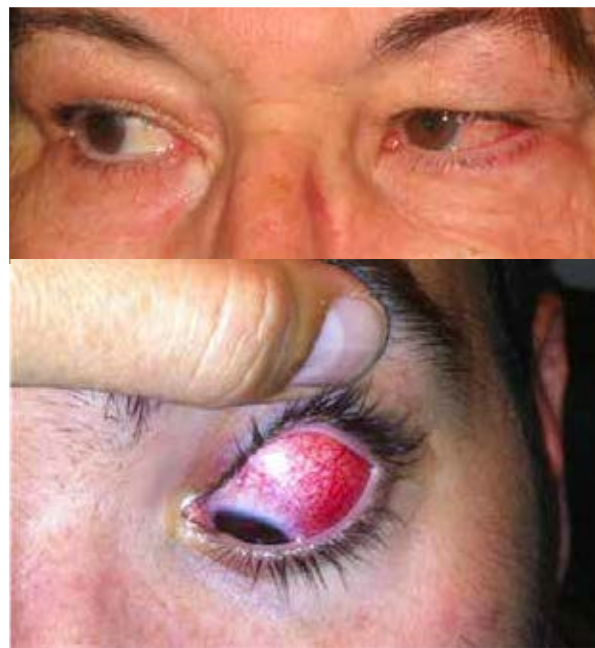

Fig. 12 and 13. Diffuse anterior scleritis (macroscopic findings).

5. Orbital apex

This is an uncommon presentation for OID. From the orbit, inflammation can spread through the optic canal and superior orbital fissure to the medial cranial fossa and cavernous sinus. This gives rise to a clinical picture – orbital apex syndrome – similar to Tolosa-Hunt syndrome, THS, which is described below. It can also spread through the inferior cranial fossa to the infratemporal and pterygopalatine fossae. The main differential diagnosis are IOI, THS, lymphoma, metastasis, sarcoidosis or infection.

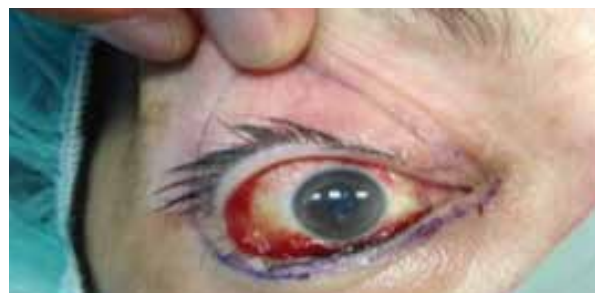

Fig. 14. Mucormycosis in a diabetic patient (macroscopic findings; pre-operative).




Fig. 15. Orbital apex syndrome in a case of thyroid orbitopathy (macroscopic findings).



Fig. 16. Orbital apex syndrome in a case of thyroid orbitopathy (computed tomography).

6.Orbital cellulitis

May result from sinus disease, dental procedures and trauma, and typically presents with fever and leukocytosis (differentiated from non-infectious OID). It is potentially life-threatening and these patients should be admitted for broad-spectrum intravenous antibiotics.

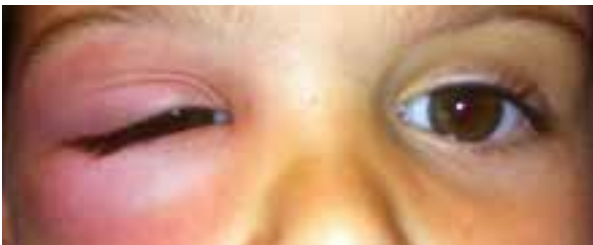

Fig. 17. Orbital cellulitis secondary to ethmoiditis (macroscopic findings).

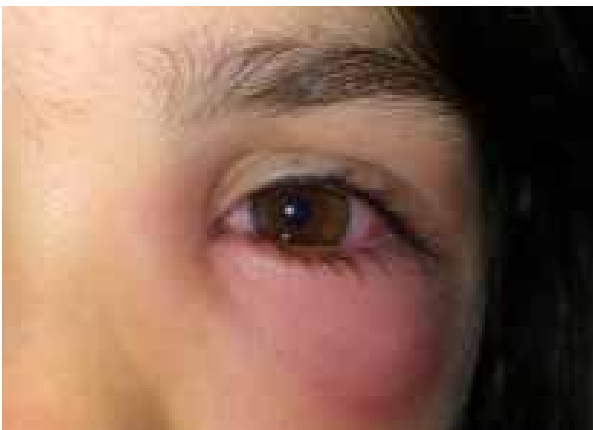

Fig. 18. Orbital cellulitis (macroscopic findings).

Diffuse OID with chronic presentation is challenging for the physician, who must consider several potential etiologies, including thyroid eye disease, sarcoidosis, granulomatosis with polyangiitis, lymphoproliferative diseases or vasculitis^{1, 28}. A diffuse acute OID usually results from infectious orbital cellulitis, a tumor with acute inflammatory signs or thyroid eye disease¹.

Treatment

This section will focus mainly on IOI, since the other causes have specific treatments. Treatment options are varied and can include surgery, steroids, chemotherapeutic agents and irradiation²⁹.

The initial treatment of choice is high-dose oral corticosteroids (adult dose ranging from 60 to 80 mg prednisone per day), and 80% of patients respond³⁰. Slow tapering of steroids over weeks or months is needed to prevent exacerbation or recurrence. Long-term treatment may be necessary and entails several side effects (including mood and weight changes, hyperglycemia, dyspepsia, accelerated bone loss).

Patients who have a rapidly progressing presentation or those who fail to respond to corticosteroids can be treated with radiotherapy (this may be the initial treatment of choice in case of metastasis or lymphoproliferative diseases, but never for IOI). Apart from corticosteroids and radiotherapy, certain chemotherapeutic agents are also therapeutic options, such as methotrexate, cyclophosphamide, mycophenolate mofetil, rituximab.

Granulomatous inflammatory diseases

Sarcoidosis

Sarcoidosis is a multisystem granulomatous inflammatory disease that affects the ocular system in 50% of patients. Presents with noncaseating granulomas of several ocular structures, uveitis, optic neuropathy, and also affects the lacrimal gland, extraocular muscles and fat. Up to 90% of patients have pulmonary involvement, and thoracic radiography and CT should be done if sarcoidosis is suspected. Serum-ACE can be helpful for follow up since it reflects the total amount of granuloma tissue. Using ACE for diagnosis is controversial since it is also elevated in many other illnesses. Patients undergoing treatment with ACE inhibitors should be monitored with lysozyme instead.

Ocular sarcoidosis may present as Heerfordt's syndrome, also known as as uveoparotid fever, which includes uveitis, swelling of the parotid gland, chronic fever, and in some cases, palsy of the facial nerves.

Recent diagnostic criteria have been created [by the First International Workshop on Ocular Sarcoidosis (FIWOS)]^{1, 31, 32}.

Granulomatosis with polyangiitis

Granulomatosis with polyangiitis (former Wegener's granulomatosis) is a systemic vasculitis that typically affects the respiratory and renal systems and, in up to 50% of cases, affects the orbit. The autoantibody c-ANCA against proteinase 3 is present in 90% of patients with the active systemic form of the disease, although a study has shown a positivity of only 32% in the case of the orbit limited form. Treatment usually requires systemic corticosteroids and another kind of medical treatment, such as cyclophosphamide^{1, 33}.

Churg-Strauss syndrome

Churg-Strauss syndrome is a necrotizing vasculitis with tissue infiltration by eosinophils and extravascular granulomas. Multiple organ systems may be involved and the syndrome usually presents with clinical features of asthma and eosinophilia. Lab exams may reveal increased circulating IgE and p-ANCA antibodies (in orbital cases they are associated with ischemia and poor visual prognosis)^{1, 34, 35}.

Tolosa-Hunt syndrome

Tolosa-Hunt syndrome consists of a painful ophthalmoplegia with cranial nerve palsies (third, fourth, fifth, and sixth cranial nerves, affecting motor, sensory and oculosympathetic pathways) due to an inflammation behind the eye globe, typically in the cavernous sinus or superior orbital fissure. Etiology is unknown and it is a diagnosis of exclusion; pathology reveals a granulomatous inflammation. Extension of the process can lead to optic neuropathy, facial paralysis or involvement of the second and third branches of the trigeminal nerve. Pain relief typically happens after several days of high-dose corticosteroids¹.

References

- Gordon LK. Orbital inflammatory disease: a diagnostic and therapeutic challenge. *Eye* (London, England). 2006;20(10):1196-206.
- Lindfield D, Attfield K, McElvaney A. Systemic immunoglobulin G4 (IgG4) disease and idiopathic orbital inflammation; removing 'idiopathic' from the nomenclature? *Eye* (London, England). 2012;26(5):623-9.
- Busse O HW. Exophthalmos due to chronic orbital myositis. *Arch Ophthalmol* 1943;30:446-66.
- A. B-H. Zur diagnostic and pathologic der orbital tumoren. [Concerning diagnosis and pathology of orbital tumours.]. *Ber Zusammenkunft Dtsch Ophthalmol Ges* 1905;32:127-35.
- Swamy BN, McCluskey P, Nemet A, Crouch R, Martin P, Bengier R, et al. Idiopathic orbital inflammatory syndrome: clinical features and treatment outcomes. *The British journal of ophthalmology*. 2007;91(12):1667-70.
- Weber AL, Romo LV, Sabates NR. Pseudotumor of the orbit. Clinical, pathologic, and radiologic evaluation. *Radiol Clin North Am*. 1999;37(1):151-68, xi.
- Ding ZX, Lip G, Chong V. Idiopathic orbital pseudotumor. *Clinical radiology*. 2011;66(9):886-92.
- Kargi SH AH, Sayarlioglu H, Koksai M, Ugurbas SH, Alpay A. Acquired retraction of the eye as the first sign of myositis. *Strabismus*. 2005 13(2):85-8.
- Berger JW, Rubin PA, Jakobiec FA. Pediatric orbital pseudotumor: case report and review of the literature. *Int Ophthalmol Clin*. 1996;36(1):161-77.
- Kline LB, Hoyt WF. The Tolosa-Hunt syndrome. *J Neurol Neurosurg Psychiatry*. 2001;71(5):577-82.
- Rose GE. A personal view: probability in medicine, levels of (Un)certainity, and the diagnosis of orbital disease (with particular reference to orbital "pseudotumor"). *Arch Ophthalmol*. 2007;125(12):1711-2.
- Hamano H, Kawa S, Horiuchi A, Unno H, Furuya N, Akamatsu T, et al. High serum IgG4 concentrations in patients with sclerosing pancreatitis. *N Engl J Med*. 2001;344(10):732-8.
- Chaudhry IA, Shamsi FA, Arat YO, Riley FC. Orbital pseudotumor: distinct diagnostic features and management. *Middle East Afr J Ophthalmol*. 2008;15(1):17-27.
- Okazaki K, Uchida K, Koyabu M, Miyoshi H, Takaoka M. Recent advances in the concept and diagnosis of autoimmune pancreatitis and IgG4-related disease. *J Gastroenterol*. 2011;46(3):277-88.
- Okazaki K, Uchida K, Miyoshi H, Ikeura T, Takaoka M, Nishio A. Recent concepts of autoimmune pancreatitis and IgG4-related disease. *Clin Rev Allergy Immunol*. 2011;41(2):126-38.
- Cheuk W, Chan JK. IgG4-related sclerosing disease: a critical appraisal of an evolving clinicopathologic entity. *Adv Anat Pathol*. 2010;17(5):303-32.
- Berry-Brincat A, Rose GE. Idiopathic orbital inflammation: a new dimension with the discovery of immunoglobulin G4-related disease. *Current opinion in ophthalmology*. 2012;23(5):415-9.
- Cheuk W, Yuen HK, Chan AC, Shih LY, Kuo TT, Ma MW, et al. Ocular adnexal lymphoma associated with IgG4+ chronic sclerosing dacryoadenitis: a previously undescribed complication of IgG4-related sclerosing disease. *Am J Surg Pathol*. 2008;32(8):1159-67.
- Mombaerts I, Schlingemann RO, Goldschmeding R, Kornneef L. Idiopathic granulomatous orbital inflammation. *Ophthalmology*. 1996;103(12):2135-41.
- Peterson EA, Hymas DC, Pratt DV, Mortenson SW, Anderson RL, Mamalis N. Sarcoidosis with orbital tumor outside the lacrimal gland: initial manifestation in 2 elderly white women. *Arch Ophthalmol*. 1998;116(6):804-6.
- J R. Why 'orbital pseudotumour' is no longer a useful concept. *The British journal of ophthalmology*. 1998;82:339-40.
- Menon GJ, Hollman AS, Dutton GN. Granulomatous orbital myositis. *Eye* (London, England). 2000;14 (Pt 4):676-8.
- Fay AM, Kane SA, Kazim M, Millar WS, Odel JG. Magnetic resonance imaging of optic perineuritis. *J Neuroophthalmol*. 1997;17(4):247-9.
- Frohman L, Wolansky L. Magnetic resonance imaging of syphilitic optic neuritis/perineuritis. *J Neuroophthalmol*. 1997;17(1):57-9.
- Hykin PG, Spalton DJ. Bilateral perineuritis of the optic nerves. *J Neurol Neurosurg Psychiatry*. 1991;54(4):375-6.
- Purvin V, Kawasaki A, Jacobson DM. Optic perineuritis: clinical and radiographic features. *Arch Ophthalmol*. 2001;119(9):1299-306.
- Turbin RE, Pokorny K. Diagnosis and treatment of orbital optic nerve sheath meningioma. *Cancer Control*. 2004;11(5):334-41.
- Rootman J. Inflammatory diseases of the orbit. *Highlights. J Fr Ophtalmol*. 2001;24(2):155-61.
- Narla LD, Newman B, Spottswood SS, Narla S,

- Kolli R. Inflammatory pseudotumor. *Radiographics*. 2003;23(3):719-29.
30. Mendenhall WM, Lessner AM. Orbital pseudotumor. *Am J Clin Oncol*. 2010;33(3):304-6.
 31. Bradley D, Baughman RP, Raymond L, Kaufman AH. Ocular manifestations of sarcoidosis. *Semin Respir Crit Care Med*. 2002;23(6):543-8.
 32. Heuser K, Kerty E. Neuro-ophthalmological findings in sarcoidosis. *Acta Ophthalmol Scand*. 2004;82(6):723-9.
 33. Kalina PH, Lie JT, Campbell RJ, Garrity JA. Diagnostic value and limitations of orbital biopsy in Wegener's granulomatosis. *Ophthalmology*. 1992;99(1):120-4.
 34. Takanashi T, Uchida S, Arita M, Okada M, Kashii S. Orbital inflammatory pseudotumor and ischemic vasculitis in Churg-Strauss syndrome: report of two cases and review of the literature. *Ophthalmology*. 2001;108(6):1129-33.
 35. Metzler C, Hellmich B, Gause A, Gross WL, de Groot K. Churg Strauss syndrome--successful induction of remission with methotrexate and unexpected high cardiac and pulmonary relapse ratio during maintenance treatment. *Clin Exp Rheumatol*. 2004;22(6 Suppl 36):S52-61.

26. Bacterial Orbital Cellulitis

Sara Ribeiro; Ana Paula Pina; Maria Shekhovtsova; Antonio Augusto Velasco e Cruz

Introduction

Orbital infections, which are in general referred to as “cellulitis”, can have multiple causes such as dental infection, acute dacryocystitis, trauma, periocular surgery, panophthalmitis, septicemia and immunosuppression, although in the vast majority of cases they represent complications of sinusitis. Identification of the source of infection facilitates effective management. The signs and symptoms at presentation often make it difficult to distinguish a preseptal cellulitis from an orbital cellulitis. A delay in the diagnosis or treatment of orbital cellulitis may lead to intracranial complications and even death.¹⁻⁴ In this chapter we focus only on bacterial orbital cellulitis. For a better understanding, sinonasal orbital cellulitis and non-sinonasal orbital cellulitis are addressed separately.

Sinonasal orbital cellulitis

Acute complications of paranasal sinus diseases seem to be more common in children than in adults, and are directly related to the intimate anatomical relations between the paranasal sinuses and some head and neck structures.

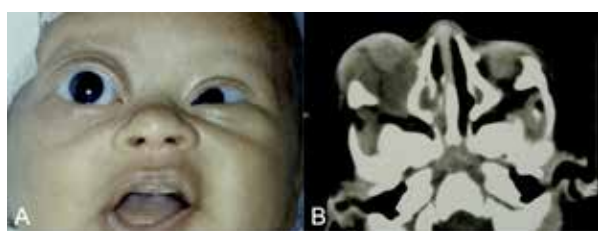


Fig. 1 – Sinonasal orbital cellulitis in a 4 month old baby. Clinical (A) and imaging aspect (B).

Rhinosinusitis is a severe disease that frequently involves severe orbital complications that require a rapid multidisciplinary approach, because a diagnostic delay may lead to the patient's death. Ognibene *et al*⁵ reported an 83.1% rate of orbital complications in 65 patients studied over a 10-year period and Mortimore and Wormald⁶ detected an 80% rate in a population studied for 5 years. Before

the advent of antibiotic therapy, the prevalence of post-rhinosinusitis orbital complications was very high. Some series mention mortality rates of 17-19% and a 20-33% prevalence of amaurosis.^{7, 8} Fortunately, today these rates do not exceed 5%¹.

1. Classification schemes

From 1937, when Hubert⁹ published the first classification of rhinosinusitis complications, to 1977, when Mortimore and Wormald⁶ proposed a new classification for orbital complications, the nomenclature of orbital infections was quite confused, as shown by the fact that the authors used the terms preseptal or periorbital, which by definition are related to extra-orbital pathologies, to stage intraorbital infections.

Hubert⁹ published a classification that included palpebral, orbital and intracranial diseases. According to the author, orbital complications deriving from sinusitis could be staged as: I – eyelid inflammatory edema, II – orbit subperiosteal abscess, III - diffuse orbital cellulitis, IV - orbital abscess and V - cavernous sinus thrombophlebitis. The latter is obviously not a form of orbital cellulitis because this is an intracranial complication of sinusitis and should not be classified as a subtype of orbital cellulitis. Hubert's description of group I was confusing in that it included eyelid and orbital signs in the same category, thus: “in the first group the infection is confined to the nasal sinuses, and there is only an inflammatory edema of the lids which may become markedly swollen. The edema may, however, extend into the orbital tissue. When this occurs, a slight exophthalmos and some limitation of movement of the eyeball appear”^{1, 2, 9}.

In 1948, Smith and Spencer¹⁰ used the Hubert classification to stage orbital complications of sinus infection. The same imprecision concerning the definition of group I was maintained. According to the authors, this category was defined as inflammatory edema of the eyelids with or without edema of the orbit. Chandler published the most quoted classification system in 1970⁷. This classification of orbital cellulitis comprised five categories: I) inflammatory edema,

II) orbital cellulitis, III) subperiosteal abscess, IV) orbital abscess, and V) cavernous sinus thrombosis. It should be noted that Chandler kept the Smith and Spencer definition of group I but, probably noticing the theoretical inconsistency of labeling as eyelid edema a category that includes exophthalmos and eye motility restriction, he removed the word eyelid from this category. Chandler also modified the definition of category III. While according to Smith this category was due to phlebitis of the orbital veins, Chandler used the expression “diffuse cellulitis” to describe orbital fat infiltration by inflammatory cells. The term preseptal used to define Chandler’s category I first appeared in the literature after the study by Moloney *et al.*¹¹. This expression is used to describe eyelid pathologies and should be discontinued for the description of orbital infections.

In order to avoid imprecision, diseases that occur within the orbit or in its vicinity should be described by terms with specific meanings. By definition, any orbital disease is a pathologic process that is post- or retroseptal, in other words, confined to the space behind the septum. Conversely, a preseptal disease is always located anterior to the septum and thus is a pure eyelid or palpebral process. Diseases that occur on both sides of the septum can be labeled as orbito-palpebral and, finally, any disease that occurs outside but close to the orbits, such as in the eyelids and/or around the bone orbital walls can be termed periorbital because the Latin prefix *peri* means around. In a similar fashion, “cavernous sinus thrombophlebitis” cannot be a category of orbital cellulitis for the simple reason that the cavernous sinus is an intracranial not an orbital structure^{1,2}.

Analysis of the current terminology regarding the classification of orbital infections of sinusal origin reveals a confusing and inaccurate system. The first classification schemes were developed in the pre-computed tomography (CT) era. Some authors had demonstrated that radiological findings yielded more reliable disease classification than clinical data alone, and some investigators suggested updating the classification of orbital cellulitis to include radiological features^{1,2,12,13}. Pereira *et al* and Cruz *et al* proposed a new and simple classification based on more specific terms to help the physician establish a linear approach to each case. They stated that, from a radiological point of view, all orbital cellulitis forms can be classified into three major categories: diffuse fat infiltration, subperiosteal abscess, and orbital abscess^{1,2}. A general consensus is needed to establish a new classification system that includes clinical and radiological findings.

2. Signs and symptoms

Clinical signs of early orbital infection include soft

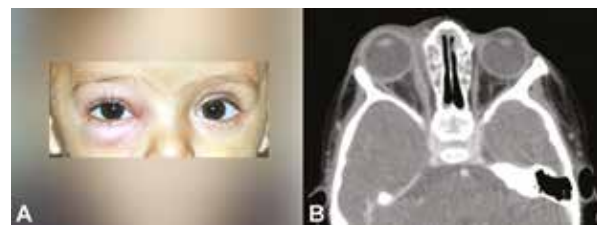

Fig. 2 – Chandler’s category I: Incipient inflammatory edema. A) Upper and lower eyelid inflammation. The eye is quiet with minimal proptosis. B) An axial CT scan shows medial rectus edema and infiltration along the medial orbital wall.

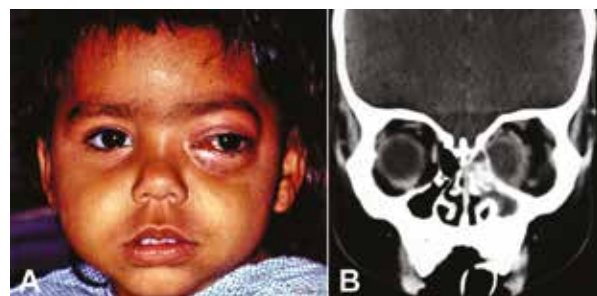

Fig. 3 - Subperiosteal abscess of the left orbit: A) Clinical picture. B) Coronal CT scan of the orbits shows an isolated subperiosteal abscess of the medial wall with no involvement of the orbital fat.

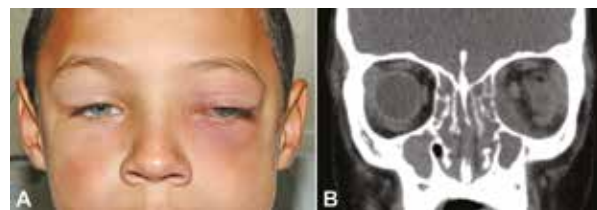

Fig. 4 - Child with swelling of the left eyelids (A). The coronal CT scan (B) shows a left inferomedial orbital abscess associated with pansinusitis.

tissue swelling, redness, and increased warmth of the eyelids. In the pediatric age group, this may be the only indication of paranasal sinusitis with the potential for more serious orbital complications. Adults with orbital infection secondary to sinusitis, commonly complain of headaches and sinus tenderness. Subperiosteal abscess and orbital cellulitis present with impairment of extraocular motility, proptosis, ocular pain, anesthesia of the area innervated by the first and second divisions of the trigeminal nerve, and chemosis. The most common cause of sudden proptosis in childhood is orbital cellulitis. Visual loss indicates involvement of the optic nerve. Abscess development is indicated by increased severity of signs and symptoms as well as an afferent pupillary defect, venous congestion, papilledema, and decreased visual acuity. Venous engorgement of the retina and cranial nerve palsies involving nerves III through VI result from septic cavernous sinus thrombosis, with the lateral rectus being the first muscle involved. Signs of meningitis or extra-axial empyema include meningismus, headache, and fever. Symptoms of

intracranial involvement such as cerebritis, abscess formation and infarction are an altered mental state, headache, fever, seizure, vomiting, unilateral weakness/hemiparesis, or a cranial nerve sign^{3, 4, 7, 14-16}. There is a clear grading between the different stages of orbital infection, and since most patients present in the early stage it is important to recognize and treat the condition early to prevent progression to further stages. However, defining the stage is often difficult because there is no clear correlation between the extent of spread and clinical signs, and one stage does not necessarily lead to the next.

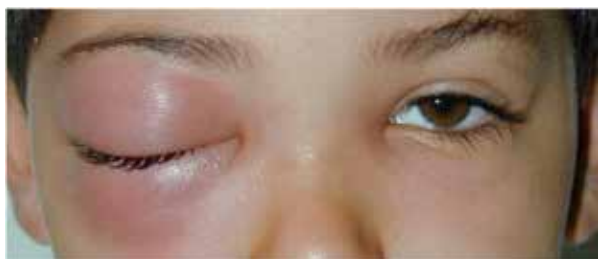

Fig. 5 - Young boy with an early orbital infection presented with soft tissue swelling, redness, and increased warmth of the eyelids.

3. Imaging of the orbit in orbital cellulitis

New diagnostic techniques such as CT scan, magnetic resonance imaging (MRI) and nasal endoscopy help with early diagnosis and help identify the stage of complication, thereby permitting a more effective therapy. Therefore, after a detailed history and physical exam, image technology is fundamental^{1, 2, 12}.

CT provides a three-dimensional assessment of abscess size, as well as its clear relation with the eyeball, extrinsic muscles and optic nerve. In children, it is critical to distinguish between orbital cellulitis and subperiosteal abscess. According to Clary *et al*⁷, the correlation between radiological and surgical findings, although not absolute, points to CT scan as the paramount means of diagnosis. In cases of subperiosteal abscesses, a CT scan reveals an edema of the extrinsic eye muscles and a homogeneous opacification between the orbit walls and the shifted periorbit. In addition, the eyeball is shifted non-axially. In the case of orbital abscesses, CT shows obliteration of the extrinsic muscles and the optic nerve, and a homogeneous mass matching the signs of an abscess. In fact, CT imaging is the modality of choice for confirming sinusitis and orbital cellulitis and is essential for diagnosis, treatment decisions, and surgical planning^{1, 2, 12}.

MRI may complement CT for the diagnosis of orbital and paranasal sinus infections and is helpful in the detection of intracranial complications of orbital infection. Orbital cellulitis is a sight-threatening and potentially life-threatening condition. Urgent imaging is indicated to assess the anatomic extent of disease, including postseptal, cavernous sinus,

and intracranial involvement, and to identify orbital abscesses that require exploration and drainage. MRI provides excellent contrast resolution in the orbit and is a powerful imaging technique for detecting these conditions. Multiplanar capability and high spatial resolution allow MRI to provide details about the extent of disease, including involvement of important anatomic structures such as vessels. Diffusion-weighted MRI has been recently advocated for patients unable to receive contrast because of renal issues¹⁸.

4. Causative agents

The most common organisms isolated from blood, the paranasal sinuses and abscesses in orbital cellulitis are streptococcal species such as *Streptococcus milleri*, *pyogenes*, *pneumoniae*, as well as *Staphylococcus aureus*, and *Haemophilus influenzae* (type b) particularly in children under 4 years of age^{11, 19-22}. More unusual organisms include *Pseudomonas* spp, *Streptococcus faecalis* and *Eikenella corrodens*. Anaerobic organisms are generally associated with chronic sinusitis and are frequently isolated from patients with inflamed sinuses²³. A considerable number of specimens taken from those with orbital and intracranial complications grow anaerobes^{7, 21, 24, 25}. Nevertheless, some papers in the past have reported low, or indeed no anaerobic growth¹⁹. Poor sampling and culture techniques may have been responsible for these results and therapy against anaerobes was therefore often only started when there was no improvement in the clinical condition²⁶. There is strong evidence supporting the use of antibiotics such as metronidazole for anaerobic cover from the outset. Previous antibiotic regimens used to be highly variable, consisting of monotherapy or combinations. The regimens described have been inconsistent^{11, 19-22, 24-26}. As resistance has emerged there has been a move to use broad spectrum cephalosporins. With the introduction of the Hib vaccine it is expected that *H. influenzae* will be a less common pathogen²⁷. All patients admitted should therefore be started on intravenous antibiotherapy for aerobic and anaerobic pathogens (such as cefuroxime and metronidazole) and therapy should be changed appropriately as culture results become available³.

5. Treatment

Differentiating types of cellulitis based on the CT appearance helps the clinician to establish guidelines for the management of specific cases. Orbital cellulitis always requires hospitalization and intravenous antibiotics; in specific cases, surgery is needed. Orbital abscesses should be drained without delay. It is well known that intravenous antibiotics can penetrate the abscess²⁸, but without drainage their antibacterial activity within the abscess is poor, probably because the purulent milieu protects

the microorganisms by enzymatic degradation of antibiotics^{29, 30}. Therefore the risk of such cases developing intracranial complications is high. In addition, an orbital abscess provokes a rapid expansion of the orbital contents, which carries an extremely high risk of visual impairment¹.

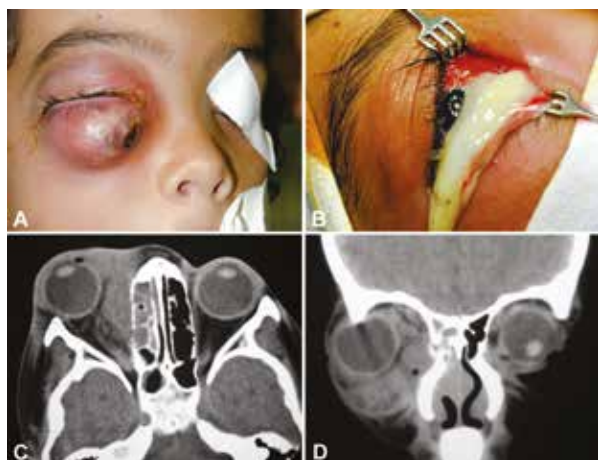


Fig. 6 – Patient with orbital and lower eyelid abscesses (A) who underwent surgical drainage through a conjunctival approach (B). Axial (C) and coronal (D) CT scans reveal an inferomedial abscess of the right orbit with diffuse infiltration.

Subperiosteal abscesses can also lead to intracranial complications and visual impairment^{31, 32}. However, this condition has distinct characteristics. The fluid collection is limited by the periorbital with varying amounts of fat infiltration beyond the well-demarcated border of the detached periorbital. It is well known that in some cases of periorbital detachment there is no pus between the bone wall and the periorbital, the periosteum elevation being caused by hemorrhagic or clear fluid and edema²⁵. The decision about the need for and timing of surgical drainage of a subperiosteal abscess is complex and involves the assessment of many factors including response to antibiotic treatment, patient age, and size and location of fluid collection^{1, 12, 33}.

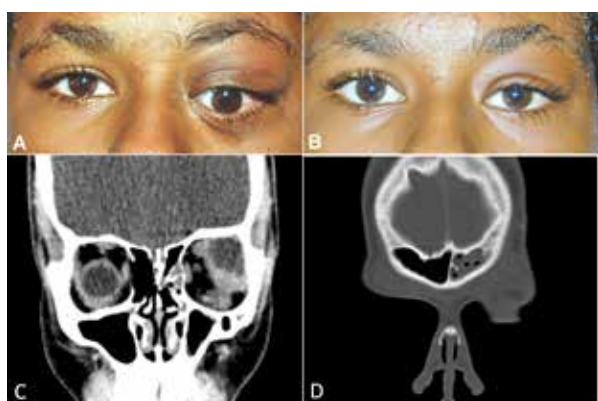

Fig. 7 - Young girl with upper eyelid swelling and left eye inferior dystopia: facial aspect before (A) and after (B) surgical drainage of a superolateral subperiosteal abscess associated with frontal sinusitis (coronal CT scans, C and D).

Diffuse fat infiltration can be seen as an initial stage in the continuum of forms of orbital infection. Since there is no true abscess, these cases can be managed with antibiotics alone. Careful follow-up of the clinical response to therapy will dictate the need for further imaging studies and for any surgical drainage if a subperiosteal or intraorbital abscess is formed¹.

6. Intracranial complications

The severe morbidity and mortality of orbital cellulitis may result from intracranial complications, including cavernous sinus thrombosis and intracranial infection. Because venous drainage of the middle third of the face and paranasal sinuses primarily occurs through the valveless orbital veins, which drain inferiorly to the pterygoid plexus and posteriorly to the cavernous sinus, cavernous sinus thrombophlebitis may occur as a complication of a sinus or orbital infection. Therefore, cavernous sinus thrombophlebitis itself may lead to blindness and is a serious medical emergency that requires prompt treatment³⁴⁻³⁶.

Intracranial infection (meningitis^{35, 37}, empyema or abscess of the epidural³⁵ or subdural space, and intracerebral abscess³⁶) can result from sinusitis by direct extension, hematogenous spread or retrograde thrombophlebitis via the diploic veins of Galen. A less common complication of sinusitis (specifically, frontal sinusitis) is Pott's puffy tumor, a frontal bone osteomyelitis resulting in a subperiosteal abscess presenting as a fluctuating mass over the forehead or scalp³⁸. Pott's puffy tumor can be complicated by downward spread to the orbit and subsequent orbital cellulitis with/without intracranial infection³⁹.

Once intracranial infection has been diagnosed and treatment initiated, serial imaging studies are needed to confirm clinical evidence of improvement and resolution of infection. Intracranial complications are most often treated with intravenous antibiotics, but abscesses sometimes need surgical drainage. These patients demand close monitoring by a multispecialty team (pediatrics, ophthalmology, otolaryngology, neurosurgery, radiology and infectious diseases). The mortality rate of patients with intracranial complications despite early and aggressive therapy can reach 25% in some series reported in the literature^{39, 40}. Intracranial infections secondary to rhinosinusitis occur sporadically and, although it appears that they cannot be prevented, early recognition and treatment are essential to reduce any subsequent morbidity or mortality^{14, 35}.

Non-Sinonasal Orbital Cellulitis

1. Odontogenic orbital cellulitis

Orbital cellulitis may result from a tooth-related infection and has been reported to occur as a result of a tooth

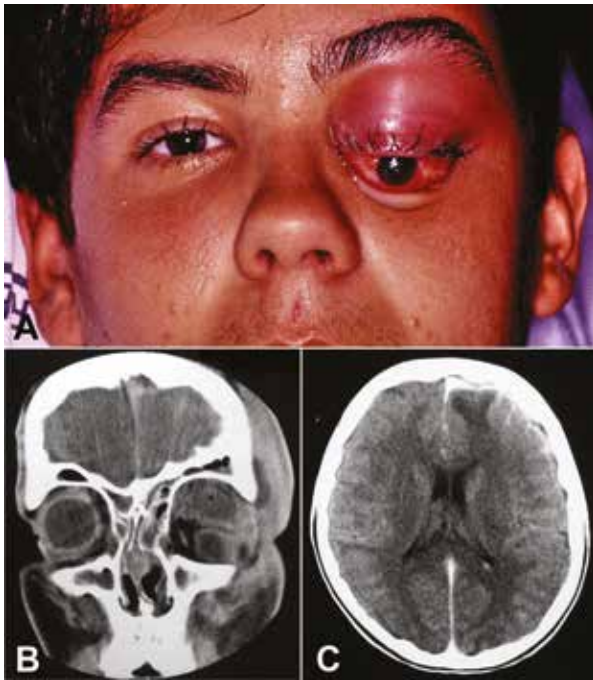

Fig. 8 – Superior orbital abscess. A) Exuberant left lid swelling and proptosis. A coronal CT scan shows a superior abscess associated with diffuse orbital infiltration complicated by cerebritis.

abscess, extraction and dental surgery. Although the widespread use of prophylactic and therapeutic antibiotics has decreased the incidence of ocular complications of dental origin, the odontogenic sources of orbital infection account for 2 to 5% of all cases of orbital cellulitis⁴¹⁻⁴⁵.

Three basic routes of spread of infection have been described in odontogenic orbital cellulitis: via the paranasal sinuses, via the premaxillary soft tissues, and posteriorly via the infratemporal fossa and inferior orbital fissure. The most common route is via the paranasal sinuses. The apices of the maxillary molars and premolars lie in close proximity to the floor of the maxillary sinus. Dental infection may result in sinusitis that may, in turn, involve the orbit. It is estimated that odontogenic infections account for approximately 10 to 12% of all cases of sinusitis^{41-44, 46-49}.

Odontogenic orbital cellulitis is usually polymicrobial, with proliferation of both aerobic and anaerobic species. The commonest organisms include sinus pathogens consisting of gram-positive aerobes (*S. aureus* and *epidermidis*, *Streptococcus*) and anaerobes (*Bacteroides*) and a few oral pathogens (*Peptostreptococcus*, *Prevotella*, *Fusobacterium*, and α -hemolytic *Streptococcus*)^{41, 43}.

The orbital manifestations of odontogenic orbital cellulitis are the same as those seen in orbital cellulitis secondary to sinus infection. A history of recent tooth infection, extraction or dental surgery may be the only clinical clue to the diagnosis. Dental nidus is often not obvious at initial clinical examination and CT findings are usually essential for a diagnosis. The hallmark

diagnostic findings of dental infection on CT scans include abnormal periapical lucency, loss of definition of the lamina dura, and widening of the periodontal ligament space. CT is also helpful in identifying sinus involvement, orbital abscesses, and cerebral complications such as cerebritis and brain abscesses. MRI can be useful in evaluating the retromaxillary soft tissues and cavernous sinus^{41-43, 46, 50}.

Multiple case reports have demonstrated that orbital cellulitis from an odontogenic source can result in devastating vision loss if not promptly treated^{41, 44, 51}. Youssef *et al* reviewed the literature on this topic and found a higher incidence of severe vision loss (light perception or worse) in this type of infection (46%) than in other causes of orbital cellulitis (11%)⁴¹. Odontogenic orbital cellulitis does not respond to antibiotics alone and requires incision and drainage of the periapical abscess or tooth extraction. Orbital or subperiosteal abscesses nearly always require emergency drainage to protect vision^{41-43, 50}.

2. Acute dacryocystitis

The immediate consequence of nasolacrimal duct obstruction is epiphora. In chronic cases, conjunctivitis and mucoid discharge ensue. Acute dacryocystitis can develop when significant bacterial growth occurs in the stagnant fluid of the lacrimal sac. The main complication of acute dacryocystitis is lacrimal sac abscess that often leads to fistulas draining to the skin. The infection can also spread to the lower eyelid tissues to become a preseptal cellulitis. Orbital extension occurs rarely and may result in diffuse cellulitis^{52, 53}, subperiosteal abscess^{54, 55} and intraconal⁵⁵⁻⁶² or extraconal^{55, 57, 63, 64} abscess formation with the risk of compromised vision^{55, 56}. The rarity of orbital extension has been attributed to the fact that the lacrimal sac is a preseptal structure^{55, 56}. In fact, the orbital septum inserts posteriorly at the lacrimal crest, acting as an anatomic barrier. In addition, other anatomical elements such as the lacrimal fascia, the posterior limb of the medial canthal ligament, and deep heads of the pretarsal and preseptal orbicularis muscles (Horner muscle) also act as a barrier to posterior extension^{55, 56}.

Once the infection ruptures the lacrimal sac the posterior barriers are likely to be overcome by the infection, leading to orbital cellulitis. Kikkawa *et al* postulated prior dacryocystitis as a risk factor for orbital extension by sac distension during episodes of dacryocystitis, with consequent stretching of the walls of the lacrimal sac and its posterior barriers. These barriers weaken from distension and increase the likelihood of posterior spread⁵⁷. Because of the anterior and inferior location of the lacrimal sac, a channel of communication can be formed between

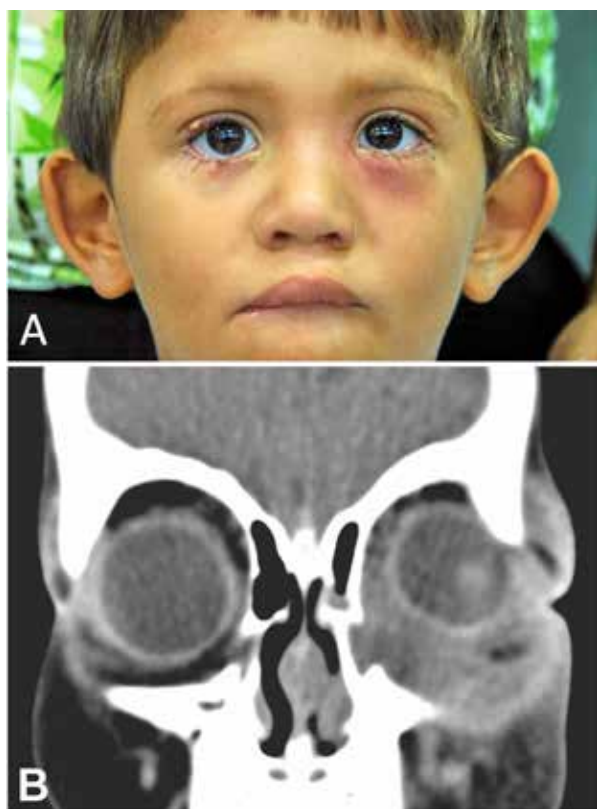


Fig. 9 - Orbital cellulitis caused by left acute dacryocystitis: A) Clinical presentation with swelling of the lower left eyelid. B) A coronal CT scan reveals an inferomedial abscess.

the medial and inferior rectus muscles directly to the intraconal space, leading to an intraconal abscess⁵⁵⁻⁵⁷. The microorganisms found in dacryocystitis-induced orbital cellulitis do not differ from the germs found in uncomplicated dacryocystitis. In most cases single isolates of gram-positive bacteria are found (mainly *Staphylococcus* and *Streptococcus* species)^{52, 54, 55, 57-59, 61-64}. Polymicrobial infections are rare^{53, 56, 57, 60}.

Orbital abscess formation can occur even in patients using oral antibiotics and can rapidly lead to vision loss⁵⁷. Intravenous antibiotic therapy is needed in all cases of orbital cellulitis. Although intravenous antibiotic therapy is necessary, surgical drainage of the orbital abscess is mandatory for the resolution of the acute orbital picture. Dacryocystorhinostomy can be delayed until complete resolution of the acute infectious disease⁵⁶.

In conclusion, acute dacryocystitis is an ophthalmic emergency that can cause orbital cellulitis with abscess formation and even vision loss if left untreated. It is very important to educate patients about the serious consequence of neglecting the symptoms of dacryocystitis.

3. Post-traumatic orbital cellulitis

Orbital infection is an uncommon and potentially devastating complication of upper and midfacial

trauma. Orbital trauma such as the introduction of foreign bodies⁶⁵⁻⁶⁷ and occurrence of orbital fractures^{66, 68-72} are only rarely associated with orbital cellulitis. Previous reports have described orbital cellulitis after orbital fractures with preexisting sinusitis^{68, 73, 74}. A break in the floor or medial wall of the orbit may facilitate direct extension of a sinus infection. The use of antibiotic prophylaxis in orbital fractures with or without involvement of the paranasal sinuses remains controversial, with no evidence that it decreases the incidence of post-traumatic infection^{70, 71, 75, 76}.

There are also reports of bacterial orbital cellulitis caused by infection of orbital implants used in orbital fracture repair^{66, 72, 77-82}. It is difficult to determine the incidence of infection because patients are often lost to follow-up and infections may occur as late as 20 years after implantation^{80, 83}.

Another controversial topic is the development of periorbital cellulitis after the closure of traumatic periorbital lacerations. The literature suggests a higher infection rate with tissue adhesive closure than with standard wound closure. Ineffective wound sterilization before tissue adhesive wound closure may contribute to the infection. Yeilding *et al* reported 3 cases of orbital extraconal cellulitis after tissue adhesive closure (Dermabond®), one of which was complicated with necrotizing fasciitis⁸⁴.

4. Post-surgery

Orbital cellulitis is a rare complication of ocular surgery. It has been described after surgery for strabismus⁸⁵⁻⁹³, cataract⁹⁴⁻⁹⁶, glaucoma⁹⁷⁻⁹⁹, blepharoplasty⁵³, pterygium¹⁰⁰ and retina¹⁰¹.

In many countries, cataract and glaucoma surgery are routinely performed under local anesthesia. Orbital cellulitis has been reported following sub-Tenon's^{96, 102-105} and peribulbar^{94, 95, 102, 106} anesthesia. There is a theoretical risk of providing a route for infection if an incision is made in the conjunctiva, Tenon's fascia and intermuscular septae¹⁰³. Sub-Tenon's and peribulbar anaesthesia involves a significant breach of the conjunctiva and iatrogenic commensal bacterial flora may be introduced into the sub-Tenon's space¹⁰². The literature suggests that the use of a povidone-iodine preparation over the skin and conjunctiva before opening up the conjunctiva can reduce the risk of infection. Topical povidone-iodine reduces the number of bacterial colonies on the conjunctiva by 91%^{96, 103, 104}. Retrobulbar injection of chlorpromazine hydrochloride is used by some physicians in Europe and the United States for the relief of pain in persons with irreversible blindness. Margo *et al* reported a case of orbital cellulitis following retrobulbar injection of chlorpromazine associated with histologic evidence of fat necrosis¹⁰⁷.

Orbital cellulitis after strabismus surgery is rare and

affects children far more than adults⁹³; it has been reported in 1/1000 to 1/1900 surgeries¹⁰⁸. There are multiple possible sources of infection after strabismus surgery, including intraoperative contamination, self-contamination after surgery by a nonhygienic patient, and concomitant sinus disease⁸⁸.

Although a number of complications are known to occur with the aqueous drainage device procedures used in the management of complicated glaucoma, orbital complications are few. To the best of our knowledge, only single cases of orbital complications have been reported: orbital cellulitis, myositis, cosmetically significant proptosis, and silicone oil migration. In the few cases found in the literature, tube exposure seems to be the source of the orbital infection. Systemic antibiotic therapy and removal of the implant are recommended in cases of clear orbital infection⁹⁷⁻⁹⁹.

A rare complication of scleral buckling surgery is the anterior migration of an encircling band through the muscle insertions. If the extruding band or sponge gets infected it can lead to orbital cellulitis. The explant removal provides symptomatic relief but is linked to a small risk of redetachment, especially within 6 months postoperatively. Careful removal of the extruding silicone scleral buckle is recommended (without interfering with the muscle insertions) to reduce the possibility of infection and preserve the rectus muscle function, and consequently ocular motility¹⁰¹.

Orbital cellulitis after orbital decompression surgery, which is an iatrogenic orbital fracture, is very rare and most commonly occurs when infectious paranasal sinusitis is present. The organisms from adjacent infected sinuses may enter the orbital cavity via the fracture and disrupted periorbital, with subsequent cellulitis and abscess formation⁷¹.

5. Endophthalmitis and panophthalmitis

Endogenous bacterial endophthalmitis and panophthalmitis result from the hematogenous spread of microorganisms into the eye during bacteremia, usually from a remote source. Predisposing factors include immunocompromised state, intravenous drug abuse and prolonged intensive care unit stay^{109, 110}.

Concurrent orbital cellulitis and panophthalmitis are rarely reported but have been described in cases of *Pseudomonas* septicemia and ecthyma gangrenosum¹¹¹ or extensive skin burns¹¹², and in *Escherichia coli* septicemia^{109, 113}, after radial keratotomy¹¹⁴ and following trauma^{115, 116}. Almost all patients required evisceration or enucleation.

Coexistence of endophthalmitis and orbital cellulitis is unusual. Endogenous endophthalmitis has been described in *Pseudomonas* pneumonia and skin lesions of ecthyma gangrenosum¹¹⁷, bacterial endocarditis¹¹⁸ and calculus cholecystitis¹¹⁰. Chaudhry *et al* reported

218 patients with orbital cellulitis, where endogenous endophthalmitis was the predisposing cause in 29 patients (13.3%). All of them required evisceration or enucleation despite treatment with systemic antibiotics¹¹⁹.

Endophthalmitis can also occur following surgery. It is a well-known complication that occurs in 1/1000 patients after cataract surgery. The most common organisms are gram-positive coagulase-negative species. A few reports have documented a marked progression to orbital cellulitis in immunocompetent and immunocompromised patients^{105, 120}. This is a very rare complication of corneal surgeries. Pavan *et al* published a case of endophthalmitis coexisting with orbital cellulitis after rupture of a penetrating keratoplasty wound¹²¹.

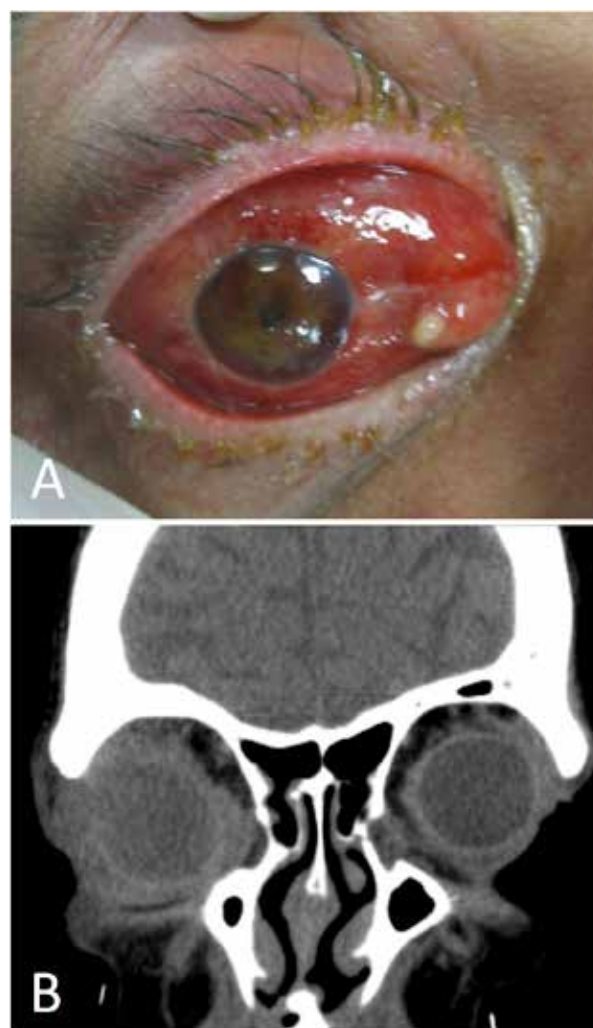


Fig. 10 – Orbital cellulitis due to an endogenous panophthalmitis. A) Clinical presentation with globe rupture. B) A coronal CT scan showed irregular contours of the lateral side of the right eyeball with associated orbital abscess.

6. Local and systemic predisposing conditions

Local and systemic conditions may predispose to orbital cellulitis. There are few reports of retinoblastoma¹²²⁻¹²⁷ and paranasal sinus tumors^{128, 129} associated with orbital cellulitis. Walinjar

et al reviewed 260 cases of retinoblastoma and found only 5.39% with retinoblastoma-associated cellulitis¹²². Mullaney *et al* reported a series of 292 retinoblastomas and found a similar percentage (4.8%)¹²³. In both studies, orbital cellulitis was more common in advanced necrotic retinoblastomas, but that did not necessarily indicate extrascleral extension of the tumor, although it correlated well with the presence of advanced intraocular disease and anterior chamber involvement. In some cases, there was only an orbital cellulitis-like picture without a real orbital infection. It is essential to differentiate between these conditions so that proper management can be instituted^{122, 123}. Paranasal sinus tumors such as ethmoid osteoma^{128, 129}, and maxillary solitary extramedullary plasmacytoma¹³⁰, may erode adjacent bones and also lead to proptosis, ocular motility disturbance and orbital cellulitis.

Systemic diseases, especially those affecting immunocompromised patients, can predispose to orbital cellulitis. There are some reports of orbital infection associated with diabetes mellitus^{109, 113, 131-133}, pancreatic¹⁰⁹, breast¹³⁴ and esophagus¹³⁵ cancers, non-Hodgkin lymphoma^{114, 136}, leukemia¹³⁷⁻¹³⁹ and myelodysplastic syndrome^{111, 140}, AIDS¹⁴¹ and infliximab treatment for ankylosing spondylitis¹⁴². All of these conditions are associated with an increased risk of serious opportunistic infections and if not promptly treated they can have a truly fulminating progression.

7. Miscellaneous

The literature shows some isolated and interesting cases of orbital cellulitis. Rat bite is known to cause a local inflammatory reaction that may rarely progress to the stage of cellulitis. Diwan *et al* reported a case in which the bite of a house rat near the inner end of the left eyebrow caused orbital cellulitis and proptosis¹⁴³. Parasomnias are defined as undesirable behavioral events during sleep such as nightmares, sleep terrors and sleep walking. We found a very unusual case in the literature of a child who presented with orbital cellulitis secondary to self-inflicted periocular and facial lacerations while asleep¹⁴⁴.

Conclusion

Bacterial orbital cellulitis is a serious condition with potentially devastating complications, including loss of visual acuity, cavernous sinus thrombosis, meningitis, intracranial abscess formation, cerebritis, septic embolus, and even death. A prompt and accurate diagnosis is therefore critical for the treatment of orbital cellulitis to avoid vision and life-threatening complications.

References

- Pereira FJ, Velasco e Cruz AA, Anselmo-Lima WT, Elias Junior J. Computed tomographic patterns of orbital cellulitis due to sinusitis. *Arq Bras Oftalmol*. 2006;69(4):513-8.
- Velasco e Cruz AA, Demarco RC, Valera FC, dos Santos AC, Anselmo-Lima WT, Marquezini RM. Orbital complications of acute rhinosinusitis: a new classification. *Braz J Otorhinolaryngol*. 2007;73(5):684-8.
- Howe L, Jones NS. Guidelines for the management of periorbital cellulitis/abscess. *Clin Otolaryngol Allied Sci*. 2004;29(6):725-8.
- Vairaktaris E, Moschos MM, Vassiliou S, Baltatzis S, Kalimeras E, Avgoustidis D, et al. Orbital cellulitis, orbital subperiosteal and intraorbital abscess: report of three cases and review of the literature. *J Craniomaxillofac Surg*. 2009;37(3):132-6.
- Ognibene RZ VR, Bensadon RL, Butugan O. Complications of sinusitis. *Am J Rhinology*. 1994;8:175-9.
- Mortimore S, Wormald PJ. The Groote Schuur hospital classification of the orbital complications of sinusitis. *J Laryngol Otol*. 1997;111(8):719-23.
- Chandler JR, Langenbrunner DJ, Stevens ER. The pathogenesis of orbital complications in acute sinusitis. *Laryngoscope*. 1970;80(9):1414-28.
- Krohnel GB, Krauss HR, Winnick J. Orbital abscess. Presentation, diagnosis, therapy, and sequelae. *Ophthalmology*. 1982;89(5):492-8.
- Hubert L. Orbital infections due to nasal sinusitis. *N Y State J Med*. 1937;37:1559-64.
- Smith AT, Spencer JT. Orbital complications resulting from lesions of the sinuses. *Ann Otol Rhinol Laryngol*. 1948;57(1):5-27.
- Moloney JR, Badham NJ, McRae A. The acute orbit. Preseptal (periorbital) cellulitis, subperiosteal abscess and orbital cellulitis due to sinusitis. *J Laryngol Otol Suppl*. 1987;12:1-18.
- Le TD, Liu ES, Adatia FA, Buncic JR, Blaser S. The effect of adding orbital computed tomography findings to the Chandler criteria for classifying pediatric orbital cellulitis in predicting which patients will require surgical intervention. *J AAPOS*. 2014;18(3):271-7.
- Eustis HS, Armstrong DC, Buncic JR, Morin JD. Staging of orbital cellulitis in children: computerized tomography characteristics and treatment guidelines. *J Pediatr Ophthalmol Strabismus*. 1986;23(5):246-51.
- Jones NS, Walker JL, Bassi S, Jones T, Punt J. The intracranial complications of rhinosinusitis: can they be prevented? *Laryngoscope*. 2002;112(1):59-63.
- Hershey BL, Roth TC. Orbital infections. *Semin Ultrasound CT MR*. 1997;18(6):448-59.
- Martin-Hirsch DP, Habashi S, Hinton AH, Kotecha B. Orbital cellulitis. *Arch Emerg Med*. 1992;9(2):143-8.
- Clary RA, Cunningham MJ, Eavey RD. Orbital complications of acute sinusitis: comparison of computed tomography scan and surgical findings. *Ann Otol Rhinol Laryngol*. 1992;101(7):598-600.
- Supsupin EP, Jr., Demian NM. Magnetic resonance imaging (MRI) in the diagnosis of head and neck disease. *Oral Maxillofac Surg Clin North Am*. 2014;26(2):253-69.
- Swift AC, Charlton G. Sinusitis and the acute orbit in children. *J Laryngol Otol*. 1990;104(3):213-6.
- Davis JP, Stearns MP. Orbital complications of sinusitis: avoid delays in diagnosis. *Postgrad Med J*. 1994;70(820):108-10.
- Schramm VL, Jr., Curtin HD, Kennerdell JS. Evaluation of orbital cellulitis and results of treatment. *Laryngoscope*. 1982;92(7 Pt 1):732-8.

22. Mills R. Orbital and periorbital sepsis. *J Laryngol Otol.* 1987;101(12):1242-7.
23. Frederick J, Braude AI. Anaerobic infection of the paranasal sinuses. *N Engl J Med.* 1974;290(3):135-7.
24. Brook I, Friedman EM, Rodriguez WJ, Controni G. Complications of sinusitis in children. *Pediatrics.* 1980;66(4):568-72.
25. Harris GJ. Subperiosteal inflammation of the orbit. A bacteriological analysis of 17 cases. *Arch Ophthalmol.* 1988;106(7):947-52.
26. Barkin RM, Todd JK, Amer J. Periorbital cellulitis in children. *Pediatrics.* 1978;62(3):390-2.
27. Ambati BK, Ambati J, Azar N, Stratton L, Schmidt EV. Periorbital and orbital cellulitis before and after the advent of Haemophilus influenzae type B vaccination. *Ophthalmology.* 2000;107(8):1450-3.
28. Yamamoto M, Jimbo M, Ide M, Tanaka N, Umebara Y, Hagiwara S. Penetration of intravenous antibiotics into brain abscesses. *Neurosurgery.* 1993;33(1):44-9.
29. Galandiuk S, Lamos J, Montgomery W, Young S, Polk HC, Jr. Antibiotic penetration of experimental intra-abdominal abscesses. *Am Surg.* 1995;61(6):521-5.
30. Black P, Graybill JR, Charache P. Penetration of brain abscess by systemically administered antibiotics. *J Neurosurg.* 1973;38(6):705-9.
31. Harris GJ. Subperiosteal abscess of the orbit. Age as a factor in the bacteriology and response to treatment. *Ophthalmology.* 1994;101(3):585-95.
32. Hamilton RC. A discourse on the complications of retrobulbar and peribulbar blockade. *Can J Ophthalmol.* 2000;35(7):363-72.
33. Garcia GH, Harris GJ. Criteria for nonsurgical management of subperiosteal abscess of the orbit: analysis of outcomes 1988-1998. *Ophthalmology.* 2000;107(8):1454-6; discussion 7-8.
34. Yang SJ, Park SY, Lee YJ, Kim HY, Seo JA, Kim SG, et al. Klebsiella pneumoniae orbital cellulitis with extensive vascular occlusions in a patient with type 2 diabetes. *Korean J Intern Med.* 2010;25(1):114-7.
35. Hytonen M, Atula T, Pitkaranta A. Complications of acute sinusitis in children. *Acta Otolaryngol Suppl.* 2000;543:154-7.
36. Udaondo P, Garcia-Delpech S, Diaz-Llopis M, Salom D, Garcia-Pous M, Strottmann JM. Bilateral intraorbital abscesses and cavernous sinus thromboses secondary to Streptococcus milleri with a favorable outcome. *Ophthal Plast Reconstr Surg.* 2008;24(5):408-10.
37. Rubinstein JB, Handler SD. Orbital and periorbital cellulitis in children. *Head Neck Surg.* 1982;5(1):15-21.
38. Pender ES. Pott's puffy tumor: a complication of frontal sinusitis. *Pediatr Emerg Care.* 1990;6(4):280-4.
39. Reynolds DJ, Kodosi SR, Rubin SE, Rodgers IR. Intracranial infection associated with preseptal and orbital cellulitis in the pediatric patient. *J AAPOS.* 2003;7(6):413-7.
40. Maniglia AJ, Goodwin WJ, Arnold JE, Ganz E. Intracranial abscesses secondary to nasal, sinus, and orbital infections in adults and children. *Arch Otolaryngol Head Neck Surg.* 1989;115(12):1424-9.
41. Youssef OH, Stefanyshyn MA, Bilyk JR. Odontogenic orbital cellulitis. *Ophthal Plast Reconstr Surg.* 2008;24(1):29-35.
42. DeCroos FC, Liao JC, Ramey NA, Li I. Management of odontogenic orbital cellulitis. *J Med Life.* 2011;4(3):314-7.
43. Caruso PA, Watkins LM, Suwansaard P, Yamamoto M, Durand ML, Romo LV, et al. Odontogenic orbital inflammation: clinical and CT findings--initial observations. *Radiology.* 2006;239(1):187-94.
44. Park CH, Jee DH, La TY. A case of odontogenic orbital cellulitis causing blindness by severe tension orbit. *J Korean Med Sci.* 2013;28(2):340-3.
45. Bullock JD, Fleishman JA. Orbital cellulitis following dental extraction. *Trans Am Ophthalmol Soc.* 1984;82:111-33.
46. Flood TP, Braude LS, Jampol LM, Herzog S. Computed tomography in the management of orbital infections associated with dental disease. *Br J Ophthalmol.* 1982;66(4):269-74.
47. Thakar M, Thakar A. Odontogenic orbital cellulitis. Report of a case and considerations on route of spread. *Acta Ophthalmol Scand.* 1995;73(5):470-1.
48. Yates C, Monks A. Orbital cellulitis complicating the extraction of infected teeth. *J Dent.* 1978;6(3):229-32.
49. Janakarajah N, Sukumaran K. Orbital cellulitis of dental origin: case report and review of the literature. *Br J Oral Maxillofac Surg.* 1985;23(2):140-5.
50. Kaban LB, McGill T. Orbital cellulitis of dental origin: differential diagnosis and the use of computed tomography as a diagnostic aid. *J Oral Surg.* 1980;38(9):682-5.
51. Ogundiya DA, Keith DA, Mirowski J. Cavernous sinus thrombosis and blindness as complications of an odontogenic infection: report of a case and review of literature. *J Oral Maxillofac Surg.* 1989;47(12):1317-21.
52. Schmitt NJ, Beatty RL, Kennerdell JS. Superior ophthalmic vein thrombosis in a patient with dacryocystitis-induced orbital cellulitis. *Ophthal Plast Reconstr Surg.* 2005;21(5):387-9.
53. Allen MV, Cohen KL, Grimson BS. Orbital cellulitis secondary to dacryocystitis following blepharoplasty. *Ann Ophthalmol.* 1985;17(8):498-9.
54. Warrak E, Khoury P. Orbital abscess secondary to acute dacryocystitis. *Can J Ophthalmol.* 1996;31(4):201-2.
55. Maheshwari R, Maheshwari S, Shah T. Acute dacryocystitis causing orbital cellulitis and abscess. *Orbit.* 2009;28(2-3):196-9.
56. Martins MC, Ricardo JR, Akaishi PM, Velasco e Cruz AA. Orbital abscess secondary to acute dacryocystitis: case report. *Arq Bras Oftalmol.* 2008;71(4):576-8.
57. Kikkawa DO, Heinz GW, Martin RT, Nunery WN, Eiseleman AS. Orbital cellulitis and abscess secondary to dacryocystitis. *Arch Ophthalmol.* 2002;120(8):1096-9.
58. Atallah S, Sloan B. Acute dacryocystitis presenting as an orbital abscess. *Clin Experiment Ophthalmol.* 2002;30(1):44-6.
59. Mauriello JA, Jr., Wasserman BA. Acute dacryocystitis: an unusual cause of life-threatening orbital intraconal abscess with frozen globe. *Ophthal Plast Reconstr Surg.* 1996;12(4):294-5.
60. Ntountas I, Morschbacher R, Pratt D, Patel BC, Anderson RL, McCann JD. An orbital abscess secondary to acute dacryocystitis. *Ophthalmic Surg Lasers.* 1997;28(9):758-61.
61. Weiss GH, Leib ML. Congenital dacryocystitis and retrobulbar abscess. *J Pediatr Ophthalmol Strabismus.* 1993;30(4):271-2.
62. Mohan ER, Chandravanshi SC, Udhay P. Retrobulbar orbital abscess secondary to dacryocystitis in a neonate. *Ophthal Plast Reconstr Surg.* 2007;23(3):238-40.
63. Molgat YM, Hurwitz JJ. Orbital abscess due to acute dacryocystitis. *Can J Ophthalmol.* 1993;28(4):181-3.
64. Ahrens-Palumbo MJ, Ballen PH. Primary dacryocystitis causing orbital cellulitis. *Ann Ophthalmol.* 1982;14(6):600-1.
65. Menon KV, Al Rawi AE, Taif S, Al Ghafri K, Mollahalli KK. Orbital roof fracture and orbital cellulitis secondary to halo pin penetration: case report. *Global Spine J.* 2015;5(1):63-8.
66. Zimmerman RA, Bilaniuk LT. CT of orbital infection

- and its cerebral complications. *AJR Am J Roentgenol*. 1980;134(1):45-50.
67. Sodhi KS, Coleman L. Impacted intranasal foreign body causing orbital cellulitis and mistaken for orbital pathology. *Afr J Paediatr Surg*. 2010;7(3):215-6.
 68. Paterson AW, Barnard NA, Irvine GH. Naso-orbital fracture leading to orbital cellulitis, and visual loss as a complication of chronic sinusitis. *Br J Oral Maxillofac Surg*. 1994;32(2):80-2.
 69. Lindstrom DG, Harris MA, Sivak-Callcott JA, Nguyen J. Delayed *Eikenella corrodens* orbital infection after fracture repair. *Ophthalm Plast Reconstr Surg*. 2012;28(2):e45-7.
 70. Goldfarb MS, Hoffman DS, Rosenberg S. Orbital cellulitis and orbital fractures. *Ann Ophthalmol*. 1987;19(3):97-9, 115.
 71. Ben Simon GJ, Bush S, Selva D, McNab AA. Orbital cellulitis: a rare complication after orbital blowout fracture. *Ophthalmology*. 2005;112(11):2030-4.
 72. Silver HS, Fucci MJ, Flanagan JC, Lowry LD. Severe orbital infection as a complication of orbital fracture. *Arch Otolaryngol Head Neck Surg*. 1992;118(8):845-8; discussion 82.
 73. Dhariwal DK, Kittur MA, Farrier JN, Sugar AW, Aird DW, Laws DE. Post-traumatic orbital cellulitis. *Br J Oral Maxillofac Surg*. 2003;41(1):21-8.
 74. Chien HF, Wu CH, Wen CY, Shieh JY. Cadaveric study of blood supply to the lower intraorbital fat: etiologic relevance to the complication of anaerobic cellulitis in orbital floor fracture. *J Formos Med Assoc*. 2001;100(3):192-7.
 75. Westfall CT, Shore JW. Isolated fractures of the orbital floor: risk of infection and the role of antibiotic prophylaxis. *Ophthalmic Surg*. 1991;22(7):409-11.
 76. Wladis EJ. Are post-operative oral antibiotics required after orbital floor fracture repair? *Orbit*. 2013;32(1):30-2.
 77. Warrior S, Prabhakaran VC, Davis G, Selva D. Delayed complications of silicone implants used in orbital fracture repairs. *Orbit*. 2008;27(3):147-51.
 78. Mauriello JA, Jr., Atypical Mycobacterial Study G. Atypical mycobacterial infection of the periocular region after periocular and facial surgery. *Ophthalm Plast Reconstr Surg*. 2003;19(3):182-8.
 79. Custer PL, Lind A, Trinkaus KM. Complications of supramid orbital implants. *Ophthalm Plast Reconstr Surg*. 2003;19(1):62-7.
 80. Mauriello JA, Jr., Hargrave S, Yee S, Mostafavi R, Kapila R. Infection after insertion of alloplastic orbital floor implants. *Am J Ophthalmol*. 1994;117(2):246-52.
 81. Kwon H, Kim SW, Jung SN, Sohn WI, Moon SH. Cellulitis related to bioabsorbable plate and screws in infraorbital rim fracture. *J Craniofac Surg*. 2011;22(2):625-7.
 82. Kent SS, Kent JS, Allen LH. Porous polyethylene implant associated with orbital cellulitis and intraorbital abscess. *Can J Ophthalmol*. 2012;47(6):e38-9.
 83. Jayamanne DG, Bell RW, Allen ED. Orbital cellulitis—an unusual presentation and late complication of severe facial trauma. *Br J Oral Maxillofac Surg*. 1994;32(3):187-9.
 84. Yeilding RH, O'Day DM, Li C, Alexander PT, Mawn LA. Periorbital infections after Dermabond closure of traumatic lacerations in three children. *J AAPOS*. 2012;16(2):168-72.
 85. Wilson ME, Paul TO. Orbital cellulitis following strabismus surgery. *Ophthalmic Surg*. 1987;18(2):92-4.
 86. Weakley DR. Orbital cellulitis complicating strabismus surgery: a case report and review of the literature. *Ann Ophthalmol*. 1991;23(12):454-7.
 87. Palamar M, Uretmen O, Kose S. Orbital cellulitis after strabismus surgery. *J AAPOS*. 2005;9(6):602-3.
 88. Hoyama E, Limawarut V, Leibovitch I, Pater J, Davis G, Selva D. Blinding orbital cellulitis: a complication of strabismus surgery. *Ophthalm Plast Reconstr Surg*. 2006;22(6):472-3.
 89. Basheikh A, Superstein R. A child with bilateral orbital cellulitis one day after strabismus surgery. *J AAPOS*. 2009;13(5):488-90.
 90. Armesto A, Ugrin MC. Orbital cellulitis after faden operation on the medial rectus. *Strabismus*. 2007;15(4):215-9.
 91. Lau FH, Leung TF, Fan DS. An unusual complication after strabismus surgery. *Hong Kong Med J*. 2009;15(4):297-8.
 92. Muzzi E, Parentin F, Pelos G, Grasso DL, Lora L, Traballini F, et al. Bilateral orbital preseptal cellulitis after combined adenotonsillectomy and strabismus surgery—case report and pathogenetic hypothesis. *Int J Pediatr Otorhinolaryngol*. 2013;77(7):1209-11.
 93. Strul S, McCracken MS, Cunin K. Orbital cellulitis and intraconal abscess formation after strabismus surgery in an adult patient. *J AAPOS*. 2014;18(1):82-4.
 94. Irvine F, McNab AA. Orbital abscess following uncomplicated phacoemulsification cataract surgery. *Clin Experiment Ophthalmol*. 2002;30(6):430-1.
 95. Kumar V, Saunders D. Orbital cellulitis after phacoemulsification and intraocular lens implantation. *J Cataract Refract Surg*. 2004;30(4):918-20.
 96. Liang SY, Moloney G, O'Donnell BA, Fernando G. Orbital cellulitis as a postoperative complication of sub-Tenon anaesthesia in cataract surgery. *Clin Experiment Ophthalmol*. 2006;34(9):897-9.
 97. Marcet MM, Woog JJ, Bellows AR, Mandeville JT, Maltzman JS, Khan J. Orbital complications after aqueous drainage device procedures. *Ophthalm Plast Reconstr Surg*. 2005;21(1):67-9.
 98. Karr DJ, Weinberger E, Mills RP. An unusual case of cellulitis associated with a Molteno implant in a 1-year-old child. *J Pediatr Ophthalmol Strabismus*. 1990;27(2):107-10.
 99. Lavina AM, Creasy JL, Tsai JC. Orbital cellulitis as a late complication of glaucoma shunt implantation. *Arch Ophthalmol*. 2002;120(6):849-51.
 100. Furness GA, Atkinson PL. Late bacterial scleritis following beta irradiation presenting as orbital cellulitis. *Aust N Z J Ophthalmol*. 1995;23(2):153-5.
 101. Kotoulas A, Symeonidis C, Kalantzis G, Droutsas K, Koutsandrea C, Georgalas I. Total extrusion of a silicone encircling band through the muscle insertions presenting as orbital cellulitis. *Orbit*. 2014;33(4):308-10.
 102. Kumar CM, Dowd TC, Dodds C, Boyce R. Orbital swelling following peribulbar and sub-Tenon's anaesthesia. *Eye (Lond)*. 2004;18(4):418-20.
 103. Muqit MM, Saidkasimova S, Gavin M. Acute orbital cellulitis after sub-Tenon's eye block. *Anaesthesia*. 2004;59(4):411-3.
 104. Dahlmann AH, Appaswamy S, Headon MP. Orbital cellulitis following sub-Tenon's anaesthesia. *Eye (Lond)*. 2002;16(2):200-1.
 105. Lip PL, Moutsou M, Hero M. A postoperative complication far worse than endophthalmitis: the coexistence of orbital cellulitis. *Br J Ophthalmol*. 2001;85(5):631-2.
 106. Hofbauer JD, Gordon LK, Palmer J. Acute orbital cellulitis after peribulbar injection. *Am J Ophthalmol*. 1994;118(3):391-2.
 107. Margo CE, Wilson T. Orbital cellulitis after retrobulbar injection of chlorpromazine. *Arch Ophthalmol*. 1993;111(10):1322.
 108. Ing MR. Infection following strabismus surgery. *Ophthalmic Surg*. 1991;22(1):41-3.
 109. Papakostas TD, Lee NG, Lefebvre DR, Barshak MB, Freitag SK. Endogenous panophthalmitis with orbital cellulitis secondary to *Escherichia coli*. *Clin Experiment Ophthalmol*. 2013;41(7):716-8.

110. Argelich R, Ibanez-Flores N, Bardavio J, Bures-Jelstrup A, Garcia-Segarra G, Coll-Colell R, et al. Orbital cellulitis and endogenous endophthalmitis secondary to *Proteus mirabilis* cholecystitis. *Diagn Microbiol Infect Dis*. 2009;64(4):442-4.
111. Maccheron LJ, Groeneveld ER, Ohlrich SJ, Hilford DJ, Beckingsale PS. Orbital cellulitis, panophthalmitis, and ecthyma gangrenosum in an immunocompromised host with *Pseudomonas* septicemia. *Am J Ophthalmol*. 2004;137(1):176-8.
112. Jain ML, Garg AK. Metastatic endophthalmitis in a patient with major burns: a rare complication. *Burns*. 1995;21(1):72-3.
113. Burns SJ, Scott JA, Hiscott PS, Hebbar G, Kamaruddin K, Jalili IK. *E coli* panophthalmitis with orbital cellulitis. *Eye (Lond)*. 1997;11 (Pt 3):436-8.
114. McLeod SD, Flowers CW, Lopez PF, Marx J, McDonnell PJ. Endophthalmitis and orbital cellulitis after radial keratotomy. *Ophthalmology*. 1995;102(12):1902-7.
115. Yabbara KF, Juffali F, Matossian RM. *Bacillus laterosporus* endophthalmitis. *Arch Ophthalmol*. 1977;95(12):2187-9.
116. Crock GW, Heriot WJ, Janakiraman P, Weiner JM. Gas gangrene infection of the eyes and orbits. *Br J Ophthalmol*. 1985;69(2):143-8.
117. Luemsamran P, Pornpanich K, Vangveeravong S, Mekandha P. Orbital cellulitis and endophthalmitis in *Pseudomonas* septicemia. *Orbit*. 2008;27(6):455-7.
118. Hornblass A, To K, Coden DJ, Ahn-Lee S. Endogenous orbital cellulitis and endogenous endophthalmitis in subacute bacterial endocarditis. *Am J Ophthalmol*. 1989;108(2):196-7.
119. Chaudhry IA, Shamsi FA, Elzaridi E, Al-Rashed W, Al-Amri A, Al-Anezi F, et al. Outcome of treated orbital cellulitis in a tertiary eye care center in the middle East. *Ophthalmology*. 2007;114(2):345-54.
120. Decock C, Claerhout I, Kestelyn P, Van Aken EH. Orbital cellulitis as complication of endophthalmitis after cataract surgery. *J Cataract Refract Surg*. 2010;36(4):673-5.
121. Pavan PR, Oteiza EE, Hughes BA, Avni A. Exogenous endophthalmitis initially treated without systemic antibiotics. *Ophthalmology*. 1994;101(7):1289-96; discussion 96-7.
122. Walinjkar J, Krishnakumar S, Gopal L, Ramesh A, Khetan V. Retinoblastoma presenting with orbital cellulitis. *J AAPOS*. 2013;17(3):282-6.
123. Mullaney PB, Karciglu ZA, Huaman AM, al-Mesfer S. Retinoblastoma associated orbital cellulitis. *Br J Ophthalmol*. 1998;82(5):517-21.
124. Agarwal M, Biswas J, S K, Shanmugam MP. Retinoblastoma presenting as orbital cellulitis: report of four cases with a review of the literature. *Orbit*. 2004;23(2):93-8.
125. Chawla B, Duraipandi K, Sharma S. MRI in retinoblastoma with orbital cellulitis. *Ophthalmology*. 2013;120(6):1308-9 e1-4.
126. Suzuki S. A case of bilateral retinoblastoma with left orbital cellulitis. *Jpn J Clin Oncol*. 2009;39(4):274.
127. Sachdeva R, Schoenfield L, Marcotty A, Singh AD. Retinoblastoma with autoinfarction presenting as orbital cellulitis. *J AAPOS*. 2011;15(3):302-4.
128. Cecire A, Harrison HC, Ng P. Ethmoid osteoma, orbital cellulitis and orbital emphysema. *Aust N Z J Ophthalmol*. 1988;16(1):11-4.
129. Mansour AM, Salti H, Uwaydat S, Dakroub R, Bashshour Z. Ethmoid sinus osteoma presenting as epiphora and orbital cellulitis: case report and literature review. *Surv Ophthalmol*. 1999;43(5):413-26.
130. Kelly SP, Lloyd IC, Anderson H, Joyce PW, Pace-Balzan A. Solitary extramedullary plasmacytoma of the maxillary antrum and orbit presenting as acute bacterial orbital cellulitis. *Br J Ophthalmol*. 1991;75(7):438-9.
131. Colapinto P, Aslam SA, Frangouli O, Joshi N. Undiagnosed type 2 diabetes mellitus presenting with orbital cellulitis. *Orbit*. 2008;27(5):380-2.
132. Wong JS, Chan TK, Lee HM, Chee SP. Endogenous bacterial endophthalmitis: an east Asian experience and a reappraisal of a severe ocular affliction. *Ophthalmology*. 2000;107(8):1483-91.
133. Alaghband P, Oworu O. An unusual case of orbital cellulitis due to *Panton Valentine Leucocidine* producing *Staphylococcus aureus*. *Eye (Lond)*. 2013;27(1):108-9.
134. Stevens RJ, Rusby JE, Graham MD. Periorbital cellulitis with breast cancer. *J R Soc Med*. 2003;96(6):292-4.
135. Oh KT, Alford M, Kotula RJ, Nerad JA. Adenocarcinoma of the esophagus presenting as orbital cellulitis. *Arch Ophthalmol*. 2000;118(7):986-8.
136. Mak ST, Wong AC, Tse RK. Diffuse large B-cell lymphoma masquerading as orbital cellulitis. *Hong Kong Med J*. 2010;16(6):484-6.
137. Morgan KW, Callen JP. Sweet's syndrome in acute myelogenous leukemia presenting as periorbital cellulitis with an infiltrate of leukemic cells. *J Am Acad Dermatol*. 2001;45(4):590-5.
138. Milstone AM, Ruff AJ, Yeaman C, Higman MA. *Pseudomonas aeruginosa* pre-septal cellulitis and bacteremia in a pediatric oncology patient. *Pediatr Blood Cancer*. 2005;45(3):353; discussion 4.
139. Farah E, Kalantzis G, Papaefthimiou I, Koutsandrea C, Georgalas I. Spontaneously resolved exudative retinal detachment caused by orbital cellulitis in an immunocompromised adult. *Eye (Lond)*. 2014;28(1):109-10.
140. Chou SY, Tsai CC, Kau SC, Kau HC, Hsu WM. *Aeromonas hydrophila* orbital cellulitis in a patient with myelodysplastic syndrome. *J Chin Med Assoc*. 2004;67(1):51-3.
141. Cano-Parra J, Espana E, Esteban M, Diaz-Llopis M, Menezo JL. *Pseudomonas* conjunctival ulcer and secondary orbital cellulitis in a patient with AIDS. *Br J Ophthalmol*. 1994;78(1):72-3.
142. Roos JC, Ostor AJ. Orbital cellulitis in a patient receiving infliximab for Ankylosing spondylitis. *Am J Ophthalmol*. 2006;141(4):767-9.
143. Diwan R, Sen DK, Sood GC. Rat bite orbital cellulitis. *Br J Ophthalmol*. 1970;54(3):211.
144. Mukherjee B, Priyadarshini O. An unusual case of orbital cellulitis. *Eye (Lond)*. 2013;27(5):678-9.

27. Thyroid Orbitopathy

Pérez Moreiras, Maria Varela, Consuelo Prada, M Tomé, João Cabral

Concept

Thyroid orbitopathy (TO) is known as the ocular involvement of Graves' disease (GD), with Saint-Yves in 1773 and Parry in 1786 being the first to describe the association between toxic goiter and ophthalmopathy. Graves published 3 cases in 1835 referencing this pathology and later, in 1840, Basedow emphasized the relationship between exophthalmos and thyroid disease. The Anglo-Saxons called it Graves' disease, the French used the term dysthyroid orbitopathy and in other countries it was known as Basedow's disease. Generally, it is associated with states of thyrotoxicosis but it has also been linked to other thyroid dysfunctions such as Hashimoto's thyroiditis, immune secreting carcinomas and even occurs in euthyroid states, hence its being referred to as dysthyroid orbitopathy.

It is an enigmatic autoimmune disease of unknown etiology that involves both the thyroid and the orbit (including muscles and orbital fat), needing complex medical treatment in its inflammatory state and surgical treatment in non-inflammatory conditions. It accounts for 50-75% of the consultations in an orbital surgeon's office (the higher the incidence the more developed the country). It tends to occur in women aged 25-50 and in men between 30 and 60, with a ratio of 8-2 in favor of females. It has a frequency of 1 female/year for every 2,000 women and 1 male/year for every 10,000 men. 85% of TO occur in hyperthyroid states, 8% in hypo- and 7% in normo- or euthyroid states. In the last 30 years we have studied 2 720 cases from a total of 4 200 orbits. In the last 10 years we have found that the incidence of TO is 7/10 patients with orbit disease.

Epidemiology and pathogenesis

Autoimmune thyroid disease (ATD) has a genetic basis influenced by environmental factors. It comprises a set of closely connected diseases:

1. Graves' disease: goiter, hyperthyroidism and thyroid associated orbitopathy;
2. Hashimoto thyroiditis and euthyroid goiter or hypothyroidism;
3. destructive thyroiditis or myxedema.

These three components of ATD share the same genetic predisposition, immunologic mechanism, pathological characteristics and familial cluster, with the same patient transitioning between different clinical pictures over time.

Phenotypic manifestations differ only in the immune responses involved, depending on the action of T lymphocytes. Activation of the inflammatory cascade occurs via auto-reactive T lymphocytes that recognize thyroid antigens. These activated T lymphocytes synthesize lymphocytes with different actions: if they are thyroid gland stimulating antibodies (helper function), Graves' disease arises; when the antibodies produced are blockers, or if a destructive process (killer function) occurs, the result is Hashimoto's thyroiditis or primary myxedema.

Common features of ATD include immune activity against thyroid specific antigens, mainly TSH receptor (TSHR), thyroid peroxidase (TPO) and thyroglobulin (TG).

Table 1: Antibodies prevalence in ATD (%)

Group	TRAb	TGAb	TPOAb
General population	0	5-20	8-27
Graves' disease	80-95	50-70	50-80
(Hashimoto)	10-20	80-90	90-100
Relatives of patients with autoimmune thyroiditis	0	30-50	30-50

TRAb: TSH Receptor antibody

TGAb: Thyroglobulin antibody

TPOAb: Thyroid Peroxidase Antibody

These antibodies, along with the hormonal status (T3, T4 and TSH), let us know which type of autoimmune thyroid disease we're dealing with.

Of all the clinical forms of ATD, the one with the highest prevalence of thyroid orbitopathy is GD.

GD has a bimodal peak incidence in both men and women, with the average age slightly higher in men. Ocular involvement in the context of EG tends to be more severe and have a worse prognosis in elderly patients, men and diabetics. TO is bilateral in about

90% of cases, yet asymmetrically so. The possibility of reactivation is rare (occurring in only 5% of patients), but must be kept in mind.

As mentioned above, the thyroid gland and the orbit are related, and both have TSH receptors. TSH receptors of the thyroid are stimulated by TRAb, increasing the synthesis of thyroid hormones, which in turn stimulate the activation of orbital fibroblasts. Fibroblasts are part of the connective support tissue of the orbit, made of both fat and orbital muscles. In the case of muscles, the connective tissue is condensed around the perimysium and emit septa into the muscle fibers, resulting in the endomysium. This is the reason we find fibroblasts within the muscle and fat, although it is not an actual pathology of muscle or normal adipocytes. Anti-TSH receptor antibodies are present in almost 100% of cases. Elevated expression of TSH receptor transcription levels has been observed in normal tissue samples from OT cases compared to control groups. It has been found in vitro, that the expression of TSH receptor proteins parallels the differentiation of fibroblasts into pre-adipocytes and IL-6.

Fibroblast activation involves the release of cytokines, which cause T cells to be attracted onto the orbit, releasing more inflammatory mediators and creating a vicious circle with Interleukin-6 attracting B lymphocytes and sustaining inflammation.

In TO, the volume of the extraocular muscles and the retroocular connective and adipose tissue increases. This happens before the inflammatory cascade involving CD4+ lymphocytes/macrophage/ B lymphocytes is initiated, and the secondary deposition of hydrophilic glycosaminoglycans (GAG) occurs, particularly chondroitin sulfate and hyaluronic acid. These compounds have high molecular weight and high osmotic power and thus generate a prominent edema that impedes blood circulation, which, together with an inflammatory state, generates an ischemic environment. Fibroblasts in low oxygen conditions or in the presence of insulin-like growth factor 1 (IGF-1), which is also present in the inflammatory cascade, increase the synthesis of collagen and hyaluronic acid, thus aggravating the situation. It has been suggested that the negative influence of smoking on TO is due, among other things, to the lower blood oxygen level produced. Orbital fibroblasts, unlike other types, appear to originate from the neural crest and possess a high degree of phenotypic plasticity. A feature of orbital fibroblasts is the possible differentiation into adipocytes and this adipogenesis generates an increased orbital content. An inflammatory hypertrophy of the fat (reversible) and a true fat hyperplasia (irreversible) occur. The formation of new fat in the adipose and connective tissues of the orbit is shown by an increase of the mRNA of adipocyte related genes, including

angiogenic inducers, followed by an increase of PPRA gamma, preadipocyte factor 1, adiponectin, leptin and stearoyl - CoA desaturase. In vitro, ordinary fibroblasts differentiate into mature adipocytes when treated with rosiglitazone (a PPRA gamma agonist). This must be taken into account when it comes to treating GD in type II diabetics because it can increase TO protrusion. If inflammation is not treated promptly it becomes chronic, allowing fibroblasts to proliferate and synthesize collagen and fibrosis components in inflamed tissues, which will certainly hinder treatment. Intense inflammation, swelling and adipogenesis lead to increased orbital muscle and fat tissue. These, together with the development of fibrosis represent the 4 mechanisms producing all the signs and symptoms known in the clinical presentation of TO (Fig. 1).

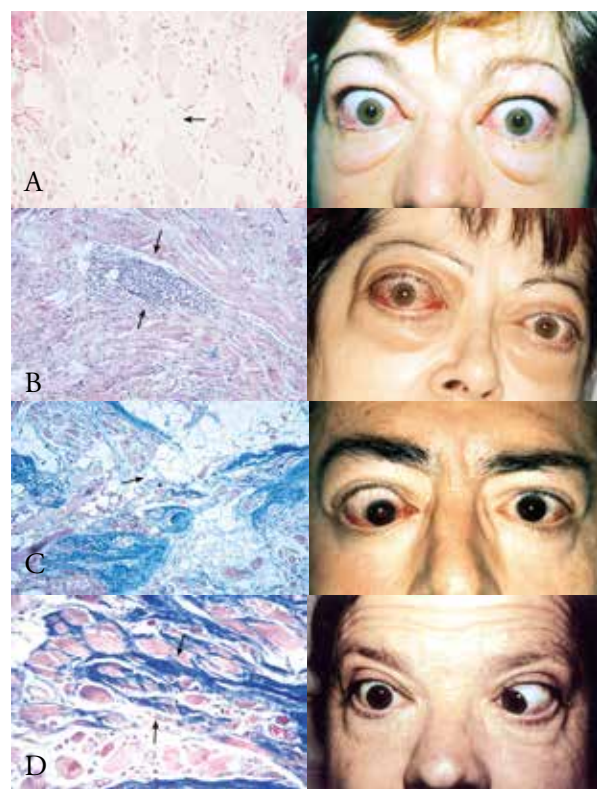


Fig. 1 A. Edema of the muscle fibers and lymphoplasmacytic infiltration (HE). B. Inflammatory infiltrate between the muscle fibers and lymphoplasmacytic. C. Inflammatory infiltrate between muscle fibers and fat and diffuse fibrosis. D. Endomysial fibrosis between the muscle fibers (Masson trichrome) growth in the center (HE) (Masson trichrome).

This pathogenic hypothesis is influenced by other risk factors such as:

- Genetics: As in other autoimmune diseases, there is some association with certain HLA haplotypes. 30% of cases have a positive family history.
- Smoking: There is a positive correlation between the incidence and gravity of TO and exposure to smoke. We can consider this the main risk factor

and it is very important for the physician to emphasize the importance of stopping smoking.

- Sex: TO is more common in women, although cases in men are usually more serious. Age of onset in women is between 25 and 60, while for men it is between 30 and 65.
- Previous treatments: Patients treated with radioactive iodine in the active inflammatory phase are more prone to developing or worsening TO (70%) within 1 year. For those treated in a non-active phase, the percentage of patients worsening increases by only 5%.
- AntiTSH-R auto-antibodies: high titers correlate with more severe cases.

Clinical Examination: Symptoms and Signs

The patient's clinical status reflects the pathophysiology of the disease. A sound knowledge of it can enable an early diagnosis, which would lead to a better response to medical treatment, ultimately avoiding surgery in many of our patients.

Once we have taken a thorough medical history, including hyper-hypothyroidism symptoms and signs, we should request TSH, FT3 FT4, thyroid antibodies and TRAB antibodies.

We should conduct a TO-centered eye examination:

- Eyelids. We find upper and lower eyelid retraction, edema and appearance of lower eyelid bags.
- Evaluation of ocular motility looking for possible restrictions (upper and inner movement of 30-40°, side and bottom of 40-45°). We look for strabismus and diplopia in primary or extreme gaze position and compensatory torticollis.
- Measuring exophthalmos with an exophthalmometer.
- Exploration of the anterior segment. Particular attention must be given to the existence of chemosis in the temporal corner, or inflammation of the lunate fold, a common finding in patients with signs of inflammation.
- Measurement of intra-ocular pressure. Performing the Braley test. (See below)
- Distance and near visual acuity
- Visual field testing, especially if we suspect compressive neuropathy. In some cases sectoral changes are present that are not perceived by the patient.
- Retinal fundus exploration. In the presence of compressive optic neuropathy the papilla will have normal coloration, with or without edema (the absence of pallor is a characteristic sign).
- A and B mode ultrasound of muscle and fat.
- CT scan - usually without contrast – and, needed less often, orbit MRI.

Below we describe the typical signs of the disease:

1. Eyelid Retraction (Dalrymple sign): (Fig. 2) this can be considered the cardinal sign. The upper lid is most often affected. The area above the limbus that is normally hidden by the eyelid, about 1 mm depth, is exposed. The mechanism is mixed: on the one hand there is sympathetic hypertonia of the Müller muscle and on the other there is fibrosis and adhesions of the lid retractors, as well as over-action of the elevator-superior rectus complex secondary to fibrosis of the inferior rectus. When upper eyelid retraction appears in downward gaze it is known as von Graefe's sign. There may also be a retraction of the upper eyelid when looking up, known as Griffith's sign. In severe cases of proptosis, ptosis may occur due to a detachment of the levator aponeurosis. Lower eyelid retraction is also common, with the lid typically positioned inferiorly to the limbus (Fig. 3).

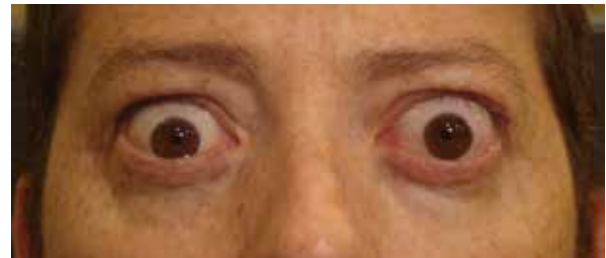

Fig. 2 Superior eyelid retraction in mild thyroid orbitopathy.

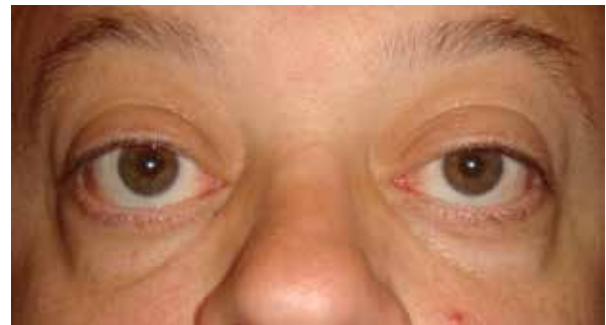

Fig. 3 Inferior eyelid retraction (3 mm) with scleral show in an inactive thyroid orbitopathy with 3 years of evolution.

2. Proptosis or exophthalmos: (Fig. 4-A and B) It is the best known sign of thyroid ophthalmopathy. It is caused by a conflict of space in the orbit due to increased muscle size, increased fat volume and lacrimal gland infiltration by lymphocytes, plasma cells and mucopolysaccharides, (Fig. 5-A and B) and it appears in 50% of cases. It is defined as an exophthalmometry greater than 21 mm and with a difference between each eye greater than 2 mm. We use the Hertel exophthalmometer for measurement. The retropulsion maneuver involves pressuring on the eyeballs. If we notice significant resistance there is muscle thickening of varying intensity. If exophthalmos is due to increased fat, the pressure moves the fat more easily, achieving better retropulsion. Globe subluxation caused by infiltrative orbitopathy has been described, called the Payne-Trousseau sign.

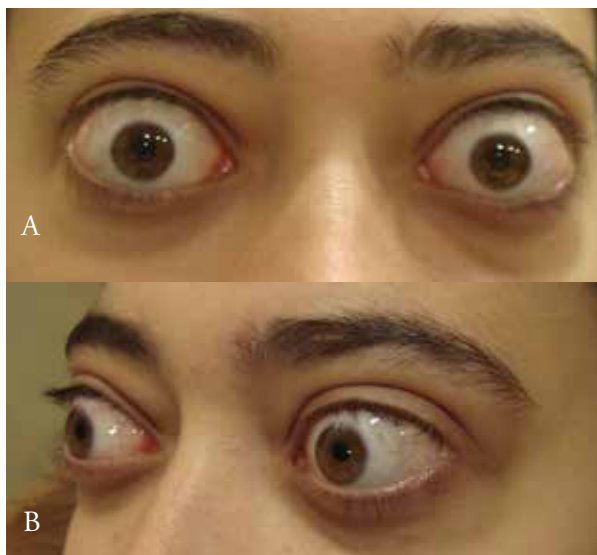

Fig. 4 A and B: Active orbitopathy with 29 mm of exophthalmos and globe subluxation.

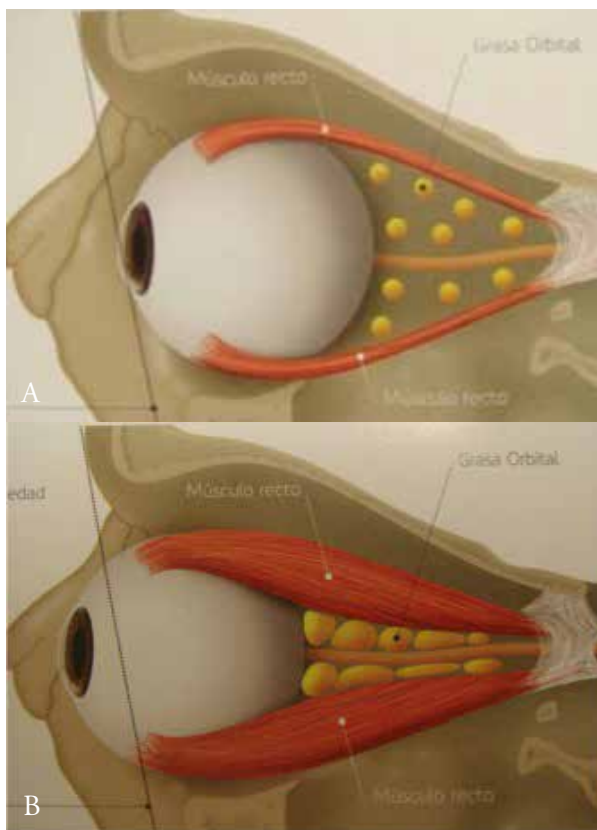


Fig. 5 A: Thyroid Orbitopathy with exophthalmos by increased fat and normal muscles. B: Thyroid Orbitopathy with exophthalmos, muscle thickening and enlargement of the orbital fat.

3. Diplopia-strabismus: the diplopia initially reported by some patients is mostly blurred or defocused vision. Over time, the lymphoplasmocytic infiltration and edema of the subacute phase result in fibroblast predominance and diplopia is established. Compensatory torticollis may appear (Fig. 6). It is more common in the morning because the muscles are more edematous, but it may persist throughout the day or appear in extreme positions of gaze. There may be pain

with eye movements when the restriction increases and limits eye movements (Fig. 7-A and B); extraocular palsy secondary to restrictive eye disease is called Ballet's sign. The muscles most often affected are the inferior rectus and medial rectus. Muscle thickening can hinder uveo-scleral outflow in some gaze positions, causing ocular hypertension and aggravating optic neuropathy. Positional tonometry – or Braley test - is considered positive if there is a difference in intraocular pressure of 4 mm or more, when measured in primary position of gaze and supraduction.

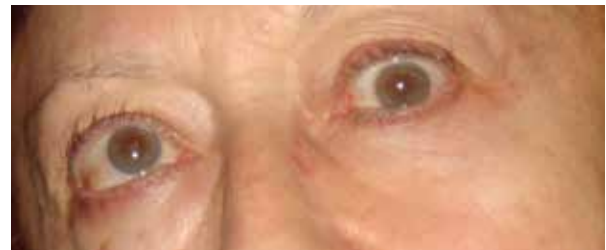

Fig. 6 Mild thyroid orbitopathy with vertical strabismus by restrictive fibrosis, in the inferior rectus muscle of the left eye. It adopts compensatory torticollis to avoid double vision.

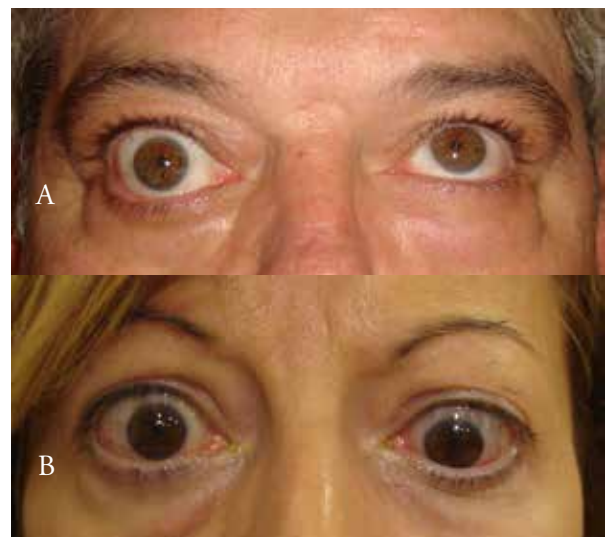

Fig. 7 A: Restrictive fibrosis in the inferior rectus muscle of the right eye that prevents elevation and generates marked diplopia in primary position. B: Restrictive fibrosis in the inferior rectus of the left eye, which generates a vertical strabismus of 15°.

4. Orbital fat: an increase of fat volume occurs in the orbital cavity. Fat gain entails early appearance of bags in the lower eyelids (Fig. 8) and in some cases exophthalmos, so that a fat decompression, and not a bony decompression, would be indicated in these patients. Palpebral edema (Fig. 9) is produced in part by an impairment of venous return and is known as the Vigouroux sign. Also, blinking may be reduced or be incomplete in these patients, called Stellwag's sign.

5. Cornea and conjunctiva: The exophthalmos and eyelid retraction can lead to exposure keratopathy of varying severity and in some cases to corneal perforation. The presence of chronic conjunctival

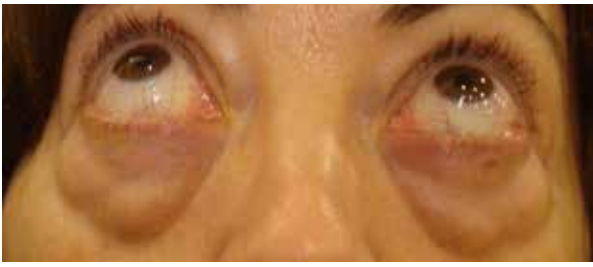

Fig. 8 Mild thyroid orbitopathy. Increase in fat volume, and edema in the lower and internal superior eyelids.

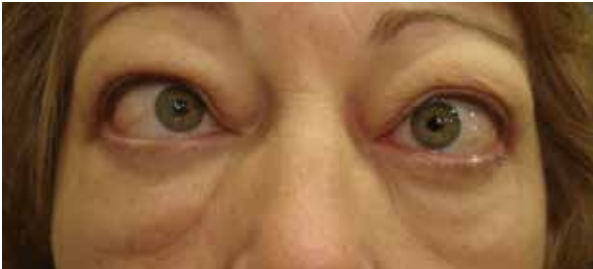

Fig. 9 Accentuated superior eyelid edema in active thyroid orbitopathy.

hyperemia and chemosis as well as swelling of the caruncula or lunette fold is a striking feature (Fig. 10). Patients usually complain of itching, lacrimation, photophobia and foreign body sensation that is worse in the morning and can improve throughout the day. Graves ophthalmopathy is associated with Theodore's limbic keratoconjunctivitis, although the association between the two entities remains unclear (Fig. 11).

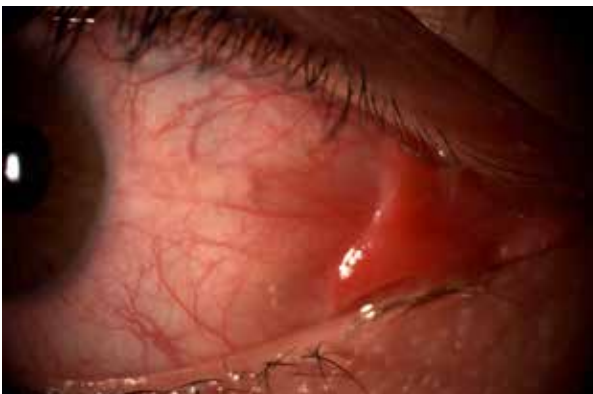

Fig. 10 Edema of the caruncula and lunette fold associated with conjunctival hyperemia.

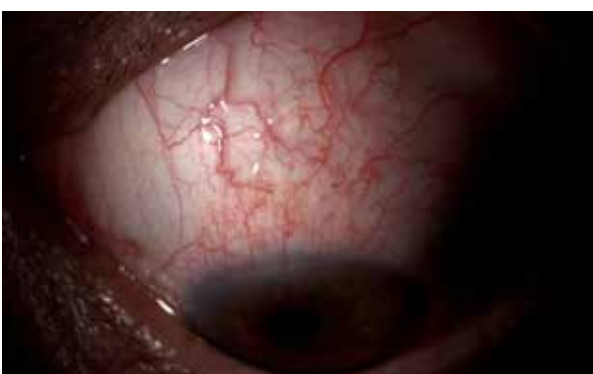

Fig. 11 Superior limbic keratitis and conjunctival hyperemia (Theodore's limbic keratoconjunctivitis).

6. Optic nerve: Compressive optic neuropathy appears in 5% of patients and is a serious complication that can cause loss of unilateral or bilateral vision down to light perception. It is reversible within several months of taking steroids to treat autoimmune inflammation or after decompressive surgery of the orbital apex. It is more common in men and the elderly (the optic disc is always normal or slightly edematous, but never pale, regardless of how impaired the vision is).

Classification: the concept of activity

TO is classified on a clinical basis, establishing two entities: an ACTIVE phase (inflammatory) (Fig. 12) and a NON-ACTIVE phase (Fig. 13). (with no inflammation). Grading the severity of the condition as light, moderate or severe depends on the clinical signs presented by the patient.

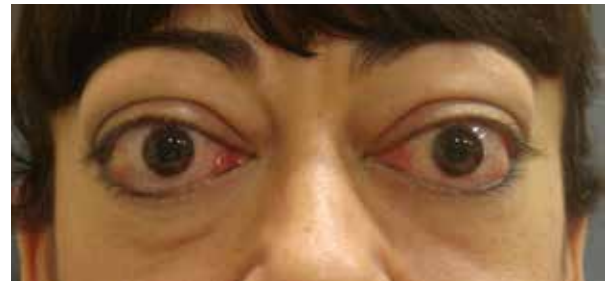

Fig. 12 Active Thyroid orbitopathy with 9/10 Mourits CAS score. Exophthalmos of 26 mm with conjunctival hyperemia, and caruncular and palpebral edema in both eyes.

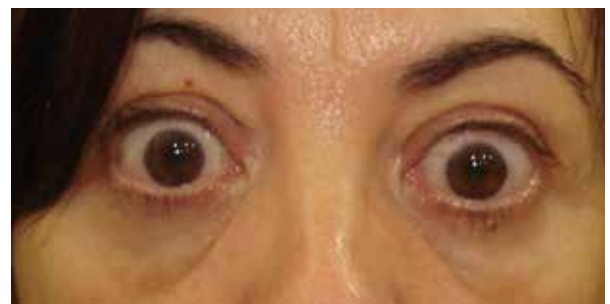

Fig. 13 Non-active thyroid orbitopathy after tocilizumab treatment.

Most patients begin with signs and symptoms of inflammation that can be more or less apparent. Even if they do not seem to present obvious inflammation, every sign must be analyzed and assessed to observe its evolution over time. Deterioration can occur in days or weeks and the whole progression should be recorded in the patient's clinical history.

• **Inactive phase,** symptoms or signs of inflammation may not appear in diagnosed TO for months or even years. It represents 45% of the TO in our center. Treatment is surgical rehabilitation except for those cases where the condition evolves rapidly and within weeks signs such as eyelid retraction, proptosis or diplopia appear. These patients are treated as active TO although they don't present the typical signs of inflammation.

• **Active Phase**, presenting with clinical signs of inflammation and activity such as: spontaneous pain or pain with ocular motility (eye pain, especially with upward or sideways movements); orbital pressure, hyperemia, chemosis (the patient reports watery eyes but no teardrop is observed to form); eyelid retraction that is accentuated when the patient speaks; eyelid edema; bags; progression of diplopia or exophthalmos that is worse in the morning and improves as the day goes by. The active or inflammatory phase represents 55% of the TO in appointments with an orbit and thyroid specialist. This active phase often extends through a period of six months to two years in 70% of cases. The rest can insidiously extend over 15 or 20 years.

The more endocrinologists and ophthalmologists are in touch with autoimmune thyroid disease, the higher the incidence of diagnosis in active phase. When we get to 80-85% we can say that we are a country with a heightened awareness of disease prevention and good health system. We tend to use the classification of Mourits (CAS: Clinical Activity Score), which is better than VISA Rootman and Dolman because it is simple and easy to perform, in just 2 minutes. Mourits classification is based on 10 clinical points to determine the degree of inflammation.

Whenever the Mourits score is greater than 3 or 4/10 points, steroid treatment and, to a lesser extent, other immune-modulation medications have priority in the days following the outbreak, in order to improve treatment response.

In the course of non-active TO, there is always an inflammatory phase or activity that may go unnoticed, or even subclinical forms that persist and have a slow and steady progression. We use Mourits CAS on each visit on all our patients with TO. Each symptom or sign equals one point. This helps grade the level of activity as well as measure the response to treatment in future appointments:

1. Pain or pressure behind the eyeball.
2. Pain or tightness in extreme positions of gaze in the last four weeks.
3. Eyelid redness.
4. Redness or conjunctival hyperemia of at least one quadrant.
5. Eyelid edema.
6. Conjunctival chemosis.
7. Caruncle or lunette fold edema.
8. Increase in exophthalmos of 2 mm or more in a period of 1 to 3 months.
9. Restriction in 5th or more eye movements in any version in a period of 1-3 months.
10. Decreased vision - one or more lines - in a period of 1 to 3 months.

Diagnosis:

Early diagnosis of TO is of vital importance if timely

medical treatment is to be initiated to halt the evolution of the disease.

History taking, emphasizing general and ophthalmological signs and symptoms, as well as the physical exam, searching for hallmarks of thyroid disease (hyperthyroidism/hypothyroidism/euthyroidism) will help guide both systemic and ocular diagnosis.

Laboratory tests, including thyroid hormones (T4 and TSH) and antithyroid antibodies (peroxidase, thyroglobulin), will help confirm the diagnosis and anti TSH-receptor antibodies (TSI or anti TSH-R) will tell us about the degree of inflammation or autoimmune inflammatory activity of the orbitopathy, although it is not uncommon for these markers to be somewhat high due to hyperthyroidism.

Based on clinical suspicion and with or without laboratory confirmation of thyroid or dysthyroid autoimmune disease, the ophthalmologist must refer the patient to the Department of Endocrinology. If ocular manifestations like exophthalmos, diplopia or edema are present the patient should be referred to a thyroid-orbit unit of. We should know which symptoms and signs these patients usually show early in the disease in order to make an early diagnosis and begin medical treatment in the active phase. Patients usually describe eyelid edema and pouches on waking up, which they associate with not having rested enough. Also common is blurred vision in the early hours of the morning and asthenopia that improves as the day progresses, allergic conjunctivitis with temporal-inferior chemosis or conjunctivitis near the superior limbus. Pain or restriction of eye movements in upper or lateral gaze is also reported. It is not uncommon for the patient to wake up one day with horizontal or vertical diplopia, that can make us suspect a stroke and take the patient to neurology when the problem is an ocular condition. Do not forget that in 23% of cases, TO appears prior to hyperthyroidism and in 30-35% of cases it appears simultaneously in daily practice, forcing us to think of TO even a few months before hyperthyroidism is diagnosed. The earlier the diagnosis, the more inflammatory activity is observed and the better the clinical response to medication will be.

Out of every 100 patients seen in our clinic, 62-65 are diagnosed in an early inflammatory phase. If on top of that we can diagnose them when exophthalmos is under 23 mm, we will be able to treat and cure over 85% of cases without the need for surgery.

In the diagnostic approach to thyroid orbitopathy, the ophthalmologist can make use of diagnostic imaging:

• **Ultrasound (B and A mode):** (Fig. 14) it is a low cost technique, routinely used in ophthalmology and which requires little experience. We can see thickening of the muscle belly, helping differentiate an incipient

inflammatory phase (with low and uniform reflectivity between muscle fibers) from a chronic fibrosis phase (high and heterogeneous reflectivity).

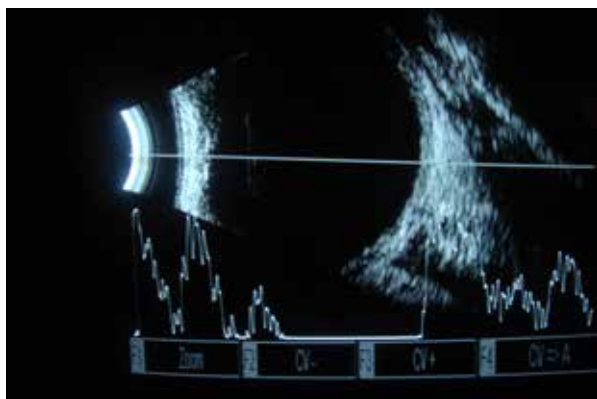


Fig. 14 Modes A and B of a transpalpebral ultrasound. Medial rectus muscle with marked thickening, with the low reflectivity and heterogeneity characteristic of active thyroid orbitopathy.

- **Computed tomography (CT)** (Fig. 15-A, B, C, D and E): Helps differentiate normal tissue from pathological structures. It is considered essential to scan with 3 mm cuts in a soft tissue program so we can see the muscles in axial and coronal cuts, the degree of exophthalmos, and the bony walls of the orbit and sinuses (no need to use iodinated contrast). The physician should request 3 mm cuts to be made following the plane of the infraorbital- external auditory meatus of Salvolini and Cabanis (the lens and optic-nerve canal will be in the central plane). We will be able to see thickening of the muscle belly inserted in normal sclera. The optic nerve can be elongated, with more than 23 to 24 mm of exophthalmos and bulging of the ethmoid wall with a longer time of evolution (coke bottle sign)

- **Magnetic Resonance or MRI:** It is much more expensive and offers little advantage over CT in thyroid orbitopathy. Some authors of the French school use it to determine the degree of muscle inflammation from edema appearing in the images, a fact that can be assessed clinically. On the plus side, it does not emit ionizing radiation.

The differential diagnosis in the early stages is made with other diseases that compromise the orbit:

- inflammatory: myositis (muscle belly and insertion are swelled), amyloidosis, etc.;
- tumor: primary tumors or metastasis (asymmetric or sectoral muscle thickening);
- vascular: vascular accidents occurring during the night can be confusing presenting with double vision in the morning, or high flow carotid-cavernous fistula presenting with myositis like muscles and ocular hypertension.

All of these diseases are usually unilateral, while TO tends to be bilateral (75%) but is often asymmetrical.

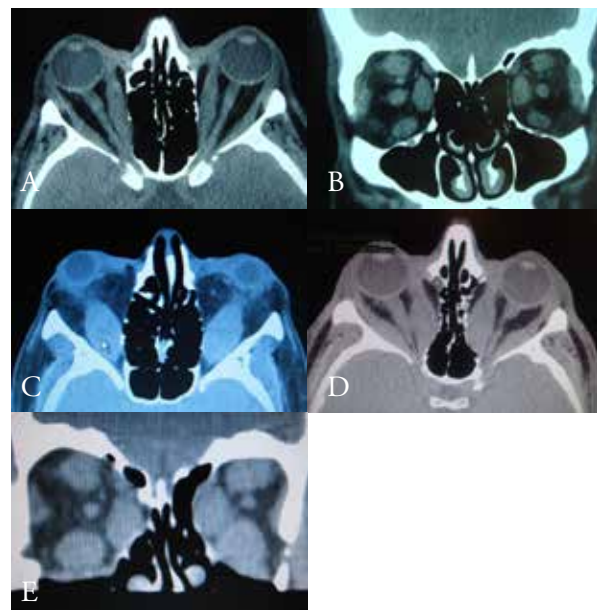


Fig. 15 A: Axial CT (Salvolini and Cabanis plane). Bilateral exophthalmos of 30 mm, thickening of both medial rectus muscles affecting the belly and also the insertion, which is rare in Graves orbitopathy. Good image of ethmoid bone for decompression. B: Orbital coronal CT. Marked thickening in the medial rectus muscles and elevator superior rectus complex. Less thickening in the inferior rectus muscles. C: Axial CT. Marked thickening of the inferior rectus muscles simulating a tumor on the floor of orbit. D: Axial CT after ethmoid decompression, with opening of the periosteum. The belly and back 1/3 of the muscle are displaced inside the ethmoid sinus. E: Decompression of ethmoid and floor of the orbit, including the channel of the infraorbital nerve.

Clinical course – prognosis

Approximately 80% of patients with Graves' disease will at some point suffer or develop subclinical TO disease that may go unnoticed. It may appear before EG (23%), both simultaneously (50%) or TO months after EG (25%)

In the initial stage of the orbitopathy, patients present with mild to moderate clinical signs that can be active and with little progression in some juvenile forms.

TO improves spontaneously in 80% of cases between 6 months and 2 years but there must always be ophthalmological supervision with analytical control. In the beginning there is usually swelling and edema. Progression will depend on the inflammatory activity, to the extent that a case with little or no activity will go unnoticed or improve in a few months and one with more activity may worsen in days or weeks.

It is always possible to stop and stabilize the clinical status of the patient with medication, initially using steroids. It is essential to try to prevent progression to more severe and dangerous forms that may present with severe exophthalmos (greater than 24 mm), corneal ulcers due to exposure or compressive optic neuropathy.

Medical Treatment

Most patients with mild Graves' disease have minimal signs and symptoms of TO which tend to improve

with endocrine therapy, but we must not forget that 15-20% will evolve to severe clinical symptoms, preventable with early diagnosis and treatment. When treating we must evaluate several aspects:

- Hypo- and hyperthyroid clinical and subclinical states should be avoided as they have an adverse effect on the TO. The endocrinologist must normalize hyper-hypo with medication.
- Thyroidectomy and antithyroid drugs appear to have no negative impact.
- Treatment with radioactive iodine (IR) is associated with a 5% rise of active TO in five years in patients who had no activity. It also increases and exacerbates active TO in 65% of patients, especially in moderate and severe cases. It is necessary to arrange the proper time of treatment with the orbit specialist, without worsening the orbitopathy, either using steroids or other immune-modulators.

If control of TO is not achieved with endocrine treatment, medical treatment is initiated aimed at controlling ophthalmic symptoms depending on the degree of ocular involvement.

In early cases or juvenile forms, inflammation is minimal with mild eyelid retraction that responds to treatment with steroids unless they have TSI or elevated TRAb. Treatment is symptomatic and checked periodically to avoid the risk of worsening. Glasses are recommended to ameliorate photophobia and eye lubricants to reduce grittiness.

If the TO worsens over a CAS of 3-4/10 we are faced with an important active orbitopathy that should mark the beginning of a more aggressive medical treatment, including:

1. Glucocorticoids: several regimens have been described depending on the degree of orbitopathy. One involves administering 50-120 mg/prednisone/day. This continues for a week and if the treatment is effective it is gradually decreased over 4 weeks. It can be used in mild or inconspicuous cases (we prefer to use an oral methylprednisolone 250 mg regimen; the powder is dissolved in half a glass of orange juice because of the bad taste of the steroids). The current trend is to use megadoses of IV methylprednisolone. The best alternative is intravenous pulses of 500 mg/methylprednisolone/day on 3 consecutive or alternate days. Analytical control of hematology and biochemistry and assessment of blood glucose and blood pressure is performed. When the response is favorable, we continue with a pulse of 500 mg/week for 6 weeks, either intravenous or oral methylprednisolone, again dissolving the powder in half a glass of orange juice. Absorption is very good orally but we always use gastric protectors and even

an osmotic diuretic each day the patient receives the pulse so as to prevent fluid retention. Intravenous pulses can be repeated whenever recurrences occur, if the response was favorable from the beginning, administering up to 9 grams of methylprednisolone (6 megadoses). In patients with less than 4/10 CAS we can use 250 mg methylprednisolone IV or orally. The response is positive in 75-80% of cases with activity in the first four months of evolution and negative in the other 20-25%, for no known medical reason. After 6 months progression of active TO, the response rate with steroid megadoses comes down to 40-50%. Intravenous treatment prior to orbital decompression is also used to eliminate marks of inflammation induced by surgical stress. If there is no positive response after a megadose of steroids on 3 consecutive or alternate days we must discard this treatment. It is likely there will be no response after weeks or months of use and we will only be triggering Cushing's syndrome and decalcification problems. (Fig. 16-A and B)

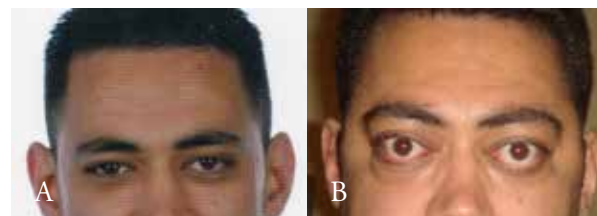

Fig. 16 A: Thyroid orbitopathy with incipient signs of active thyroid orbitopathy. Asymmetry in palpebral aperture. Patient has been treated for 8 months with 60 mg of prednisone with poor response. B: The same patient with Cushing syndrome produced by prolonged steroid treatment. The clinical course has worsened with exophthalmos of 28 mm, palpebral edema and marked lower eyelid retraction.

2. Cyclosporine 300 mg/day three months with only 10% success in patients unresponsive to corticosteroids. It is better tolerated than corticosteroids and has fewer contraindications. Association with corticosteroids is indicated in cases of poor response to oral corticosteroid treatment, outbreaks and in diabetic patients.

3. Radiation dose of 20 Gy, we have ruled out this option in the past five years due to the controversy around it.

4. Other ineffective treatments are antioxidants (selenium), somatostatin analogues, azathioprine, octreotide, infliximab, etanercept, and even rituximab with a favorable response in only 15% of patients.

5. Tocilizumab (Fig 17 A and B.) The monoclonal antibody inhibits interleukin 6 (IL-6). It is in phase III clinical trials with very good response in 32 patients treated in a double blinded trial in 2013 and 2014. We have been using it for five years now in more than 100 patients that were refractory to steroids, with very good response in over 97% of the

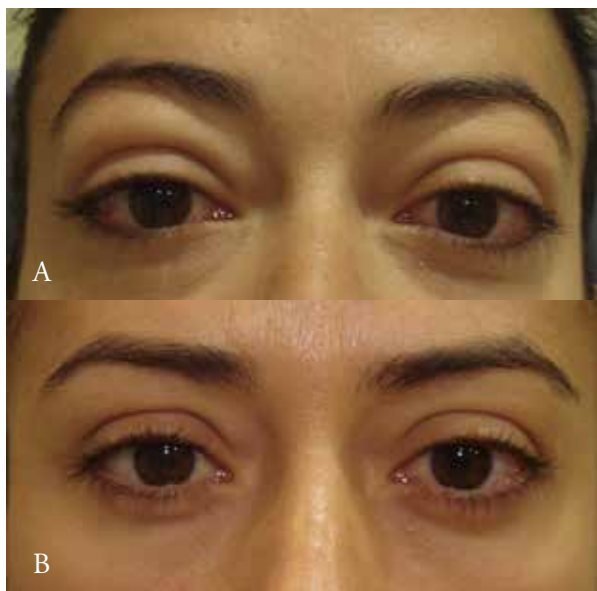

Fig. 17 A: Thyroid Orbitopathy active with a 6/10 CAS of Mourits. Upper and lower eyelid edema, hyperemia and chemosis. Poor response to megadoses of steroids. B: Tocilizumab therapy (8mgr/Kg) for 4 months. 5 mm reduction in the exophthalmos and disappearance of the signs of inflammation. No need for surgical rehabilitation.

100 cases. Our experience with this drug has shown its high efficacy and good tolerability. You need to request hepatitis screening, serology and analytical control, and tuberculosis tests before recommending treatment. Treatment is administered intravenously at a dose of 8 mg/kg. The protocol that we are using is a monthly regimen for 4 consecutive months, always performing hematological and biochemical control before each new treatment. CAS is lowered from an average value of 7 pre-treatment to zero and 50% of our patients saw TSI values return to normal. We found that patients with normal TSI levels after treatment are eleven times less likely to relapse and, according to our data, after the ninth month of inactivation 86.1% of patients had no recurrence, and at twenty-six months after treatment the remission rate remained constant at 82.2% until the end of monitoring. Because of these results we must acknowledge that, even if clinical inactivation is achieved, we should seek the normalization of TSI levels by continuing treatment for a longer period of time, since we are seeing improved outcomes in these patients. The relapse rate observed was 14.1%, generally occurring within 9 months of the last doses of tocilizumab, and all cases were responsive to a new course of treatment. With tocilizumab therapy we are achieving a 70% reduction of decompressions, 80% decrease of upper and 11.1% lower eyelid retraction surgery, and 85% of surgery to correct strabismus. The average reduction in exophthalmos is 3.2 mm (it has sometimes reached 7 mm). The results of our research will be published shortly in more detail. We

are sure that it will come to be the most widely used therapy in the future, once it has been possible to lower the price. Once the clinical and autoimmune inflammation have been treated, as in the majority of patients treated with IL-6 inhibitors, we allow 2-3 months to pass before proposing any rehabilitative surgery that may be necessary.

Surgical treatment

It is used as a rehabilitation treatment, generally in non-active OT or in active cases with poor response to the treatments listed above. With tocilizumab we have achieved inactivity in virtually 100% of cases (we changed our protocol for surgery in 2012, we now never operate with signs of activity and treat first with this IL-6 inhibitor) (Fig. 18 A and B).

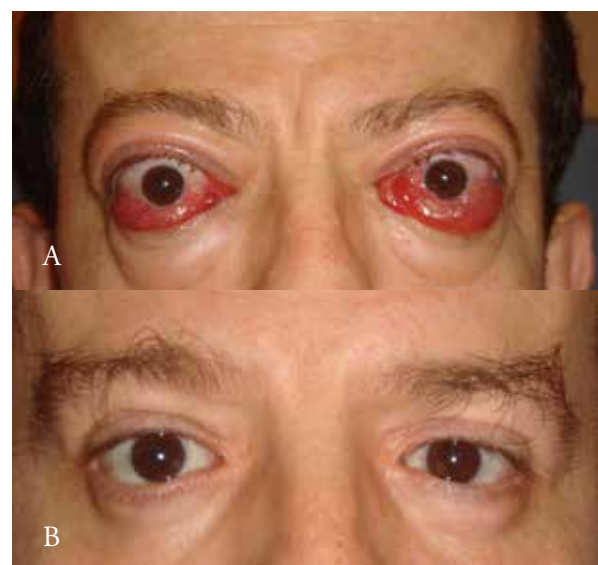

Fig. 18 A: Very active thyroid orbitopathy with 10/10 Mourits CAS score, refractory to steroid therapy in diabetic insulin-dependent patient. Exophthalmos of 26 mm with compressive neuropathy. Upper and lower eyelid edema and chemosis. B: After tocilizumab therapy and orbital decompression of both eyes. Sequel is a restrictive fibrosis in the medial and inferior rectus muscles.

It is important to get to know each of the surgical techniques, and perform them in stages according to the patient's needs. If all surgeries are necessary, the first is decompression, followed by strabismus and eyelid surgery last:

- **Orbital decompression:** Effective in correcting exophthalmia and improving the edema produced by venous congestion as it achieves expansion and enlargement of the orbital cavity to accommodate the enlarged tissues. It is performed during an idle stage of the disease, although sometimes it can be performed as an emergency treatment in the presence of severe keratopathy or compressive optic neuropathy. In each patient it is important to study the axial and coronal CT cuts in soft tissue program with 3 mm cuts in the neuro-ocular plane described

by Salvolini-Cabanis (lens, optic nerve and optic canal appear in the same plane), which in Caucasians is almost always parallel to the infraorbital- external auditory meatus line.

- Ethmoid decompression: the ethmoid is decompressed via the caruncle or through the internal upper eyelid crease (Perez Moreiras technique described in 1996, which have performed on over 800 orbits) (Fig. 19). We conduct orbital microsurgery through a 10 mm incision using 4x or 6x magnification in the microscope. We can enter the orbital fat compartment through an internal upper eyelid crease access and perform a lipectomy using a Colorado needle at 15 watts power. We can continue with lipectomy of the eyelid fat, whose color is more yellow than the former. Searching for the attachment of the orbital septum to the periosteum of the medial wall, we try to separate the orbital content in order to protect the periorbit and detach the periosteum from the ethmoid. Dissection continues deep into the lesser wing of the sphenoid and the optic canal, which demarcates our limits posteriorly, while we detach the periosteum behind the lacrimal crest and, in some cases, all the way to the infraorbital nerve canal. Once the ethmoidal area and the medial third of the orbital floor are exposed we fracture the wall and perform the osteotomy, removing the ethmoidal anterior and posterior cells. We can decompress all the ethmoid until we reach the lesser wing of the sphenoid. Posteriorly we fracture and remove the inferior third, the strut or bony bridge between the medial wall and the floor. The whole ethmoid is decompressed without opening the periosteum, thus preventing the onset of horizontal diplopia caused by a restrictive strabismus that can appear when we move the medial rectus into the ethmoid on muscles that have moderate to severe enlargement. The risk of diplopia is minimal if we open the periosteum with normal muscles when attempting to gain an extra 1 mm of decompression. It is a technique that leaves no aesthetical sequela because the incision is made in the supero-internal crease and that reduces proptosis by 2 or 3 mm. If we enlarge the decompression until the strut and infero-posterior floor, we can reduce proptosis by 4 mm but we have to be careful not to damage the periosteum because it can lead to convergent strabismus and diplopia.
- Inferior wall decompression: Decompression can also be achieved via the inferior bony wall or orbital floor through a conjunctival opening and a lateral 5 mm canthotomy. If we decompress the

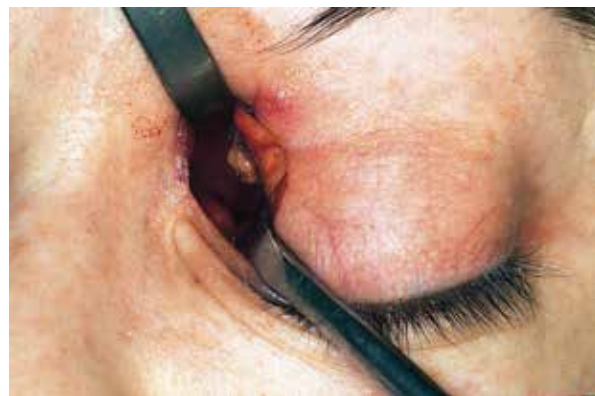

Fig. 19 Ethmoid wall decompression. Transpalpebral approach through the superior eyelid crease to decompress the ethmoid (Perez Moreiras technique 1996).

infra-orbital nerve canal and open the periosteum we can achieve 3 mm or more and the eye globe will descend slightly, which can be beneficial when an inferior eyelid retraction of 2-3 mm is present. We must remember that, by decompressing the bony canal, we will cause anesthesia of the region of the nose, upper lip and incisive teeth for 2-3 months. By decompressing part or all of the orbital floor we can perform an osteotomy or drill in the infero-lateral bone area corresponding to the malar bone outside the speno-maxillary joint, and we would gain an extra 2-3 mm of decompression, thus reaching 7-10 mm, depending on the bone structure of the patient.

- Lateral wall decompression: We can also decompress the lateral bony wall, although that technique was mostly used in the past. Currently we usually perform the techniques described above to correct exophthalmos. With this surgery we would decompress the lateral bony wall, including the greater wing of the sphenoid, which would allow 3-4 mm of decompression. All of the orbital floor up to the infraorbital nerve canal is accessible.

In 2% of patients that underwent decompression active TO is reactivated after surgery, so close monitoring of CAS grading and TSI levels is recommended. Whenever we begin decompression of the ethmoid we ask the anesthetist to administer 500 mg of IV methylprednisolone to avoid the risk ischemic optic neuropathy in patients under 40 years of age (just over 15 years ago we had 3 cases of vision loss and ever since we started administering megadoses we had no more cases).

- **Lipectomy** (fatty decompression of the orbit): (Fig. 20) We perform a peripheral lipectomy in the inferior and superior-internal compartments of 4-6 cm³ that will reduce proptosis by 2-4 mm, depending on the amount of fat seen on CT. We

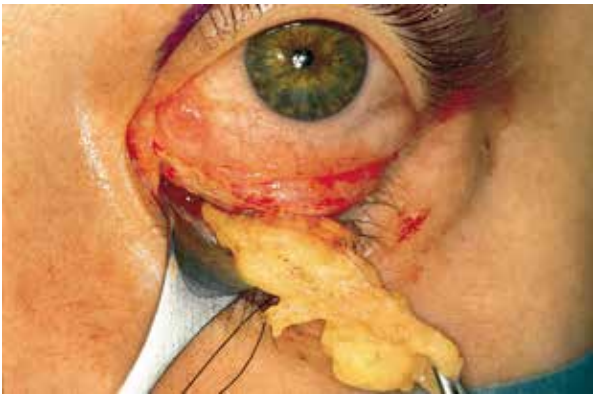

Fig. 20 Lipectomy through a transconjunctival approach to excise palpebral and orbital fat.

should avoid the intraconal fat, trying not to harm the ciliary vascular bundles. We can always try a mixed surgical technique of bony decompression and lipectomy of the inferior and superior-internal quadrants, through which we can resect 4–6 cm³ of fat without harming the muscles.

- **Strabismus:** It is the commonest complication or sequela. Muscular impairment can produce vertical or horizontal diplopia, or both. We still don't know why some patients develop muscular restriction within a few days while in others it seems to take years to evolve. In initial stages, the diplopia can be compensated by the patient's posture or by using prisms. When it appears in an active phase, it can improve in up to 75% of cases with biological therapy using tocilizumab in angles under 10°, whether in primary position or in extreme versions, which does not occur with corticosteroids. Surgery should always be performed in an inert phase. We always choose a debilitating surgery (retro-insertion) because of the fibrosis and restriction of the muscles. We can associate vertical muscle surgery with decompression but not horizontal muscle surgery, because it can change the degree of the strabismus after surgery. Retro-insertions under 4 mm are ineffective and in some cases we go as far as 10 mm and even perform free tenotomy when improvement is only achieved through retro-insertion.
- **Eyelid Retraction:** We perform this in patients with eyelid retraction that present a scleral show larger than 0-1 mm. It must always be performed in an inactive phase, to avoid the risk of recurrence. It should be performed last, after orbital decompression and strabismus surgery. The most widespread technique is the Mullerectomy using a conjunctival approach (achieving a 1-3 mm descent of the superior eyelid) (Fig. 21), alone or combined with weakening of the eyelid elevator (achieving an eyelid descent of 2-7 mm), via conjunctival or external approach. The external third must always be left 1 mm lower so as not to create an Asiatic appearance (reaching all

the way to the lateral Withnall ligament between the lacrimal glands). Retraction of the inferior eyelid requires intervention when the eyelid is more than 1 mm from the corneal limbus. We perform a release of the retractor muscle and place a spacer, in our case sclera from the eye bank, to correct the position of the inferior eyelid (Fig. 22).

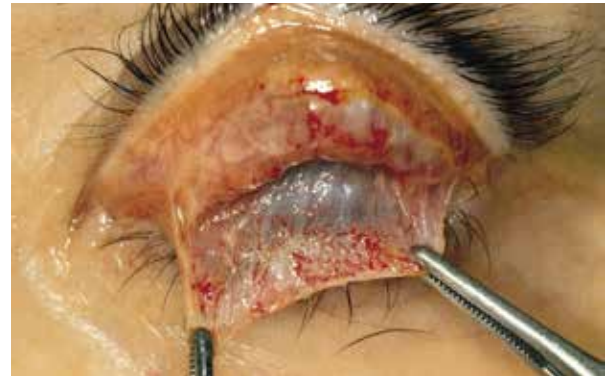

Fig. 21 Müllerectomy. Surgery to weaken the Müller muscle through a transconjunctival approach, disconnecting it at the lower edge of the upper tarsus.

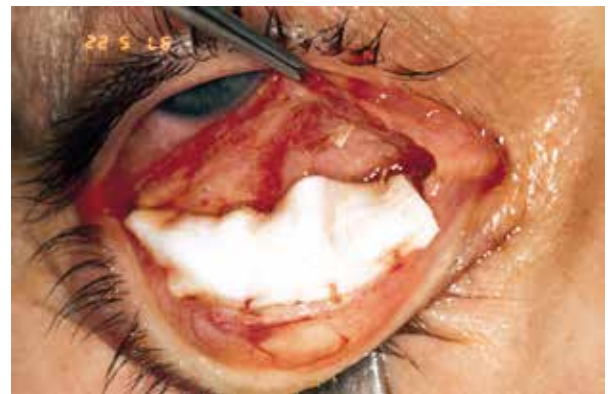

Fig. 22 Surgery for lower eyelid retraction. Incision in the lower edge of the tarsus with conjunctiva and retractor in a single plane. Scleral graft sutured to lower edge of tarsus and inferiorly to the conjunctiva and retractor.

- **Blepharoplasty:** Considered a rehabilitative surgery for patients who have undergone decompression or lipectomy to remove excess skin or fat (Fig. 23)

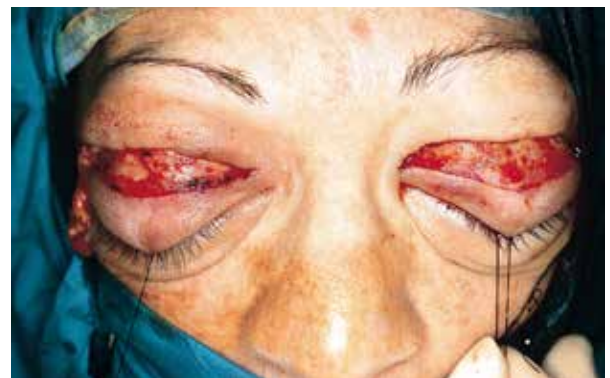

Fig. 23 Superior blepharoplasty and eyelid fat lipectomy in a patient with non-active thyroid orbitopathy.

Conclusions

In the past 30 years in COM we have seen more than 2 800 patients with TO and performed more than 3 000 decompression, restrictive strabismus or eyelid retraction surgeries. Our rate of complications is low, with some optic neuropathies in young patients up to the year 2000. We customarily administer 500 mg methylprednisolone IV before decompression surgery and have not had any neuropathies in the past 15 years. Incidence of ethmoidal cerebrospinal fluid fistula is under 1/200 and can be solved using cyanoacrylate or fibrin to seal the open zone. Our incidence of horizontal strabismus has also fallen to rates lower than 5% in thick muscles by preserving the ethmoidal periosteum.

Superior eyelid retraction is unchanged by the decompression surgery and is always dealt with after the latter, in our case using a conjunctival approach. Our experience over the years has taught us not to operate for eyelid retraction if activity is still present because the rate of recurrence and the need for further surgery is extremely high. We aim for under-correction on these patients because if retreatment is needed it will be simple, using a conjunctival approach, despite the fact that ptosis surgery following a Mullerectomy or weakening of the superior eyelid is more difficult.

In conclusion we can state that, with IL-6-like cytokine inhibitors, an incredible future is ahead concerning the treatment and prognosis of thyroid orbitopathy. If on top of that we can add early diagnosis of active orbitopathy in patients who are under 23-24 mm of exophthalmos we will be able to avoid surgery in over 85% of cases and rehabilitation time will be under 6 months. A prospect that was unthinkable, or even a dream, only 5 years ago.

Bibliography:

1. Adenis JP, Lasudry J, Robert PY. Orbithopathie dysthyroïdienne en pathologie orbito-palpebrale. Soc Française d'Ophthalmologie. Paris, Masson, 1998. 456-480.
2. Akamizu T, Amino N and DeGroot LJ. Hashimoto's Thyroiditis. In www.thyroidmanager.org, Updated 15 August 2008.
3. DeGroot LJ, Weetman AP. Autoimmunity of the Thyroid Gland. In www.thyroidmanager.org, Updated January 2010.
4. DeGroot LJ. Graves' Disease and the Manifestations of Thyrotoxicosis. In www.thyroidmanager.org, Revised 5 March 2008.
5. Jacobson EM, Tomer Y: The Genetic Basis of Thyroid Autoimmunity. *Thyroid* 2007, Vol. (17);10:949-961.
6. Khanna D, Chong KK, Affiyan NF, Hwang CJ, Lee DK, Garneau HC, et al. Rituximab treatment of patients with severe, corticosteroid-resistant thyroid-associated ophthalmopathy. *Ophthalmology*. 2010 Jan;117(1):133-139.
7. Lehmann GM, Feldon SE, Smith TJ, Phipps RP: Immune Mechanisms in Thyroid Eye Disease. *Thyroid* 2008, Vol. 18; (9):959-965.
8. Marcocci C, Bartalena L, Tanda ML, Manetti L, Dell'Un-

- to E, Rocchi R, et al. Comparison of the effectiveness and tolerability of intravenous or oral glucocorticoids associated with orbital radiotherapy in the management of severe Graves' ophthalmopathy: results of a prospective, single-blind, randomized study. *J Clin Endocrinol Metab* 2001 Aug;86(8):3562-7
9. Mourits M., Prummel M., Wiersinga W., Koornneef L. Clinical Activity Score as a guide in the management of patients with Graves ophthalmopathy. *Clinical endocrinology*, 1997;47,9-14.
10. Metello JL, Gonzalez M, Eusébio R, Rocha V. Oftalmopatía Asociada a Tiroide. *Acta Méd Port* 2004; Vol.17: 329-334.
11. Neves C, Alves M, Delgado JL, Medina JL: Enfermedad de Graves. *Archivos de Medicina*, 2008. Vol. 22, No. 4/5: 137-46.
12. Pérez Moreiras JV, Coloma Bockos JE, Prada Sánchez MC. Thyroid orbitopathy (pathogenesis, diagnosis and treatment). *Arch Soc Esp Ophthalmol*. 2003 Aug; 78(8):407-31.
13. Pérez Moreiras JV, Prada Sánchez MC., Coloma Bockos J, Prats Bartomeu J, Adenis JP, Rodríguez F, et al. Oftalmopatía distiroidea. En: Pérez Moreiras JV, Prada Sánchez MC. *Patología Orbitaria*, Tomo 2. Barcelona, Edika Med, S.L., 2002; 949-1033
14. Ponto KA, Pitz S, Mann WJ, Weber MM, Pfeiffer N, Kahaly GJ. Management of Graves' orbitopathy: evidence-based recommendations. *Dtsch Med Wochenschr*. 2009 Dec;134(49):2521-4.
15. Sánchez-Ortiga R, Moreno-Pérez O, González Sánchez V, Arias Mendoza N, Mauri Dot M, et al. Treatment of Graves' ophthalmopathy with high-dose intravenous methylprednisolone: a comparison of two dosing regimens. *Endocrinol Nutr*. 2009 Mar; 56(3):118-22.
16. Szucs-Farkas Z, Toth J, Kollar J, Galuska L, Burman KD, Boda J, et al. Volume changes in intra and extraorbital compartments in patients with Graves' ophthalmopathy: effect of smoking. *Thyroid* 2005 Feb;15(2):146-51.
17. Zhu W, Liu N, Zhao Y, Jia H, Cui B, Ning G. Association analysis of polymorphisms in IL-3, IL-4, IL-5, IL-9 and IL-13 with Graves' disease. *J Endocrinol Invest*. 2010 Mar; 22.
18. Smith TJ, Hegedüs L, Douglas RS. Role of insulin-like growth factor-1 (IGF-1) pathway in the pathogenesis of Graves' orbitopathy. *Best Pract Res Clin Endocrinol Metab*. 2012 Jun; 26(3): 291-302.
19. McLachlan SM, Rapoport B. Breaking tolerance to thyroid antigens: changing concepts in thyroid autoimmunity. *Endocr Rev*. 2014 Feb; 35(1): 59-105.
20. Wei H, Guan M, Qin Y, Xie C, Fu X, Gao F, Xue Y. Circulating levels of miR-146a and IL-17 are significantly correlated clinical activity of Graves' ophthalmopathy. *Endocr J*. 2014 Nov 28; 61 (11): 1087-92.
21. Raychaudhuri N, Fernando R, Smith TJ. Thyrotropin regulates IL-6 expression in CD34+ fibrocytes: clear delineation of its cAMP-independent actions. *PLoS One*. 2013 Sep 25; 8 (9) : e 75100.
22. Pérez-Moreiras JV, Alvarez-López, Gómez EC. Treatment of active corticosteroid-resistant graves' orbitopathy. *Ophthalm Plast Reconstr Surg*. 2014 Mar-Apr ;30 (2) : 162-7.

28. Adult Orbital tumors

João Cabral, Mara Ferreira

The great variety of tissues present in the orbit means that many different kinds of tumor can arise from them. This explains the wide variety of clinical presentations as well as treatments required, which include surgery, radiotherapy and chemotherapy.

Diagnosis of orbital tumors is based on clinical characteristics. Usually, they present with signs and symptoms suggesting the presence of a space-occupying lesion in the orbit, such as proptosis, globe displacement, chemosis, conjunctival injection, eye movement restriction, diplopia and visual impairment. The diagnostic approach is aided by imaging exams like ultrasound, computerized tomography (CT) scans, magnetic resonance imaging (MRI), which help to identify orbital lesions, characterize their circulation and describe their relationship to adjacent structures. In some cases, biopsy is needed to confirm the diagnosis (fine-needle aspiration, TC-guided biopsy, surgical biopsy...).

Orbital tumors may arise from any orbital structure (blood vessels, adipose tissue, nerve fibers, lacrimal gland, connective tissue or bone).

A useful classification for orbital tumors is the distinction between benign (more common) and malignant tumors. Benign tumors, although benign in histopathology, can compromise visual function and require early treatment because of their location and size. The most common benign orbital tumors are cavernous hemangioma, lacrimal gland tumors and schwannomas. Malignant tumors of the orbit are less frequent and can be primary or secondary to other adjacent tumors (intracranial, nasal sinuses) or to distant tumors (metastases). The most common primary orbital malignant tumor in adults is non-Hodgkin lymphoma. Other classification of orbital tumors is based on the their origin: cystic, vascular, lymphoproliferative, inflammatory, mesenchymal, neurogenic, from the lacrimal gland, secondary tumors and metastatic. This is the classification adopted in this chapter.

1) Cystic orbital tumors

Cysts are not tumors but can resemble them as they behave like a space-occupying lesion. A true cyst consists

of a cavity lined by a secretory epithelium. The majority of orbital cysts are benign. These lesions arise from development anomalies of the nasal sinuses or the skull.

Congenital cysts

The most frequent congenital cyst is the dermoid cyst (or epidermoid, if the wall of the cyst does not contain dermal tissues). They are the most frequent choristomas in children and result from epithelial structures becoming trapped in fetal bone sutures (most commonly in the frontozygomatic suture). The contents of the cyst may be adipose tissue, keratin and dermic structures such as hair follicles that can sometimes be seen through the cyst capsule. They can be superficial or deep, according to their position relative to the orbital septum. Although congenital, they might only become visible during the first year of life. When they are deep they may only become apparent in childhood or adult life (Fig. 1 and 2).

Dermoid cysts present as a cystic masses that are easily palpable if anteriorly located, and are often located over the superior external orbital rim (inducing the characteristic S shape of the superior lid). They do not usually present with inflammatory signs unless they rupture and cause a foreign body reaction to keratin. CT scans and MRI imaging reveal the location and dimension of cysts with well-defined walls and heterogeneous contents. Treatment is generally surgical and the whole of the capsule has to be removed (intact, if possible) as the smallest trace of secretory epithelium can give rise to a new cyst.

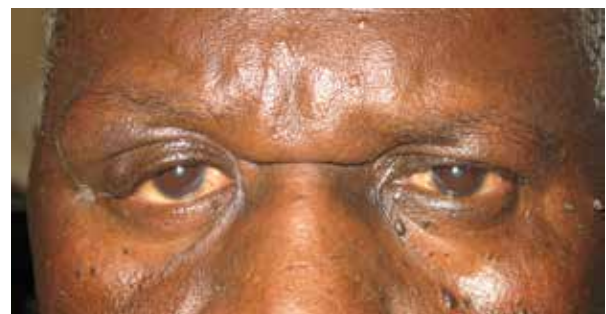

Fig. 1 – Dermoid cyst of the superior external quadrant of the right orbit in a 56-years-old male.

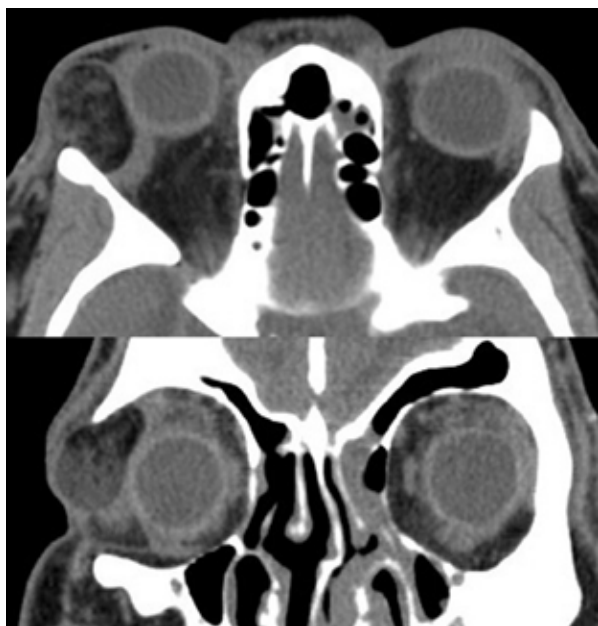

Fig. 2 – CT scan of the same dermoid cyst showing heterogenous contents and deformation of the lateral orbital wall.

Teratoma is another type of congenital cystic tumor of the orbit. By definition, it is composed of tissues from the three germ layers (ectoderm, mesoderm and endoderm). They can contain tissues like skin, intestine, lung, brain, thyroid, cartilage and bone. They are usually unilateral and more frequent in females. Like dermoid cysts, they grow due to secretion accumulation within them (Fig. 3 and 4).

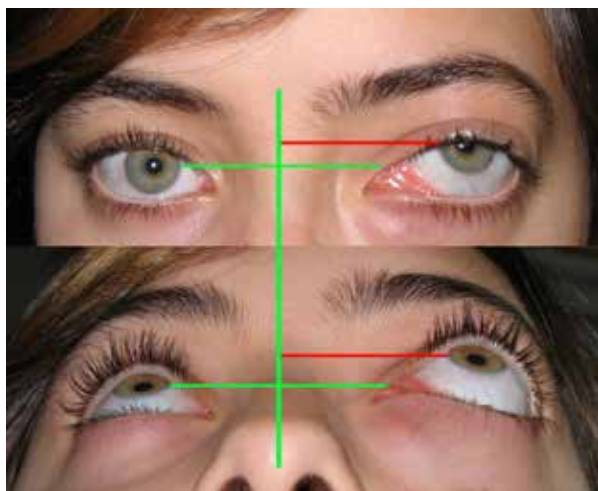


Fig. 3 – Left orbital teratoma with proptosis and supero-lateral displacement of the globe in a 14 year-old girl.

Acquired cysts

Acquired cysts can have many origins: “chocolate cysts” (when lymphangioma cysts are filled with hemoglobin breakdown products), other “hemorrhagic cysts”, lacrimal gland cysts (when there is an obstruction of the excretory canal), parasite cysts.... Sweat gland and conjunctival cysts can simulate an orbital origin when large enough. Cysts

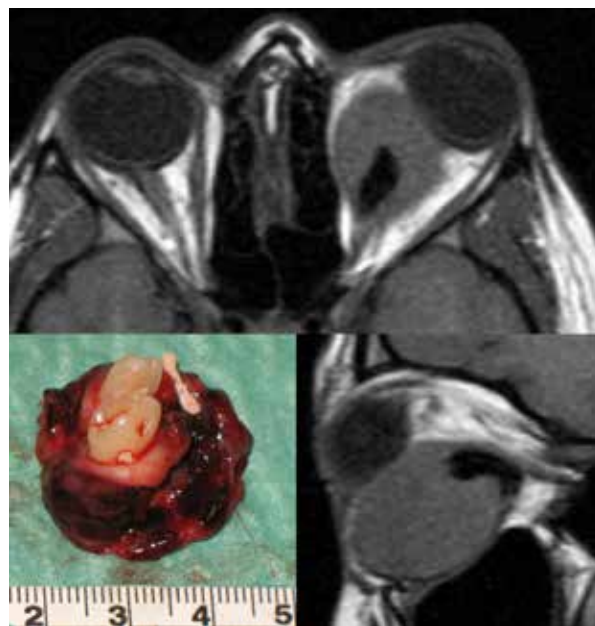


Fig. 4 – The same teratoma in MRI, with origin in the orbital apex anteriorly pushing and deforming the globe. Inside, teeth are visible.

can also arise from the expansion of mucocoeles from adjacent perinasal sinuses.

Orbital cyst treatment is surgical, which is done when the cyst is big enough. Excision must be complete, without rupturing the capsule to prevent local inflammation and possible recurrences.

2. Vascular orbital tumors

Vascular lesions are the commonest tumors in adults (cavernous hemangioma and hemangiopericytoma, varices and other arteriovenous conditions).

Cavernous Hemangioma

Cavernous hemangioma is the most frequent orbital vascular tumor in adults (70% of cases in female patients). Usually, it is a single tumor not associated with other systemic disease. The most usual location is the intraconal space between the rectus muscles and its presence is revealed by an axial proptosis, without pain or inflammatory signs. Since the tumor grows slowly, diplopia is not a common finding (the insidious growth rate allows the extraocular muscles to adapt) but hypermetropization, related to the anterior displacement of the posterior pole, and choroidal folds are frequent. It is a globous, well defined tumor with elastic consistency, formed by multiple spaces filled with blood (Fig. 5 and 6). While small, it is diagnosed by chance when imaging is required for some other reason. Surgical treatment is indicated when clinically justified.

Lymphangioma

Some authors regard lymphangioma as an orbital choristoma because the orbit does not contain the

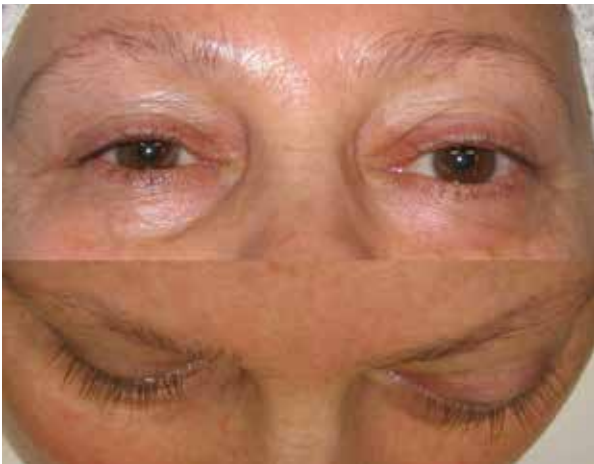

Fig. 5 – Large cavernous intraconal hemangioma of the left orbit, causing mild proptosis (no diplopia) in a 56-year-old woman.

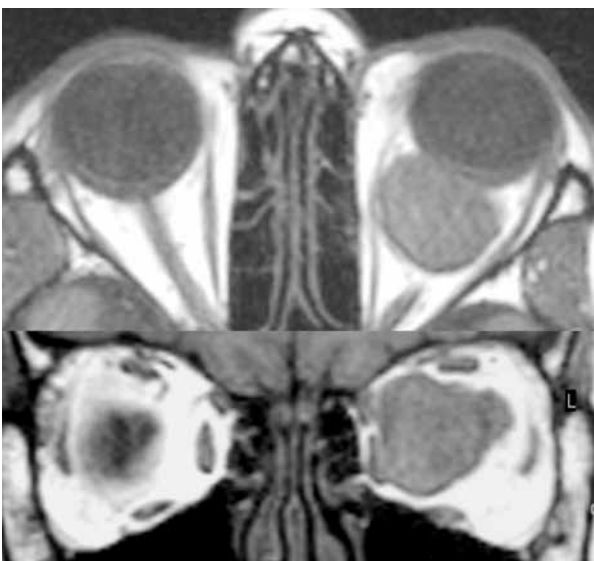

Fig. 6 – The same cavernous hemangioma in MRI.

lymphatic nodules, follicles or vessels, which are the origin of such lesions. These tumors can be restricted to the orbit or they may extend throughout the conjunctiva, eyelids and periorbital tissues. They usually become clinically manifest in the first decade of life, but are often present at birth. Sometimes they are detected later, after trauma or hemorrhage. When several orbital structures (muscles, optic nerve) are involved, this can produce eye movement restriction, proptosis, ptosis or present as an elastic, floating, palpable mass filled with lymphatic material (Fig. 7 and 8). Spontaneously or after trauma or a viral infection these channels can be filled with blood (forming the “chocolate cysts”), causing acute proptosis capable of compressing the ocular globe or optic nerve. Surgical treatment is challenging because it can be an option in circumscribed tumors but is very limited in diffuse lesions. Other therapeutical options have been tried in such cases. Unlike capillary hemangiomas in children, these tumors do

not spontaneously involute.

Surgical management is recommended when clinical manifestations are present. The potential involvement of noble orbital structures means that their complete excision is not always possible. When acute globe compression occurs, urgent intervention to decompress the orbit is required to preserve vision.

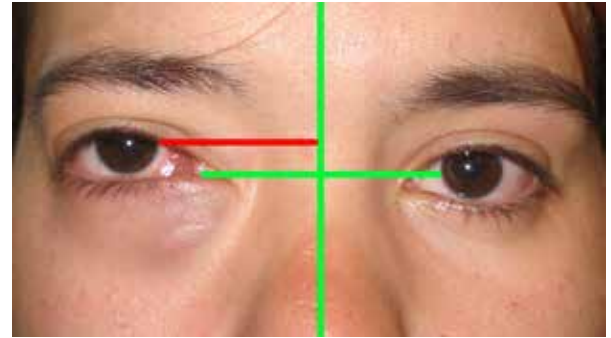


Fig. 7 – Large right orbital lymphangioma inferiorly and medially located, causing supero-lateral globe displacement in a 25-year-old woman.

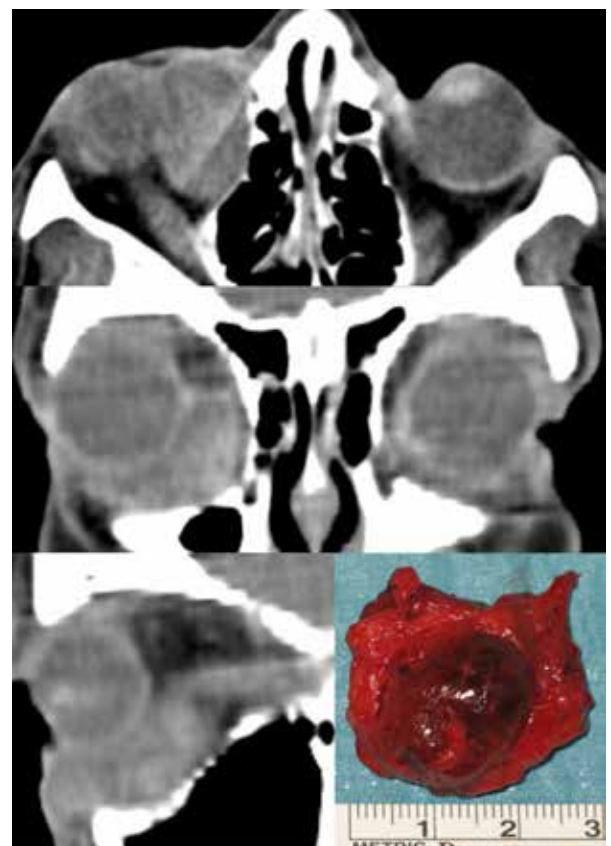


Fig. 8 – Orbital CT scan of the same lymphangioma and gross macroscopy.

3. Lymphoproliferative orbital tumors

Lymphoproliferative tumors belong to a major group of histiocytic, hematologic and lymphoproliferative conditions which cover a wide spectrum. They include benign conditions such as reactive lymphoproliferative lesions to low-grade lymphomas (small lymphocytic

28. Adult Orbital tumors

lymphoma and follicular lymphoma, for example), more aggressive lymphomas (mantle cell lymphoma) and high-grade malignant lymphomas.

Hodgkin lymphomas usually have extra-orbital manifestations. The commonest orbital lymphoma is non-Hodgkin lymphoma, which is also the most common orbital malignant tumor in adults. Clinically, lymphomas are difficult to distinguish from each other and biopsy and subsequent immunohistochemistry and cytometry are needed to characterize their phenotypes. Lymphomas tend to occur in older ages. They typically present as an orbital, non-painful, firm mass with insidious growth, sometimes for years, palpable through the superior eyelid, frequently producing mechanical ptosis (Fig. 9 and 10). Lymphomas are the orbital tumors that most often present as a palpable mass, which reflects their tendency to extend throughout the anterior orbit planes, ocular muscles and ocular globe, instead of forming a circumscribed mass in the posterior orbit. Therefore, these tumors tend to take the shape of the space they grow into.

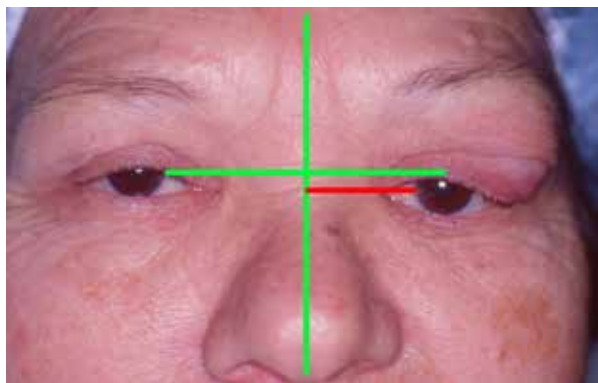


Fig. 9 – Left orbit B-cell lymphoma from the lacrimal gland region that displaces the globe inwards and downward in a 66-year-old woman.

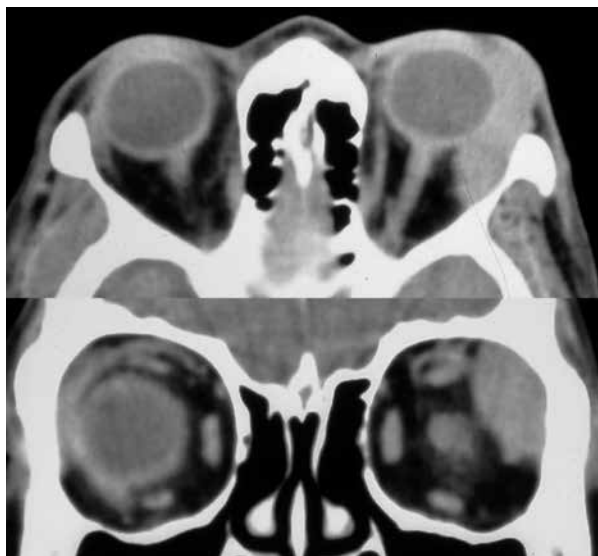


Fig. 10 – CT scan shows a mass that infiltrates the orbit and eyelids but without globe deformation.

A subconjunctival mass in the surface of the globe, salmon pink in color, is sometimes the only visible part of a mass that extends to the intraconal space (Fig. 11).

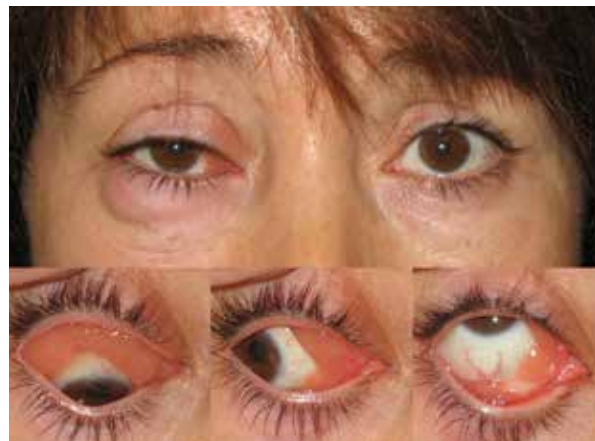

Fig. 11 – Marginal B-cell lymphoma with subconjunctival involvement (causing mild ptosis) and the characteristic salmon appearance in a 50-year old woman.

The treatment varies according to how aggressive the tumor is and includes chemotherapy and/or radiotherapy. Surgery alone is seldom enough to prevent recurrences.

4. Inflammatory orbital tumors

Orbital inflammatory disease (previously named inflammatory orbital pseudotumor or orbital idiopathic inflammation) covers a large spectrum of pathologies that can be classified as specific (known etiology) and nonspecific (unknown etiology). Nonspecific inflammation is defined as polymorphous benign lymphoid infiltrate with various degrees of associated fibrosis, without local or systemic underlying cause. This diagnosis can only be made after excluding all possible specific causes.

The etiopathology is thought to be linked to immune origin as this condition is frequently associated with specific autoimmune diseases (Crohn's disease, disseminated lupus erythematosus, diabetes mellitus, myasthenia gravis and ankylosing spondylitis) and responds favorably to steroid treatment and other immunomodulators as cyclophosphamide, methotrexate or cyclosporine (indicating a cell-mediated immunity). Other etiopathological mechanisms could include post-infectious (usually after upper respiratory tract infections) or post-traumatic (especially in children) conditions.

These conditions are more frequent in adults and have several clinical presentations which point to a specific location of the inflammatory process. The inflammation can be located in muscles, the lacrimal gland, anterior orbit or apical orbit, or be diffuse (Fig. 12 and 13). Each site will produce signs and symptoms consistent with the location of the inflammatory

process. The process can present acutely (days), subacutely (days to weeks) or chronically (weeks to months). The most frequent pattern of presentation is acute onset with orbital pain, hyperemia, palpebral edema, chemosis and proptosis. Concomitant ocular inflammation can also be present (uveitis, optic papillitis, and exudative retinal detachment).

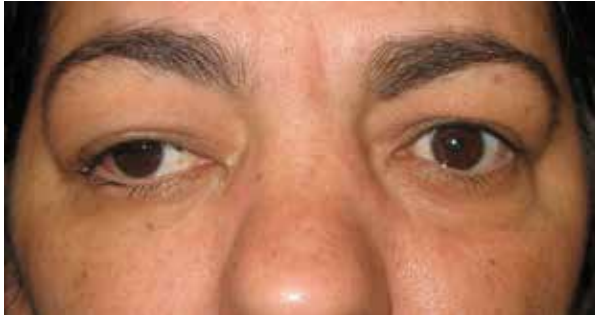

Fig. 12 – Right diffuse orbital sclerosing tumor producing orbital apex syndrome with ptosis, ophthalmoplegia and amaurosis in a 41-year-old woman.

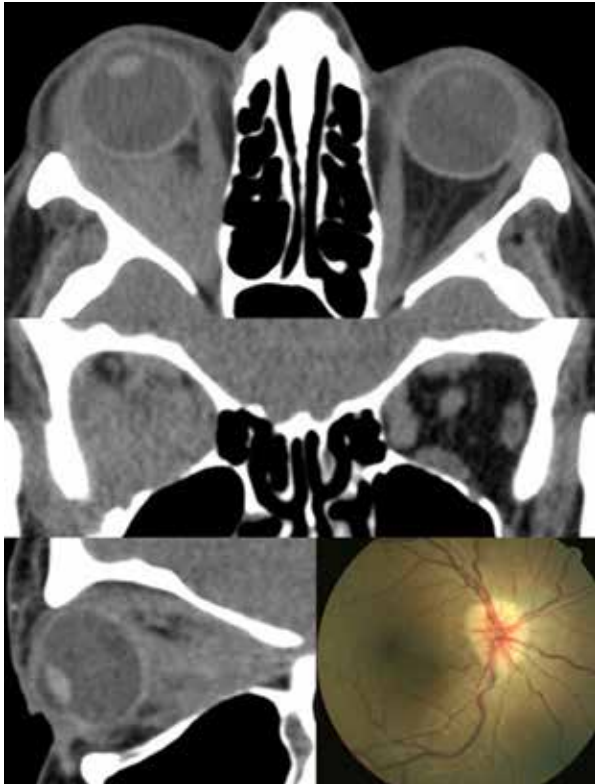


Fig. 13 – The same sclerosing tumor occupying almost all the orbital compartment, compressing its structures with optic nerve atrophy.

5. Mesenchymal orbital tumors

Mesenchymal orbital tumors arise from a wide range of tissues and, because almost all mesenchymal tissues are present in the orbit, a great variety of mesenchymal tumors can be found there.

Fibrous Histiocytoma

Fibrous histiocytoma is one of the commonest

primary mesenchymal tumors in adults. The name arises from the cells that compose it, which resemble normal fibroblasts and histiocytes, but its origin is not totally understood. This tumor can be difficult to differentiate from a fibrous lesion and has malignant potential. It is more frequent after the fifth decade (Fig. 14 and 15). Macroscopically, fibrous histiocytoma is a well delimited, lobulated tumor whose color varies from whitish (if the fibrous component predominates) to yellowish (if the histiocytic component predominates). The tumor may recur after apparently complete excision.

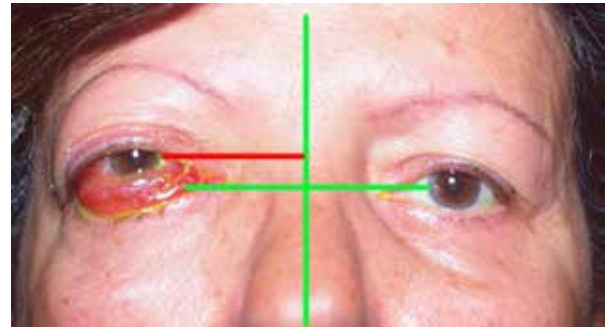


Fig. 14 – Right orbital fibrous histiocytoma displacing the globe upwards and outwards, with marked chemosis, in a 52-year-old woman.

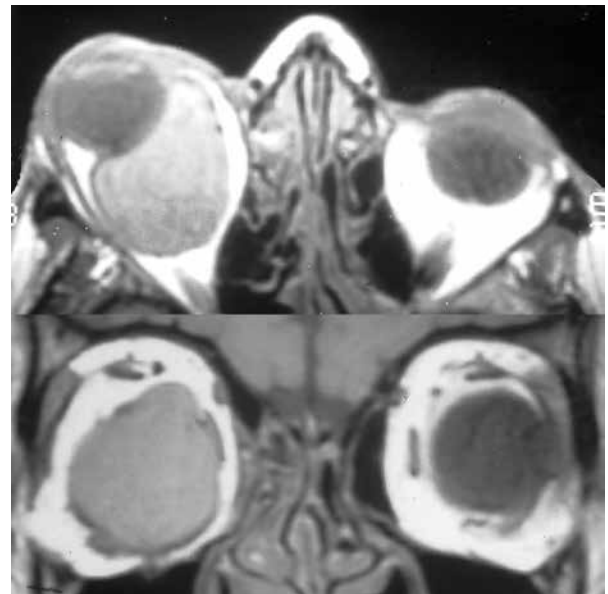


Fig. 15 – MRI from the same fibrous histiocytoma.

Solitary Fibrous Tumor

Orbital solitary fibrous tumor (formerly called fibrous mesothelioma) occurs more often in the extraconal space. It is anteriorly located in the orbit, and can become quite large (Fig. 16 and 17). It has a slow growth pattern and seldom causes diplopia. Macroscopically, solitary fibrous tumor is a well delimited greyish tumor and does not recur after complete excision.

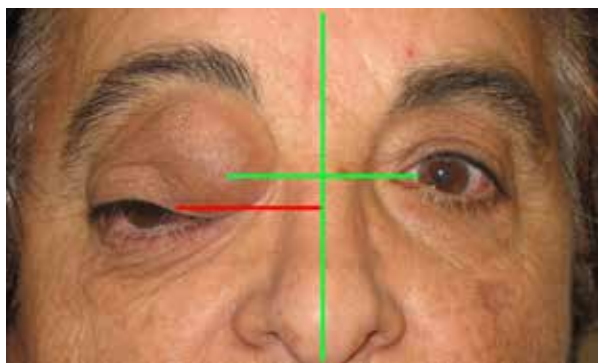


Fig. 16 – Right orbital solitary fibrous tumor that displaces the globe downwards and outwards, in a 64-year old woman.

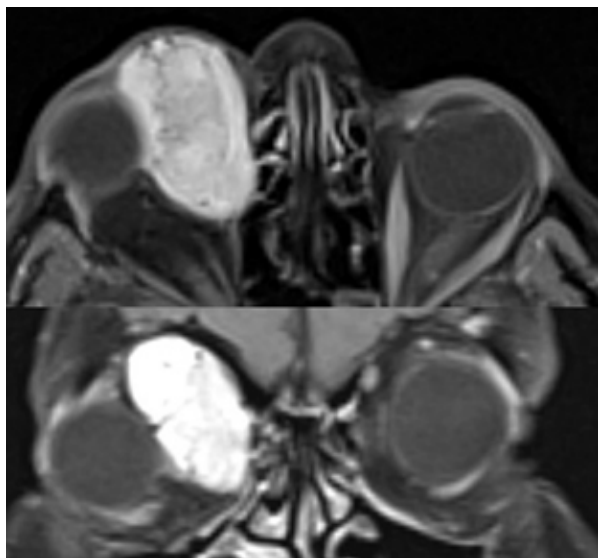


Fig. 17 – MRI from the above tumor in which slow growing nature of the tumor causes ethmoidal distortion.

Fibrous Dysplasia

Fibrous dysplasia is a benign lesion of unknown origin, characterized by the presence of fibrous tissue in an immature bone pattern. It is not considered a true malignancy and arises during the second decade, but continues to grow throughout adult life. Symptoms depend on the lesion's location. Initially there is no optic nerve compression and visual acuity is maintained. Treatment can be challenging and conservative approach can be an option (Fig. 18 and 19).

Osteoma

Orbital osteomas are mesenchymal tumors that develop from bones and sinuses of the face. The most usual sites of origin are the frontal sinus (50%), maxillary (40%) and sphenoid sinus (3%). Location and size will determine clinical presentation, which is most often displacement of the ocular globe (Fig. 20 and 21). Surgical treatment depends on the size, location and extent of the tumor.

Orbital Lipoma

Although lipomas are the most frequent mesenchymal

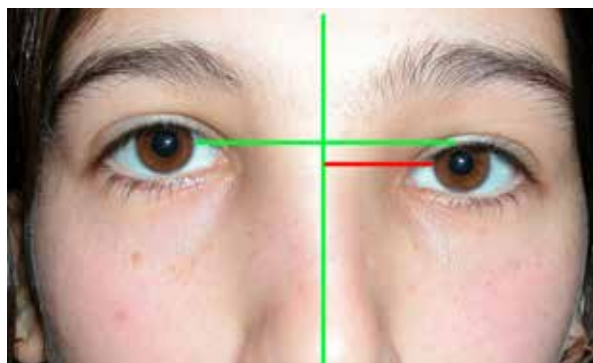


Fig. 18 – Left orbital fibrous dysplasia in a 17-year-old woman.

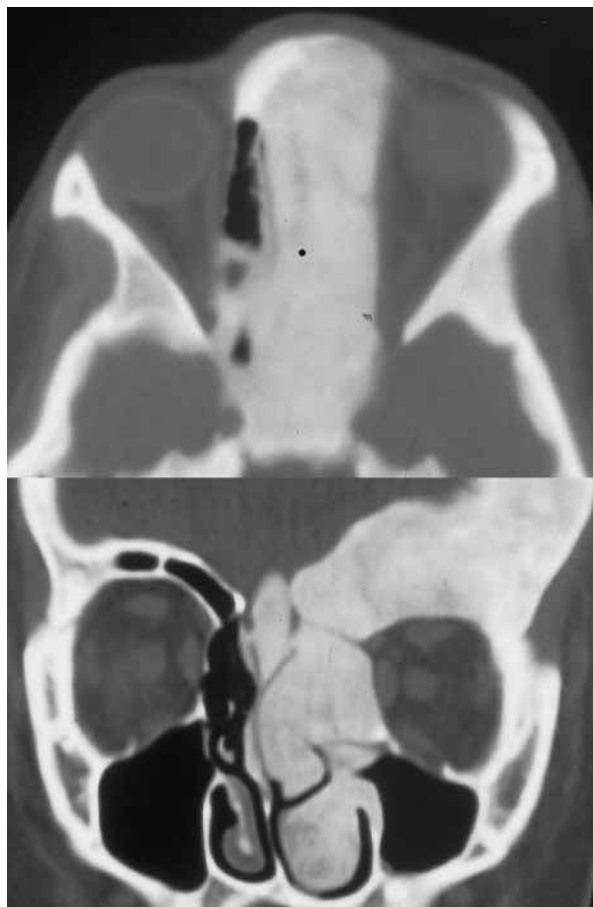


Fig. 19 – CT scans from the above patient in bone window that show involvement of the ethmoidal, sphenoidal and frontal bones.

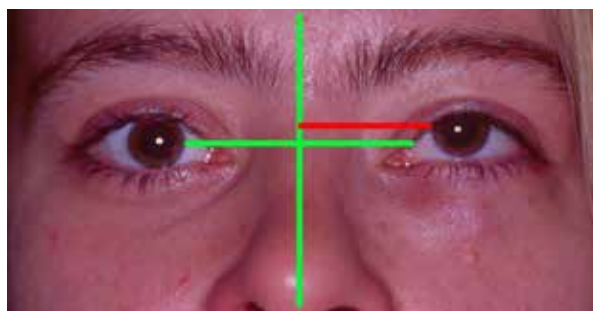


Fig. 20 – Left orbital floor osteoma causing upwards and outwards displacement of the ocular globe, in a 22-year-old woman.

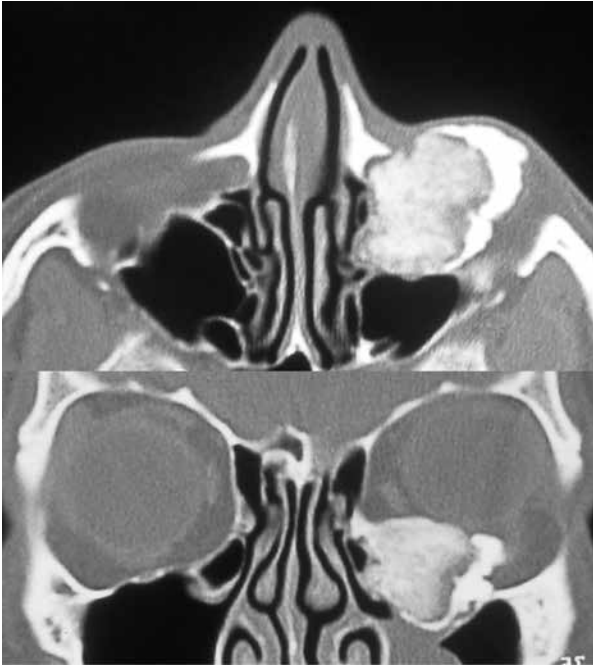

Fig. 21 – CT-scan from the above patient showing an osteoma located in the medial aspect of the orbital floor.

tumor in the rest of the body, orbital location is rather rare. They arise mainly in elderly people, in whom growth of the orbital adipose tissue occurs, sometimes in combination with other orbital tissues. Growth is slow and visual acuity is not affected in early stages, although the tumor can become quite large (Fig. 22 and 23). In the early stages, lipomas can be misdiagnosed as subconjunctival orbital fat prolapse, which is common in obese patients. Other less common mesenchymal orbital tumors are fibromas and histiocytomas.

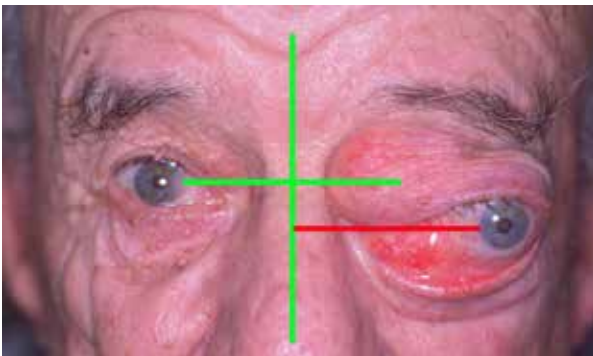


Fig. 22 – Large left orbital lipoma producing exuberant outwards and downwards displacement of the globe in a 80-year-old man.

6. Neurogenic orbital tumors

Schwannoma (Neurilemoma)

Schwannoma is an encapsulated, benign tumor of the Schwann cells. It can either be primarily orbital or reach the orbit through an adjacent peripheral nerve. Clinically, this tumor is similar to the solitary orbital

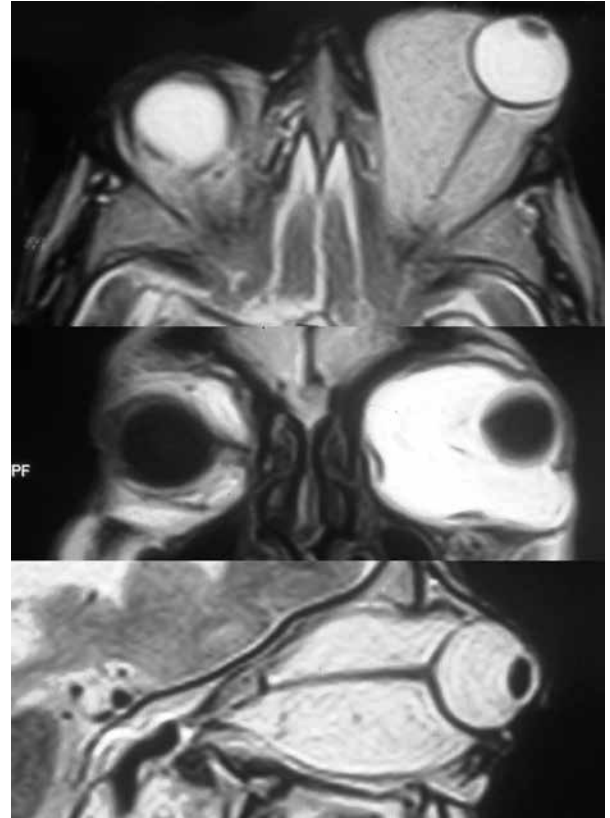


Fig. 23 – MRI of the above patient showing the lipoma occupying almost all the orbital cavity and causing optic nerve stretching.

tumor and causes proptosis and globe displacement, according to its location (Fig. 24 and 25). Although schwannomas arise from a nerve sheath, they do not provoke pain. In contrast to neurofibroma, a solitary schwannoma is not associated with neurofibromatosis. Imaging exams show a solid, elongated and extraconal tumor extending along the supraorbital, supratrochlear or infraorbital nerves. It is a well delimited, capsulated, whitish tumor. The preferred approach is surgical excision.

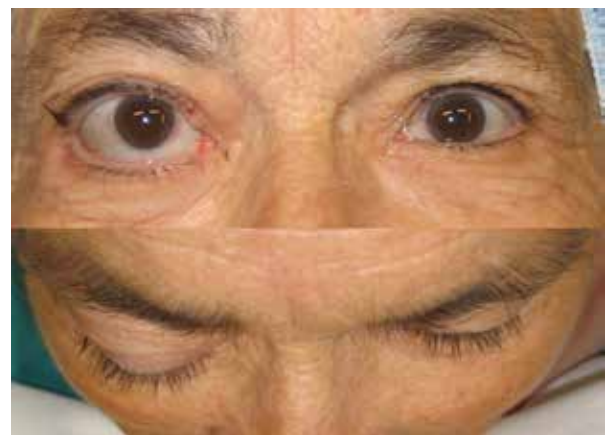

Fig. 24 – Right orbital schwannoma with proptosis in a 72-year-old woman.

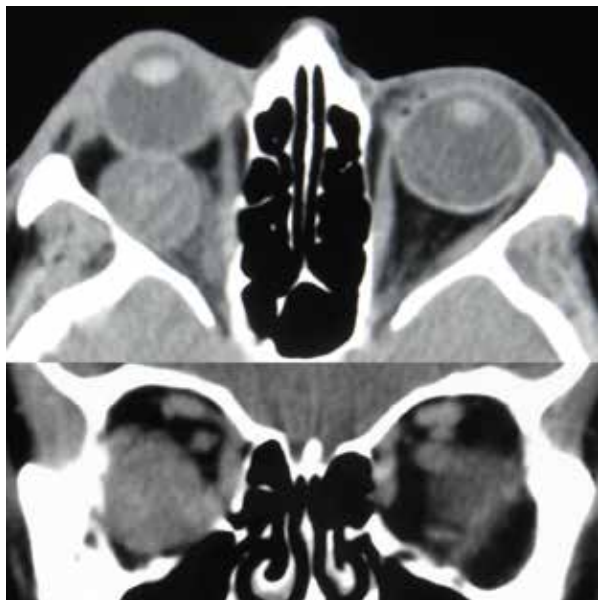


Fig. 25 – CT-scan from the above patient with a nodular circumscribed orbital schwannoma in the inferior temporal quadrant of the right orbita.

Neurofibroma

Neurofibroma is a benign tumor from the peripheral nerves. It can be classified as localized, diffuse or plexiform. Localized neurofibroma can be clinically and imagiologically indistinguishable from schwannoma and is associated with type-1 neurofibromatosis (NF-1) in 10% of cases. Diffuse neurofibroma has a variable association with NF-1 and plexiform neurofibromas are almost invariably associated with NF-1. In 10 to 15% of cases there is association with optic nerve gliomas. Clinically, it presents as a thickening or edema of the external third of the superior eyelid (causing ptosis), with the typical description of “bag of worms” upon palpation (Fig. 26). The therapeutic approach is surgical excision, which is a complex procedure because of the tendency to hemorrhage, especially in plexiform neurofibromas.

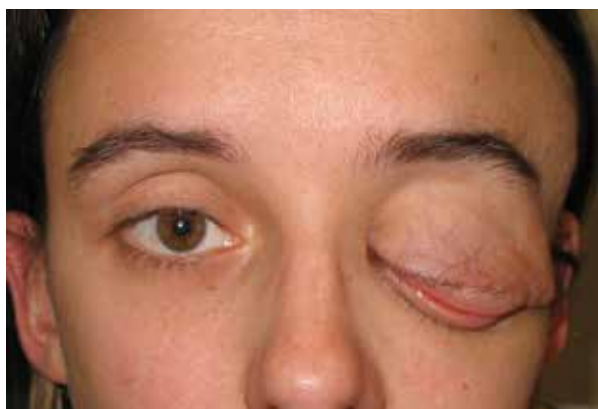

Fig. 26 – Left orbital plexiform neurofibroma with eyelid involvement in a 26-year-old woman.

Pilocytic Astrocytomas

Pilocytic astrocytoma is a tumor of the glial cells (astrocytes) which support the white matter of the brain and optic nerve. In 70% of cases, these tumors arise in the first decade and are called juvenile pilocytic astrocytomas or gliomas. Of these, 30% are associated with NF. Clinically, they present as non-painful proptosis with variable visual and motility impairment. Less frequently, pilocytic astrocytomas can arise in adults (Fig. 27 and 28) and are called pilocytic astrocytomas or infiltrative anaplastic astrocytomas when malign transformation occurs.

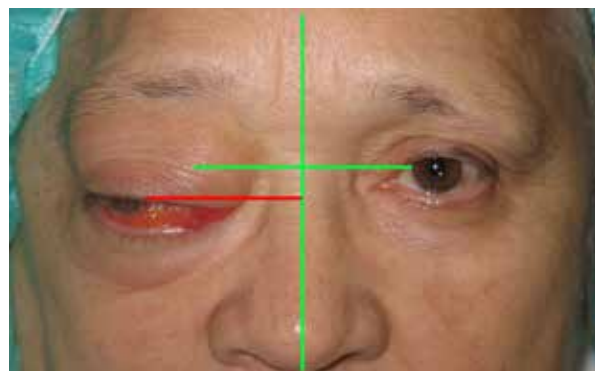


Fig. 27 – Right optic nerve pilocytic astrocytoma with proptosis and globe displacement in a 71-year-old woman.

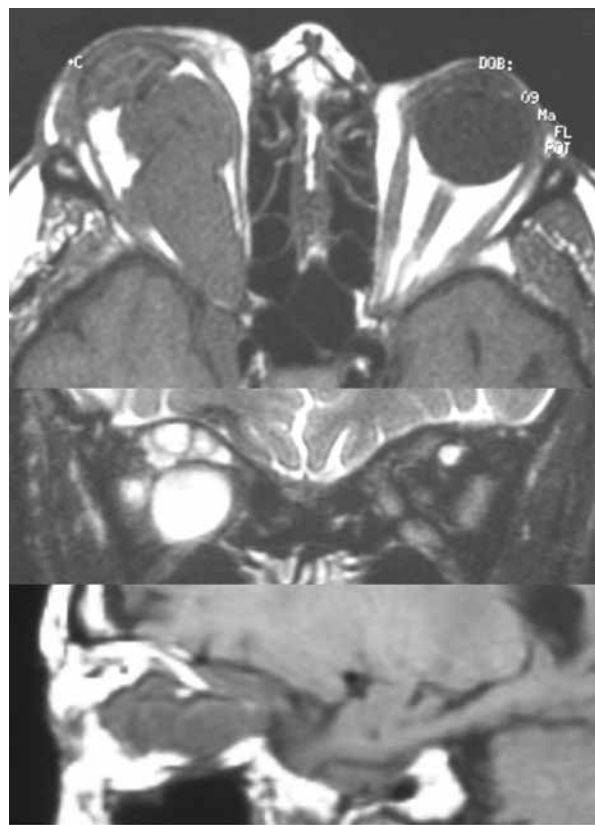

Fig. 28 – MRI from the above patient with an astrocytoma enveloping the optic nerve, extending to its intracanal portion.

Meningioma

Meningioma is a benign tumor of the arachnoid (meninges), which often affects the orbit. It arises from the optic nerve sheath or the greater wing of the sphenoid bone (*en plaque* meningioma). A large percentage of cases (80%) occur in adult women. When located in the optic nerve, these tumors can cause visual loss, optic nerve edema or atrophy, frequently with a chorioretinal vascular shunt in the optic nerve margin. Although benign, meningiomas can behave in a clinically aggressive way. Imaging studies show thickening of the nerve sheaths, sometimes calcified, with preserved dimensions of the optic nerve, occasionally showing the tram-track sign in MRI (Fig. 29). Asymmetrical cases can be managed with a conservative approach by monitoring visual acuity, perimetry and MRI scanning. If any growth is detected and ophthalmological consequences arise, fractionated stereotactic radiotherapy can become an option. Surgery is reserved for extreme cases with visual loss and perimetric repercussions.

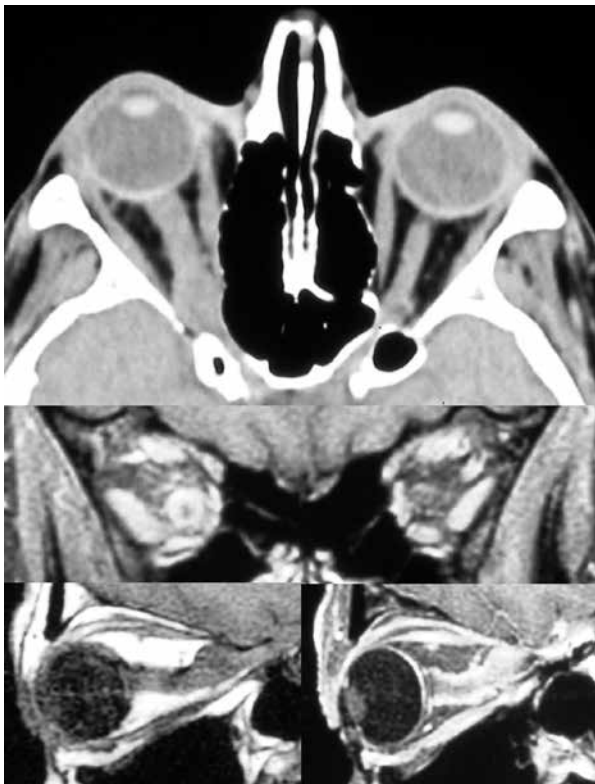


Fig. 29 – Right optic nerve sheath meningioma in CT-scan and MRI, with the tram-track sign due to contrast uptake, in a 55-year-old woman.

7. Lacrimal gland tumors

About 10% of orbital space occupying lesions arise from the lacrimal gland. As the lacrimal gland is the only site in the orbit where epithelial tissue can be found, the majority of primary epithelial orbital lesions originate from the lacrimal gland. However,

only 20% of these tumors are epithelial (pleomorphic adenoma and adenocarcinoma) with the other 80% being non-epithelial (lymphoproliferative or inflammatory conditions). Of the epithelial tumors, 55% are benign and 45% malignant. Benign tumors and lymphomas do not usually cause pain, whereas malignant tumor and inflammatory processes do. Clinical evolution can help distinguish benign from malignant tumors as the former show slow progressive growth, while malignant conditions do not. Imaging demonstrates that benign tumors characteristically deform bone tissue but do not invade or destroy it.

Pleomorphic adenoma of the lacrimal gland

Pleomorphic adenoma (previously called benign mixed tumor) is the most common epithelial tumor of the lacrimal gland. Most of them arise in the orbital lobe of the gland and are most commonly diagnosed in young adults. These tumors grow slowly and cause anterior globe displacement inward and downward (Fig. 30). When the tumor is too large the globe can be displaced outward. When they arise in the palpebral lobe (infrequent) these tumors do not cause proptosis and are palpable as a hard, non-painful masses in the superior lateral quadrant of the orbit. Imaging shows a spherical or ovoid tumor in the lacrimal fossa of the orbit (Fig. 31). Histopathologically, it is composed of epithelial and mesenchymal tissues (hence the name mixed tumor). Surgery is the recommended approach and the entire capsule should be completely removed as the tumor can recur or even become malignant.

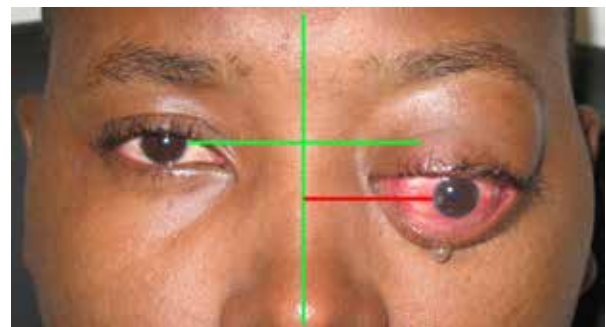


Fig. 30 – Large pleomorphic adenoma of the left lacrimal gland causing ocular displacement anteriorly, downwards and outwards, in a 29-year-old man.

Adenocarcinoma of the lacrimal gland

Adenocarcinoma is an aggressive tumor and the most common primary malignant epithelial tumor of the lacrimal gland. Clinical presentation is similar to pleomorphic adenoma and cystic adenoid carcinoma, nonetheless it usually occurs in older patients. This tumor presents with faster growth, induces pain when invading nerves and the periorbital tissues, and

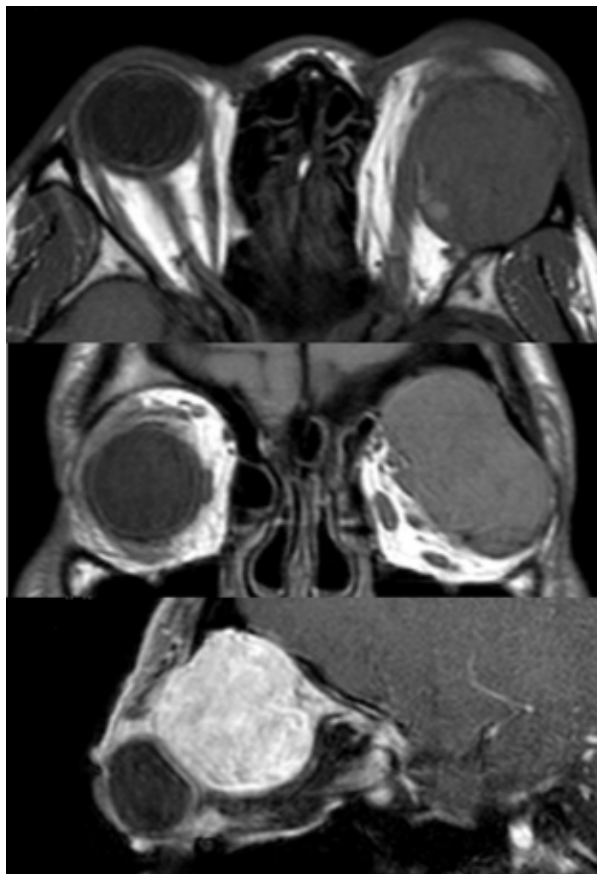


Fig. 31 – MRI from the above pleomorphic adenoma showing large dimensions, heterogeneous density, globe deformation and bone deformation, but not invasion.

can cause hypoesthesia of the ipsilateral periocular area (Fig. 32 and 33). When the tumor is small and encapsulated, complete excision can be curative. When bone tissue is involved, orbital exenteration may be necessary, yet not curative, as this tumor easily recurs and spreads by a lymphatic pathway.

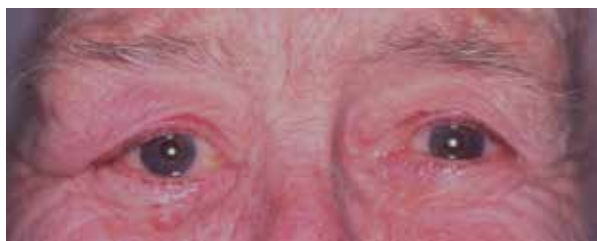

Fig. 32 – Right lacrimal gland adenocarcinoma in a 84-year-old woman.

Secondary orbital tumors

Secondary orbital tumors are those that invade the orbit after originating in the adjacent extra-orbital structures (eyelid, conjunctiva, perinasal sinuses or brain) or intraocular tissues. As a group, these secondary malignancies are three times more common in the orbit than primary malignancies. The difference for metastatic lesions is that in the latter the primary lesion is distant from the orbit

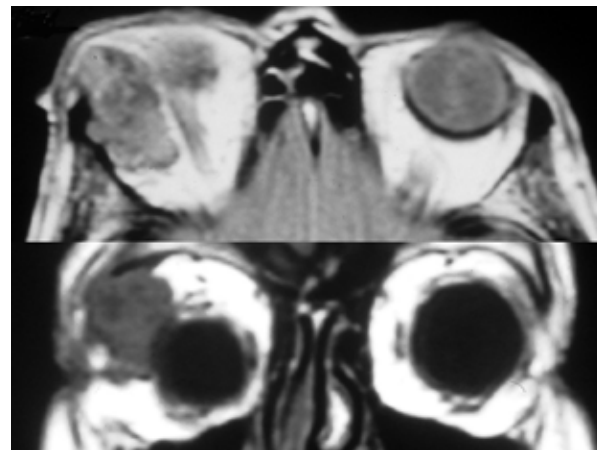


Fig. 33 – MRI of the same lacrimal gland adenocarcinoma with adjacent osseous invasion and destruction.

and reaches it through hematogenous dissemination. The most common eyelid tumors that secondarily invade the orbit are squamous-cell carcinoma, basal cell carcinoma (especially from the medial canthus), cutaneous melanoma and Merkel cell carcinoma. The most common conjunctival tumors that secondarily invade the orbit are melanoma and squamous cell carcinoma (especially mucoepidermoid type). Of tumors originating in the perinasal sinuses, squamous cell carcinoma is the most common (Fig. 34 and 35), and the commonest intracranial tumor to invade the orbit is sphenoidal meningioma. Uveal melanoma and retinoblastoma, in adults and children respectively, are the most frequent intra-ocular malignancies to secondarily invade the orbit. Clinical presentation varies depending on type and primary tumor location. Patients often have a history of previous periorbital surgery (for eyelid, conjunctival, perinasal and intracranial tumors).

In perinasal sinus tumors and greater wing of the sphenoid tumors, the orbital signs are usually the first to appear.

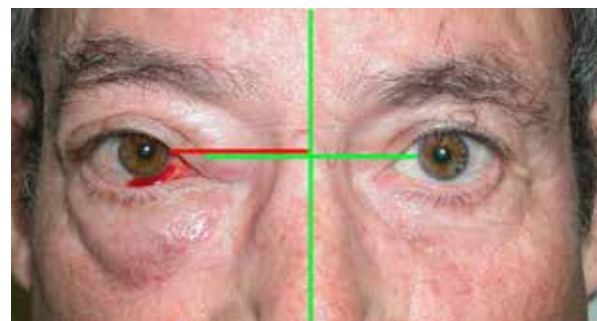


Fig. 34 – Squamous-cell carcinoma of the ethmoid with right orbital invasion, with outwards globe displacement in a 68-year-old man.

Mucocele

Although mucocèles are not real malignancies, they can resemble a tumor as they behave as a

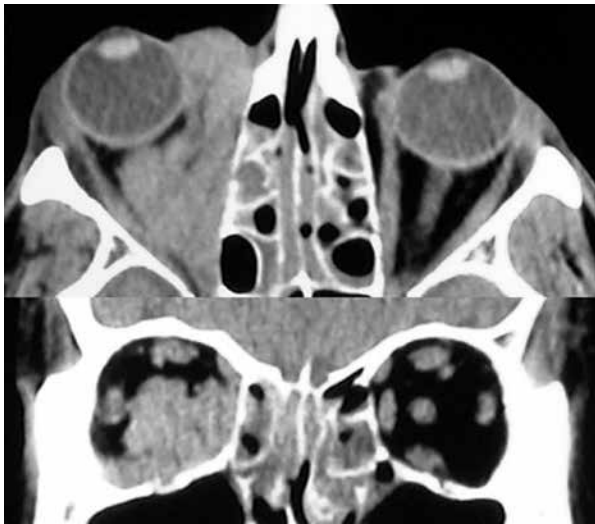


Fig. 35 – CT-scan of the above patient.

space-occupying lesion. Mucocoeles are the most common secondary tumors in adults and there is often a previous history of chronic sinusitis. They arise from an orbital extension of perinasal sinus mucocoeles (frontal - the most frequent - ethmoidal, sphenoidal or maxillary - the least frequent) and may become infected, constituting a mucopyocoele. Most mucocoeles are palpable and produce proptosis, which can worsen with secretion accumulation (Fig. 36 and 37). Proposed treatment is the surgical drainage and ventilation of the involved sinus, when there is a clinical repercussion.

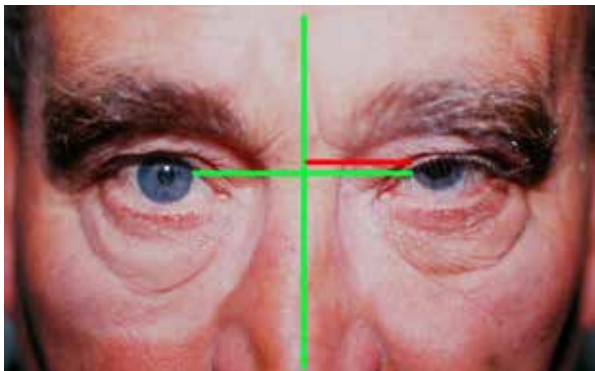


Fig. 36 – Maxillary mucocoele with left orbital invasion and upwards globe displacement.

9. Metastatic orbital tumors

A variety of tumors can hematogenously reach the orbit. In adults, in order of frequency, the most common tumors are breast, lung, prostate and kidney. Metastasis will predominantly locate in the most vascularized tissues. Breast and lung carcinoma usually metastasize to soft tissues while prostate cancer spreads to bone tissue, causing pain in the earlier stages. Secondary bone lesions are commonly osteoblastic masses that can also be osteolytic. Most

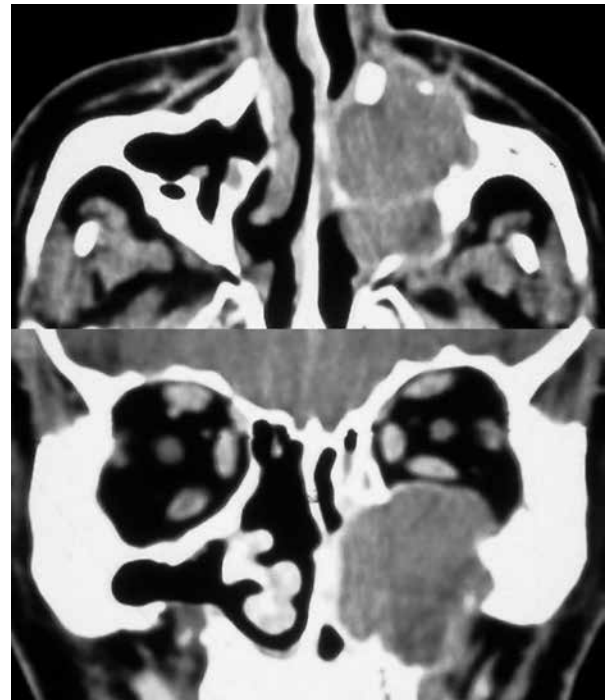


Fig. 37 – CT-scan of the above mucocoele.

patients (80%) have a known history of malignancy. Clinical presentation will depend on the type and site of the tumor but classically the patient presents with ptosis, proptosis, globe displacement, diplopia, chemosis and eyelid edema. Pain is usually associated with bone destruction and when accompanied by vision loss, an orbital vertex lesion should be suspected. The treatment will depend on the management of the original tumor.

Bibliography:

1. Garrity JA, Henderson JW. Henderson's orbital tumors. 4th Ed. U.S.A. Lippincott Williams & Wilkins. 2007.
2. Karcioğlu ZA. Orbital tumors. Diagnosis and treatment. U.S.A. Springer. 2009.
3. Pérez Moreiras JV, Prada Sánchez MC. Patología orbitaria. España. Edika Med. 2002.
4. Singh AD, Damato BE, Pe'er J, Murphree AL, Perry JD. Clinical ophthalmic oncology. U.S.A. Saunders Elsevier. 2007.
5. Shields JA, Shields CL. Eyelid, conjunctival, and orbital tumors. An atlas and textbook. 2nd Ed. U.S.A. Lippincott Williams & Wilkins. 2008.
6. Rootman J. Diseases of the orbit. A multidisciplinary approach. U.S.A. J.B. Lippincott Company. 1988.
7. Yanoff M, Sassani JW. Ocular pathology. 6th Ed. U.S.A. Mosby Elsevier. 2009.
8. Esmaili B. Ophthalmic oncology. U.S.A. Springer. 2011.
9. Char DH. Tumors of the eye and ocular adnexa. American Cancer Society. London. BC Decker Inc. 2001.

29. Pediatric Orbital Tumors

Guilherme Castela, Marco Marques

Introduction

The etiology of orbital tumors in infants is quite distinct from those that occur in adult age. Many are congenital, presenting at birth or in early ages. They can be classified as cystic, vascular, inflammatory, mesodermal, neurogenic or metastatic tumors, according to their histologic features. The majority of pediatric orbital tumors have a benign behavior: the most commonly detected lesions are developmental cysts, which account for about half of those diagnosed, followed by capillary hemangiomas and inflammatory diseases. The most common malignant tumor of the orbit, while rare, is the rhabdomyosarcoma. Optic nerve glioma is the most common neurogenic tumor, and it often presents in association with Von Recklinghausen disease (Type I Neurofibromatosis). In children, ophthalmologic metastatic disease is often encountered in the orbit, with the most common metastatic tumor being the neuroblastoma. In adults, metastases tend to involve the choroid.

Proptosis is often the first presenting sign of an orbital mass in young children, and it can be an alarming experience for both child and parents. Other clinical features linked with orbital tumors in children are eyelid retraction or ptosis, eyeball dystopia, vascular congestion, pupil abnormalities, strabismus, diplopia, visual acuity loss and optic disc edema or atrophy. In each case, according to the clinical features, image exams can help in reaching a diagnosis. If uncertainties still persist, biopsy of the lesion can lead to a definite diagnosis. Treatment approaches may range from observation to surgical excision depending upon the extent of the lesion and diagnosis¹.

Early diagnosis of these tumors is key to preventing visual compromise, and in some cases to extending survival rates. The pediatrician has a critical role in early diagnosis and prompt referral to an ophthalmologist. The purpose of this chapter is to outline the most common pediatric orbital tumors and offer a description of the clinical manifestations, diagnosis, and treatment options.

Cystic tumors

Dermoid and epidermoid cysts

These cysts originate in epithelial cellular residues in the bony structure of the orbit, or arise when the neural tube fails to detach from the superficial ectoderm during in-uterus development². They have a benign course and an excellent prognosis. The presence of dermal components differentiates dermoid from epidermoid cysts. Dermoid cysts enclose adnexal structures such as hair follicles, sweat or sebaceous glands whereas epidermoids contain no adnexal structures. These masses are commonly called choristomas as they are histologically regular tissues that grow in an abnormal organ or cavity.

Epidemiology and clinical features

These are the most common neoplasms of the orbit, representing 30–46% of all excised masses^{1, 3}. Although they can grow in virtually any subcutaneous area, many are found in the cephalic region⁴ and orbit. They usually lodge superficially (anteriorly to the septum), superiorly and temporally near the frontozygomatic and frontolacrimal suture, but they can also be located more deeply, lying within the orbit. Their most common location requires differentiation from a lacrimal gland neoplasm.

The typical clinical picture is of a child or adolescent with slowly growing, painless, firm (or slightly mobile), subcutaneous tumefaction located in the superior temporal quadrant of the orbit. When superficial, they are promptly detected, generally within the first decade of life. However, a deeply located mass can be overlooked and only diagnosed later. Occasionally globe dystopia may occur. Visual disturbance is rare unless the tumor is within the intraconal orbit. In this location it can cause proptosis as well as ocular motility disorders and optic nerve compression. Its slow growth can produce bony remodeling. When ruptured, content leakage can trigger an acute inflammatory reaction that mimics acute cellulitis⁵. Moreover, cyst-contiguous fistulae may become infected and also simulate orbital

cellulitis, which may be the presenting manifestation in these circumstances⁶ (Fig. 1 to 3).

Imaging

Ultrasonography may be useful when the cyst is superficial. Characteristically, a heterogeneous, non-vascularized lesion with variable echogenicity and smooth borders is seen⁷.

In CT imaging, these tumors show up as well-defined masses, with a hyperintense periphery surrounding a hypointense centre. Occasionally, epithelial remains can be recognized as irregular densities within the lesion. About 85% cause some degree of bony deformation, and a bony depression is frequently seen on CT, most often near the frontozygomatic fossa⁸. The MR imaging signal differs according to the luminal contents. However, most are hypointense to fat on T1-weighted images and hyperintense to fat in T2-weighted images⁹. In fat suppression MR imaging series, dermoid cysts are also suppressed, a phenomenon that doesn't occur with epidermoid cysts as they lack dermal components, such as adipose tissue⁵.

Contrast staining does not enhance this kind of tumor.

Treatment and prognosis

Approach to these cysts is centered on their location and progression. A small, asymptomatic cyst does not require treatment. However, when symptoms develop, a surgical approach is of utmost importance. The surgical technique should involve complete excision with an intact capsule¹⁰. Capsular disruption is a complication of surgery and should be prevented⁸. Many approach techniques are described in the literature, but the one that gives the best results involves a surgical incision in the superior eyelid crease. This technique is useful mainly for the frontozygomatic locations, and scar tissue can be effectively concealed as well^{11, 12}. The removal of deeper cysts needs a more complex procedure, and incomplete removal is associated with recurrence of the cyst¹³ and malignant transformation to epidermoid carcinoma¹⁴. When dealing with large cysts, a lateral orbitotomy may be the best approach⁸. When disruption complicates surgery, it must be treated as an acute inflammatory situation. If a new procedure is planned, it is advisable to wait until the inflammation subsides. The waiting time can be up to several weeks.

Colobomatous orbital cyst with microphthalmos

Faulty closure of the posterior part of the embryonic fissure between the 5th and 6th weeks of embryonic development causes this congenital syndrome¹⁵. It is defined as a cyst of neural tissue associated with ophthalmic underdevelopment. The colobomatous cyst is lined with neuroectoderm and appears within



Fig. 1: Right superior and temporal subcutaneous dermoid cyst.

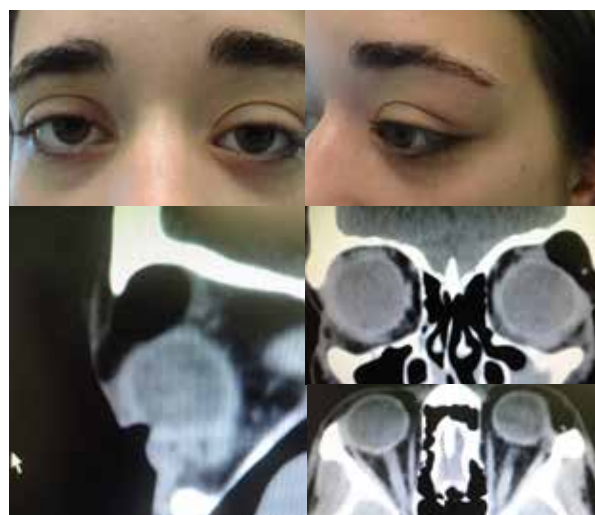


Fig. 2: Left superotemporal dermoid cyst in a 13-year-old girl. A barely visible subcutaneous mass is noticed. CT demonstrates bony remodeling in the frontozygomatic aspect of the orbit.

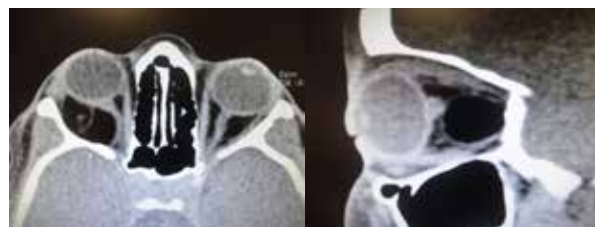

Fig. 3: Right intraconal orbital dermoid cyst in a 14-year-old child. Optic nerve deviation is evident on the CT scan.

an orbit with a colobomatous microphthalmic eye⁴. The causes of cyst formation are many and multifactorial, but in the majority of cases they are sporadic. The exact mechanism of formation is poorly understood, but probably there is a prolapse of the intraocular contents through a wall defect into the adjacent orbit, which results in an abnormal scleral ectasia¹⁶.

Epidemiology and clinical features

Although the exact incidence is not known, it is a rare condition usually diagnosed at birth or in the first days of life, with no gender predilection. The majority of cases are unilateral but bilateral cases have been described¹⁷. The latter ones can be related to systemic

abnormalities involving the central nervous, renal, or cardiovascular systems, or chromosomal deletions.

Three clinical presentations can be observed with distinctive spectrums of gravity that influence treatment: Severe microphthalmos with voluminous bluish cyst that exerts pressure on the eyelids and occupies the entire orbit; microphthalmos with a similar-sized cyst; and less severe microphthalmos with formation of a small cyst¹⁸. These eyes usually have a poor visual outcome: typically, cyst grows after birth, and when of large dimensions it leads to an asymmetry between the orbits, due to a bony reaction and overgrowth. Early diagnosis and treatment are critical to ensure the adequate orbital development (Fig. 4, 5).

Imaging

Ultrasound shows the image of a small-sized globe with a coloboma, and a cystic cavity of greater dimensions.

Cyst reflectivity is very low due to its liquid content¹⁸. CT and MR imaging complement the information given by ultrasound, demonstrating the presence of a microphthalmic eye and the full extent of the cystic cavity¹⁵. The orbital cavity can be enlarged, with expansion of the walls, without bone destruction¹⁸. It is quite often possible to identify a communication between the cyst and the globe. This information is useful when planning the surgical management of these lesions. Contrast injection does not enhance the mass. Co-existing cranioencephalic malformations can also be assessed with these exams.

Treatment and prognosis

Management of these cysts depends on the age of the patient, size of the cyst, presence of a communication between the globe and the cyst, and visual prognosis¹⁹. Surgical treatment is variable: simple aspiration of cyst

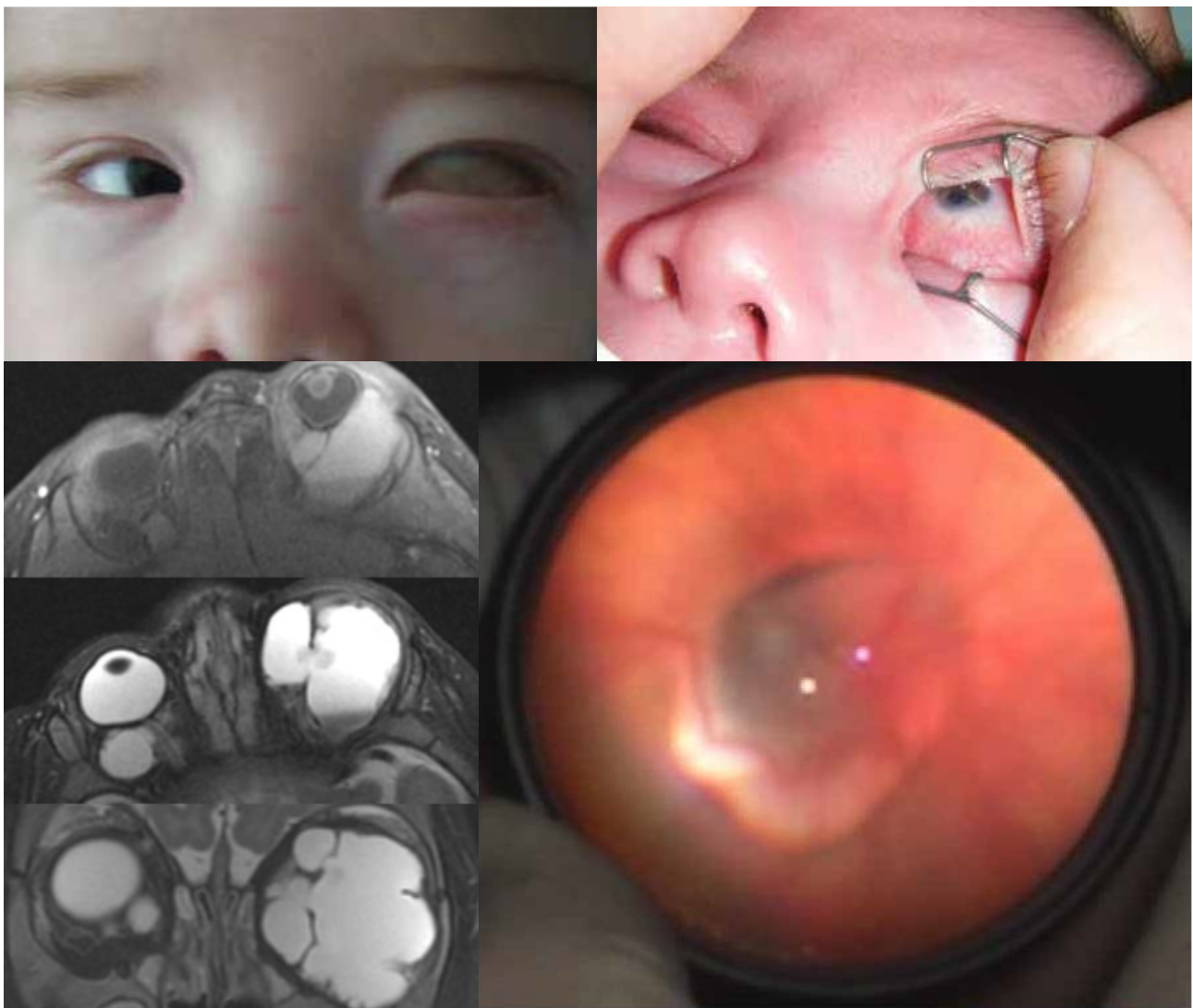

Fig.4: Bilateral orbital cyst with microphthalmos in a 4-months child. Left Inferior eyelid presents a bluish mass, and a severe microphthalmic eye is also evident. Right eye presents an axial length of 17mm, and 9 mm of corneal diameter. A coloboma of the right optic nerve is evident on funduscopy. MR demonstrates a big multilobulated cyst with relation to the optic nerve on the left eye, along with a severe microphthalmos. An enlarged bony left orbit is observed. A small multilobulated cyst is noticed in the right eye, as well as its communication with the optic nerve.

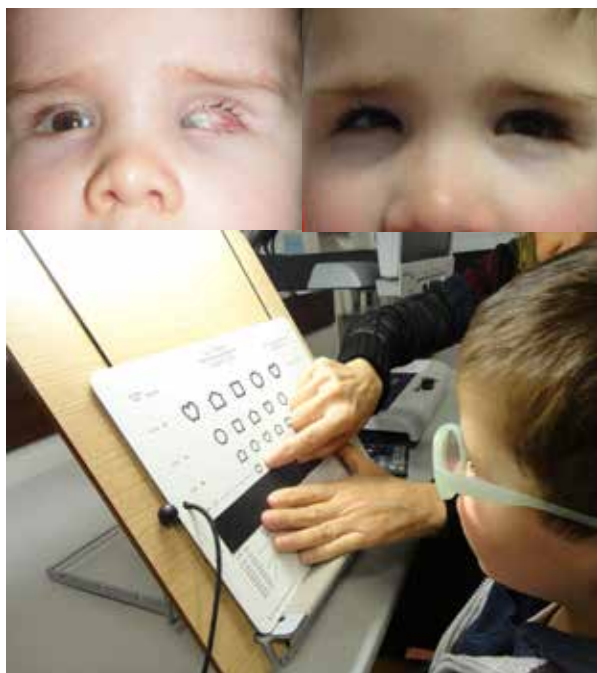

Fig.5: Same child after surgical removal of the left cyst. Microphthalmos was maintained to give volume to the orbit. Despite the low vision, the visual potential is satisfactory with the use of optical aids.

content, enucleation of the cyst and microphthalmos, and excision of the cyst with preservation of the eyeball are some possible approaches. Surgery is reserved for cases presenting severe microphthalmos and a voluminous cyst. In these situations, if the orbital dimensions are not reduced there will be asymmetric bone growth relative to the fellow orbit. Observation is advised if the cyst is small and allows regular orbital growth¹⁸. After surgery, rehabilitation of the anophthalmic cavity should be performed, either with conservative treatment by applying a prosthesis over the microphthalmos, or with surgery.

Vascular tumors

Infantile hemangioma (capillary hemangioma)

According to Mulliken and Glowacki²⁰, hemangiomatous lesions can be defined as vascular channels surrounded by endothelial proliferating cells. Other vascular lesions should not be regarded as neoplasms but rather as development anomalies, and called malformations.

Epidemiology and clinical features

Capillary hemangioma is the most common vascular neoplasm in pediatric patients, and the second most common orbital tumor, considering all etiologies. About 10% of children present these lesions in the first year of life, with 1-3% of newborns being affected. Cephalic and cervical regions are the most common locations (about 60% of hemangiomas)²¹. No hereditary patterns of transmission are known so far. Females are slightly more affected, in a 3:2 proportion, although this is arguable²².

This lesion may be evident at birth, but usually becomes evident by the 6th month of life. Its progression involves three stages: a 10-month proliferative stage, followed by a short stabilization stage and finally a protracted stage of involution, which may last up to 5-7 years, until 10-12 years of age²⁰. In this stage, cellular elements are continuously replaced by fibrofatty tissue, and residual lesions may subside as a scar or telangiectasia.

When there is cutaneous involvement, as happens in most orbit hemangiomas, a red-bluish tumefaction with well-defined borders, resembling a strawberry, is noticed. Deeper-located hemangiomas may occasionally change skin color to a bluish hue, or even cause proptosis. The mass effect can cause several complications, of which amblyopia is the most threatening. Factors related to amblyopia development involve refractive error, strabismus, or deprivation. Other possible complications include bleeding, glaucoma, or corneal ulceration.

One third of these patients present hemangiomas in other sites, either cutaneous or visceral²³. More aggressive variants may trigger consumptive thrombocytopenia, known as Kasabach-Merritt syndrome. Hemangiomas are also a feature of PHACES syndrome (posterior fossa anomalies, hemangiomas of the face, and sternal or ventral developmental anomalies) (Fig. 6).

Imaging

Doppler ultrasonography is useful when diagnosing any vascular lesion. During the proliferative phase, the tumor is generally hyperechoic. Typical features on Doppler echography include >5 vessels/cm², with an intensification in arterial and venous flux speed

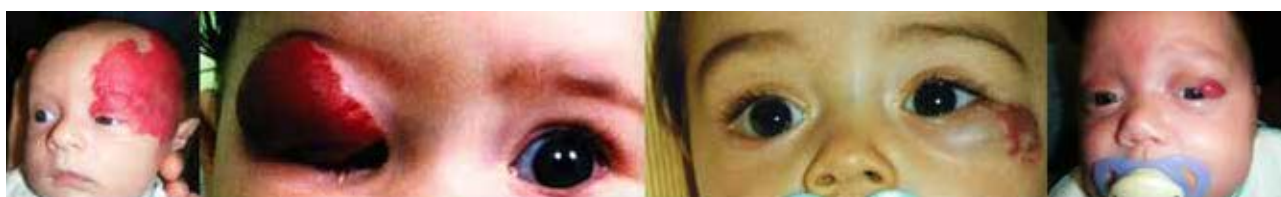

Fig. 6: children with periocular capillary haemangioma.

with simultaneous arterial resistance attenuation. In the proliferative phase, CT shows a lobular homogenous lesion, isoattenuating to muscle, which enhances with contrast injection. Calcified spots are rare but may be seen. During involution, contrast-enhancing decreases as the mass turns increasingly heterogeneous due to the fibrofatty tissue. Bony erosions and depressions are also visible. MR is the best exam to evaluate these masses, due to better contrast and vascular flow sensitivity. Generally, hemangiomas are iso- or hyperintense in T1 series, hyperintense in T2 series, and enhance after gadolinium injection. During involution, fatty tissue appears hyperintense in both T1 and T2 series, while fibrous tissue is hypointense in T2 series.

Treatment and prognosis

Not all capillary hemangiomas (CH) require treatment. On average, only 20% may require treatment when neighboring normal tissues, visual acuity, or even life, in extreme cases, are at stake²⁴. The main indications for treatment are amblyopia, compressive optic neuropathy, exposure keratopathy and aesthetics - where we must take parents' anxiety into account²⁵. Steroid therapy was for many years the gold standard in the treatment of HC. When no response was achieved, other options included interferon, cyclophosphamide, vincristine, laser, endovascular embolization and surgery²⁶. Nevertheless, there was no uniformly effective and safe treatment with the ability to control CH development and growth²⁷. Propranolol usage in CH was discovered accidentally by Léauté-Labrèze in 2008, after two children under steroid treatment for severe hemangiomas developed cardiopulmonary side effects. Propranolol treatment was then initiated, resulting in hemangioma involution²⁸. After this report, several worldwide groups started testing this compound and today propranolol is the first line of treatment for CH²⁹. Propranolol is a non-selective beta-adrenergic receptor antagonist, FDA-approved for systemic hypertension, arrhythmia, headache and angina pectoris, for example. It is now known that hemangioma endothelial cells express surface beta-adrenergic receptors³⁰, but the specific mechanism of action of propranolol is not totally understood. Possible explanations for its therapeutic effect include: the phenomenon of vasoconstriction, as evidenced by the change in the tumor's color and texture in the first days of treatment; downregulation of antiangiogenic factors responsible for the intermediate effects, such as VEGF, bFGF and MMP, and upregulation of apoptosis in the endothelial cells, responsible for the late effects³¹. Beta-blockers are more effective in the initial phase of proliferation³¹, and their safety

and side effects are well documented³². They include bronchospasm, orthostatic hypotension, bradycardia, congestive heart failure, hypoglycemia, cutaneous rash, gastrointestinal discomfort and fatigue³³.

Selective β_1 -blockers may be of some interest when treating this condition, as they can provoke fewer side effects. Atenolol, a selective β_1 -antagonist, is reported to have similar effects with less undesirable symptomatology³⁴. Topical timolol (a non-selective beta-blocker) has also proved its effectiveness in the treatment of localized and superficial CH, with fewer systemic effects. Its efficacy is comparable to oral therapy, to which it can be used as an adjunct^{35, 36}.

In spite of the growing acceptance of propranolol, there is still significant uncertainty and discrepancy of opinions regarding safety monitoring and dose escalation. Currently, there are no uniform guidelines and protocols for treatment³⁷. The most frequently proposed regimen is 2-3 mg/kg/day³¹, although there are reports that lower-dose regimens (1.5-2 mg/kg/day) are effective³⁸. Some authors advocate starting with a lower dose and then increasing it instead of starting with maximum one³¹.

In our protocol, we usually start with a total of 2.5 mg/kg/day of propranolol, twice a day. When treating localized and superficial forms we prefer topical timolol 0.5% (gel), twice a day, with or without systemic propranolol. Propranolol usage in this kind of CH depends on the response to local therapy. Dose is adjusted to the child's weight throughout the total treatment time. An ophthalmologist and a pediatric oncologist are involved in the follow-up of these patients. All patients undergo a cardiology assessment with ECG before treatment. Vital signs and a basic blood analysis are evaluated after the first week of treatment, and then each month until the end of therapy. Patients are admitted to the infirmary within the first 24 h of treatment to monitor possible acute side effects. The duration of this therapy is highly variable, and it can last up to 2 years. The average duration of treatment in our case is 13.6 months for the oral propranolol group and 7.5 months for the topical timolol group. Before stopping treatment, we recommend a slow weaning process over about 2 weeks. It's also important to monitor the evolution of astigmatism and to record the features of the lesion throughout the whole follow-up period. All our patients so far have had an excellent treatment response, with at least 50% reduction in tumor size. Most present merely residual lesions after therapy. As for astigmatism, we also found an over 50% reduction in refractive error in all patients but one. In this case, the probable cause of this under-response was the late introduction of treatment - at 8 months of age. No major

side effects were found. Only minor undesirable effects were registered, such as irritability and sleep disturbances (Fig. 7 to 12).

Surgery still has an important role in CH treatment, particularly when fibrotic scar tissue or residual lesions persist after these lesions involute.

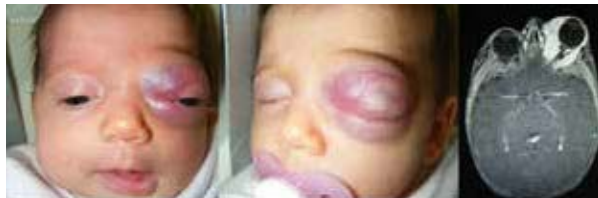

Fig. 7: 1,5-month girl with a mixed (eyelid and orbit) capillary hemangioma.

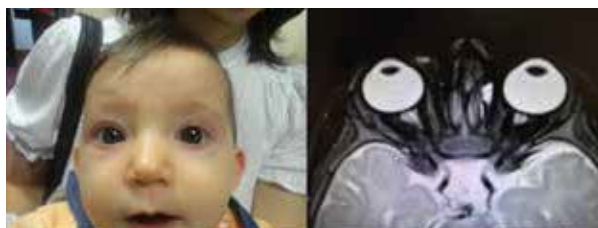

Fig. 8: same girl after 10 months of oral propranolol treatment. MRI demonstrates just a small residual lesion, medial to the globe.

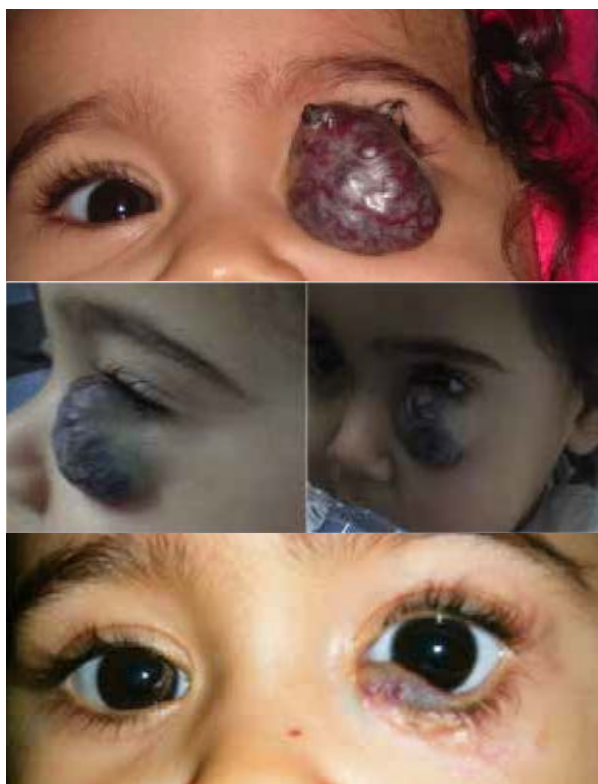

Fig. 9: 10 months girl with an infantile hemangiomas of the inferior left eyelid, with an occluded visual axis.

Fig. 10: Third day after starting oral propranolol therapy. An evident change in colour and texture of the lesion is noticed.

Fig. 11: 14 months after starting oral propranolol, and after surgery.

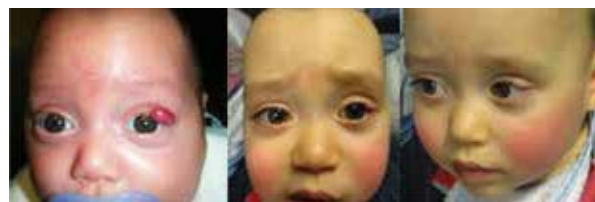

Fig. 12: 4-months boy with a capillary hemangioma of the superior left eyelid. A residual lesion is noted after 12 months of oral and topical b-blocker.

Vascular malformation (lymphangioma)

Mulliken and Glowacki²⁰ affirmed that the term “lymphangioma” did not embrace the venous and lymphatic components of this vascular tumor, and indicate “vascular malformation” as a more accurate expression to classify this lesion. These masses are uncapsulated blood-filled channels lined with endothelial cells. They can be placed in four subgroups in terms of their location: superficial, deep, mixed, or even complex, when anatomical limits such as the orbital septum or conal fascia are breached. We can split them into type 1 (without flux), type 2 (venous flux), and type 3 (arterial flux), according to the flow characteristics. Superficial malformations tend to have a relationship with a lymphatic component, and deeper ones with a venous component³⁹⁻⁴¹.

Epidemiology and clinical features

This vascular malformation mainly affects females, with a ratio of approximately 3:1. They have a congenital etiology and account for 4% of pediatric orbit masses. They generally appear in the first decade of life⁴². In about 70% of cases, homologous intracranial lesions are found⁴³. Superficial lesions tend to be diagnosed earlier than deeper ones. The first manifest as a bluish mass, generally in the superior nasal quadrant of the orbit⁴⁴. Deeper tumors become apparent as acute proptosis after an episode of infection or hemorrhage. Hemorrhage into the lumen of the lesion may be seen in imaging as a chocolate cyst. Moreover, hormonal fluctuations caused by pregnancy or adolescence also can trigger a growth in tumor size. Less common presentations include restriction of ocular movements, pain, diplopia, corneal exposure, amblyopia or compressive optic nerve disease. Visual alterations seldom occur, even with large masses. One exception is the presence of visual complaints after repeated episodes of hemorrhage (Fig. 13 to 15).

Imaging

In echography, a heterogeneous and ill-defined lesion with septa that form pseudocysts, may be seen. This lesion shows low to medium reflectivity in an A-mode ultrasound.

As for CT imaging, we can find calcifications

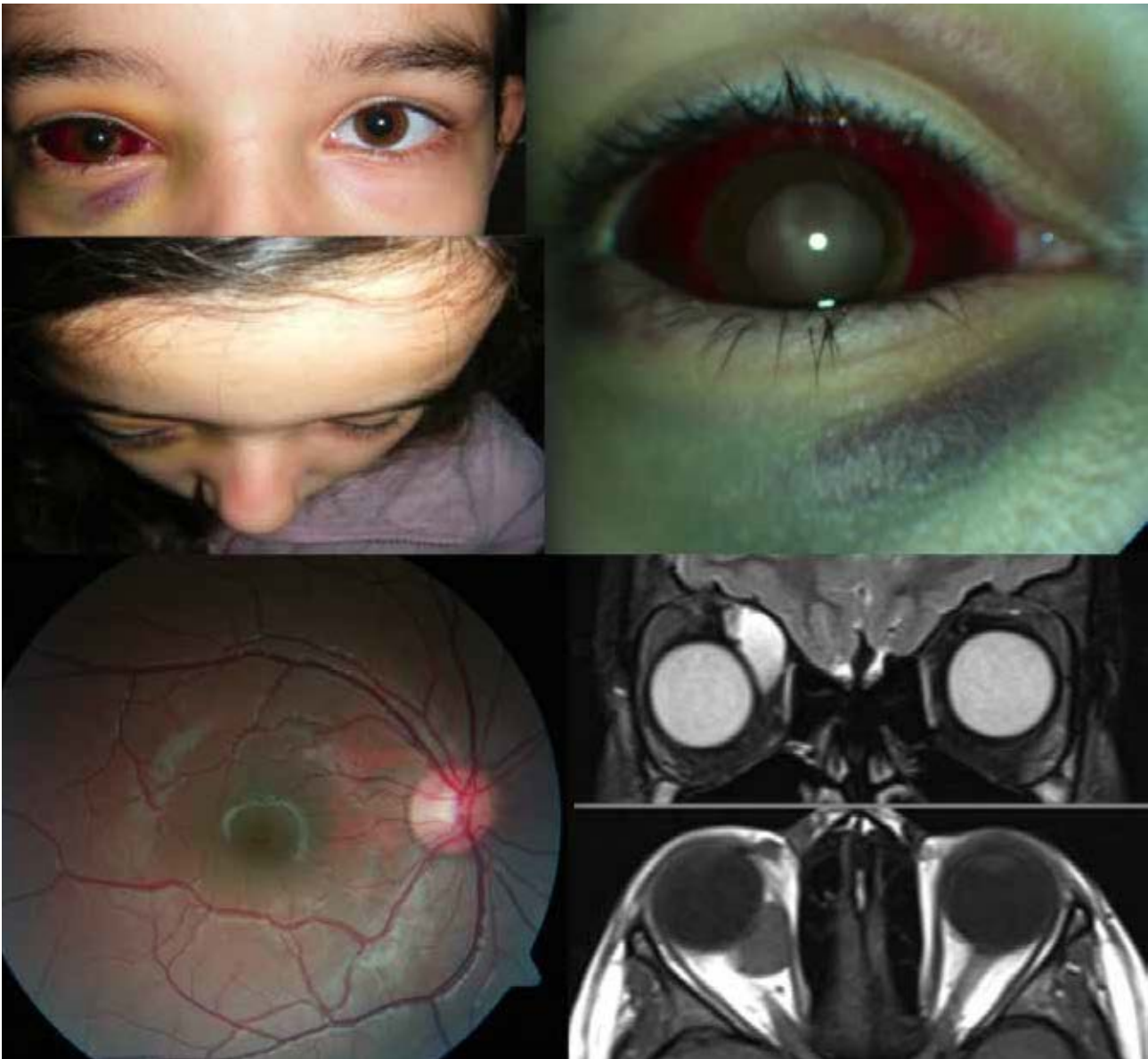


Fig.13: 10-year-old girl presenting with diplopia, subconjunctival hemorrhage, eyelid ecchymosis and non-axial right eye proptosis (Herthel 21mm RI; 18 mm LI) with two days of evolution. No trauma history, normal ophthalmoscopy. MR demonstrates an intra-orbital right mass involving the intraconal and extraconal spaces, specifically between the medial rectus muscle and the optic nerve, showing hypointense signal on T1 and slightly heterogeneous signal in T2, with fluid-fluid levels and peripheral enhancement after contrast.

(phlebolytes) within the lumen of the lesions, as well as bony remodeling caused by the mass effect. Density on CT imaging varies according to the presence and volume of hemorrhage.

MR is the exam of choice when studying vascular malformations. Its sequences give a more reliable definition of tumor margins, distinction of venous and lymphatic components, and identification of fluid-fluid levels or menisci. An RM study should be performed if there is intracranial extension. Normally, the mass is iso- or slightly hyperintense to brain in T1-weighted series and very hyperintense in T2-weighted series. Contrast imaging is heterogeneous. While not enhancing as much as hemangiomas, the cyst septa may enhance. Flow voids are not visible in this type of lesion.

Treatment and prognosis

Surgery is accepted as the standard treatment, but the excision is complicated by the uncapsulated cytoarchitecture of these masses. Often they infiltrate adjacent tissues and bleed profusely, causing painful acute proptosis. The clinical diagnosis of a vascular malformation does not always indicate a surgical approach. Surgery is reserved for cases with optic nerve compression, intolerable pain, or diplopia, for example. Also, factors such as the clinical evolution, age, aesthetics, visual disturbances, surgeon's expertise, and the patient's and parents' expectations must be taken into account. New drugs and treatments have become available in the last few years, including sclerosing therapy with several different compounds. None have yet been approved for this purpose, but

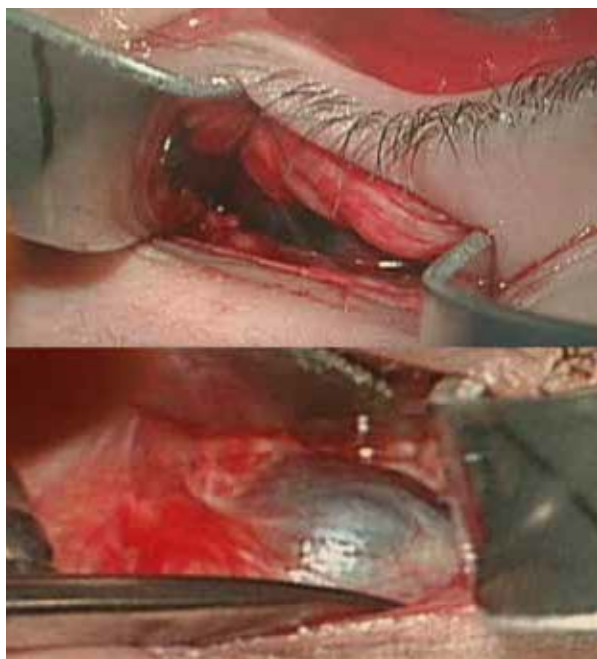


Fig.14: 12mm incision in the superior eyelid crease with marsupialization of lesion, aspiration of the serous and haematic content and capsule excision.

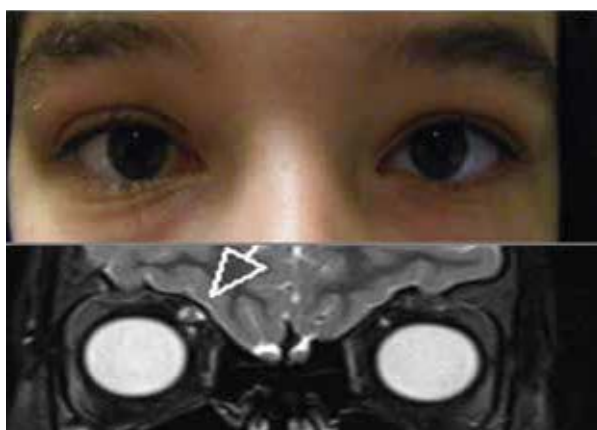


Fig.15: No proptosis or haemorrhage after 3 months of follow up; 20/20 best-corrected visual acuity in both eyes. MRI still demonstrates a small residual fibrotic lesion.

clinical trials are suggesting a decrease of 10-85% in the size of these lesions⁴⁵⁻⁴⁸. The use of fibrin glue has also been studied. This material allows the cystic components to acquire a solid shield, which makes them easier to mobilize and remove^{49, 50}. Surgical treatment can involve drainage, debulking and excision. Anyway, as noted above, complete excision is rarely possible. Recurrence and growth often occur after treatment, despite the absence of malignant features. Chocolate cysts are correlated with higher relapse rates⁵¹. A negative pressure drain may help to reduce recurrence and hemorrhage rates after surgery.

Mesodermic tumors

Rhabdomyosarcoma

Rhabdomyosarcoma is the most common malignant orbital tumor in pediatric patients. It arises in pluripotent mesenchymatous cells, which have the ability to differentiate in striated muscular tissue. We can group these lesions according to their histologic features as embryonal, alveolar, spindle cell and botryoid subtypes. Most have an embryonal histology, which is typical of young ages. The alveolar form is less common and has the worst prognosis.

Epidemiology and clinical features

Rhabdomyosarcoma corresponds to about 5% of all pediatric masses^{52, 53}. One-third have their origin in cephalic and cervical regions. About 25-35% of these, and 10% of all rhabdomyosarcomas, have an orbital location^{54, 55}. It mostly appears in the first decade of life, generally between 6-8 years of age⁴². Males are affected more than females, in a proportion of 5:3⁵⁴. A sudden explosive onset in an otherwise healthy child is a prominent characteristic of this tumor. It features an aggressive presentation with progressive proptosis or dystopia. Lid swelling and chemosis are also common. The increase in proptosis is easily noted when examining the patient on two consecutive days. The superior nasal quadrant is usually affected by the embryonal form, while the alveolar pattern mainly locates to the inferior orbit⁵⁶. Neighboring tissue invasion is frequent: bone in 30-40% of cases, perinasal sinuses in 20% and central nervous system in 3%⁵². Hematogenic dissemination occurs mainly to the lungs and bony tissue⁴². However, orbit-located rhabdomyosarcomas are less infiltrative than those originating elsewhere (Fig. 16 to 19).

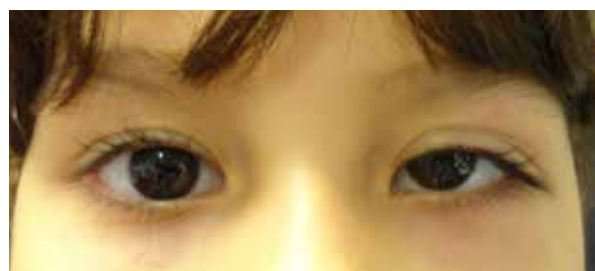

Fig. 16: Left orbital Rhabdomyosarcoma in a 6 years old girl.

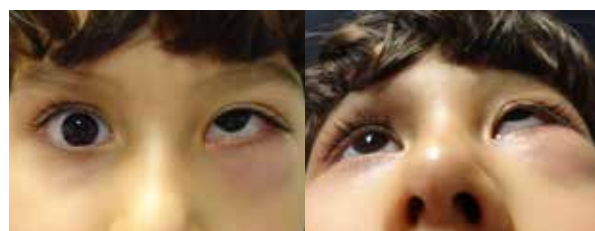

Fig. 17: Same girl one week after the previous foto, demonstrating a rapid progressive proptosis and globe dystopia.

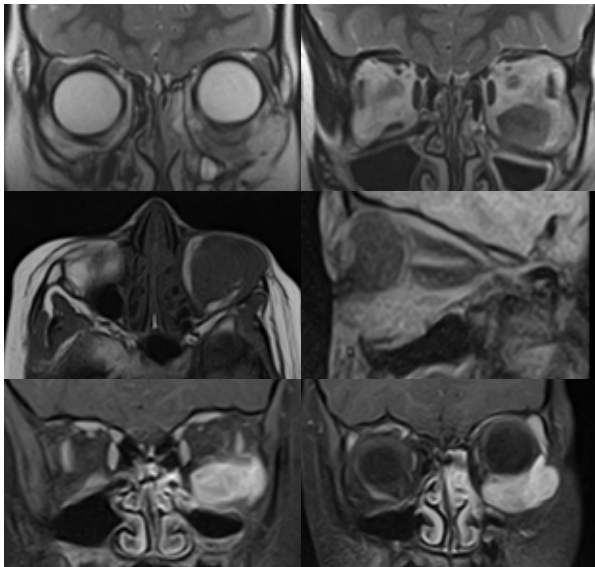


Fig. 18: MR identifies a iso-hyperintense T2 and iso-hypointense T1 inferior orbital lesion, involving the inferior rectus /inferior oblique muscles. No cleavage plane between the lesion and the muscles. After gadolinium relatively marked homogeneous capture is evident.

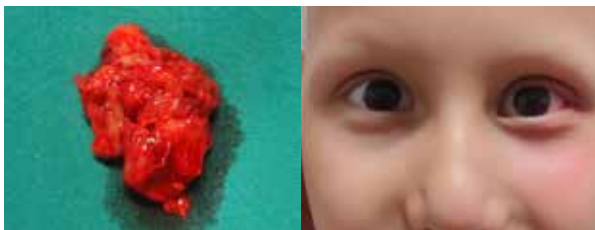

Fig. 19: Same girl after extensive debulking surgery, chemotherapy and radiation.

Imaging

Echography is of little use in the approach of these masses. A heterogeneous lesion with a variable vascular pattern can be perceived.

In CT imaging, it appears as an attenuated-to-muscle area, with ill-defined margins, characteristically when assessing large tumors. Foci of necrosis, hemorrhage or calcification can be recognized. Calcified foci are usually a consequence of bony tissue erosion. Lid swelling can also be identified, even in deep located lesions. Contrast usually enhances these masses in a diffuse or a ring-shaped layout, due to intralesional cavitation. CT is also useful in evaluating metastases. The lesion is isointense to muscle and brain in T1 MR imaging, and hyperintense in T2. When hemorrhagic, hypersignal foci can be observed in both T1 and T2 sequences. Contrast infusion enhances the lesion in T1 and T2 images, making it possible to distinguish between perinasal sinus secretions and tumor infiltration⁵⁷.

Differential diagnosis

A fast growing unilateral proptosis demands ruling

out rhabdomyosarcoma. If accompanied by eyelid edema, the hypothesis of orbital cellulitis should also be kept in mind. Both conditions can present with an orbital mass and involve the perinasal sinuses. Contrast RM allows distinguishing between tumor infiltration and mucous material in the sinuses. Fever and leucocytosis also can help to reach a diagnosis. Interestingly, the enhancing pattern seen in rhabdomyosarcoma sometimes takes the shape of a ring, simulating orbital cellulitis with an abscess. Tearing of a dermoid cyst can trigger an inflammatory response in adjacent tissues that leads to acute proptosis. Nevertheless, a cystoid appearance in imaging series, T1 hyperintensity with calcification, or a zygomaticofrontal fossa instead of erosion, may all help to establish the diagnosis of a ruptured dermoid cyst.

The vascular component of rhabdomyosarcoma can imply a differential diagnosis with a growing capillary hemangioma. Earlier presentation, contrast enhancing, and the typical flow voids indicate a diagnosis of CH.

Infected or hemorrhagic vascular malformations may progress with acute proptosis. A cystic multilobular lesion, occasionally with fluid-fluid levels and phleboliths on image exams, should suggest a diagnosis of vascular malformation.

Neuroblastoma metastasis may also mimic rhabdomyosarcoma. Evidence of a retroperitoneal tumor in CT or MRI sequences easily yields a diagnosis.

Treatment and prognosis

Diagnosis of a tumor requires full systemic work-ups, including a physical examination, chest radiograph, liver function tests, lumbar puncture, and bone marrow biopsy. Management should always involve a pediatric oncologist. The IRSG (Intergroup Rhabdomyosarcoma Study Group) categorizes this lesion into four distinct stages⁵⁵:

- I – complete resection following surgery,
- II – microscopic residual disease following surgery,
- III – macroscopic residual disease following surgery,
- IV – metastatic disease at diagnosis.

Most cases are diagnosed at stage III⁵⁸.

The treatment of orbital rhabdomyosarcoma has improved drastically over the last 20 years, from orbital exenteration to a more conservative approach combining systemic chemotherapy, debulking surgery and radiation. Nowadays, excisional biopsy followed by chemotherapy and radiotherapy is the preferred approach. Treatment side effects include cataracts, retinal degeneration, ptosis, keratoconjunctivitis and facial asymmetry.

The 5-year survival rate is over 90%. Embryonic lesions have better prognosis than the alveolar subtype. The most relevant prognosis factor is treatment

response. Other indicators of a favorable prognosis include localized disease, tumor size <5cm, orbit as primary site of disease, surgical success, age <10 years, and hyperdiploid DNA^{54, 58}.

Neurogenic tumors

Optic nerve glioma

Epidemiology and clinical features

Optic nerve gliomas, also known as juvenile pilocytic astrocytomas, generally appear between 5-9 years of age, and can grow in any segment of the optic nerve. Half of optic nerve gliomas are associated with type 1 neurofibromatosis (Von Recklinghausen's disease), and about 30-58% of the patients with this condition have optic nerve gliomas⁵⁹. When bilateral, coexisting neurofibromatosis is almost certain. Gliomas are seldom malignant or histologically aggressive, therefore they are associated with a later onset of symptoms. Their course is slowly progressive, and the first symptom is usually vision loss. Vision progressively declines as the tumor infiltrates the optic nerve. As the tumor grows, the eye is pushed out and down, with optic nerve atrophy or optic nerve head

swelling. A Marcus Gunn pupil is often present, in association with reduced color sensitivity and defects in campimetry. Disturbed ocular motility can also be found during physical examination (Fig. 20).

Imaging

MRI is the most suitable exam to evaluate smaller sized lesions and intracranial disease. Typical features on imaging include enlargement of the optic canal and cystic degeneration. Typically these lesions are hypointense in T1-weighted and hyperintense in T2-weighted images. Meningiomas, a differential diagnosis, are quickly distinguished as they appear hypointense in T2 images.

Treatment and prognosis

Treatment is controversial, because the glioma can expand, stabilize or regress after diagnosis. Observation is the recommended approach, as long as there is good visual acuity and proptosis is mild, due to the low malignancy of these masses. When the disease is progressing, chemotherapy is the treatment of choice. When chemotherapy fails, radiotherapy should be used. Surgery is reserved for refractory lesions, especially when dealing with a non-viable eye.

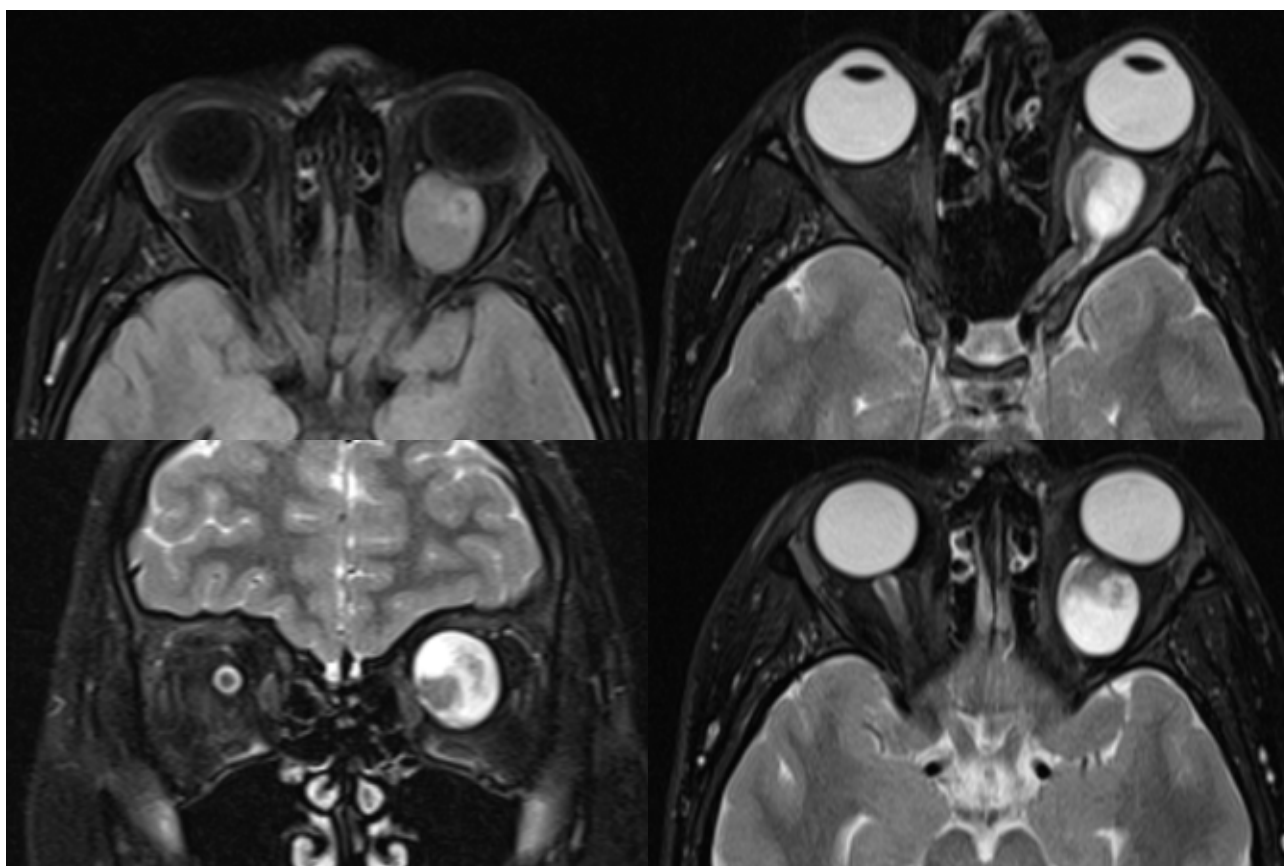


Fig. 20: 10 years old girl with a left optic nerve glioma without type 1 neurofibromatosis. Mild proptosis with 20/40 of vision in the left eye. Left Marcus Gunn present. No evolution in the last 6 years. MR demonstrating an hypointense in T1 and hyperintense in T2 heterogeneous lesion with cystic areas. No intracranial invasion. Left visual fields test with an augmented blind spot.

Plexiform neurofibroma

Epidemiology and clinical features

This ectodermal hamartoma accounts for 1-2% of all orbital masses and comes to the clinician's attention in the first decade of life. Plexiform neurofibromas are always associated with type 1 neurofibromatosis. It traditionally affects sensitive neurons of the orbit but it can be present in almost any peripheral neuron. These non-metastasizing fibrous tumors invade locally and recur frequently.

They are generally located in the eyelids and generate a characteristic S-shaped deformity in the superior eyelid. They are easily depressible, with a consistency described as similar to a "bag of worms". Larger ones can cause amblyopia by privation (ptosis), but also by refractive error and strabismus. They can affect the rest of the periorbital soft tissue and face, causing thickening, hypertrophy, and varying degrees of facial disfigurement. Deeper lesions can present with proptosis, superior orbital fissure expansion or dysplasia of the greater wing of the sphenoid, which

can lead to temporal lobe herniation and pulsatile exophthalmos with possible vision impairment⁶⁰. The natural course is slowly progressive with centripetal growth along the nerve of origin (Fig. 21, 22).

Imaging

In imaging exams, plexiform neurofibromas appear as ill-defined and irregular masses that infiltrate the eyelids, but also the orbit and other facial regions. Swelling of soft tissue, sclera or choroid are quite often seen, as well as nodules on the fascia of the optic nerve⁶¹. This tumor can also invade sensitive neurons, extra-ocular muscles, bony structures and the lacrimal gland. MRI is better than CT when evaluating a possible extension into adjacent tissues. Neurofibromas appear as a hypointense mass in T1 and hyperintense in T2 imaging. After contrast injection, these masses enhance diffusely and heterogeneously.

Treatment and prognosis

Growth with facial disfiguration may continue after the diagnosis. Complete excision is rarely

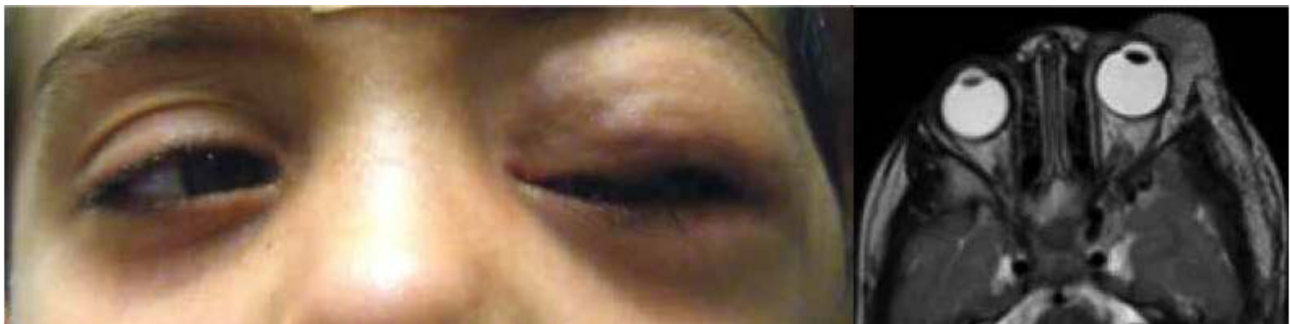

Fig. 21: Left palpebral and orbital neurofibroma in a 5-year-old child with type 1 Neurofibromatosis. MR ill-defined irregular mass compatible with plexiform neurofibroma infiltrating left superior eyelid, lateral cantus with posterior extension to the orbit; anterior auricular neurofibroma; bilateral optic nerve, chiasm and optical tracks gliomas.

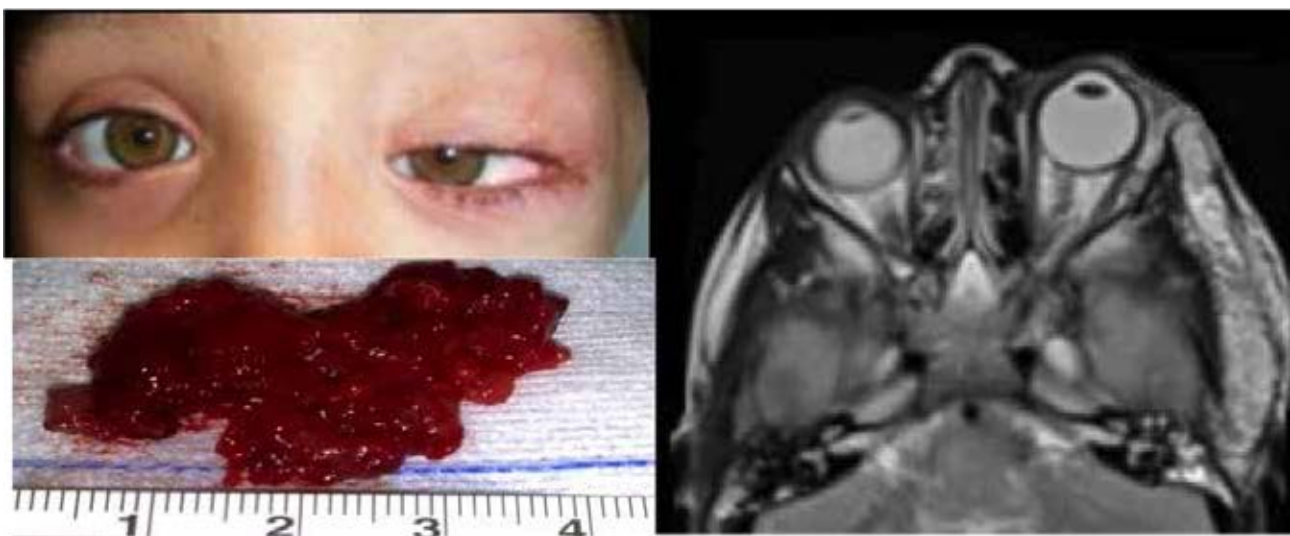


Fig. 22: Same patient after debulking surgery through superior eyelid crease with a free visual axis. MR after surgery with evident mass reduction.

29. Pediatric Orbital Tumors

accomplished, and therefore treatment is symptom-related. It usually comprises a debulking procedure to widen the eyelid fissure, and is also recommended in cases of severe disfigurement. Ipsilateral glaucoma risk is about 50%, and in 7-10% of cases there is progression to malignant sarcoma⁶².

Metastatic tumors

Neuroblastoma

Epidemiology and clinical features

Neuroblastoma is an undifferentiated malignant tumor of the primitive neuroblasts, which can be metastatic to the orbit. Neuroblastoma metastases are the ones that most often affect this site (20%)⁶³. It is the second commonest malignant orbital tumor in children, after rhabdomyosarcoma. The most common primary tumor site is the abdomen, but primary orbital neuroblastomas have been reported occasionally⁶⁴. They have their origin in neural crest cells, a prevalence of 0.9/100,000, and 42% are diagnosed within the first year of life⁶⁵. When orbital metastases are present, the diagnosis is usually made later, at around 2 years of age.

It typically presents as a rapid progressive unilateral or bilateral proptosis with periorbital ecchymosis (“racoon eye”). Clinical features also include ptosis, periorbital edema, hemorrhage, strabismus, and optic nerve atrophy⁵. Horner’s syndrome may also be evident if there is sympathetic nervous system commitment. The commonest location for these masses is the posterior lateral wall of the orbit, and bony lytic lesions are sometimes associated with them. Diagnostic procedures include catecholamine quantification in urine and work-up for specific tumor markers such as MYCN oncogene (Fig. 23).

Imaging

Echography is of limited use when evaluating these masses.

In CT images, neuroblastoma metastases can present well or ill-defined margins, attenuated to muscle, sometimes with intrinsic calcifications. Intracranial extension of the tumor can also be assessed.

As for MRI, these lesions characteristically appear as hypointense areas in T1 and heterogeneous in T2 imaging, because of hemorrhage or necrosis. These events also explain the occasional enhancement after contrast injection. Adjacent tissue extension is more easily evaluated with MRI than CT.

Treatment and prognosis

The prognosis in neuroblastoma is mainly influenced by age, stage, and site of origin. Children

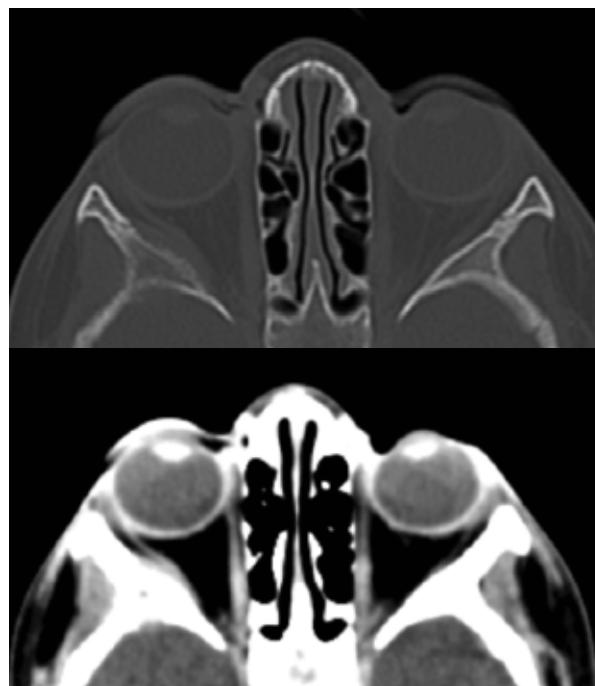


Fig. 23: 18 months child with a neuroblastoma presenting a right orbital soft tissue and bone metastasis, located in the posterior lateral wall. On the MRI it is observed a loss of cortical bone definition on the external wall of the right orbit, adjacent to the medial rectus muscle, with discreet soft tissue component associated, making a slight moulding of that muscle. No mass effect is evident on the remaining orbital structures.

diagnosed with metastatic neuroblastoma before 12 months of age have better survival rates (80% at 5 years) than those over a year old (45% survival at 5 years)². Early diagnosis is an important factor that shapes the prognosis. The ophthalmologist plays a major role here, since ophthalmologic involvement is possible. Treatment consists of multimodal therapy, including multiagent chemotherapy, radiation therapy, surgery, stem cell transplantation, immunotherapy, and differentiation therapy.

Leukemia

Epidemiology and clinical features

Leukemia is the most common systemic malignancy seen in children, with acute lymphoblastic leukemia (ALL) accounting for approximately 80% of all cases and acute myeloid leukemia (AML) for the other 20%. The orbit may be affected in all types of leukemia, but its involvement is more likely in AML. In this scenario, the development of a solid tumor consisting of primitive granulocyte precursors is called a granulocytic (or myeloid) sarcoma. Its green appearance, resulting from a reaction between myeloperoxidase and ultraviolet light, explains why it is called “green tumor”. Myeloid sarcoma is quite rare among orbital tumors of

childhood and accounts for only 1 in 250 cases¹. The mass usually appears before hematologic evidence of leukemia, but it also can grow simultaneously or afterwards. The common feature is a rapidly increasing orbital mass, which can cause pain, eyelid swelling, ecchymosis, diplopia, and proptosis. Granulocytic sarcomas typically consist of an irregular homogeneous mass next to the temporal wall of the orbit and encase rather than invade the adjacent lacrimal gland and extraocular muscles (Fig. 24).

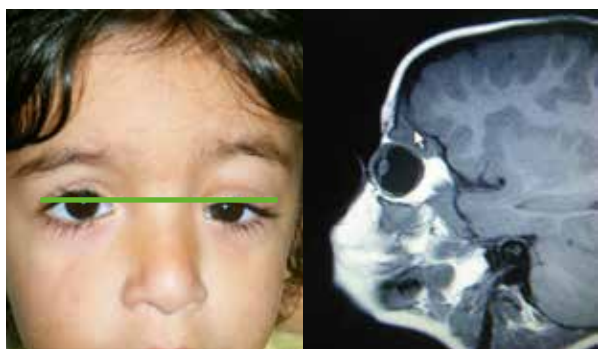


Fig. 24: 3 years old child with a non-axial proptosis and mechanical ptosis of the left eye secondary to a granulocytic sarcoma in the context of an acute myeloid leukemia. MRI demonstrating a soft orbital superior mass iso-intense to muscle.

Imaging

CT and/or MRI studies are often sufficient to diagnosis a granulocytic sarcoma. However, when a diagnosis of leukemia is not yet available, proper distinction between this tumor and rhabdomyosarcoma or neuroblastoma can be difficult. In such circumstances a biopsy is mandatory.

A soft tissue mass, isointense to muscle, with minimal bony erosion and subperiosteal reaction can be perceived in CT imaging.

In MRI, the mass is iso- to hypointense to muscle on T1-weighted sequences, and heterogeneously iso- to hyperintense on T2-weighted sequences. This mass enhances mildly after gadolinium injection.

Treatment and prognosis

Management depends on the patient's leukemic status. Treatment is guided by the pediatric oncologist and involves multiagent chemotherapy, with or without supporting radiation therapy. A bone marrow transplant should be considered, if possible. Radiation is indicated when optic neuropathy develops despite previous treatments. Although the overall survival rate for patients with leukemia has improved over the past 3 decades, the mortality of patients who have developed orbital leukemic tumors unfortunately remains high (55% survival rate)⁶⁶.

References

1. Shields JA, Bakewell B, Augsburger JJ, Donoso LA, Bernardino V. Space-occupying orbital masses in children. A review of 250 consecutive biopsies. *Ophthalmology*. 1986;93(3):379-84.
2. Rao AA, Naheedy JH, Chen JY, Robbins SL, Ramkumar HL. A clinical update and radiologic review of pediatric orbital and ocular tumors. *Journal of oncology*. 2013;2013:975908.
3. Bullock JD, Goldberg SH, Rakes SM. Orbital tumors in children. *Ophthalmic plastic and reconstructive surgery*. 1989;5(1):13-6.
4. Shields JA, Shields CL. Orbital cysts of childhood--classification, clinical features, and management. *Survey of ophthalmology*. 2004;49(3):281-99.
5. Chung EM, Murphey MD, Specht CS, Cube R, Smirniotopoulos JG. From the Archives of the AFIP. Pediatric orbit tumors and tumorlike lesions: osseous lesions of the orbit. *Radiographics : a review publication of the Radiological Society of North America, Inc*. 2008;28(4):1193-214.
6. Wells TS, Harris GJ. Orbital dermoid cyst and sinus tract presenting with acute infection. *Ophthalmic plastic and reconstructive surgery*. 2004;20(6):465-
7. Neudorfer M, Leibovitch I, Stolvitch C, Dray JP, Hermush V, Nagar H, et al. Intraorbital and periorbital tumors in children--value of ultrasound and color Doppler imaging in the differential diagnosis. *American journal of ophthalmology*. 2004;137(6):1065-72.
8. Shields JA. Orbital dermoid cysts. Clinicopathologic correlations, classification, and management. *Ophthalmic plastic and reconstructive surgery*. 1997;13:265-76.
9. DePotter, Shields CL, Shields JA. *MRI of the eye and orbit*. JB Lippincott Co. 1995:119-29.
10. Penn S, Dunbar M. Orbital tumours in children. *Clinical eye and vision care*. 1999:195-204.
11. Nelson KE, Mishra A, Duncan C. Upper blepharoplasty approach to frontozygomatic dermoid cysts. *The Journal of craniofacial surgery*. 2011;22(6):e41-4.
12. Ruszkowski A, Caouette-Laberge L, Bortoluzzi P, Egerszegi EP. Superior eyelid incision: an alternative approach for frontozygomatic dermoid cyst excision. *Annals of plastic surgery*. 2000;44(6):591-4; discussion 4-5.
13. Leonardo D, Shields CL, Shields JA, Nelson LB. Recurrent giant orbital dermoid of infancy. *Journal of pediatric ophthalmology and strabismus*. 1994;31(1):50-2.
14. Holds JB, Anderson RL, Mamalis N, Kincaid MC, Font RL. Invasive squamous cell carcinoma arising from asymptomatic choristomatous cysts of the orbit. Two cases and a review of the literature. *Ophthalmology*. 1993;100(8):1244-52.
15. Nunes T, Ben-Ayed H, Hamedani M, Morax S, Matayoshi S. Microftalmia com cisto colobomatoso orbitário - relato de casos. *Arq Bras Oftalmol*. 2004;549-62.
16. Weiss A, Martinez C, Greenwald M. Microphthalmos with cyst: clinical presentations and computed tomographic findings. *Journal of pediatric ophthalmology and strabismus*. 1985;22(1):6-12.
17. Yoshihara M, Ishizawa A, Sato K, Tamaki H. Bilateral microphthalmos with orbital cyst--case report. *Neurologia medico-chirurgica*. 1991;31(4):223-5.
18. Pérez Moreiras J, Prada Sánchez M. *Patología orbitaria*. 2002(Edika Med).
19. Polito E, Leccisotti A. Colobomatous ocular cyst excision with globe preservation. *Ophthalmic plastic and reconstructive surgery*. 1995;11(4):288-92.
20. Mulliken JB, Glowacki J. Hemangiomas and vascular malformations in infants and children: a classification based

- on endothelial characteristics. Plastic and reconstructive surgery. 1982;69(3):412-22.
21. Dubois J, Garel L. Imaging and therapeutic approach of hemangiomas and vascular malformations in the pediatric age group. *Pediatric radiology*. 1999;29(12):879-93.
 22. Haik BG, Karcioğlu ZA, Gordon RA, Pechous BP. Capillary hemangioma (infantile periocular hemangioma). *Survey of ophthalmology*. 1994;38(5):399-426.
 23. Haik BG, Jakobiec FA, Ellsworth RM, Jones IS. Capillary hemangioma of the lids and orbit: an analysis of the clinical features and therapeutic results in 101 cases. *Ophthalmology*. 1979;86(5):760-92.
 24. Schwartz SR, Blei F, Ceisler E, Steele M, Furlan L, Kodsi S. Risk factors for amblyopia in children with capillary hemangiomas of the eyelids and orbit. *Journal of AAPOS : the official publication of the American Association for Pediatric Ophthalmology and Strabismus / American Association for Pediatric Ophthalmology and Strabismus*. 2006;10(3):262-8.
 25. Ni N, Guo S, Langer P. Current concepts in the management of periocular infantile (capillary) hemangioma. *Current opinion in ophthalmology*. 2011;22(5):419-25.
 26. Cornish S, Reddy A. The use of propranolol in the management of periocular capillary haemangioma: a systematic review. *Eye (Lond)*. 2011;1277-83.
 27. Nguyen J, Fay A. Pharmacologic therapy for periocular infantile hemangiomas: a review of the literature. *Semin Ophthalmol*. 2009;178-84.
 28. Leaute-Labreze C, Dumas de la Roque E, Hubiche T, Boralevi F, Thambo JB, Taieb A. Propranolol for severe hemangiomas of infancy. *The New England journal of medicine*. 2008;358(24):2649-51.
 29. Thoumazet F, Leaute-Labreze C, Colin J, Mortemousque B. Efficacy of systemic propranolol for severe infantile haemangioma of the orbit and eyelid: a case study of eight patients. *The British journal of ophthalmology*. 2012;96(3):370-4.
 30. Dunn A, Zeidler K, Devic Z, Kuri M, Belek K, Kuo J, et al. Propranolol inhibits tubulogenesis in endothelioma cells and alters the expression of angiogenic genes in infantile hemangiomas. *Plastic and reconstructive surgery*. 2010;125.
 31. Storch CH, Hoeger PH. Propranolol for infantile haemangiomas: insights into the molecular mechanisms of action. *The British journal of dermatology*. 2010;163(2):269-74.
 32. Salazar-Murillo R, Garcia-Pacheco S, Gonzalez-Blanco MJ, Bolivar-Montesa P, Campos-Garcia S. [Propranolol: Treatment of capillary hemangioma with orbital involvement]. *Archivos de la Sociedad Espanola de Oftalmologia*. 2012;87(12):411-4.
 33. Zimmermann AP, Wiegand S, Werner JA, Eivazi B. Propranolol therapy for infantile haemangiomas: review of the literature. *International journal of pediatric otorhinolaryngology*. 2010;74(4):338-42.
 34. de Graaf M, Raphael MF, Breugem CC, Knol MJ, Bruijnzeel-Koomen CA, Kon M, et al. Treatment of infantile haemangiomas with atenolol: comparison with a historical propranolol group. *Journal of plastic, reconstructive & aesthetic surgery : JPRAS*. 2013;66(12):1732-40.
 35. Chakkittakandiyil A, Phillips R, Frieden IJ, Siegfried E, Lara-Corrales I, Lam J, et al. Timolol maleate 0.5% or 0.1% gel-forming solution for infantile hemangiomas: a retrospective, multicenter, cohort study. *Pediatric dermatology*. 2012;29(1):28-31.
 36. Guo S, Ni N. Topical treatment for capillary hemangioma of the eyelid using beta-blocker solution. *Archives of ophthalmology*. 2010;128(2):255-6.
 37. Drolet B, Frommelt P, Chamlin S, Haggstrom A, Bauman N, Chiu Y, et al. Initiation and Use of Propranolol for Infantile Hemangioma: Report of a Consensus Conference. *Pediatrics*. 2013;131(128).
 38. Tan CE, Itinteang T, Leadbitter P, Marsh R, Tan ST. Low-dose propranolol regimen for infantile haemangioma. *Journal of paediatrics and child health*. 2014.
 39. Katz SE, Rootman J, Vangveeravong S, Graeb D. Combined venous lymphatic malformations of the orbit (so-called lymphangiomas). Association with noncontiguous intracranial vascular anomalies. *Ophthalmology*. 1998;105(1):176-84.
 40. Wright JE, Sullivan TJ, Garner A, Wulc AE, Moseley IF. Orbital venous anomalies. *Ophthalmology*. 1997;104(6):905-13.
 41. Rootman J, Hay E, Graeb D, Miller R. Orbital-adnexal lymphangiomas. A spectrum of hemodynamically isolated vascular hamartomas. *Ophthalmology*. 1986;93(12):1558-70.
 42. Shields JA, Shields CL, Scartozzi R. Survey of 1264 patients with orbital tumors and simulating lesions: The 2002 Montgomery Lecture, part 1. *Ophthalmology*. 2004;111(5):997-1008.
 43. Bisdorff A, Mulliken JB, Carrico J, Robertson RL, Burrows PE. Intracranial vascular anomalies in patients with periorbital lymphatic and lymphaticovenous malformations. *AJNR American journal of neuroradiology*. 2007;28(2):335-41.
 44. Volpe NJ, Jakobiec FA. Pediatric orbital tumors. *International ophthalmology clinics*. 1992;32(1):201-21.
 45. Suzuki Y, Obana A, Gohto Y, Miki T, Otuka H, Inoue Y. Management of orbital lymphangioma using intralesional injection of OK-432. *The British journal of ophthalmology*. 2000;84(6):614-7.
 46. Poonyathalang A, Preechawat P, Jiarakongmun P, Pongpech S. Sclerosing therapy for orbital lymphangioma using sodium tetradecyl sulfate. *Japanese journal of ophthalmology*. 2008;52(4):298-304.
 47. Schwarcz RM, Ben Simon GJ, Cook T, Goldberg RA. Sclerosing therapy as first line treatment for low flow vascular lesions of the orbit. *American journal of ophthalmology*. 2006;141(2):333-9.
 48. Hill RH, 3rd, Shiels WE, 2nd, Foster JA, Czyz CN, Stacey A, Everman KR, et al. Percutaneous drainage and ablation as first line therapy for macrocystic and microcystic orbital lymphatic malformations. *Ophthalmic plastic and reconstructive surgery*. 2012;28(2):119-25.
 49. Boulos PR, Harissi-Dagher M, Kavalec C, Hardy I, Codere F. Intralesional injection of Tisseel fibrin glue for resection of lymphangiomas and other thin-walled orbital cysts. *Ophthalmic plastic and reconstructive surgery*. 2005;21(3):171-6.
 50. Hayasaki A, Nakamura H, Hamasaki T, Makino K, Yano S, Morioka M, et al. Successful treatment of intraorbital lymphangioma with tissue fibrin glue. *Surgical neurology*. 2009;72(6):722-4; discussion 4.
 51. Tunc M, Sadri E, Char DH. Orbital lymphangioma: an analysis of 26 patients. *The British journal of ophthalmology*. 1999;83(1):76-80.
 52. Shields CL, Shields JA, Honavar SG, Demirci H. Primary ophthalmic rhabdomyosarcoma in 33 patients. *Transactions of the American Ophthalmological Society*. 2001;99:133-42; discussion 42-3.
 53. Crist WM, Anderson JR, Meza JL, Fryer C, Raney RB, Ruymann FB, et al. Intergroup rhabdomyosarcoma study-IV: results for patients with nonmetastatic disease. *Journal of clinical oncology : official journal of the American Society of Clinical Oncology*. 2001;19(12):3091-102.
 54. Shields JA, Shields CL. Rhabdomyosarcoma: review

- for the ophthalmologist. *Survey of ophthalmology*. 2003;48(1):39-57.
55. Maurer HM, Beltangady M, Gehan EA, Crist W, Hammond D, Hays DM, et al. The Intergroup Rhabdomyosarcoma Study-I. A final report. *Cancer*. 1988;61(2):209-20.
 56. Sohaib SA, Moseley I, Wright JE. Orbital rhabdomyosarcoma--the radiological characteristics. *Clinical radiology*. 1998;53(5):357-62.
 57. Mafee MF, Pai E, Philip B. Rhabdomyosarcoma of the orbit. Evaluation with MR imaging and CT. *Radiologic clinics of North America*. 1998;36(6):1215-27, xii.
 58. Font R, Croxatto J, Rao N. Tumors of the orbit. In: Silverberg S, Robin L, eds. *AFIP atlas of tumor pathology: tumors of the eye and ocular adnexa*. 2006:265-319.
 59. Chung EM, Specht CS, Schroeder JW. From the archives of the AFIP: Pediatric orbit tumors and tumorlike lesions: neuroepithelial lesions of the ocular globe and optic nerve. *Radiographics : a review publication of the Radiological Society of North America, Inc.* 2007;27(4):1159-86.
 60. Jost SC, Ackerman JW, Garbow JR, Manwaring LP, Gutmann DH, McKinstry RC. Diffusion-weighted and dynamic contrast-enhanced imaging as markers of clinical behavior in children with optic pathway glioma. *Pediatric radiology*. 2008;38(12):1293-9.
 61. Dutton J, Escaravage G. *Ophthalmic Oncology* (edited by B. Esmaeli), Springer, USA. 2011.
 62. Filippi CG, Bos A, Nickerson JP, Salmela MB, Koski CJ, Cauley KA. Magnetic resonance diffusion tensor imaging (MRDTI) of the optic nerve and optic radiations at 3T in children with neurofibromatosis type I (NF-1). *Pediatric radiology*. 2012;42(2):168-74.
 63. Gunalp I, Gunduz K. Metastatic orbital tumors. *Japanese journal of ophthalmology*. 1995;39(1):65-70.
 64. Mirzai H, Baser EF, Tansug N, Nese N, Isisag A. Primary orbital neuroblastoma in a neonate. *Indian journal of ophthalmology*. 2006;54(3):206-8.
 65. Gutierrez JC, Fischer AC, Sola JE, Perez EA, Koniaris LG. Markedly improving survival of neuroblastoma: a 30-year analysis of 1,646 patients. *Pediatric surgery international*. 2007;23(7):637-46.
 66. Bidar M, Wilson MW, Laquis SJ, Wilson TD, Fleming JC, Wesley RE, et al. Clinical and imaging characteristics of orbital leukemic tumors. *Ophthalmic plastic and reconstructive surgery*. 2007;23(2):87-93.

30. Ocular Prosthesis

Cecília Ramos, Guilherme Castela

1. Introduction

The eye is a vital organ not only in terms of vision, as an important element of facial expression, but also as the first point of contact between people¹. The partial or total loss of an eye impairs the patient's visual function and also results in a noticeable deformity. It may have a severe emotional and psychological impact on the patient². A prosthesis should be provided as early as possible to improve the patient's aesthetics and restore and maintain health of the remaining structures, thereby providing physical and mental well-being³.

A multidisciplinary team approach is important in the accurate and effective rehabilitation and follow-up care for patients with an anophthalmic cavity. Therefore, the combined efforts of the ophthalmologist and the ocularist are essential to restore the patient's quality of life⁴.

2. What is an ocularist?

An ocularist is a carefully trained professional who is skilled in the science and art of fitting, making and painting ophthalmic prostheses (artificial eyes). In addition to creating it, the ocularist shows patients how to handle and care for their prosthesis, and provides long-term care through periodic examinations and replacements⁵.

3. History of artificial eyes

Artificial eyes have been made since ancient times. The first ocular prostheses were made by Roman and Egyptian priests as early as the fifth century B.C. In those days, artificial eyes were made of painted clay attached to cloth and worn outside the socket.

It took many centuries for the first in-socket artificial eyes to be developed. At first, they were made of gold with colored enamel. Then, in the later part of the sixteenth century, the Venetians started making artificial eyes out of glass. These early glass eyes were crude, uncomfortable to wear, and very fragile. Even so, the Venetians continued making them and kept their methods secret until the end of the eighteenth century. After that, the center for artificial eye-making shifted to Paris for a time, but by the

mid-nineteenth century German glass-blowers had developed superior techniques, and the center for glass eye-making moved to Germany.

Shortly afterwards, glass eye-making was introduced in the United States. Because of World War II, the imported German glass used for glass prostheses was no longer available in the U.S.A. As a result of this shortage, the U.S. Government joined forces with a number of American firms to develop techniques for making artificial eyes out of acrylic plastic, the material that is still used today⁶.

4. Types of prosthesis

A prosthesis is an artificial device used to replace a missing body part. The prostheses used to improve the cosmetic appearance of the orbital region can be broadly classified as ocular and orbital prostheses⁷. Ocular prostheses can be further classified into stock and custom prostheses, with the latter referring to tailor-made prostheses^{8,9}.

Classification of ocular and orbital prostheses:

Ocular

- ✓ Prosthetic contact lens
- ✓ Scleral shell
- ✓ Full thickness prosthesis

Orbital

- ✓ Partial
- ✓ Complete
 - Spectacle mounted prosthesis
 - Adhesive retained prosthesis
 - Magnetic retained prosthesis

A. Prosthetic contact lens

Prosthetic contact lenses are fitted over scarred corneas with partial/total discoloration of the cornea. A wide variety of soft and semi-soft contact lenses are available for cosmetic use¹⁰ (Fig. 1,2).

B. Scleral shell versus full thickness ocular prosthesis

Kelly et al., defined a scleral shell as any ocular prosthetic device fitted over a residual globe like phthisis bulbi, atrophic bulbi or microphthalmos. It

30. Ocular Prosthesis

is less than 1.5 mm thick, which is less than the full thickness ocular prosthesis (Fig. 3).



Fig. 1 – The different types of prosthetic contact lens.

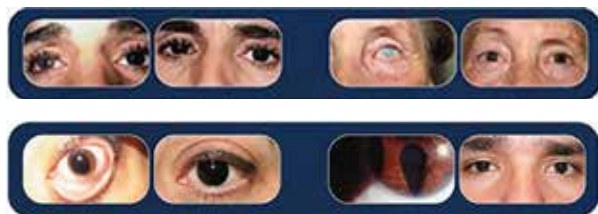

Fig. 2 - Prosthetic Contact Lenses are used in patients with corneal disfigurements, corneal scarring and de-centered pupils.



Fig. 3 – Scleral shell.

C. Orbital prosthesis

An orbital prosthesis is fitted when there is additional loss of periocular tissues like eyelids, eyelashes and eyebrows. When an orbital prosthesis is made, the utmost care is taken not only to replace lost periocular tissue but also to ensure a match in terms of the color and texture of the fellow orbit (Fig. 4).



Fig. 4 – Orbital prosthesis.

5. Material used in prosthetic devices

- ✓ Glass
- ✓ Polymethylmethacrylate (PMMA)
- ✓ Silicone

Glass was once the prosthetic material of choice, but because it is both difficult to mold and fragile it is seldom used today. However, glass eyes are still made in some parts of Europe. Modern ocular prostheses are produced using polymethylmethacrylate. The ease with which it can be molded into any desired shape and its intrinsically inert nature make it the material of choice for ocular prostheses.

Silicone is the best material for the orbital prosthesis with periocular skin and pattern. It is nonreactive, it molds easily and above all the desired skin texture can be created on the surface^{7, 10}.

6. Custom versus stock prostheses

“Stock” or “ready-made” ocular prostheses are mass-produced. Since a “stock eye” is not made for any particular person, it doesn’t fit any particular patient. A “custom” ocular prosthesis, on the other hand, is individually made by the ocularist for each patient.

Poor apposition between a stock prosthesis and the surface leads to unequal weight distribution and constant irritation of the surface. This presents as chronic discharge and laxity of the lower eyelid in the long term. A custom molded prosthesis, however, allows even distribution of volume and weight in the socket to give better cosmetic appearance and less discomfort to the patient over time. Moreover, it allows correction of a deep superior sulcus, mild degrees of blepharoptosis and better cosmetic results in sockets with cicatricial bands (fig. 5).

With respect to the empirical fitting of an ocular prosthesis where the prosthesis should be tightly fitted as close as possible, in the case of a “stock” prosthesis vaulted spaces are left in the cavity, leading to pooling of the tears and mucous secretion. As time passes, the patient with this prosthesis starts feeling heaviness in the cavity and ends up removing the prosthesis from the cavity. A custom-made modified impression-based prosthesis provides a very close contact with the socket. They fit well with orbital soft tissue and leave no space for pooling and accumulation of tear fluid. Moreover, the close contact with orbital tissue helps to adapt the socket and thus reduces mucous secretion from the cavity^{5, 8, 9}.

7. When should the patient see an ocularist?

At the end of the surgery, an acrylic conformer is often placed in the socket to help the healing process of the tissues⁸. With most new patients, a first visit is required within one to two months after surgery. This will give time to adjust the prosthesis to the

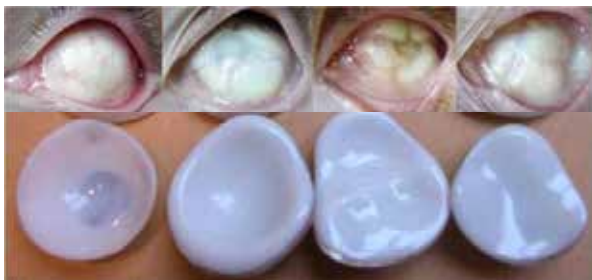

Fig. 5 – Custom prosthesis.

tissues of the socket and to eliminate any edema (swelling). Often, the patient is ready for the fitting of a custom prosthesis after 6 to 8 weeks⁵. According to the American Academy of Ophthalmology, two of the most difficult challenges for ophthalmologists and ocularists are working with superior sulcus deformities and ptosis of the lids.

8. Ocular conformers (Fig. 6):



Fig. 6 – Ocular Conformer.

A. Insertion

- ✓ Wash hands thoroughly
- ✓ Place conformer flat on lower eyelid
- ✓ Look downwards
- ✓ Lift the upper eyelid and gently push the conformer upwards under the upper eyelid
- ✓ Look downwards and position the lower eyelid over the lower edge of the conformer

B. Removal

Use a plastic extractor to remove the conformer, as follows:

- ✓ Touch the conformer with extractor tip
- ✓ Push lower eyelid down with extractor until tip is beneath conformer edge
- ✓ Look upwards as the handle of the extractor is brought downwards until nearly flat to the cheek
- ✓ Look downwards and the conformer is normally expelled

C. Cleaning

The conformer should be removed and cleaned with disinfectant every 15 days unless otherwise instructed.

N.B. It is important to keep the holes in the conformer clear as they allow ventilation, drainage and irrigation, which are very important in the healing process.

9. How custom-made ocular prosthesis are made

Each patient is individually assessed and advised. Factors such as lifestyle, environment, and climatic differences may affect the advice given but some general guidance notes are given below.

The following steps are involved: (Fig.7)

1. Taking an impression (A)
2. Centration of the prosthesis (A)
3. Painting of the iris and pupil (B)
4. Molding in acrylic (C)
5. Polishing (D)

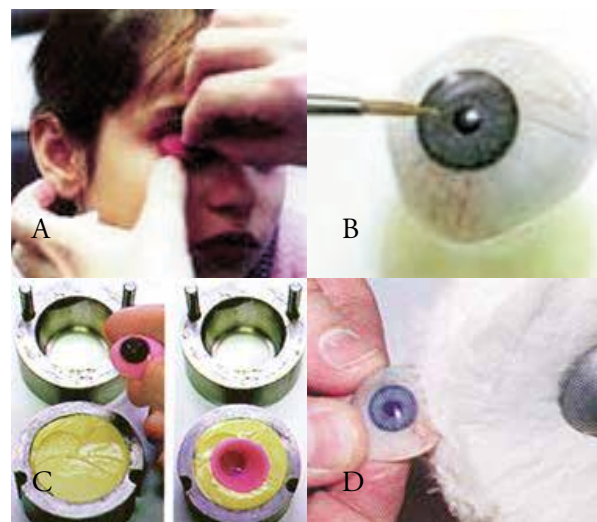


Fig. 7 – Orbital prosthesis.

The process begins by taking an impression of the eye socket to duplicate the exact nature of the space the prosthesis will fit into. Then, the correct positioning of the iris is determined, along with the outer curvature and the extent to which the eyelids will open. The iris is hand painted from direct observation of the unaffected eye. We prepare a master mold which is filled with acrylic plastic to create a cast of the prosthesis. The prosthesis is further colorized and vessels are added to simulate a natural appearance. Finally, the prosthesis is polished to give it a perfectly smooth surface and wet-looking appearance.

10. Use and care advice







It is recommended to clean the prosthesis daily with an eye bath liquid without removing it. Allergies, colds, dust, sand and fatigue can lead to excessive discharge, which leaves no choice but to remove and clean your prosthesis. If there is excessive dryness (most likely in the winter months), it is suggested that you apply a natural oil to the surface of the prosthesis. The oil will bring immediate relief to your eyelids and slow down the development of dryness. (Table 1)

When cleaning the ocular prosthesis it is important to:

- 1) Soap hands, using a mild dishwashing liquid or

30. Ocular Prosthesis

Table 1 – Removing and inserting the ocular prosthesis¹¹.

Removing the prosthesis	Inserting the prosthesis
<p>Pull down the lower lid with your index finger, look up and allow the prosthesis to slide out over the lower lid.</p> 	<p>Wash the prosthesis between your hands with a non-abrasive, fragrance and moisturizer free soap and hot water. Hold the prosthesis between your thumb and middle finger. Lift the upper lid with your other hand.</p> 
<p>Wet the cup, squeeze the stem, and press it against the prosthesis. Relax the squeeze and confirm the cup grips.</p> 	<p>Gently slide the top of the prosthesis under the upper lid.</p> 
<p>Hold down the lower lid as you tilt the prosthesis out and over the lower lid.</p> 	<p>Hold the prosthesis in place with your index finger as you pull down the lower lid with your other hand.</p> 

optic soap.

- 2) Pick up prosthesis and rub vigorously with the fingers.
- 3) Thoroughly rinse hands and prosthesis with water and make sure that all soap is removed. Rinse the prosthesis with a disinfectant. The prosthesis is ready for insertion while it is still wet.

DO NOT expose the prosthesis in any way to alcohol or aggressive substances. It should be used with the recommended products.

11. Ideal prosthesis and socket

Ideally, the posterior part of a prosthesis should be about 7 mm thick and the anterior chamber should be 3 mm thick. It should be light and exert minimal pressure on the orbital tissues in the socket. It must achieve acceptable movement to all sides. The material must be inert in nature. It should effectively correct the volume deficit and also match the appearance of the fellow eye¹².

If the socket does not meet this criterion, the cosmetic appearance is usually compromised. Kaltreider (2000), defines an ideal socket as one that has suitably deep fornices, the volume loss not exceeding 4.2 ml. It should have a well-centered orbital implant with a

conjunctiva and no granulomas. There should be no blepharoptosis, eyelid malpositioning or laxity, sulcus deformity, socket contracture and lagophthalmos. Sockets very often develop various kinds of deformity and thus fitting the prosthesis is a real challenge. Allen (1969) described how to correct the various deformities by using the modified impression technique. The impression of the prosthesis needs to be modified in most cases, due to socket uniqueness, which is why, even in the absence of an ideal socket, a good cosmetic appearance can nearly always be achieved with the modified impression technique¹³.

12. Prerequisites for a good prosthetic fitting

- ✓ Deep fornices in all quadrants
- ✓ Normal tear secretion
- ✓ Effective volume replacement with orbital implants
- ✓ Adequate orbital fat
- ✓ Well-centered and covered orbital implant
- ✓ Absence of socket inflammation

In the absence of inadequate space in the cavity, socket reconstruction surgery can be performed and a custom prosthesis can be provided afterwards¹⁴.

13. Consulting the ocularist

As the plastic artificial eye is porous, it will absorb fluids produced by the mucous membrane tissues. The acids in these fluids will eventually work their way into the plastic and cause small separations in the prosthesis. These separations will ultimately cause discomfort and may lead to infection. It is generally recommended that infants under 3 years old should be seen every 3 months, patients under 9 years old twice yearly, and all other patients at least once a year. It is important for the patient to return annually for a checkup to see if any small fitting changes are needed, since the body is constantly changing. However, the time of such changes varies considerably from patient to patient¹⁵.

14. Life of prosthesis

A prosthesis usually lasts between 5 and 7 years; however, the patient should consult an ocularist at least once a year for the ocular prosthesis to be cleaned and polished⁵.

15. References

1. Doshi, P. J., & Aruna, B. (2005). *Prosthetic management of patient with ocular defect*. J. Indian prosthodontsoc., 5, 37-38;
2. Lubkin V, Sloan S., (1990). *Enucleation and psychic trauma*. AdvOphthalPlastReconstr Sur, 8:259-62;
3. Hooper S., Westcott T., Evans P., Bocca A. & Jagger D., (2005). *Implantsupported facial prosthesis provided by a maxillofacial unit in a U.K. regional hospital: longevity and patient opinions*. J Prosthodont, 14:32-8;
4. Prithviraj, D., Gupta, V., Muley, N.& Suresh, P. (2013).

Custom ocular prosthesis: Comparison of two different techniques, Journal of Prosthodontic Research 57, 129-134;

5. American Association of Ocularists (2015). Resources, consulting at <http://www.ocularist.org>;
6. Roman, F. (1994). *The history of artificial eyes*. Br J Ophthalmol. 78(3): 222;[12] Kaltreider, S., (2000). *The ideal ocular prosthesis: analysis of prosthetic volume*. Ophthal Plastic Reconst Surg;16(5):388–92;
7. Raizada, K., & Rani, D. (2007). *Ocular prosthesis*. Contact Lens & Anterior Eye, 30, 152-162;
8. Hegde, V., Hassija, J., Nayak, R. & Sridhar, N. (2011). *Ocular impressions in children – review of literature and case report*, Indian Journal of Dentistry, volume 2/ Issue 4;
9. Patil, S., Meshramkar, R., Naveen, B. & Patil, N. (2007). *Ocular prosthesis: a brief review and fabrication of an ocular prosthesis for a geriatric patient*, Gerodontology; 25:57-62;
10. Bairo, F., Pereo, S., Ferraris, S., Miola, M., Balanga, C., Verné, E., Vitale-Brovarone, C., Coggiola, A., Dolcino, D. & Ferraris, M. (2013). *Biomaterials for orbital implants and ocular prostheses: overview and future prospects*, Acta Materialia 10; 1064-1087;
11. Artificial Eyes Organization, http://www.artificialeye.net/inserting_removing.htm;
12. Kaltreider, S. (2000). *The ideal ocular prosthesis: analysis of prosthetic volume*. Ophthal Plastic Reconst Surg;16(5):388–92;
13. Allen. et al, (1980). *Artificial eyes and tears measurements*. Am Acad Ophthalmol; 87(2);
14. Allen L., Webster H., (1969). *Modified impression method of artificial eye fitting*. Am J Ophthalmol, 67:189–218;
15. AIOS Presentation. Myoconjunctival technique of enucleation. Debraj Shome;



